



E-ISSN: 2395-1958
P-ISSN: 2706-6630
IJOS 2019; 5(4): 1023-1026
© 2019 IJOS
www.orthopaper.com
Received: 11-08-2019
Accepted: 15-09-2019

Dr. Tahir Husain
Junior Resident, Department of
Orthopedic, M.L.B. Medical
College, Jhansi, Uttar Pradesh,
India

Dr. Abhishek Nagaich
Lecturer, Department of
Orthopedic, M.L.B. Medical
College, Jhansi, Uttar Pradesh,
India

Dr. Paras Gupta
Associate Professor and Head,
Department of Orthopedic,
M.L.B. Medical College, Jhansi,
Uttar Pradesh, India

Corresponding Author:
Dr. Abhishek Nagaich
Lecturer, Department of
Orthopedic, M.L.B. Medical
College, Jhansi, Uttar Pradesh,
India

Management of neglected neck femur fracture in different age group

Dr. Tahir Husain, Dr. Abhishek Nagaich and Dr. Paras Gupta

DOI: <https://doi.org/10.22271/ortho.2019.v5.i4r.1814>

Abstract

Background: Fracture neck femur has been termed as an 'unsolved fracture' as it has always presented a great challenge to the orthopaedic surgeons regarding the ideal management and the prognosis.

Aims and objectives: To study the incidence, causes and management of neglected fracture neck femur.

Materials and methods: Fifty patients having fractures of neck femur presenting after 3 weeks were studied in the Department of Orthopaedics, M.L.B. Medical College, Jhansi, between January 2018 to Aug 2019; after dividing them into two groups. Group A (n=20): patients <60 years of age with fracture neck of femur of >3week since injury treated with valgus inter-trochanteric osteotomy and DHS with 120° double angle barrel plate and Group B (n=30): patients >60 years of age with fracture neck of femur of >3week since injury treated with bipolar hemi hip replacement arthroplasty. A detailed history of patient regarding, age, sex, Mode of injury, duration, associated injuries, past history, clinical examination and radiological examination were done along with the X-Ray pelvis. All cases were followed up at monthly interval after surgery for 6 months and then at three monthly intervals for next 6 months, then 6 monthly interval and results evaluated by using Harris Hip Scoring System (HHS).

Results: Mean age of patients in Group A was 38.9 years and that in Group B was 74.6 years. Mean Pauwel's angle, neck shaft angle and limb length shortening and Harris Hip Score was improved post operatively in Group A. The mean HHS in group B preoperatively was 65.6 and after surgery it was increased to 91.4. Quality of internal fixation was satisfactory in 90% cases. Consolidation at osteotomy site was achieved in 95% cases. In 80% cases fracture united within 6 months. In Group B, 4 patients lost to follow up, out of 26 remaining patients, 14 patients had no pain and 10 patients had slight pain at the end of 6 months. Out of these 7 patients had no limp and 19 patients had slight limp. At the end of one year, 21 (80.7%) patients could walk more than 1000 meter with single cane.

Conclusion: Valgus osteotomy in young and bipolar hemi hip replacement arthroplasty in elders has high success rate in neglected fracture neck of femur.

Keywords: Valgus osteotomy, Pauwel's angle, Hip fractures, neck femur

Introduction

Hip fractures are devastating injuries that most often affect the elderly and have a tremendous impact on both the health care system and the society in general. Fracture of neck femur mostly occurs in osteoporotic elderly individuals as a result of trivial or moderate injuries [1].

The incidence of fracture neck femur is increasing among young patients who sustain high energy trauma. The term 'insufficiency fractures' have been used to describe femoral neck fractures in elderly patients with osteoporosis [2].

The problem become still more difficult in neglected/ununited femoral neck fracture. The ingenuity of orthopaedic surgeons has been demonstrated by the widely different methods of treatment which they have advocated, and each of these methods has been successful in promoting bony union in certain proportion of cases [3].

This study is conducted to evaluate the result of valgus intertrochanteric osteotomy along with internal fixation (DHS with 120° double angle barrel plate) in younger patient (<60 years of age) and hemi hip replacement arthroplasty with bipolar prosthesis in elderly patients (>60 years of age) with neglected fracture neck femur.

Materials and Methods

The present study was conducted in the Department of Orthopaedics, M.L.B. Medical College,

Jhansi, between January 2018 to Aug 2019: including 50 cases having fractures of femur neck, presenting after 3 weeks without treatment or improper treatment.

Patients with fractures presenting <3 weeks, pathological fracture, compound fracture and MRI showing avascular necrosis of femoral head were excluded from the present study.

Patients were divided into two groups depending on the age and methods used for treatment. Group A (n=20): Patients <60 years of age with fracture neck of femur of >3week since injury, treated with valgus inter-trochanteric osteotomy and DHS with 120° double angle barrel plate.

Group B (n = 30): Patients >60 years of age with fracture neck of femur of >3week since injury treated with bipolar hemi hip replacement arthroplasty.

A detailed history of patient regarding, age, sex, mode of injury, duration, associated injuries, past history, clinical examination and radiological examination were done. X-Ray pelvis with both hip-Antero-Posterior view in 15° internal rotation was also performed.

X-Ray of affected hip (lateral view) was performed to observe site of fracture, type of fracture (Anatomical, Pauwel's type), and pre-operative drawing, quality of bone, amount of neck absorption and degree of posterior comminution. MRI was done to assess the vascularity of femoral head.

Both the techniques were performed in their respective groups. All cases were followed up at monthly interval after surgery for 6 months and then at three monthly intervals for next 6 months, then 6 monthly interval and results were evaluated using Harris Hip Scoring System (HHS). Grading for the Harris Hip Score was taken as Poor (<70) Fair (70-79), Good (80-89) and Excellent (90 -100).

All the data analysis was performed using IBM SPSS ver. 20 software. Frequency distribution was performed to prepare the tables. Quantitative data was expressed as mean and standard deviation whereas categorical data was expressed as percentage.

Results

Out of 50 patients, the age of patients in Group A (n=20) varied from 20-56 years (avg. 38.9 years) and age of patients in Group B (n=30) varied from 62-94 years (avg. 74.6 years). Out of 50 patients, 56% cases were male and 44% cases were female. Seventeen in Group A and 11 patients in Group B were males.

In our study of 50 cases of fracture neck femur there were 78% cases of pauwel's type 3 and 22% cases were pauwel's type 2 fracture. Among Group A, 17 (85%) cases were pauwel's type 3 and 3 cases (15%) were pauwel's type 2 whereas in Group B, 22 patients were of pauwel's type 3 and 8 were of pauwel's type 2.

Most of the cases (48.0%) were transcervical type of fracture followed by basal type of fracture (28.0%) then sub capital type (24.0%). Most of the patients in group A were transcervical type while in group B, all the variety of fracture were in equal proportion (10 each).

Out of 50 cases, there were no associated bony injuries present in 82% cases (41 patients) while 16% cases (8 patients) had associated distal end radius fracture. In Group A (n=16) and Group B (n=25) majority had no associated bony injuries.

Quality of internal fixation in Group A was not satisfactory in 10% cases. Dynamic hip screw was placed in antero-superior quadrant. The satisfactory portion was considered to be central or postero-inferior quadrant in head of femur.

Satisfactory placement was achieved in 90% cases. Consolidation at osteotomy site achieved in 95% cases, in one case consolidation at osteotomy site was not satisfactory due to comminution at osteotomy site. In 80% cases fracture united within 6 months. Three cases united within 7 months and one case passed in to non-union due to cut through of Richard's screw from head of femur.

Table 1: Comparing different pre and post-operative parameters in Group A

Parameters	Preoperative	Postoperative
Pauwel's angle	62.53 ⁰	32 ⁰
Neck shaft angle	97.4 ⁰	135.6 ⁰
Limb length discrepancy (cm)	2.32	0.4
Harris Hip Score (HHS)	65.6	91.4

Group B patients were followed up regularly up to a period of 12 months. Four patients were lost in follow up and hence the observations are based on the study of only 26 patients and results evaluated by using Harris Hip Score.

Table 2: Functional Evaluation in Group B

	Function	No of patients	Percentage
Pain	None	14	53.8
	Slight	10	38.4
	Mild	2	7.7
	Moderate	0	0
	Marked	0	0
Limp	Disabling	0	0
	None	7	26.9
	Slight	19	73.0
	Moderate	0	0
Support	Severe	0	0
	None	4	15.3
	Single cane for long walks	16	61.5
	Single cane for most of the time	5	19.2
	One crutch	0	0
	Two canes	1	3.8
	Two crutches	0	0
Distance walked	Not able to walk	0	0
	Unlimited	8	30.7
	<1000 meter	13	50
	<500 meter	4	15.3
	Indoor only	1	3.8
	Bed and Chair	0	0

Table 3: Showing activities in Group B

	Activity	No of patients	Percentage
Stairs	Without banister	5	19.2
	Using banister	14	53.8
	In any Manner	6	23
	Unable	1	3.8
Putting on shoes and socks	With easy	18	69.2
	With difficulty	8	30.8
	unable	0	0
Sitting	Comfortable in any chair for one hour	24	92.3
	Comfortable in high chair for one hour	2	7.7
	Unable to sit in any chair	0	0
Public transportation	Able to enter	11	42.3
	Unable to enter	15	57.7

There were no fixed deformities in the study. Two patients (7.6%) had shortening of 1cm. One patient (3.8%) had lengthening of 0.5 cm. Range of motion is determined by

using Harris Hip Scoring system. 18 patients (69.2%) had a score of 5 indicating good range of motion, while 8 patients (30.8%) had a score of 4.

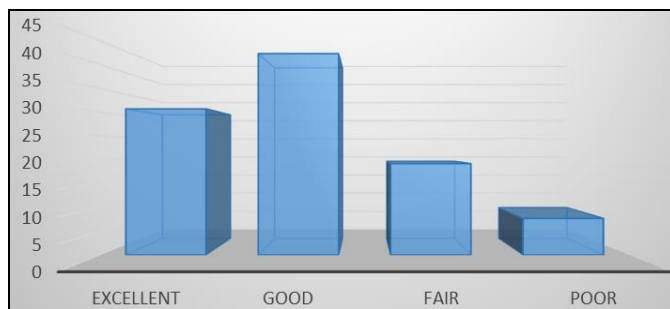


Fig 1: Showing results based on Harris Hip Score in Group

In group A one patient had superficial infection at the incision site which subsided with the course of antibiotic. In three cases there were 0.4 cm shortening left post operatively due to under correction and in one case there was gain in length of 0.6 cm due to over correction. Among the 20 cases, one case passed in to non-union due to failure of fixation from femoral head.

In Group B two patients developed superficial infection and it was noticed on 7th postoperative day which subsided with course of antibiotics, according to culture sensitivity report. In one patient prosthesis dislocated which was reduced under general anaesthesia.

Discussion

If the fracture neck of femur remains untreated for more than 3 weeks, internal fixation alone is likely to have high rate of non-union, as reported by Barnes *et al.* [4]. The choice of treatment depends considerably on age of the patients, functional demands, and congruity of the femoral head. The head preservation is the treatment of choice in younger individual with congruous head [5].

Group A

In our study 20 young patients with neglected fracture femoral neck treated with valgus osteotomy and internal fixation with dynamic hip screw and 120 double angle barrel plate plays effective role in union of non-union site. It converts the shearing forces in to compressive forces by placing the fracture site perpendicular to the resultant of body weight forces and also produces compression at fracture site. In most of studies reported in literature on valgus osteotomy, blade plate fixation has been used, which is technically demanding but blade may displace the fracture and minimal change in direction of blade may change the direction of plate anterior or posterior to the shaft femur.

In our series, the age of the patient in group A varied from 20 to 56 years. The average age was 38.9 years. In another series of 146 cases of femoral neck fractures, the average age was 58.2 years. [6] In study of Marti *et al.* [5], mean age was 53 years with a range of 19 to 76 years and union was achieved in 86% of cases at an average of 3.6 months.

In Balimer *et al.* mean duration was 32.14 weeks (range 13 to 73 weeks) [7]. Carlos Roberto *et al.* [8] reported a mean duration of 6.5 months. 8 In our study of 20 cases, 80% cases (n=16) were operated between 3 to 12 weeks of injury and mean duration of operation was 9.6 weeks.

In our study, 70% (n=14) cases were of transcervical variety, 20% (n=4) were of basal type and 10% (2) were of subcapital type while in study of Zehi K *et al.* 53% cases were of

subcapital type, 40% were of transcervical type and 7% cases were of basicervical type [9].

In our study, Pauwel's type III (85%) was most common and pauwel's type II was 15%. Similar to that Balimer *et al.* reported that the commonest was type III (52.9%), and type II was 47.1%. [7] In study of Marti *et al.* the most common was type III (62%) Whereas type II was 32% and type I was 6% [5]. In our study of 20 cases of fracture neck femur, 17 cases of pauwel's type III variety united well within 5 to 6 months except 2 cases. Post-operative corrected pauwel's angle in all cases was 28-35°. Postoperative pauwel's angle in these cases was 25°-30°.

In our study union site is defined by presence of trabeculae across and absence of fracture line. Average preoperative pauwel's angle and neck shaft angle was 62.5° and 97.4° respectively which was 32 and 135.6 degree respectively after surgery. In 80% (16) cases fracture united within 6 months of operation and average time for union of fracture site was 5.2 months.

In 15% (3) cases fracture united at 8 months of operation and one case failed to unite (5%) and also developed avascular necrosis of femoral head after which patient was planned for THR. Mean rate of union in Marti *et al.* was 14.4 weeks with a range of 8-32 weeks. In his study out of 50 cases, 47 attained bony union with 3 cases of nonunion [5] In Balimer *et al.* out of 17 cases, 15 attained union with two cases of nonunion [7].

In our study of 20 cases, average follow up was 11.5 months. All cases were followed up for more than one year. Follow-up was done by clinical and radiological assessment. In study of Sharma *et al.* average follow up was 18 months (12-38 months) [6]. The average limb length shortening preoperatively was 2.32cm, decreased to 0.4cm after surgery. Galal *et al.* reported preoperative limb shortening averaged 2.5 cm and post-operative shortening averaged 0.5 cm [10]. Bansal *et al.* reported that in 83% patients no limb length discrepancy present postoperatively [11].

In our series of 20 cases there were pre-operative shortening in all cases. In 80% cases there were no limb length discrepancy after operation. Post operatively we achieve full correction. In 15% cases there was 0.4 cm. shortening left postoperatively due to under correction. In 5% cases there was gain in length of 0.6 cm due to over correction. In all patients of study of Sharma *et al.* there was limb length discrepancy of average 1.5 cm after osteotomy [6]. The average Harris Hip Score preoperatively was 65.6 and after surgery it was increased to 91.4. Marti *et al.* in their study of 50 patients reported mean Harris Hip Score improvement up to 91 [5].

In our study, there was a superficial infection in 5% cases at incision site which subside after a course of antibiotics. 4.2% cases showed stiffness due to inappropriate physiotherapy. In study of Bailmer *et al.* there was a 5.9% incidence of post-operative infection [7].

Group B

Fracture neck femur are relatively common injuries among the elderly individuals. In order to reduce the morbidity and mortality, the aim of the management should be towards making the patient mobile. Hemiarthroplasty is advocated as best modality of these fractures.

In 80% of patients with bipolar arthroplasty, common sizes of prosthesis used were 41mm-45mm. The smaller size of prosthesis required may be due to comparatively smaller structure of average Indians as compared to different races.

Raghvendra *et al.* used 45mm prosthesis in 55% of cases followed by 43mm (30%), 47mm (15%) and 41mm (5%) prosthesis in the order of frequency. The average period of hospitalization was 19.3 days^[12]. This is comparable to the study of Gilberty *et al.* where, average duration of stay was 21 days^[13].

In our study of bipolar arthroplasty, 92.3% patients had none to slight pain and only 7.7% patients had mild pain. This was comparable to other studies. Labelle *et al.*^[14] reported 79.2% and Calder *et al.*^[15] reported 65%. This confirm that bipolar endoprosthesis provides pain free hip in most of the cases.

In our study 61.5% of the patients could walk for long distance with single cane which is similar to reports of Wethrell *et al.*^[16] and Vishwanath *et al.*^[17]. In our study most of our patients did not have restriction of daily activities. All patients could climb stairs with or without the help of Banister, could sit comfortably on chair for long hours and they had no problems in putting shoes and shocks. In our study there were no fixed deformities, only 2 patients (6.67%) had minimal shortening of 1.0cm and only 1 patients (3.3%) had minimal lengthening of 0.5cm in contrast to the requirement of <3.2cm limb length discrepancy in Harris Hip Score.

Conclusion

Valgus osteotomy and internal fixation by DHS with 120 double angel barrel plate has high success rate in young patients with neglected fracture neck of femur in whom preservation of head is preferred as compared with head-sacrificing procedure like total hip replacement. The incidence of fracture neck femur is maximum in elderly patients, commonly in female due to post-menopausal osteoporosis. Aim is to mobilize the patients as early as possible to reduce the morbidity and mortality. Bipolar arthroplasty is safe, less time consuming and gives good to excellent results, and also provides movements at two sites, thus lessen the wear and tear and increases the stability of the hip.

References

1. Freeman MA, Todd RC, Pirie CJ. The role of fatigue in the pathogenesis of senile femoral neck fractures. *J Bone Joint Surg Br.* 1974; 6-B(4):698-702.
2. Swiontkowski MF *et al.* Current concepts review of intracapsular fracture of hip. *JBJS.* 1994; 76A:129-135.
3. Sandhu HS. Management of fracture neck of femur. *Indian J Orthop.* 2005; 39:130-6
4. Barnes FR, Brown JT, Garden RB, Nicoll BA. Subcapital fracture of femur. A prospective review. *JBJS.* 1976; 58:B2.
5. Marti RK, Schuiler HM, Raaymakers ELEB. Intertrochanteric osteotomy for nonunion of the femoral neck. *J Bone Joint Surg (Br).* 1989; 71-B:782-787.
6. Manish S, Sood LK, Kanojia RK, SudAlok. Valgus osteotomy for nonunion fracture neck femur. *Indian Journal of Orthopaedics.* 2004; 38(2):88-91.
7. Balimer FT, Bailmer PM, Baumgartel F, Ganz Mst JW, pauwel's osteotomy for nonunions of the femoral neck. *Orthop Clin North Am.* 1990; 21:759-767.
8. Schwartzmann CR, SpinelliL De F, Yépez AK, Boschín LC, Silva MF. Femoral neck non-union treatment by valgus intertrochanteric osteotomy. *Acta Ortop Bras.* 2015; 23(6):319-322.
9. Zehi K, Bouguira A, Saadaoui F. Valgus osteotomy in the treatment of pseudarthrosis of the femoral neck. *Rev Chir*

- Orthop Reparatrice Appar Mot. 2001; 87:562-8.
10. Galal S, Farouk, Osama, El-Sayed A, Said, Hatem. Salvage of failed dynamic hip screw fixation of intertrochanteric fractures. *Injury.* 2006; 37:194-202.
11. Bansal P, Singhal V, Lal H, Mittal D, Arya RK. A Convenient Way to do Valgus Osteotomy for Neglected Fracture Neck of Femur. *Kathmandu University Medical Journal.* 2013; 11(2):147-151.
12. Raghvendra TS, Jayakrishna Reddy BS, Jithuram Jayaram. Management of Fracture Neck of Femur with Cemented Bipolar Prosthesis. *Indian Journal of Clinical Practice.* 2014; 24(9):861-871.
13. Giliberty RP. Bipolar endoprosthesis minimizes protrusion acetabuli, loose stems. *Ortho Review.* 1985; 14:27.
14. LaBelle LW, Colwill JC, Swanson AB. Bateman bipolar hip arthroplasty for femoral neck fractures-A five to ten year follow up study. *Clin Orthop.* 1990; 251:20-25.
15. Cadler SJ, Anderson GH, Jagger C, Harper WM, Gregg PJ. Unipolar or bipolar prosthesis for displaced intracapsular hip fracture in octogenarians: A randomized prospective study *J Bone Joint Surg Br.* 1996; 78:391-4.
16. Wetherell RG, Hives BL. The Hastings bipolar hemiarthroplasty for subcapital fractures of the femoral neck: a 10-year prospective study. *J Bone Joint Surg [Br].* 1990; 72-B:788-793.
17. Vishwanath C, Sushanth B. Mummigatti. Comparative study between Austin Moore prosthesis and bipolar prosthesis in fracture neck of femur. *National Journal of Clinical Orthopaedics.* 2017; 1(2):53-61.