



International Journal of Orthopaedics Sciences

E-ISSN: 2395-1958
P-ISSN: 2706-6630
IJOS 2019; 5(4): 903-907
© 2019 IJOS
www.orthopaper.com
Received: 08-08-2019
Accepted: 12-09-2019

Dr. J Solomon Thomas
M.S. Orthopedics, Christian
Medical College and Hospital,
Ludhiana, Punjab, India

Dr. Rajesh Paul
Professor and Head of
Department, Department of
Orthopedics, Christian medical
College and Hospital, Ludhiana,
Punjab, India

Dr. Anupam Mahajan
M.S., DNB. Orthopedics,
Professor, Department of
Orthopedics, Christian Medical
College and Hospital,
Ludhiana, Punjab, India

Corresponding Author:
Dr. J Solomon Thomas
M.S. Orthopedics, Christian
Medical College and Hospital,
Ludhiana, Punjab, India

Functional outcome in non-operative management of displaced Intra-articular calcaneal fractures (Diacf's)

Dr. J Solomon Thomas, Dr. Rajesh Paul and Dr. Anupam Mahajan

DOI: <https://doi.org/10.22271/ortho.2019.v5.i4p.1795>

Abstract

Displaced intra-Articular calcaneus fractures (DIACFs) represent a source of potential disability to the patient, economic burden to the society and a treatment challenge to the average orthopedic surgeon. Despite lack of evidence whether operative management is superior to non-operative management, there is a trend favoring the former. This was a 2 year retrospective study & a 1 year prospective study of 37 patients with 44 displaced intra-articular calcaneal fractures managed non-operatively to observe the functional outcome of intra-articular fractures of calcaneus in adults in an Indian population. Each patient was followed up at 3, 6, 9 months and 1 year from injury. Appropriate lateral and axial view x-rays done at 3 months and 1 year follow-ups and radiological assessment done. Retrospective patients from previous two years were re-assessed with appropriate x-rays and functional outcome scoring done. The AOFAS score was assessed and recorded at each of these follow-ups.

In our study of 37 patients with 44 displaced intra-articular calcaneal fractures, AOFAS clinical outcome at 1 year was excellent in 7 cases (15.91%), good in 29 cases (65.91%), fair in 7 cases (15.91%) and poor in one case (2.27%). Complications were seen in 11 patients at one year follow-up but none of the patients with complications required any surgical intervention and the average AOFAS functional outcome score at 1 year was 80.43 (Good). We hereby conclude that non-operative management of intra-articular calcaneal fractures continues to be an acceptable mode of treatment with low complications and comparable functional outcome with less complications.

Keywords: Calcaneal fracture, intra-articular, displaced, non-operative treatment, complications, AOFAS score, functional outcome

Introduction

The calcaneus (heel bone) or Os Calcis is the largest & most frequently injured tarsal bone. Calcaneus fracture can be a painful and disabling injury usually caused by a high-energy injury such as a fall from height where the heel is crushed under the weight of the body or a motor vehicle accident. Calcaneus injuries represent 2% of all fractures seen in adults. Intra-articular fractures constitute 70% and are most commonly seen in young men with mean age of 35-40 years^[1].

An axial load causes a displaced intra-articular calcaneal fracture (DIACF) & leads to crushing and sheering injury of the bone. Primary and secondary fracture lines develop. The primary fracture lines run through the posterior facet of the subtalar joint creating a superolateral fragment and a superomedial or "constant fragment" which includes the sustentaculum tali. If this force continues even further, a secondary fracture line is created. Depending on the direction of the force, it may form a tongue-type fracture or joint depression-type fracture^[2].

Radiological evaluation of calcaneal fractures is essentially to classify the fracture as intra-articular or extra-articular, but other angles and parameters such as Bohler's angle, critical angle of Gissane, Talar and tibial alignment, calcaneal height, width, length and varus angle also constitute in assessing fracture and help in planning treatment. Assessment of fracture fragments, displacement, intra-articular extension, lateral wall blow-out, bone quality and comminution are part of reading a calcaneal fracture radiograph^[3].

Coronal CT imaging at the widest part of the posterior facet allows us to classify displaced intra-articular calcaneal fractures (DIACF's) based on the classification proposed by Sanders *et al.* in 1993 which is particularly used in pre-op planning. Type I fractures are nondisplaced; type II are two-part or split fractures; Type III are three-part or split depression fractures; and

Type IV are four-part or highly comminuted articular fractures [4].

With conservative treatment alone, the calcaneus can heal but remains deformed. This leads to incongruity of the subtalar joint and widening of heel, loss of talo-calcaneal lever arm. Walking on the incongruous joint may give rise to osteoarthritis of the subtalar joint and pain [5].

Over the past two decades the pendulum has swung back towards surgical management due to improved surgical techniques and less soft tissue stripping. However, anatomic restoration is not necessarily associated with good outcome in terms of function and quality of life. It is also well established that pre-existing co-morbidities such as peripheral vascular disease, diabetes and smoking adversely affect wound healing following operative management [2].

Non operative management consists of initial treatment of all patients with bed rest, analgesia, elevation, ice packs and splintage till swelling subsides & soft tissues start healing. Early mobilization of ankle & subtalar joints was started while continuing patient on non-weight bearing ambulation. Operative treatment often involves surgery to reconstruct the normal anatomy of the heel and restore height & mobility using various techniques such as closed reduction with percutaneous pinning, open reduction & fixation (ORIF), or ORIF combined with primary subtalar arthrodesis.

Wound complications (10-25%) with increased risk in smokers, diabetics, and open injuries are common in fractures treated operatively. Subtalar arthritis requiring subtalar arthrodesis later, compartment syndrome (10%), and malunion also lead to poor results of calcaneal fracture treatment [6].

Recent advances in fixation devices and antibiotics have improved outcomes with operative management. Some studies have confirmed better results with operative treatment but still associated with considerable morbidity [7-10] However many subsequent and recent meta-analysis studies have shown that there is no significant improvement in overall outcomes between operative and non-operative management and in some cases non-operative management is better [11, 12].

In Indian population which practises open foot wear, poor foot hygiene, poor patient compliance, and need for cost-effective treatment, a non-operative line of management may find better acceptance.

The aim of this study is to observe the radiological and functional outcomes of displaced intra-articular calcaneal fractures (DIACF's) managed non-operatively.

Material and Methods

This observational study was conducted in the department of Orthopedics at CMC hospital, Ludhiana as a 2 year retrospective study (30th November 2014 to 30th November 2016) & a 1 year prospective study (1st December 2016 to 1st December 2017), of all patients with intra-articular fractures of calcaneus managed non-operatively. Only adult patients in the age group of 18 to 65 were included. Patients with associated ankle injuries, or other tarsal bone fractures and patients with associated neurological or vascular injuries were excluded.

After obtaining consent, appropriate x-rays of the foot in lateral and axial views were obtained. The patients received either a short leg splint or a jones bandage for the injured limb. The patients who were treated non-operatively had no attempt at closed reduction and were treated only with rest, elevation and ice packs. Splint is continued for 6 weeks to prevent equinus of the ankle and allow soft tissue healing.

Based on radiological union and pain status, patient is advised partial weight bearing at 2 months and full weight bearing at 4 months. Non-operative management also consisted of early non-weight bearing movement exercises of subtalar and ankle joints, as tolerated.

The patients were followed up at 3 months, 6 months, 9 months and 1 year from injury. Appropriate lateral and axial view x-rays done at 3 months and 1 year follow-ups and radiological assessment done. The American Orthopedic Foot and Ankle Society hind foot scale (AOFAS score) was assessed and recorded at each of these follow-ups. The maximum score is 100. Functional outcome was graded as excellent (score greater than 85), good (score 70-84), fair (score 55-69) and poor (score less than 55) (Appendix 1). Retrospective patients were selected from patient records treated here from last 2 years and were reviewed with appropriate check x-rays and AOFAS functional scoring done.

Radiological assessment included Böhler angle, Angle of Gissane, Calcaneal inclination angle, Lateral talocalcaneal angle, Tibiocalcaneal angle, Talar declination angle, Length of the calcaneus, Absolute foot height, Height of the posterior facet, Width of the calcaneus, and Calcaneal varus angle measured on appropriate lateral and axial views of the foot. Radiological outcomes were compared with final functional outcome scores. The data was entered in pre-designed data collection forms, and the functional and radiological outcomes from the data obtained were studied. Data was summarized using frequency distribution and descriptive statistical analyses.

Results

Out of 44 intra-articular calcaneal fractures in 37 patients, 24 were retrospective patients (64.86%) with 29 fractures and 13 were prospective patients (35.14%) with 15 fractures managed non-operatively. The mean age of patients in our study was 46 years, minimum age was 21 years and maximum age was 71 years.

The study of 44 intra-articular calcaneal fractures in 37 patients managed non-operatively showed an excellent AOFAS clinical outcome in 7 patients (15.91%), predominantly good score in 29 patients (65.91%), fair score in 7 patients (15.91%) and poor score in one patient (2.27%). Overall, 36 fractures (81.82%) had good/excellent functional outcome.

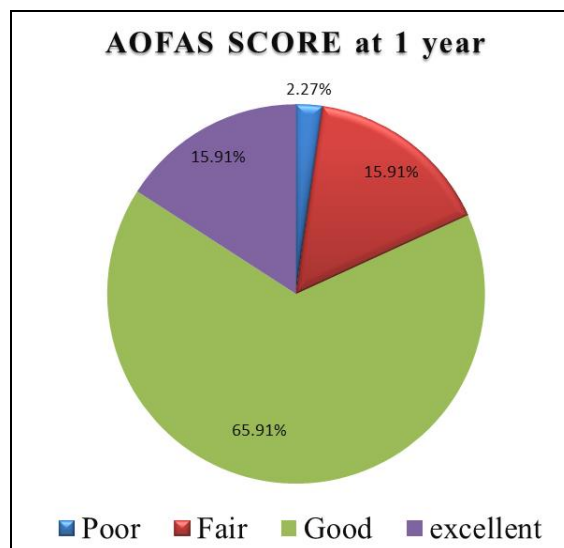


Fig 1: Overall final AOFAS outcome score distribution

There was a preponderance of males in our study with 30 males (81.08%) and only 7 females (18.92%). Bilateral fractures was observed in 7 patients (18.92%) and all 7 patients (100%) had good/excellent AOFAS outcome scores. Among 30 unilateral patients, 24 patients (80%) had good/excellent outcome while 6 patients (20%) had poor/fair outcome.

The study included patients with various occupations. Predominant patients were farmers (18.92%), homemakers (13.51%) and self-employed (13.51%). 21 patients (56.76%) were admitted while the rest 16 patients (43.24%) were managed on outpatient basis with same protocols of management. Systemic factors were observed in 13 patients (35.14%) with hypertension being predominant, seen in 7 patients (53.85%), followed by diabetes in 2 patients (15.38%) and smoking in 2 patients (15.38%).

The predominant mode of injury was by fall from height as seen in 31 patients (83.78%), followed by RTA in 5 patients (13.51%) and fall of heavy object in 1 patient (2.70%). The study had predominantly closed fractures as seen in 34 patients (90.91%) as compared to 4 open fractures in 3 patients, one patient with bilateral open fractures (9.09%). Good/excellent AOFAS outcome scores was observed in 3 intra-articular open calcaneal fractures in 2 patients (75%) while one patient (25%) with unilateral open fracture had poor outcome. Closed fracture patients had good/excellent outcome in 33 fractures (82.5%) and poor/fair outcomes in 7 patients (17.50%).

Patients were started on weight bearing based on clinical and radiological progress in fracture healing and data was collected. The study showed good/excellent AOFAS outcome scores in 15 patients (83.33%) and poor/fair outcomes in 3 patients (16.67%) who were started on early partial weight bearing (<= 2 months). AOFAS outcome scores were good/excellent in 21 patients (80.77%) and poor/fair in 5 patients (19.23%) who were started on late partial weight bearing (>2 months). AOFAS outcome scores was good/excellent in 19 patients (76%) and was poor/fair in 6 patients (24%) who were started on early full weight bearing (<=4 months). AOFAS scores were good/excellent in 17 patients (89.47%) and poor/fair in 2 patients (10.53%) started on late full weight bearing (>4 months).

The study showed a mean Bohler's angle of 13.2 degrees at injury and 15.53 degrees at 1 year follow-up as compared to a mean angle of 27.87 degrees on the uninjured normal foot. The Bohler's angle at the final follow-up at 1 year showed good/excellent AOFAS outcome scores in 25 patients (75.76%) and poor/fair scores in 8 patients (24.24%) with deranged Bohler's angle. Also, all 11 patients with normal Bohler's angle at final follow-up had good/ excellent AOFAS outcome scores.

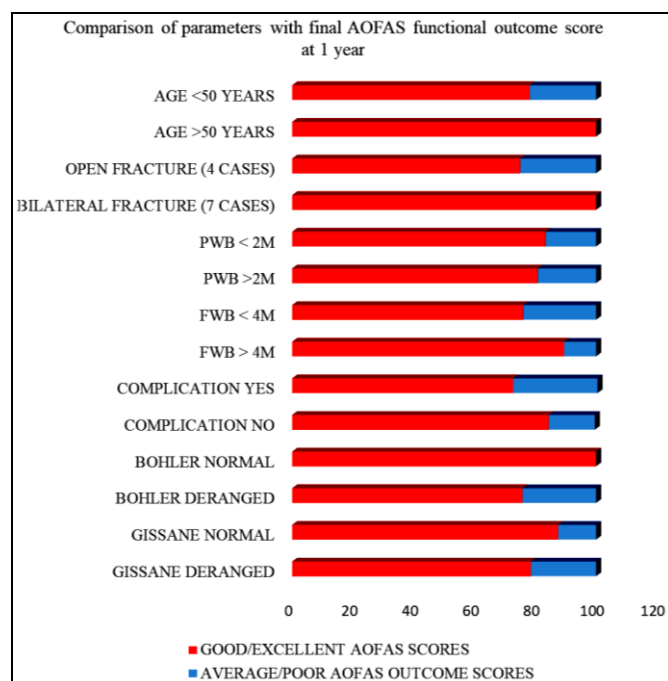
The study showed a mean Gissane's angle of 126.8 degrees at injury and 121.17 degrees at 1 year follow-up as compared to a mean angle of 118.47 degrees on the uninjured normal foot. The Gissane's angle at the final follow-up at 1 year showed good/excellent AOFAS outcome scores in 22 patients (78.57%) and poor/fair scores in 6 patients (21.43%) with deranged Gissane's angle. Also, 14 patients (87.50%) with normal Gissane's angle at final follow-up had good/ excellent AOFAS outcome scores and 2 patients (12.50%) had poor/fair outcome scores.

The study showed a mean varus angle of 77.93 degrees at injury and 82.47 degrees at 1 year follow-up as compared to a mean angle of 87.13 degrees on the uninjured normal foot.

The varus angle showed good/excellent AOFAS outcome scores in 8 patients (66.67%) and poor/fair scores in 4 patients (33.33%) with deranged Varus angle. Also, 28 patients (87.50%) with normal varus angle at final follow-up had good/ excellent AOFAS outcome scores and 4 patients (12.50%) with normal Varus angle had poor/fair outcome scores.

The study of correlation showed a weakly positive linear relationship with the length and height of calcaneus and respective AOFAS scores and a weakly negative linear relationship with the width of calcaneus at 1 year follow-up. However the findings were not statistically significant.

The study 16 fractures (36.36%) in 11 patients with complications at the end of one year follow-up. Early subtalar arthritis was seen in 4 fractures (9.09%), varus malunion was seen in 6 fractures (13.64%), altered gait was seen in 3 fractures (6.82%), superficial wound infection was seen in 2 fractures (4.55%), and peroneal tenosynovitis was seen in 1 fracture (2.27%). The study showed good/excellent AOFAS outcome scores in 8 patients (72.73%) with complications as compared to poor/fair scores in 3 patients (27.27%) among 11 patients with complications.



Legends: PWB*- Partial weight bearing / FWB†- Full weight bearing

Fig 2: Comparison of parameters with final AOFAS functional outcome score at 1 year

Discussion

Displaced intra-Articular calcaneus fractures (DIACFs) represent a source of potential disability to the patient, economic burden to the society and a treatment challenge to the average orthopedic surgeon. Despite lack of evidence whether operative management is superior to non-operative management, there is a trend favoring the former.

In our study of 44 displaced intra-articular calcaneal fractures in 37 patients treated non-operatively with either short leg splint or jones bandage, we have observed a good/excellent overall functional AOFAS outcome score in 36 fractures (81.82%) with a mean value of 80.43. This finding was comparable to other studies on operative, and non-operative methods of treatment as shown in the table below.

Table 1: AOFAS overall outcome

| Study | Mode of treatment | No. of patients | Avg. score |
|--|--------------------------------------|-----------------|------------|
| Kennedy <i>et al.</i> (2003) ^[13] | ORIF | 10 | 65 |
| | ORIF + bone graft | 12 | 64 |
| | Non-operative | 14 | 53 |
| Ibrahim <i>et al.</i> (2007) ^[14] | MIS with K-wire fixation | 15 | 70.0 |
| | Non-operative | 11 | 78.5 |
| Zwipp <i>et al.</i> (2013) ^[15] | ORIF | 163 | 70.2 |
| Agren <i>et al.</i> (2013) ^[16] | ORIF | 42 | 81.0 |
| | Non-operative | 40 | 77.2 |
| Griffin <i>et al.</i> (2014) ^[12] | ORIF | 54 | 79.2 |
| | Non-operative | 60 | 76.8 |
| Van Hoeve <i>et al.</i> (2015) ^[17] | ORIF | 13 | 72 |
| Li <i>et al.</i> (2016) ^[18] | MIS with screw fixation / Mini-plate | 9 | 89.0 |
| | Non-operative | 9 | 88.2 |
| Pawar <i>et al.</i> (2018) ^[19] | ORIF with bone grafting | 21 | 82.61 |
| | ORIF without grafting | 21 | 79.9 |
| Prabhakar <i>et al.</i> (2018) ^[20] | ORIF by 'open-envelope technique' | 30 | 75.1 |
| Present study | Non-operative | 37 | 80.43 |

External factors such as age, occupation, co-morbidities, and initial swelling/ soft tissue injury had no influence on the final radiological healing or functional outcome scores. Non-operative treatment poses no technical challenge and has good results even in the hands of young orthopedicians. Easy outpatient application of jones bandage/short leg splint avoids hospital stay and decreases morbidity of the patient.

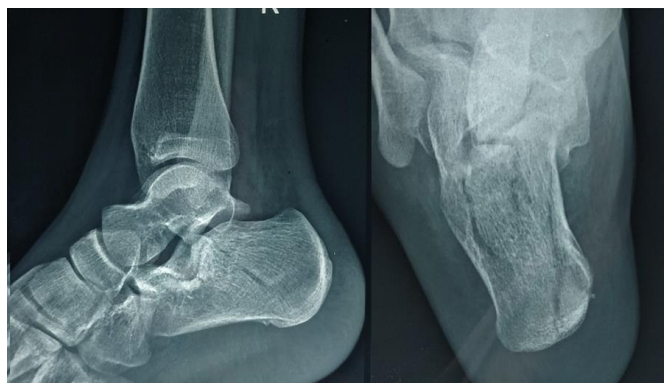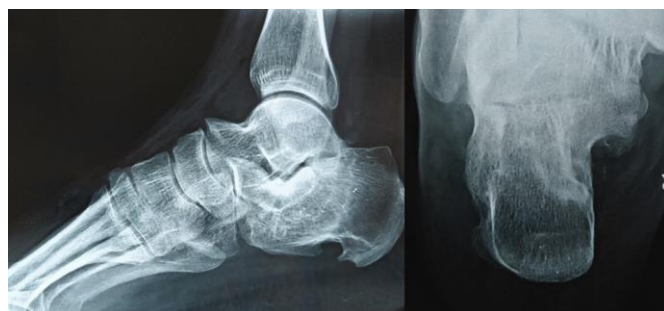Radiological outcomes compared with functional outcomes showed no significant results in our study. Bohler's and Gissane's angle continue to be the best radiological parameters to assess outcomes. Poor initial Bohler's angle had poor functional outcome with non-operative treatment at the end of 1 year but the finding was not statistically significant. Other parameters such as varus angle, height and width of calcaneus play important roles.

Influence of delayed partial and full weight bearing have significant effects on overall functional outcomes as observed in our study. Delayed full weight bearing after complete radiological healing at 4 months is recommended. Early non weight bearing ambulation and ankle range of motion exercises also showed better healing with easy return to daily activity. Sports shoes or other custom made comfortable shoe wear with a higher heel help to abate post healing symptoms and allow painless daily activities.

Complications such as varus malunion, altered gait, superficial wound infection, and peroneal tenosynovitis were observed in a small percentage of patients. However no significant effect on functional outcome scores at one year was observed. 4 open fractures were treated in our study of which two patients developed superficial skin infections and one of them had fair outcome score.

Poor outcome score was observed in only 1 patient who had highly deranged initial Bohler's angle and severe posterior facet comminution. He was ambulant with moderate difficulty in daily activities but had chronic pain and also developed early subtalar arthritis at the end of one year.

The study had limitations such as the limited number of cases, due to which obtaining statistically significant inference was difficult. Both open and closed cases were included in the study and considered together for outcome analysis. The outcome was not analyzed as per Sander's classification since the number of cases were few. Limited follow-up period of one year does not allow us to generalize the results.

**Fig 3:** Sample x-rays of patient at the time of injury**Fig 4:** Sample x-rays of patient at 1 year follow-up with good functional outcome score

Conclusion

Non-operative management of intra-articular calcaneal fractures continues to be an acceptable mode of treatment with low complications and comparable functional outcome with predominantly good/excellent AOFAS scores. Non-operative management does not require inpatient admission and has good results even when applied in low resource settings. Complications are significantly less and do not affect outcome scores adversely. Initial splint application and early range of motion exercises of ankle and subtalar joints helps good healing and better functional outcomes. Delay in partial and full weight bearing allows fracture to heal better and gives good functional outcomes. Deranged Bohler's and Gissane's angles at 1 year have no statistically significant effect on functional outcome.

References

1. Mitchell MJ, McKinley JC, Robinson CM. The epidemiology of calcaneal fractures. *Foot (Edinb Scotl)*. 2009; 19:197-200.
2. Razik A, Harris M, Trompeter A. Calcaneal fractures: Where are we now? *Strateg Trauma Limb Reconstr*. 2018; 13:1-11.
3. Schepers T, Ginai AZ, Mulder PGH, Patka P. Radiographic evaluation of calcaneal fractures: To measure or not to measure. *Skeletal Radiol*. 2007; 36:847-52.
4. Sanders R, Fortin P, DiPasquale T, Walling A. Operative treatment in 120 displaced intraarticular calcaneal fractures. Results using a prognostic computed tomography scan classification. *Clin Orthop*. 1993; (290):87-95.
5. Bruce J, Sutherland A. Surgical versus conservative interventions for displaced intra-articular calcaneal fractures. *Cochrane Database Syst Rev*. 2013; (1):CD008628.
6. Crosby LA, Kamins P. The history of the calcaneal fracture. *Orthop Rev*. 1991; 20:501-9.
7. Luo X, Li Q, He S, He S. Operative versus Non-operative Treatment for Displaced Intra-Articular Calcaneal Fractures: A Meta-Analysis of Randomized Controlled Trials. *J Foot Ankle Surg*. 2016; 55:821-8.
8. Dhillon MS, Prabhakar S. Treatment of displaced intra-articular calcaneus fractures: a current concepts review. *SICOT-J*. 2017; 3:59.
9. Liu Y, Li Z, Zhang Y. Protective Effect of Surgery Against Early Subtalar Arthrodesis in Displaced Intra-articular Calcaneal Fractures: A Meta-Analysis. *Medicine (Baltimore)*. 2015; 94:e1980-1984.
10. Randle JA, Kreder HJ, Stephen D, Williams J, Jaglal S, Hu R. Should calcaneal fractures be treated surgically? A meta-analysis. *Clin Orthop*. 2000; (377):217-27.
11. Buckley R, Tough S, McCormack R, Pate G, Leighton R, Petrie D *et al*. Operative compared with nonoperative treatment of displaced intra-articular calcaneal fractures: a prospective, randomized, controlled multicenter trial. *J Bone Joint Surg (Am)*. 2002; 84:1733-44.
12. Griffin D, Parsons N, Shaw E, Kulikov Y, Hutchinson C, Thorogood M *et al*. Operative versus non-operative treatment for closed, displaced, intra-articular fractures of the calcaneus: randomised controlled trial. *BMJ*. 2014; 349: 4483.
13. Kennedy JG, Jan WM, McGuinness AJ, Barry K, Curtin J, Cashman WF *et al*. An outcomes assessment of intra-articular calcaneal fractures, using patient and physician's assessment profiles. *Injury*. 2003; 34:932-6.
14. Ibrahim T, Rowsell M, Rennie W, Brown AR, Taylor GJS, Gregg PJ. Displaced intra-articular calcaneal fractures: 15-year follow-up of a randomised controlled trial of conservative versus operative treatment. *Injury*. 2007; 38:848-55.
15. Zwipp H, Rammelt S, Amlang M, Pompach M, Dürr C. Operative treatment of displaced intra-articular calcaneal fractures. *Oper Orthopadie Traumatol*. 2013; 25:554-68.
16. Agren PH, Wretenberg P, Sayed-Noor AS. Operative versus nonoperative treatment of displaced intra-articular calcaneal fractures: a prospective, randomized, controlled multicenter trial. *J Bone Joint Surg (Am)*. 2013; 95:1351-7.
17. Van Hove S, de Vos J, Verbruggen JPAM, Willems P, Meijer K, Poeze M. Gait Analysis and Functional Outcome after Calcaneal Fracture. *J Bone Joint Surg (Am)*. 2015; 97:1879-88.
18. Li B, Wu G, Yang Y. Conservative versus surgical treatment for displaced fracture of the medial process of the calcaneal tuberosity. *J Orthop Surg (Hong Kong)*. 2016; 24:163-6.
19. Pawar E, Gavhale S, Sharma A, Ramteke U, Marfatia A. Correlation of Bohler's angle and role of bone graft in the functional outcome of displaced intra-articular calcaneal fractures. *Int. J Orthop Sci*. 2018; 4:753-8.
20. Prabhakar S, Dhillon MS, Khurana A, John R. The Open-Envelope Approach: A Limited Open Approach for Calcaneal Fracture Fixation. *Indian J Orthop*. 2018; 52:231-8.