

E-ISSN: 2395-1958
P-ISSN: 2706-6630
IJOS 2019; 5(4): 914-917
© 2019 IJOS
www.orthopaper.com
Received: 14-08-2019
Accepted: 18-09-2019

Dr. Parimal Patel
Assistant Professor, Department
of Orthopedics, Veer Nirmal
South Gujarat University
Government Medical College,
Surat, Gujarat, India

Dr. Krunal Chaudhari
Assistant Professor, Department
of Orthopedics, Veer Nirmal
South Gujarat University
Government Medical College,
Surat, Gujarat, India

Corresponding Author:
Dr. Krunal Chaudhari
Assistant Professor, Department
of Orthopedics, Veer Nirmal
South Gujarat University
Government Medical College,
Surat, Gujarat, India

A study of greenstick fractures in forearm bones in children

Dr. Parimal Patel and Dr. Krunal Chaudhari

DOI: <https://doi.org/10.22271/ortho.2019.v5.i4p.1797>

Abstract

Background and objectives: Definition: A fracture in which one side of a bone is broken and the other is bent John Insall, a British-American orthopedist and Michal Slupecki, a Polish-American orthopedist, described the fracture like that of a breakage of green wood, which simply breaks outer side when bent. Ligaments and Tendons are stronger than bone when young. Bone is more likely to be injured than soft tissue. Periosteal is biologically active in children and often stays intact with injury. This stabilizes fractures and promotes healing. Force to side of bone may cause break in only one cortex—Greenstick fracture. The outer cortex only bends. In very young children none of the cortex may break—Plastic deformation.

Methods: Out of 35 cases treated in our instate 23 were male and 12 female child. Patients pre and post reduction serial follow up x-rays were studied. Follow up period ranges from 3 months to 3 year. In greenstick fracture reduction done according to angulation of fracture. When the apex of the fracture is towards dorsum of the forearm (apex dorsal- pronation injury), the forearm supinated to achieve reduction. When the apex of the fracture is towards volar aspect of the forearm (apex volar- supination injury), the forearm pronated to achieve reduction.

Results: Out of twenty patients treated, overall good to excellent results were obtained in 96% patients. The results was fair in one patient each. There were no intraoperative complications.

Interpretation and conclusion: Maximum fractures were in age group of 5-10 year with predominance in males. Most of the fractures were on subordinate side. Average union time in greenstick fracture was 6 week. In this series the highest degree of angulation (at final follow up) which got corrected was in radius 18° and in ulna 13°. Remodeling and returning of final range of motion is excellent.

Keywords: Greenstick, angulation, children, supination, pronation

Introduction

Greenstick fracture is defined as a type of fracture where the bone bends and partially breaks. Greenstick fracture usually occurs during infancy and childhood when bones are soft. This fracture was described by John Insall, a British- American Orthopedist and Michal Slupecki, a Polish-American Orthopedist. They described the fracture like that of a breakage of a green wood, which simply breaks outer side when bent. Angulated Greenstick fracture of the shaft radius and ulna at different levels indicates a significant rotational component of injury. Evans, Rang and others have stated that the apex-volar angulation pattern usually associated with supination type injury mechanism, while most apex dorsal angulation greenstick fracture involve a pronation type injury mechanism. The objective of treatment in greenstick fracture is to correct angular deformity by simply reversing the forearm rotational forces.

Material and Method

We have treated 35 cases in our institute. There were 23 male child and 12 female child. Patients Pre and Post reduction serial follow up x-ray were studied. Follow up period ranges from 3 month to 3 year

Table 1: Level of Bone Fractured

Level	No. of Patients
Upper 1/3 rd	07
Midshaft	08
Lower 1/3 rd	13
Lower1/4 th	07
Total	35

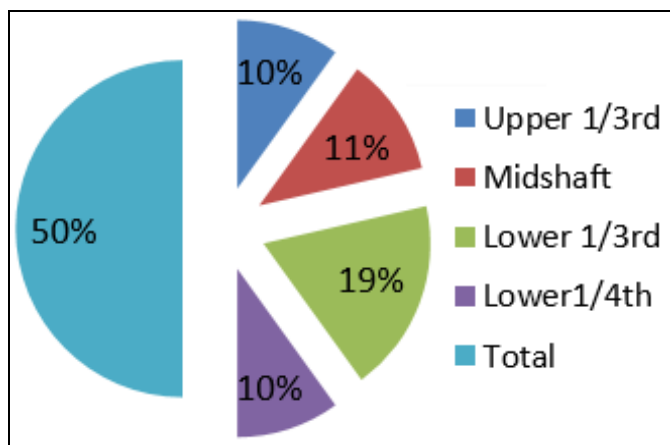


Fig 1: No. of Patients

Table 2: Apex of Fracture Angulation

Level	No. of Patients
Volar	30
Dorsal	5
Total	35

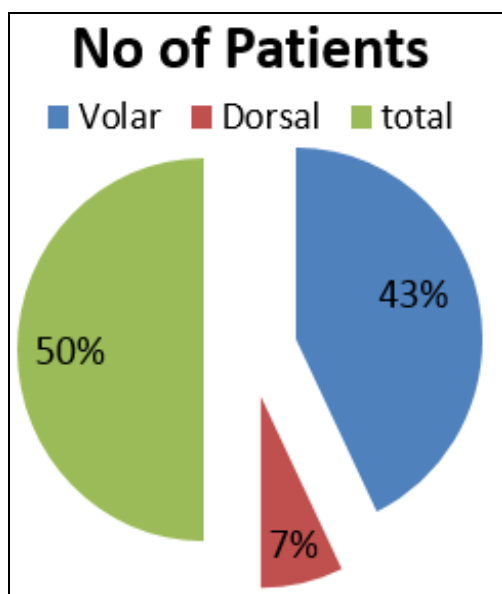


Fig 2: Show the total volar and Dorsal

Table 3: Bone Involved

Bone	No. of Patients
Isolated Radius	14
Isolated Ulna	02
Both	19

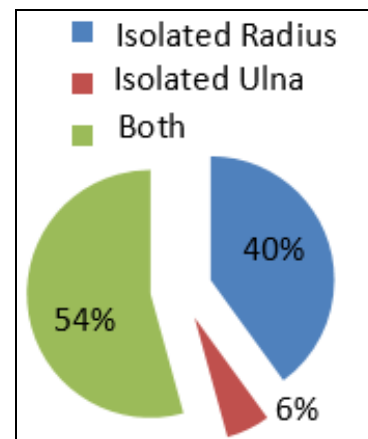


Fig 3: Both are different of isolate radius and ulna

Plaster Technique

In Greenstick fracture reduction done according to angulation of fracture. When the apex of fracture is towards dorsum of forearm (Apex Dorsal-Pronation Injury), the forearm is supinated to achieve reduction. When the apex of fracture towards the volar aspect of forearm (Apex Volar-Supination Injury), the forearm is pronated to achieve reduction. So depend of injury plaster given in Pronation or in supination. Plaster given in oval shaped and with ulnar border straight. Cast Index is maintained. Plaster post reduction check x-ray was taken and patient was kept under observation with elevation of limb for 2 days, if there was oedema and stretch pain at extension of finger, plaster slit from ulnar border and simple bandage was applied over it. If there was no oedema or circulatory disturbance patient was discharge after 2 days. And patient was advice to come after 1 week to check plaster condition.

Results

Table 4: Duration of final follow up

Final Follow Up(month)	No.Of Patients
2-8	07
8-14	09
14-20	05
20-26	04
>26	10
Total	35

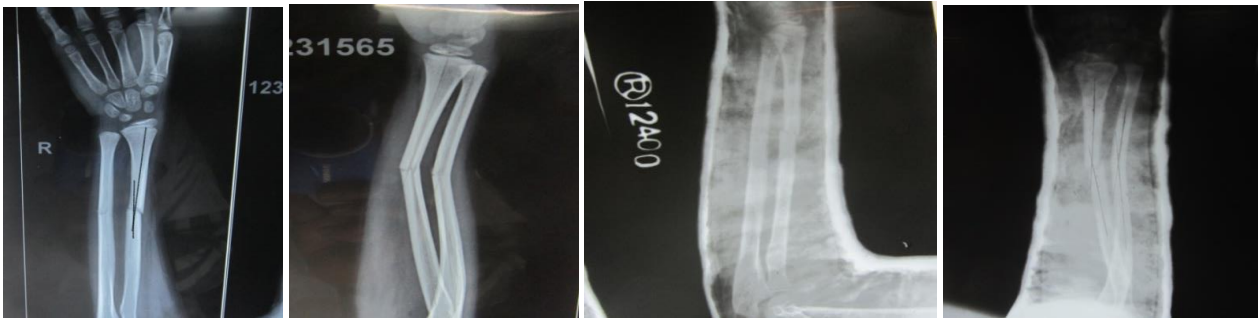
Table 5: Range of motion at final follow up:

Forearm	No Of Patients				Total
	<30	30-50	50-70	>70	
Pronation	-	-	6	29	35
Supination	1	-	-	34	35

Table 6: Final result based on objective assesment criteria:

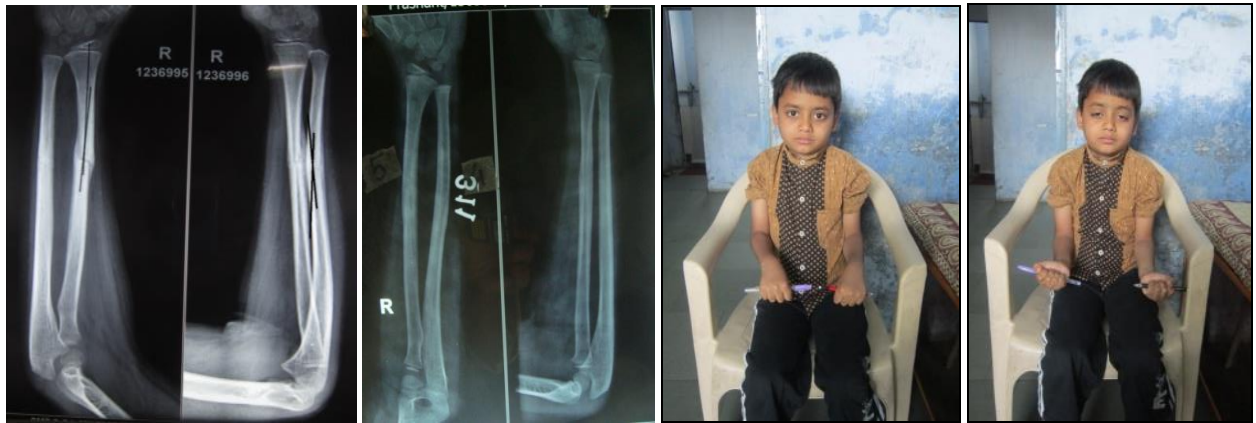Results	Patients
Excellent	26
Good	08
Fair	01
Poor	--

Case 1: 7 Year Male



Pre Reduction

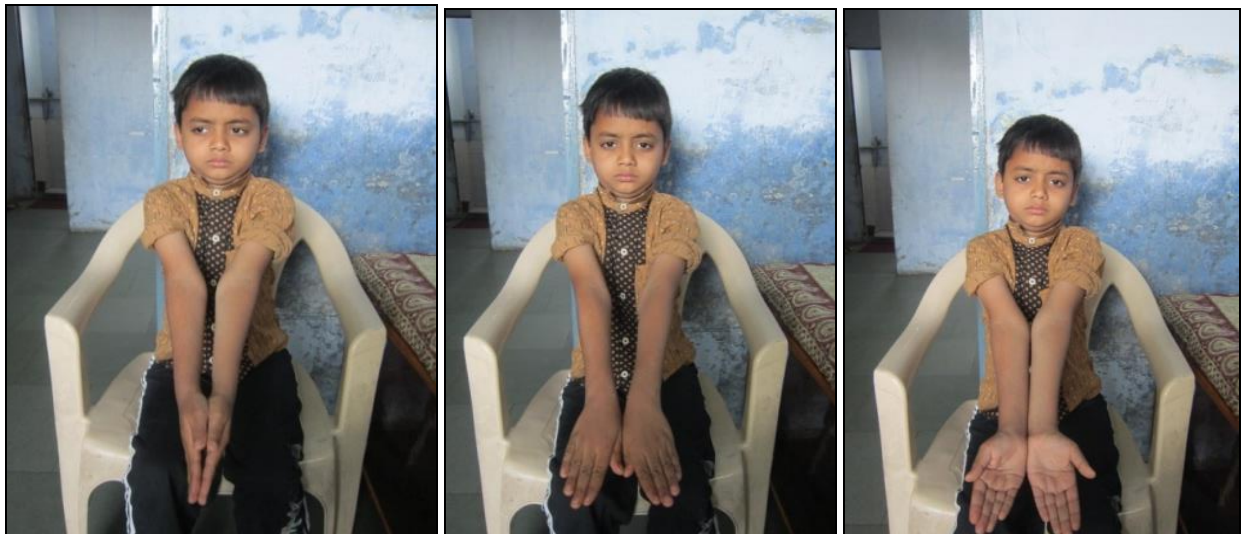Post Reduction



6 week follow up

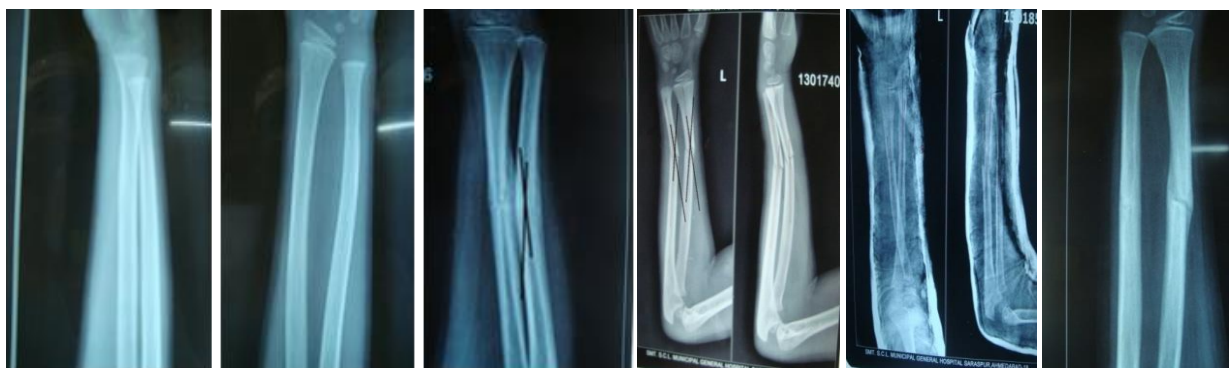5 month follow up

Functional Outcome



Functional Outcome-Excellent

Case 2: 6 Year Male



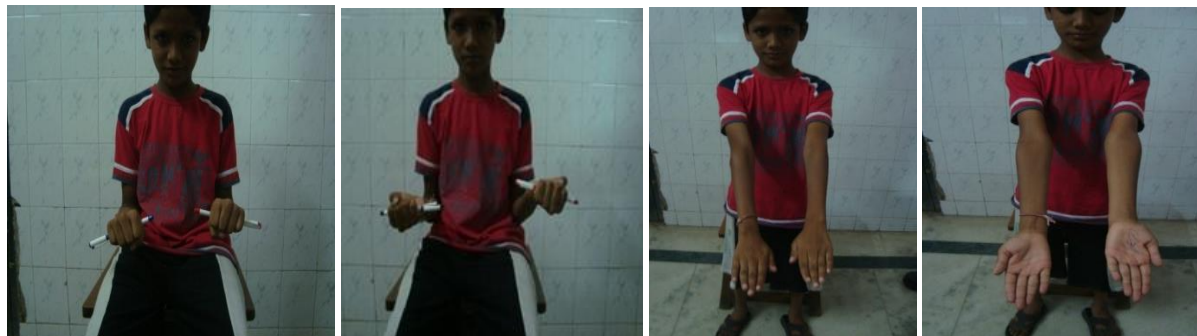Pre Reduction

Post Reduction,

6 week follow up

6 week follow up

2 year follow up



Function Outcome-Excellent

Discussion

In our study we have taken 35 cases of Greenstick fracture of forearm bones, in which there were 23 male & 12 female with age between 3-13 year, High incidence of Greenstick fracture of forearm were found in age group 5-10 year with mean age 7 year. Female are less involve than male.

In present series both bone involved more than isolated bone. Volar angulation is more common than dorsal. In present series lower 1/4th level is more common. Pronation is more common than supination. 17% patient has 10° loss of pronation in our study while one patient has restriction of supination (short term follow up of 2 month). Average period of immobilization is 6 weeks. In present series the highest degree of correction in radius is 18° and in ulna is 13°. In our study 74% has excellent result, 22% has good result & 1% has fair result. None of has poor result.

Conclusion

35 cases of Greenstick fracture for arm bones are studied. Maximum fracture were in age group of 5-10 year with predominance in males. Most of the fractures were on subordinate side. Average union time in Greenstick fracture was 6 week. In this series the highest degree of angulation (at final follow up) which got corrected was in radius 18° and in ulna 13°. There is rare incidence of slitting plaster. Remodeling and returning of final range of motion is excellent.

References

1. Bochang C, Katz K, Weigl D, Jie Y, Zhigang W, Bar-On E *et al.* Are frequent radiographs necessary in the management of closed forearm fractures in children? *J Child Orthop.* 2008; 2:217-220. Doi: 10.1007/s11832-008-0101-5. [PMC free article] [PubMed] [Cross Ref] [Google Scholar]
2. Boyer BA, Overton B, Schrader W, Riley P, Fleissner P. Position of immobilization for pediatric forearm fractures. *J Pediatric Orthop.* 2002; 22:185-187. [PubMed] [Google Scholar]
3. Davidson JS, Brown DJ, Barnes SN, Bruce CE. Simple treatment for torus fractures of the distal radius. *J Bone Joint Surge Br.* 2001; 83:1173-1175. Doi: 10.1302/0301-620X.83B8.11451. [PubMed] [Crossruff] [Google Scholar]
4. Farbman KS, Vinci RJ, Cranley WR, Creevy WR, Bauchner H. The role of serial radiographs in the management of pediatric torus fractures. *Arch Pediatric Adolesc Med.* 1999; 153:923-925. Doi: 10.1001/archpedi.153.9.923. [PubMed] [Cross Ref] [Google Scholar]
5. Noonan KJ, Price CT. Forearm and distal radius fractures in children. *J Am Acad Orthop Surg.* 1998; 6(3):146-

56. [PubMed]

6. Schmuck T, Altermatt S, Büchler P, Klima-Lange Ds, Krieg A, Lutz N *et al.* Greenstick fractures of the middle third of the forearm. A prospective multi-center study. *Eur J Pediatric Surg.* 2010; 20(5):316-20. [PubMed]
7. Casey PJ, Moed BR. Greenstick fractures of the radius in adults: a report of two cases. *J Orthop Trauma.* 1996; 10(3):209-12. [PubMed]