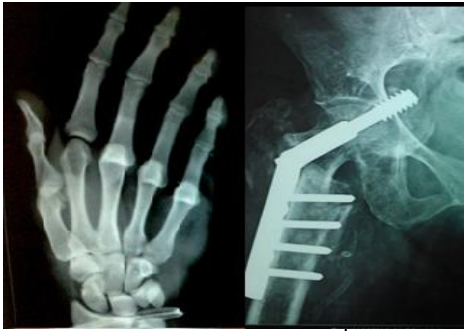

International Journal of Orthopaedics Sciences

E-ISSN: 2395-1958
P-ISSN: 2706-6630
IJOS 2019; 5(4): 882-885
© 2019 IJOS
www.orthopaper.com
Received: 24-08-2019
Accepted: 28-09-2019

Dr. Amarjit Kaur
Professor, Govt. Medical College
& Hospital, Patiala, Punjab,
India

Dr. Girish Sahni
Associate Professor, Govt.
Medical College & Hospital,
Patiala, Punjab, India

Dr. Munish Kumar Garg
Junior Resident, Govt. Medical
College & Hospital, Patiala,
Punjab, India

Dr. Sanjeev Kumar
Senior Resident, Govt. Medical
College & Hospital, Patiala,
Punjab, India

Dr. Ayush Kumar Jain
Senior Resident, Govt. Medical
College & Hospital, Patiala,
Punjab, India

Comparison between radiography and MRI features in evaluation of osteoarthritis of knee joint

Dr. Amarjit Kaur, Dr. Girish Sahni, Dr. Munish Kumar Garg, Dr. Sanjeev Kumar and Dr. Ayush Kumar Jain

DOI: <https://doi.org/10.22271/ortho.2019.v5.i4o.1790>

Abstract

Background: Osteoarthritis (OA) is a widely prevalent disease worldwide and is a major public health problem that primarily affects the elderly. The present study was undertaken to define the radiographic findings of osteoarthritis (OA) of knee joint using Kellgren-Lawrence (K-L) scores and to define cartilage abnormalities on magnetic resonance imaging (MRI).

Materials & Methods: Present study was conducted on 50 patients presenting with knee pain and clinical suspicion of osteoarthritis. Antero-posterior radiographs of the knee were obtained in a weight-bearing extended position by using a standard radiographic technique. All radiographs were assigned scores by using the Kellgren-Lawrence scoring system. Cartilages alterations on MRI were assigned grades as follows: grade 0, normal; grade I, internal signal intensity alteration only; grade IIA, defect of cartilage of less than 50%; grade IIB, defect of cartilage of 50%–99%; grade IIIA, 100% defect of cartilage with no bony changes; or grade IIIB, 100% defect of cartilage with subjacent bony changes. Radiographic and MR imaging findings were compiled and analysed using appropriate statistical tests.

Results: Among 26 patients of grade 0 K-L score, 6, 4, 6, 4, 4 and 2 patients had grade 0, grade 1, grade 2A, grade 2B, grade 3A and grade 3B Cartilage abnormality (On MRI) respectively. Among 8 patients of grade 1 K-L score, 2, 2, 2 and 2 patients had grade 0, grade 2A, grade 2B and grade 3A Cartilage abnormality (On MRI) respectively. Among 14 patients of grade 2 K-L score, 1, 4, 4 and 5 patients had grade 2A, 2B, 3A and grade 3B Cartilage abnormality (On MRI) respectively. Among 2 patients of grade 3 K-L score, both of these had grade 3B Cartilage abnormality (On MRI).

Conclusion: Conventional radiography being easily available is a common investigation tool to diagnose osteoarthritis knee. But MRI reveals structural changes of articular cartilage, joint effusion and meniscal extrusion or tear etc. thereby helping in early diagnosis. This can lead to timely management and hence better functional outcome in OA knee cases.

Keywords: Magnetic resonance imaging, osteoarthritis, radiographic findings

Introduction

Osteoarthritis (OA) of knee joint is common worldwide. It primarily affects the elderly. The increasing importance of imaging in osteoarthritis for diagnosis, prognosis and follow-up is well recognized by both clinicians and osteoarthritis researchers. Conventional radiography is still the gold standard imaging technique for the evaluation of known or suspected osteoarthritis knee in clinical practice and research^[1-3]. Though it is still the most commonly used imaging modality for establishing an imaging-based diagnosis of OA but it has limitations that have become apparent in the course of large magnetic resonance imaging (MRI)-based knee osteoarthritis studies^[4].

Radiography enables detection of OA-associated bony features such as osteophytes, subchondral sclerosis and cysts. Radiography reveals joint space width (JSW), but direct visualization of articular structures is not possible. Decrease in joint space width or joint space narrowing (JSN) is the most commonly used criterion for the assessment of progression of OA of knee joint and the total loss of JSW (“bone-on-bone” appearance) is one of the indicators for joint replacement^[5, 6].

Cartilage loss is not the only contributor to JSN but other changes in the meniscus such as meniscal extrusion and meniscal substance loss are also causative factors. The severity of radiographic OA can be assessed with many scoring systems. The Kellgren and Lawrence

Corresponding Author:
Dr. Girish Sahni
Associate Professor, Govt.
Medical College & Hospital,
Patiala, Punjab, India

(KL) grading system is a widely accepted scheme for defining radiographic OA based on the presence of definite osteophytes (grade 2) [6].

Focal cartilage defects and bone marrow lesions are best assessed using fluid-sensitive fast spin echo sequences (e.g. T2-weighted, proton density-weighted or intermediate-weighted) with fat suppression [7-9].

Present study was undertaken to define the radiographic findings of osteoarthritis (OA) of knee joint using Kellgren-Lawrence scores and to define cartilage abnormalities on magnetic resonance (MR) imaging.

Material and Methods

Present study was conducted on 50 patients presenting with

knee pain and clinical suspicion of osteoarthritis who were referred to the department of Radiodiagnosis, Rajindra hospital, Patiala. Detailed radiographic and MR imaging was done in all subjects. Antero-posterior radiographs of the knee were obtained in a weight-bearing extended position by using a standard radiographic technique. All radiographs were assigned scores by using the Kellgren-Lawrence scoring system. Kellgren-Lawrence score was based on osteophytes formation, joint space narrowing, sclerosis, and joint deformity characteristics according to the five-level scale defined as follows: grade 0, normal; grade 1, doubtful osteoarthritis; grade 2, minimal osteoarthritis; grade 3, moderate osteoarthritis; or grade 4, severe osteoarthritis.

Table 1: Type of classification and description

Grade	Classification	Description
0	Normal	No radiographic features of osteoarthritis
1	Doubtful Osteoarthritis	Possible joint space narrowing (normal joint space is at least 2mm) and osteophyte formation
2	Minimal Osteoarthritis	Definite osteophyte formation with possible joint space narrowing
3	Moderate Osteoarthritis	Multiple osteophytes, definite joint space narrowing, sclerosis and possible bony deformity
4	Severe Osteoarthritis	Large osteophytes, marked joint space narrowing, severe sclerosis and definite bony deformity

MR imaging of the knee was performed on Siemens magneto aera 1.5T MRI machine. Multiplanar MR imaging was performed in axial, coronal and sagittal planes as per the following protocol: PD fat suppressed Axial, sagittal and coronal view, T1WI sagittal view, T2WI sagittal view, T2WI space sagittal view.

Cartilages alterations were assigned grades as follows: grade 0, normal; grade I, internal signal intensity alteration only;

grade IIA, defect of cartilage of less than 50%; grade IIB, defect of cartilage of 50%-99%; grade IIIA, 100% defect of cartilage with no bone abnormality; or grade IIIB, 100% defect of cartilage with subjacent bone abnormality. Radiographic and MR imaging findings were compiled and analysed using appropriate statistical tests.

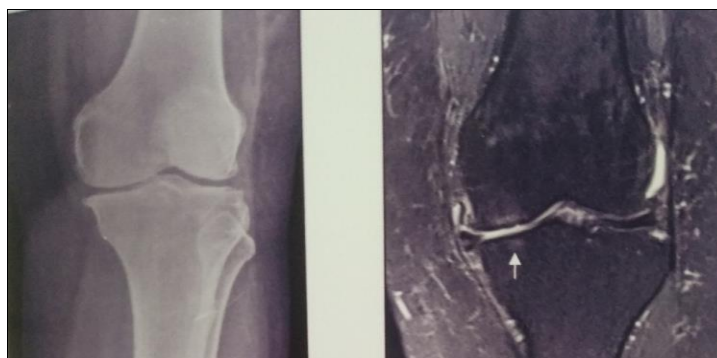Results

Table 2: Age-wise distribution of patients

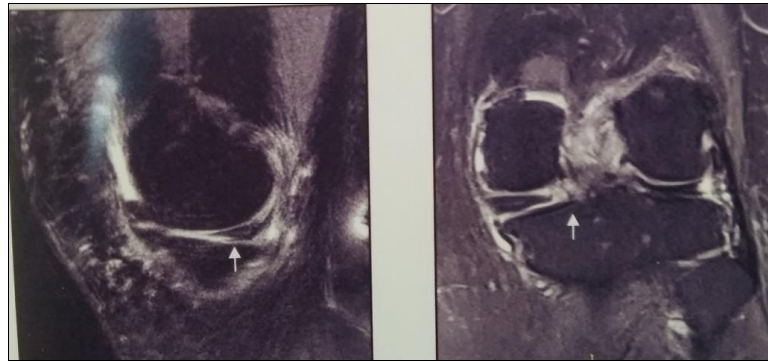
Age group (in years)	No. of patients	% age
< 40	5	10
40 to 50	6	12
51 to 60	15	30
61 to 70	12	24
> 70	12	24
Total	50	100
Mean ± SD	57.26±8.89	

A total of 50 patients with OA knee were included in study. Mean age of the patients was 57.26 years. 26 patients (52%) had grade 0 K-L score, 8 patients (16%) had Grade 1 K-L score, 14 patients (28%) had Grade 2 K-L score, 2 patients (4%) had Grade 3 K-L score, while none of the patient had grade 4 K-L score. Among 26 patients of grade 0 K-L score, 6, 4, 6, 4, 4 and 2 patients had grade 0, grade 1, grade 2A, grade 2B, grade 3A and grade 3B Cartilage abnormality (On

MRI) respectively. Among 8 patients of grade 1 K-L score, 2, 2, 2 and 2 patients had grade 0, grade 2A, grade 2B and grade 3A Cartilage abnormality (On MRI) respectively. Among 14 patients of grade 2 K-L score, 1, 4, 4 and 5 patients had grade 2A, 2B, 3A and grade 3B cartilage abnormality (On MRI) respectively. Both grade 3 K-L score patients had grade 3B Cartilage abnormality (On MRI).



1. X ray showing KL grade 2 changes 2. MRI coronal PD fat sat image showing grade 3b cartilage loss



3. Sagittal and coronal PD fat sat images showing grade three horizontal tear of posterior horn of medial meniscus

Fig 1: Images showing x-ray picture of K-L grade 2 OA knee and comparative MRI images of the same knee

Table 3: Distribution of patients according to Kellgren-Lawrence score (on Radiography)

Kellgren-Lawrence Score (on Radiography)	Parameter	No. of Patients	Percentage
Grade 0	Normal	26	52
Grade 1	Doubtful Osteoarthritis	8	16
Grade 2	Minimal Osteoarthritis	14	28
Grade 3	Moderate Osteoarthritis	2	4
Grade 4	Severe Osteoarthritis	0	0
Total		50	100

Table 4: Comparison of distribution of patients according to Kellgren-Lawrence score (on Radiography) and according to cartilage abnormality (on MRI)

Cartilage abnormality (On MRI)	Kellgren-Lawrence score (On Radiographic)				Total	Fisher's Exact Test P-value
	Grade 0	Grade 1	Grade 2	Grade 3		
Grade 0	6	2	0	0	8	0.032 (Significant)
Grade I	4	0	0	0	4	
Grade II A	6	2	1	0	9	
Grade II B	4	2	4	0	10	
Grade III A	4	2	4	0	10	
Grade III B	2	0	5	2	9	
Total	26	8	14	2	50	

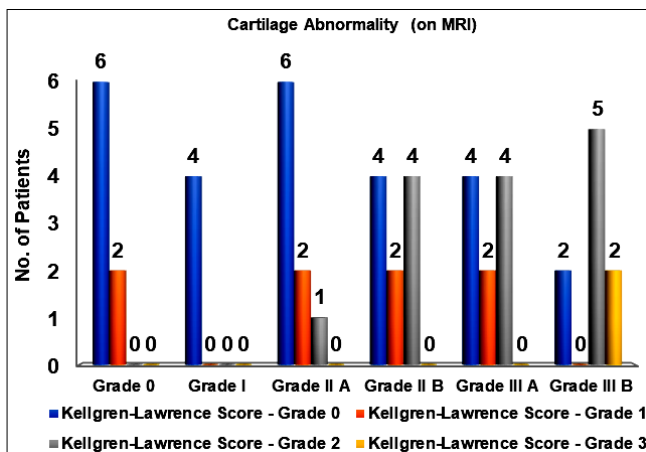


Fig 2: Cartilage abnormality (on MRI)

Discussion

Total 50 cases with history of knee pain and clinical suspicion of Osteoarthritis of knee joint underwent X-ray and MRI of the Knee Joint. Antero-posterior radiographs of the knee were done in a weight-bearing extended position by using a standard radiographic technique. All the scans were done using Siemens 1.5 Tesla High Gradient MRI scanner and using a scan protocol which included PD fat suppressed Axial, sagittal and coronal view, T1WI sagittal view, T2WI sagittal view, T2WI space sagittal view.

78 percent of patients were of more than 50 years of age.

Mean age of the patients was 57.26 years. There were 56 percent female patients were while 44 percent were males. Singh *et al.* (2017) [9] reported that 56.25 percent of OA patients in their study were of more than 50 years of age.

As reported in the past literature, about 13% of women and 10% of men aged 60 years and older have symptomatic knee OA. The proportions of people affected with symptomatic knee OA is likely to increase due to the aging of the population and the rate of obesity or overweight in the general population. A female predilection for occurrence of OA has also been reported in the past literature by Pal *et al.* (2016) [8] and Singh *et al.* (2017) [9].

The definite increase in OA in women around the time of menopause has lead investigators hypothesize that hormonal factors may play a role in the development of OA [10, 11].

In the present study, on MRI, 8 (16%) patients had grade 0 (normal) cartilage abnormality, 4 patients (8%) had Grade 1 cartilage defect (Intense signal intensity alteration), 9 patients (18%) had Grade IIA abnormality (defect of cartilage less than 50%), 10 patients (20%) had Grade IIB abnormality (defect of cartilage of 50% to 99%), 10 patients (20%) had Grade III A abnormality (100% defect of cartilage with no bone ulceration) while 9 patients (18%) had Grade III B abnormality (100% defect of cartilage with subjacent bone ulceration). while on comparing this data with K-L score we found that among 26 patients of grade 0 K-L score, 6, 4, 6, 4, 4 and 2 patients had grade 0, grade 1, grade 2A, grade 2B, grade 3A and grade 3B cartilage abnormality (On MRI)

respectively. Among 8 patients of grade 1 K-L score, 2, 2, 2 and 2 patients had grade 0, grade 2A, grade 2B and grade 3A cartilage abnormality (On MRI) respectively. Among 14 patients of grade 2 K-L score, 1, 4, 4 and 5 patients had grade 2A, 2B, 3A and grade 3B cartilage abnormality (On MRI) respectively. Among 2 patients of grade 3 K-L score, both of these had grade 3B cartilage abnormality (On MRI).

Our results were in concordance with the results obtained by Hayes *et al.* (2005) ^[7], who also reported similar findings in their study. They reported that 17.2%, 8.2%, 19.5%, 19.8%, 20.8% and 14.7% of the patients had normal, Grade I, Grade IIA, Grade IIB, Grade IIIA and Grade IIIB defect of cartilage. MR imaging of the articular cartilage is particularly important, as articular cartilage degeneration is often cited as the structural hallmark of OA progression. A 2005 study by Amin *et al.* ^[6] revealed that a significant number of symptomatic patients show cartilage loss on MRI even when joint space narrowing or disease progression is not visualized on radiography. In their study, radiographic progression was 91% specific but only 23% sensitive for cartilage loss.

MR technology has evolved to provide quantitative information about the physiological content of articular cartilage. These developments have been useful in identifying early damage and breakdown. In OA, proteoglycan and collagen content are reduced. This disrupts the collagen network and results in increased water content and matrix degradation. Newer methods of MRI exploit these macromolecule changes to provide a quantitative understanding of the breakdown process. In general, fat suppression is useful in cartilage imaging because it results in a higher dynamic range of signal intensities in the articular cartilage and reduces or eliminates chemical shift artifacts ^[12, 13].

MRI reveals cross-sectional images of the anatomy whereas radiography has projectional limitations. MRI directly depicts all the components of the joint and their pathologies, that includes the articular cartilage, menisci, intraarticular ligaments, synovium, effusion, bone attrition, bone marrow lesions (BMLs), subchondral cysts, and intra- and periarticular cystic lesions. Knee joint can be evaluated as a whole organ, providing a much more detailed picture of the changes associated with OA than is possible with other techniques ^[14]. MRI can detect the pathology of pre radiographic OA and possible complications of the disease at as much earlier stage than radiography ^[15].

Conclusion

OA knee is a whole joint disease. Conventional radiography being easily available is a common investigation tool to diagnose osteoarthritis knee on the basis of joint space narrowing and presence of osteophytes. MRI reveals three dimensional images of all soft tissues of knee joint along with structural changes of articular cartilage, joint effusion and meniscal extrusion or tear etc. thereby helping in early diagnosis. This can lead to timely management and hence better functional outcome in OA knee cases.

Source of funding: Nil

Conflict of interest: None

Consent of patients: Taken

Ethical committee approval: Taken

References

- Hayashi D, Roemer FW, Guermazi A. Imaging for osteoarthritis. *Annals of Physical and Rehabilitation Medicine*. 2016; 59(3):161-9.
- Menashe L, Hirko K, Losina E, Kloppenburg M, Zhang W, Li L *et al.* The diagnostic performance of MRI in osteoarthritis: a systematic review and meta-analysis. *Osteoarthritis Cartilage*. 2012; 20(1):13-21.
- Guermazi A, Hayashi D, Roemer F, Felson DT, Wang K, Lynch J *et al.* Severe radiographic knee osteoarthritis - does Kellgren and Lawrence grade 4 represent end stage disease? *Osteoarthritis Cartilage*. 2015; 23:1499-505.
- Guermazi A, Niu J, Hayashi D, Roemer FW, Englund M, Neogi T *et al.* Prevalence of abnormalities in knees detected by MRI in adults without knee osteoarthritis: population based observational study (Framingham Osteoarthritis Study). *BMJ*. 2012; 345:e5339.
- Guermazi A, Roemer FW, Haugen IK, Crema MD, Hayashi D. MRI-based semiquantitative scoring of joint pathology in osteoarthritis. *Nat Rev Rheumatol*. 2013; 9:236-51.
- Amin S, LaValley MP, Guermazi A, Grigoryan M, Hunter DJ, Clancy M *et al.* The relationship between cartilage loss on magnetic resonance imaging and radiographic progression in men and women with knee osteoarthritis. *Arthritis Rheum*. 2005; 52(10):3152-9.
- Hayes CW, Jamadar DA, Welch GW, Jannausch ML, Lachance LL, Capul DC *et al.* Osteoarthritis of the knee: comparison of MR imaging findings with radiographic severity measurements and pain in middle-aged women. *Radiology*. 2005; 237(3):998-1007.
- Pal CP, Singh P, Chaturvedi S, Pruthi KK, Vij A. Epidemiology of knee osteoarthritis in India and related factors. *Indian J Orthop*. 2016; 50(5):518-22.
- Singh AK, Sharma V, Senger KPS, Singh A, Prateek. Degenerative disease of knee joint: a clinico-radiological correlation. *Int Surg J*. 2017; 4:866-73.
- Zhang Y, Jordan JM. Epidemiology of osteoarthritis. *Clin Geriatr Med*. 2010; 26(3):355-69.
- Sowers M. Epidemiology of risk factors for osteoarthritis: systemic factors. *Current Opinion in Rheumatology*. 2001; 13(5):447-51.
- Dijkgraaf LC, de Bont LG, Boering G, Liem RS. The structure, biochemistry, and metabolism of osteoarthritic cartilage: a review of the literature. *J Oral Maxillofac Surg*. 1995; 53:1182-92.
- Roemer FW, Crema MD, Trattnig S, Guermazi A. Advances in Imaging of Osteoarthritis and Cartilage. *Radiology*. 2011; 260(2):332-54.
- Peterfy CG, Guermazi A, Zaim S *et al.* Whole-Organ Magnetic Resonance Imaging Score (WORMS) of the knee in osteoarthritis. *Osteoarthritis Cartilage*. 2004; 12:177-190.
- Javaid MK, Lynch JA, Tolstykh I *et al.* Pre-radiographic MRI findings are associated with onset of knee symptoms: the MOST study. *Osteoarthritis Cartilage*. 2010; 18:323-328.