



International Journal of Orthopaedics Sciences

E-ISSN: 2395-1958
P-ISSN: 2706-6630
IJOS 2019; 5(4): 757-761
© 2019 IJOS
www.orthopaper.com
Received: 16-08-2019
Accepted: 20-09-2019

Dr. Ashutosh Vikram
Assistant Professor, Department
of Orthopaedic, Narayan Medical
College and Hospital, Sasaram,
Bihar, India

Reena
Associate Professor, Department
of Anaesthesiology, Heritage
Institute of Medical Sciences,
Bhadwar, Varanasi, Uttar
Pradesh, India

Functional outcome of displaced supracondylar fracture humerus in children treated by closed reduction and percutaneous pinning with Kirchner wires: An observational study

Dr. Ashutosh Vikram and Reena

DOI: <https://doi.org/10.22271/ortho.2019.v5.i4m.1765>

Abstract

Background: Displaced supracondylar fracture of humerus is a common orthopaedics problem in children. The most common complications associated with these fractures are mal-union leading to cubitus varus, stiffness of elbow, myositis ossificans, compartment syndrome and neurovascular deficit. Different methods have been described for its management of which closed reduction and percutaneous pinning with K-wires has been preferred treatment with satisfactory results.

Material and Methods: Between March 2017 to May 2018, 36 patients with supracondylar fracture of humerus of Gartland type II & III in children were included in this study. These patients were treated by closed reduction of fracture and percutaneous fixation with K-wire under C-arm guidance. The functional outcome was assessed clinically by Flynn's criteria. The assimilated data was analyzed using various statistical methods like descriptive statistics (mean, standard deviation, standard error), chi-square test. Estimates of population proportions were obtained using estimator sample proportions and 95% confidence intervals under standard normal distribution approximation for large sample.

Results: In our study, the mean age of the patients was found to be 6.64 years with male preponderance (72.22%) as compared to females (27.78%). Statistical analysis (test statistic; Fisher Exact test for count data – two sided) on the observations of Flynn's grading score for different fixation methods *viz.* 2 Cross-wire (2C), 2 Lateral (2L) and 3K-wire depicted that proportions of satisfactory grading in all fixation methods (2C, 2L and 3K) are same (p-value 1.00) and hence results found no significant difference between fixation methods and Flynn's grading score. This study revealed that the mean hospital length of stay for 2C and 3K fixation methods was 2.11 ± 0.29 and 2.33 ± 0.35 (p=0.609) respectively. The satisfactory result for loss of carrying angle and loss of range of motion was 94.44% and 100% for 2C and 3K fixation methods respectively.

Conclusions: The results of our study demonstrated that closed reduction and percutaneous fixation using K-wire of displaced supracondylar fractures of humerus in children would be the simple, cheap, safe and effective method of treatment with relatively fewer complications and reduced hospital stay.

Keywords: Supracondylar fractures, elbow trauma, children, closed reduction, percutaneous k-wire

1. Introduction

Supracondylar fracture of humerus is the second most common fracture in children [1]. They occur primarily in the first decade of life, increasing steadily during the first 5 years and reaches the peak incidence between 5-8 years [2, 3]. Incidence is 2 times more in boys than in girls [2]. The fear of the injury still remains. Complications are common. Treatment is controversial and often technically difficult [4]. Incidence of vascular injury is 0.5%-0.8%; nerve injury incidence is 6-16%, cubitus varus is 30%, which doesn't remodel with growth [5, 6, 7, 8]. Drawbacks in the management occur frequently and continue to trouble the orthopaedic surgeon's caring for these patients, especially with respect to displaced supracondylar fractures.

There are no controversies about management of the non-displaced fractures which is immobilisation in plaster of paris slab. Whereas, many methods have been proposed for the treatment of displaced supracondylar fracture *viz.* CR + immobilisation, Traction by various

Corresponding Author:
Dr. Ashutosh Vikram
Assistant Professor, Department
of Orthopaedic, Narayan Medical
College and Hospital, Sasaram,
Bihar, India

methods, CR + Kirschner wires (K-wire) pinning with C-arm control and OR + IF with K-wire pinning for comminuted fracture. Closed reduction with plaster of paris slab immobilization has been traditionally recommended for displaced supracondylar fractures, but loss of reduction and necessity of repeated manipulation is likely to go for malunion producing varus or valgus deformity of elbow and elbow stiffness. Traction (skin or skeletal), which has also been used for many years, has been shown to be safe and reliable, but it has the drawback of requiring a long stay in the hospital [2, 5]. Open reduction and internal fixation have generally been reserved for specific indications mainly for an open fracture, a fracture requiring vascular exploration, or an irreducible fracture. [7, 9].

However, most of the recent studies have shown good functional results with closed reduction and percutaneous fixation using K-wires and is the most commonly accepted treatment of displaced supracondylar fractures of the humerus in children. With this viewpoint, the present was conducted with the objective to study the functional outcome following closed reduction and percutaneous pinning with K-wires in displaced type of supracondylar fractures of humerus and evaluation of advantages and complications related to procedure.

2. Material and Methods

2.1 Study population

This is a prospective study, conducted on 36 patients admitted to the OPD and emergency services and treated at Heritage Institute of Medical Sciences (HIMS), Varanasi, U.P. informed written consent was taken from patients about the participation in present study. Ethical clearance was sought and approved by institute ethical committee before the conduct of study. All those patients reporting with elbow injuries were evaluated. Any associated neurovascular injuries, fractures, compartment syndrome were noted. Radiograph of the elbow was taken in antero-posterior and lateral views. The diagnosis was confirmed by radiological examination. The fractures were classified according to Gartland's classification. All patients were taken up for surgery as soon as possible after necessary routine preoperative hematological investigation.

2.2 Gartland's classification

- Type-I Non-displaced
- Type-II Minimally displaced with intact posterior cortex
- Type-III Completely displaced with no cortical contact
 - a) Postero-medial
 - b) Postero-lateral

2.3 Inclusion criteria

Children with supracondylar fracture of humerus who fulfil the following inclusion criteria were included in the study.

- All closed displaced supracondylar fractures of the humerus (Gartland's Type –II & III) in pediatric population treated with closed reduction and percutaneous pinning with K-wires.

2.4 Exclusion criteria

- Age more than 12 years.
- Delayed presentation more than 7 days.
- Open supracondylar fractures of humerus.
- Supracondylar fractures of humerus with neurovascular complications.
- Associated ipsilateral limb injury.

- Pathological fracture.
- Re-fracture.
- Pre-existent congenital anomalies of the involved limb.

2.5 Surgical procedure

Anaesthesia: General anaesthesia

Patient Positioning: For closed reduction: Supine with ipsilateral shoulder at the edge of the table. Sandbags were placed beneath the arm; the forearm was left to hang freely with the elbow flexed.

Painting and Draping: The injured elbow, arm and forearm was scrubbed, painted and draped well leaving the elbow, lower third of arm and upper third of forearm exposed.

Technique of closed reduction and internal fixation: Traction along the longitudinal axis with elbow in extension and supination were given. At the same time counter traction was given by an assistant by holding proximal portion of arm. Medial or lateral displacements were corrected by valgus or varus forces respectively. After that, posterior displacement and angulation was corrected by flexing the elbow and applying posteriorly directed force from anterior aspect of proximal fragment and anteriorly directed force from posterior aspect of distal fragment. Reduction was confirmed under image intensifier in two views:

- 1). Antero-posterior view or Jone's view.
- 2). Lateral view.

After confirming satisfactory alignment, reduction was maintained by percutaneous K-wire fixation. Above elbow posterior POP splint in 90° elbow flexion of forearm was applied.

Introduction of K-wires: K-wires of about 1.2 mm to 2.0 mm were used. Either 2 criss-cross pins were used, one from medial epicondyle and one from lateral epicondyle or 3 K-wires (2 K- wire from lateral & 1 K- wire from medial) were used or at times 2 lateral K- wires were used. After achieving satisfactory reduction, K-wires were introduced with the help of a drill.

Medial pin entry was from tip of the medial epicondyle and lateral pin was introduced from the centre of the lateral condyle. Both pins were directed 40° to the humeral shaft in sagittal plane and 10° posteriorly. K-wire placement was checked in image intensifier in antero posterior and lateral views in case of closed reduction and precautions were taken to engage both cortices to cross above the fracture site and not to cross the olecranon fossa. K-wires were bent and kept at least 1 cm outside the skin. Sterile pin-tract dressing was applied.

2.6 Post-operative management

Post-operatively above elbow POP slab applied in an appropriate position. Operated limb was kept elevated using an arm sling. Patient was encouraged to move fingers. A careful observation for any neurovascular deficit was done at regular intervals. Appropriate antibiotics and analgesics therapy were used. On 2nd post-operative day, dressing check was done and condition of the operative wound or pin site were noted. X-ray checks in antero posterior & lateral views were taken. Patients were discharged on 2nd or 3rd post-operative day with oral antibiotics.

2.7 Follow-up

These patients were reviewed on 12th post-operative day on outpatient basis for suture removal and dressing check. K-wires removal done between 3 to 5 weeks post-operatively after X- ray confirmation of satisfactory callus formation.

POP splint was discarded at the same time and patient was encouraged to do active elbow flexion extension and supination - pronation exercises. Patients were advised to avoid massage and passive stretching and not to lift heavy weights till 12 weeks post-operatively. Follow up was done on OPD basis at 3rd, 4th, 5th, 12th and 24th weeks post operatively by clinical and radiological evaluation, and results were assessed based on pain, swelling, tenderness at fracture, movements of the elbow, carrying angle of the elbow compared to normal side and X-ray check for union at fracture site. The results were analyzed based on the criteria laid down by Flynn ^[10] as below.

Table 1: Flynn's grading system

Result	Rating	Cosmetic factor:	Functional factor:
		Carrying angle loss (degrees)	motion loss (degrees)
Satisfactory	Excellent	0-5	0-5
	Good	6-10	6-10
	Fair	11-15	11-15
Unsatisfactory	Poor	> 15	>15

2.8 Statistical analysis

The assimilated data was analyzed using various statistical methods like descriptive statistics (mean, standard deviation, standard error), chi-square test. p-value <0.05 was considered significant. Estimates of population proportions were obtained using estimator sample proportions and 95% confidence intervals under standard normal distribution approximation for large sample. All statistical analysis was done using Microsoft Excel 2007 and statistical software like SPSS.

3. Results

In our study, patients were in the age range of 2-12 years with male preponderance (72.22%) as compared to females (27.78%). The mean age of the patients was found to be 6.64 years. (Table 2)

Table 2: Demographic profile of patients enrolled in the study.

S. No.	Characteristics	No. of cases	Percentage
1.	Age (in years)		
	0-4	8	22.22
	4-8	14	38.89
	8-12	14	38.89
2.	Gender		
	Male	26	72.22
	Female	10	27.78

2 Cross-wire (2C) and 2 Lateral (2L) fixation method was done for 81.25% and 18.75% of Gartland-II type fracture. Similarly, 2 Cross-wire (2C) and 3K-wire fixation type was done for 25.00% and 75.00% of Gartland-III fracture type. (Table 3) Statistical analysis of proportions of post-operative complications for 2C and 3K fixation revealed that methods are same with p-value 0.091, making this an insignificant result (Value of Z-test statistic 1.332).

Table 3: Fixation method and fracture type

Fixation method	Fracture type	
	Gartland-II	Gartland-III
2 Cross-wire (2C)	81.25%	25.00%
2 Lateral (2L)	18.75%	0.00%
3K-wire	0.00%	75.00%

In majority of patients i.e. 50% 2 Cross-wire (2C) fixation

method was done followed by 3 K-wire fixation method in 41.67% and 2 lateral (2L) fixation method was applied in 8.33% patients. (Figure 1).

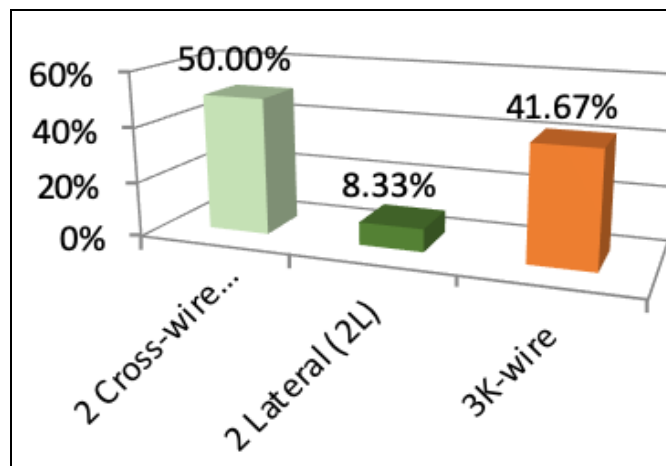


Fig 1: Distribution of patients according to fixation method

Duration of hospital stay of patients undergone different fixation methods was plotted in Figure 2. Statistical analysis of mean hospital length of stay for fixation methods 2C and 3K are same with p-value 0.609, making this a insignificant result (value of test statistics -0.5156, degrees of freedom 31, test statistic used two sample two sided t-test under the assumption of equality of variance) Variances are same with p-value 0.7224, value of test statistics 0.839, test statistics used: F-statistics (two sided test) with degree of freedom.

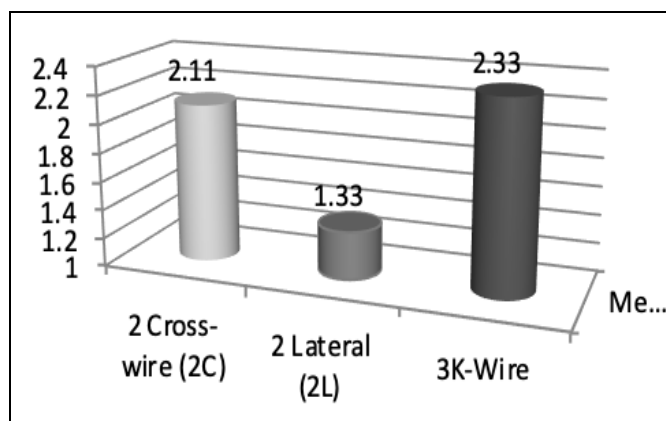


Fig 2: Duration of hospital stay of patients undergone different fixation methods

The observations of Flynn's grading score for different fixation methods viz. 2 Cross-wire (2C), 2 Lateral (2L) and 3K-wire was represented in Table 4 and 5. Proportions of satisfactory grading in all fixation methods (2C, 2L and 3K) are same with p-value=1 (test statistic used: Fisher Exact test for Count Data-two sided) Hence results found no significant difference between fixation methods and Flynn's grading score.

Table 4: Flynn's grading system (Loss of carrying angle)

Fixation method	Satisfactory				Unsatisfactory
	Excellent	Good	Fair	Satisfactory	Poor
2 Cross-wire (2C)	55.56%	33.33%	5.56%	94.44%	5.56%
2 Lateral (2L)	100.00%	0.00%	0.00%	100.00%	0.00%
3K-wire	60.00%	33.33%	6.67%	100.00%	0.00%

Table 5: Flynn's grading system (Loss of range of motion)

Fixation method	Satisfactory				Unsatisfactory
	Excellent	Good	Fair	Satisfactory	Poor
2 Cross-wire (2C)	72.22%	11.11%	11.11%	94.44%	5.56%
2 Lateral (2L)	100.00%	0.00%	0.00%	100.00%	0.00%
3K-wire	73.33%	13.33%	13.33%	100.00%	0.00%

Table 6: Mean and p-value of various parameters (Overall)

	Fixation Methods		P-value
	2C	3K	
Hospital Length of Stay (days)	2.11 ± 0.29	2.33 ± 0.35	0.609
Loss of Carrying Angle (degree)	4.28 ± 1.18	3.27 ± 1.10	0.529
Loss of Carrying Angle (% satisfactory result)	94.44	100.00	1.000
Loss of Range of Motion (degree)	3.44 ± 1.50	2.20 ± 1.04	0.506
Loss of Range of Motion (% satisfactory result)	94.44	100.00	1.000
Post-operative Complication (% Cases)	11.11	0.00	0.091

4. Discussion

A supracondylar fracture of the humerus is one of the most common injuries in children. Difficulty in treating this fracture lies in the fact that this gets complicated very often. Initial treatment and definitive treatment of this fracture is of utmost importance. The main objectives of the treatment of supracondylar fractures are to achieve functionally and cosmetically satisfactory results and to avoid complications. Assuring a low cost and decreasing the hospitalization period are very important for both surgeons and patient's parents. In this clinical study, 36 children with supracondylar fracture of humerus were included and treated with closed reduction and K-wire pinning for displaced extension type of supracondylar fracture of the humerus in children. Results of the surgery with reference to restoration of function and prevention of complications of the fracture was evaluated.

The treatment of supracondylar fracture of humerus in children is quiet challenging. These fractures are very common in children between 5 to 10 years of age as reported in studies by Ziontes *et al.* [11] In the present study mean age of study subjects was 6.64 years which is similar to other studies [12, 13]. The incidence of this type of fracture was reported to be more in boys than girls. In the present study, 26 (72.22%) were male patients and 10 (27.78%) were female. These findings are in concurrence with other studies [14, 15]. Based on Gartland's classification, 16 (44.44%) patients had Type II fracture and 20 (55.56%) had Type III fracture. Type-III fractures predominance was reported in other studies [16, 17]. It was evident from previous studies that posteromedial displacement was much more common than posterolateral. In our study, among 20 cases who had type III fracture, 85% had posteromedial displacement and 15% had posterolateral displacement. In the present study, one patient had superficial pin tract infection, which was treated with appropriate antibiotic therapy and was recovered fully, another one patient had cubitus varus deformity (12°) of the left arm with good functional range of movements, for which no intervention was done. These findings are in concurrence with previous studies [2, 3]. Boyd *et al.* prefer two parallel laterally inserted K-wires for percutaneous fixation, if fracture is stable. If it is unstable, they prefer crossed medial and lateral K-wires. In their series, 70 out of 71 patients had satisfactory results. Six patients had neurovascular complications. One ulnar and two interosseous nerve palsies were documented before surgery, and two cases treated with crossed medial and lateral pins had iatrogenic ulnar nerve palsies at postoperative clinical examinations. All nerve palsies had completely

The overall mean and p-values of various parameters was represented in the Table 6. This study revealed that the mean hospital length of stay for 2C and 3K fixation methods was 2.11 ± 0.29 and 2.33 ± 0.35 (p=0.609) respectively. The satisfactory result for loss of carrying angle and loss of range of motion (ROM) was 94.44% and 100% for 2C and 3K fixation methods respectively.

recovered by the time of the follow-up evaluation. [18]

The average duration of hospital stay in this study was 2.14 days with a p-value of 0.6098 (95% CI is 2-3days). These findings are comparable to previous study reported by Flynn *et al.* Ramsey *et al.* [10, 12] In our study out of 36 cases, 35 cases obtained satisfactory results (22 excellent, 11 good and 2 fair results) and 1 case had unsatisfactory results. Similar results were obtained by other studies [2, 6, 19]. At the final follow up, 0- 5° loss of range of motion of the affected extremity was noted in 27 (75%) patients and more than 15° loss of range of motion was noted in only 1 (2.78%) patient in our study. The mean loss of range of motion was observed as 2.75° in the present study. Nacht *et al.* noted mean loss of range of motion was 7.8° at the final follow up examination in their study. Whereas, the mean carrying angle loss of 5.8 degree (range 2°-15°) in 20 patients and increased carrying angle in 4 patients by an average of 6.8° at the final follow up examination [6]. Flynn *et al.* reported mean loss of carrying angle was 6.2 degrees [10].

Pirone *et al.* reviewed 230 patients treated by different methods. The highest percentage of excellent results were achieved by percutaneous K-wire fixation (78%), skeletal traction (67%) and open reduction with internal fixation (67%). No ulnar nerve injuries were attributed to the medial pin and two pin track infection occurred in percutaneous pin fixation group [2].

Flynn *et al.* reported out of 52 patients treated by closed reduction and percutaneous-pin fixation 51 (98%) patients had satisfactory results by their own criteria. They reported that one patient had transient ulnar neuropathy due to medial pin insertion. Two patients had loss of reduction. There were no pin tract infections, broken pins or growth disturbances [10]. France *et al.* reported a large series treated with different methods. They found significantly better clinical results in the patients treated with closed reduction and percutaneous pin fixation. On the other hand, when they compared the two groups, treated with two lateral pins, and crossed medial and lateral pins, they found no significant difference between the groups. Only one patient had ulnar nerve palsy in the crossed medial and lateral pins [20].

In our study, the final results evaluated by Flynn's criteria depicted that 97% of patients had satisfactory results. The result of the present study compares favourably with those of other previously reported methods of treatment of the displaced supracondylar fractures of the humerus in children. The present study revealed that closed reduction and percutaneous fixation using K-wires would be the most

appropriate method for the treatment of displaced supracondylar fractures of the humerus in children.

5. Conclusion

In conclusion, closed reduction and percutaneous pin fixation for displaced supracondylar fractures of humerus in children is a simple, cheap and safe method of treatment that gives excellent to good functional results with relatively fewer complications.

6. Acknowledgements

None

7. Conflicts of Interest

Nil

8. References

- David DA, Bruce IP. Supracondylar fractures of humerus-a modified technique of closed pinning. *CORR*. 1987; 219:174-84.
- Pirone AM, Graham HK, Krajbich JI. Management of displaced extension-type supracondylar fractures of the humerus in children. *The Journal of bone and joint surgery*. American volume. 1988; 70(5):641-650.
- Mostafavi HR, Spero C. Crossed pin fixation of displaced supracondylar humerus fractures in children. *Clinical Orthopaedics and Related Research (1976-2007)*. 2000; 376:56-61.
- James HB. *Rockwood & Willkin's Fractures in children*. Fifth Edition, Lippincot Williams & Wilkinson, 2001, 563-624.
- Herring JA. In: *Tachdjian's Pediatric Orthopaedics*. 3rd ed. Philadelphia: W.B. Saunders. 2002; 3:2139-221.
- Nacht JL, Ecker ML, Chung SM, Lotke PA, Das M. Supracondylar fractures of the humerus in children treated by closed reduction and percutaneous pinning. *Clinical orthopaedics and related research*. 1983; (177):203-9.
- Canale TS. *Campbell's Operative Orthopaedics*, 9th edition, Vol. 3. New York: Mosby; 1998. Fractures and Dislocations in Children. 1998; 2407-2422.
- Robert EL, Ryan WS, Peter MW. Supracondylar fractures of humerus. *OCNA*. 1999; 30:120-124.
- Attenborough CG. Remodelling of the humerus after supracondylar fractures in childhood. *The Journal of bone and joint surgery*. British volume. 1953; 35(3):386-95.
- Flynn JC, Mathews JG, Benoit RL. Blind pinning of supracondylar fractures of the humerus in children. *J Bone & Joint Surg (Am)*. 1974; 56A:263-272.
- Zionts LE, McKellop HA, Hathaway R. Torsional strength of pin configurations used to fix supracondylar fractures of the humerus in children. *The Journal of bone and joint surgery*. American volume. 1994; 76(2):253-6.
- Ramsey RH, Griz J. Immediate open reduction and internal fixation of severely displaced supracondylar fractures of the humerus in children. *Clinical Orthopaedics and Related Research (1976-2007)*. 1973; 90:130-2.
- Ippolito E, Scola E. Supracondylar fractures of humerus in children. *The Journal of bone and joint surgery*. 1986; 68:333-334.
- Wilkins KE. The operative management of supracondylar fracture. *Orthop Clin North Am*. 1990; 21(2):269-289.
- Almohrij SA. Closed reduction with and without percutaneous pinning in supracondylar fractures of the humerus in children. *Annals of Saudi medicine*. 2000; 20(1):72-74.
- Zamzam MM, Bakarman KA. Treatment of displaced supracondylar humeral fractures among children: crossed versus lateral pinning. *Injury*. 2009; 40(6):625-30.
- Zhong ZP, Cao J. Comparison of two approaches for the treatment of supracondylar fractures in children by K-wires. *Zhongguo Gu Shang*. 2009; 22(10):767-769.
- Boyd DW, Aronson DD. Supracondylar fractures of the humerus: a prospective study of percutaneous pinning. *Journal of pediatric orthopedics*. 1992; 12(6):789-794.
- Richard TD, John TG. Supracondylar fractures of humerus in children, a comparison of operative treatment methods *CORR*. 2000; 376:49-55.
- France J, Strong M. Deformity and function in supracondylar fractures of the humerus in children variously treated by closed reduction and splinting, traction, and percutaneous pinning. *Journal of pediatric orthopedics*. 1992; 12(4):494-498.