



International Journal of Orthopaedics Sciences

E-ISSN: 2395-1958
P-ISSN: 2706-6630
IJOS 2019; 5(4): 748-752
© 2019 IJOS
www.orthopaper.com
Received: 11-08-2019
Accepted: 15-09-2019

Dr. Gaurang Patel
Associate professor, Department
of Orthopaedics, Medical College
and SSG Hospital, Baroda,
Gujarat, India

Dr. Aarjav Naik
Senior Resident, Department of
Orthopaedics, Medical College
and SSG Hospital, Baroda,
Gujarat, India

Dr. Hemant Mathur
Professor and Head, Department
of Orthopaedics, Medical College
and SSG Hospital, Baroda,
Gujarat, India

Dr. Nisarg Trivedi
Senior Resident, Department of
Orthopaedics, Medical College
and SSG Hospital, Baroda,
Gujarat, India

Dr. Bhavin Rathva
Senior Resident, Department of
Orthopaedics, Medical College
and SSG Hospital, Baroda,
Gujarat, India

Corresponding Author:
Dr. Gaurang Patel
Associate professor, Department
of Orthopaedics, Medical College
and SSG Hospital, Baroda,
Gujarat, India

One stage bilateral total hip arthroplasty in Indian patients

Dr. Gaurang Patel, Dr. Aarjav Naik, Dr. Hemant Mathur, Dr. Nisarg Trivedi and Dr. Bhavin Rathva

DOI: <https://doi.org/10.22271/ortho.2019.v5.i4m.1763>

Abstract

There are few studies which investigate peri-operative safety and surgical outcome of one stage bilateral total hip arthroplasty. Avascular necrosis of hip is the most common indication for total hip arthroplasty which is frequently bilateral. In present study, we studied 30 patients who were operated with one stage bilateral total hip arthroplasty. Most of them (93%) were suffering from avascular necrosis of hip. We analysed intra-operative blood loss, peri-operative blood transfusion requirement, length of hospital stay and peri-operative complications for the aforesaid patients. All patients were followed up for a period of 6 months post-operatively to determine functional outcome using harris hip score. We concluded that one stage bilateral total hip arthroplasty is safe and efficacious treatment modality for our patients. This study also demonstrates brisk rehabilitation in patients operated with single stage bilateral total hip arthroplasty.

Keywords: One stage, simultaneous, bilateral total hip arthroplasty, harris hip score, surgical outcome

Introduction

The invention of total hip arthroplasty (THA) has drastically changed management of patients with advanced hip disorders. With THA, it is now possible to restore patient's life to near normal and to put an end to debilitating pain caused by arthritic hip. Thus, THA is correctly termed Operation of century by Lancet journal ^[1]. Osteoarthritis and avascular necrosis (AVN) are two major indications for THA ^[2]. At the time of diagnosis, disease can be unilateral or bilateral. Avascular necrosis is frequently bilateral. In unilateral cases, if there is radiological involvement on opposite side it will not remain asymptomatic for prolonged time. Conversely, asymptomatic contralateral hip without radiographic evidence of AVN is unlikely to develop clinically significant AVN. AVN is a disease of young people with average age of patient reported at 38 years ^[3]. This disease affecting people in their productive life makes burden of disease on society very high. Considering this, it is important to find effective means for its treatment. Bilateral total hip arthroplasty is indicated for bilateral disease. This can be done either as simultaneous procedure or staged procedure. The first simultaneous bilateral total hip arthroplasty was performed by Charnley *et al* in 1971. He had published a study of 50 simultaneous bilateral total hip arthroplasties ^[4]. After that multiple studies have been published comparing simultaneous and staged bilateral total hip arthroplasty. Some specific concerns are as follows:

- Blood loss
- Thromboembolism
- Peri-operative mortality
- Faster rehabilitation
- Reduced cost and Shorter hospitalisation

One of the major considerations for simultaneous bilateral total hip arthroplasty is significantly higher blood loss and subsequent higher requirement of allogenic blood transfusion. However, when compared with staged bilateral total hip arthroplasty meta-analysis of studies by shao *et al* found no significant increase in cumulative blood loss of both hip arthroplasties.

Also, requirement of allogenic blood transfusion was similar in both groups [5]. Strategies used to reduce perioperative blood loss and allogenic transfusion requirement are use of injection tranexamic acid [6], autologous blood transfusion [7] and perioperative blood salvage using cell saver machine which is transfused back post-operatively [8].

Theoretically, risk of deep vein thrombosis increases during simultaneous bilateral total hip arthroplasty because of prolonged surgical procedure and blood loss. However, recent meta-analysis concluded that there was no significant difference between patients of simultaneous and staged bilateral total hip arthroplasty [5]. Risk of peri-operative mortality after total hip replacement is extremely small. Significant causes of peri-operative mortality are hypotensive shock, fat embolism, exacerbation of pre-existing disease like sickle cell disease and cardiac complications. Most common causes of death in peri-operative period post THR are cardiovascular complications and pulmonary embolism [9]. Presently, meta-analysis by Shao *et al.* concluded no difference between simultaneous and staged bilateral total hip arthroplasty [5]. Simultaneous bilateral total hip arthroplasty offers significantly faster rehabilitation and recovery for bilateral disease as compared with staged bilateral THR. It has been noted that when unilateral THR is done for bilateral disease, there is significant restriction of daily activities as compared to simultaneous bilateral THR [10].

Simultaneous bilateral total hip replacement leads to surgery of both hips under one time anaesthesia, single set of peri-operative investigations, single post-operative antibiotics regime and significantly shorter hospital stay. These factors lead to significant reduction in cost of treatment which is especially important in country like India. Currently, there is only one published study from India evaluating outcome of simultaneous bilateral total hip replacement arthroplasty [11]. So, there is need of other studies for better evaluation of simultaneous bilateral total hip arthroplasty as treatment modality of bilateral hip disease. This study is precisely aimed in that direction.

Materials and Methods

The present study was carried out on 30 patients of either sex who were admitted in the Department of Orthopaedics, Shri Sayajirao General Hospital, Vadodara between May 2016 and June 2018.

Inclusion criteria

- Patients with bilateral hip disease regardless of aetiology (sickle cell disease, chronic steroid use, chronic alcoholism, primary osteoarthritis etc.)
- Patients of adult age group (>18 years).

A detailed history was taken regarding name, age, sex, occupation, chief complains, pain, limp, severity of pain, duration of symptom, any deformity in the limb, any treatment taken for every patient. Thorough general physical examination was done including vital signs. Local examination was performed to record any swelling, local tenderness, deformity, shortening of extremity, movements of the both hips, gait, limb length discrepancy, involvement of any other joints in that extremity. Pre-operative Harris Hip score was calculated for every patient. Following blood investigations were carried out: CBC, S. Urea, S. Creatinine, S. bilirubin, RBS, Blood Grouping and Viral markers. Following investigations were done in every patient as a part of THR profile:

1. Erythrocyte Sedimentation Rate(ESR)
2. C- reactive Protein
3. RA Factor
4. Sickle solubility test

Haemoglobin electrophoresis was done to differentiate between Sickle Cell Disease and Sickle cell Carrier State if sickle solubility test turned out to be positive.

Xray of both hips, AP view and Frog leg view were obtained pre-operatively. Patients with systemic diseases like hypertension and diabetes mellitus were treated as per physician's advice and the respective pathologies were brought under control. Sickle Cell Disease was managed peri-operatively by means of oral and injectable hydration therapy and oral alkaline therapy with Tablet Sodamint (contains sodium bicarbonate 300 mg) 2 tablets five times a day. The local parts were cleaned and scrubbed on early morning on the day of surgery. The scrubbed local parts were then wrapped in sterile surgical sheets prior to shifting the patient to the operation theatre.

All the instruments were autoclaved for two sessions of 20 min. each at a temperature of 121 °C and pressure of 15 psi. The operation theatre was cleaned and fumigated on the previous night so as to maintain the utmost asepsis. Functioning of Laminar airflow system was also checked. Two different sets of instrumentation were prepared for bilateral THR and kept near laminar air flow unit. One set was utilized for each THR. During first surgery, instrument trolley for second surgery was kept covered. Instrumentation set included general instruments as well as set of total hip arthroplasty. After first surgery, Surgeon, assistants as well as nurse de-scrubbed and the whole team scrubbed again for second surgery.

Patients were operated under spinal anaesthesia or combined spinal plus epidural anaesthesia or in some cases general anaesthesia (if specifically indicated). Epidural catheter when used was kept in situ for 24-48 hours to provide post-operative analgesia. Pre-operative medications were given five minutes before skin incision. This included 1000 mg tranexamic acid [6], 400 mg teicoplanin, 1500 mg cefosulbactam. In patients with tight adductors, adductor tenotomy was done preoperatively to facilitate intraoperative dislocation of femoral head. The side where patient had more pain was operated first. Lateral position on a straight table was used for the operative procedure and the patient was anchored firmly using side supports of the table. After the surgery, patient was kept in supine position and adductor tenotomy was done on opposite side if required. Then lateral position for opposite side was given. Once the patient was firmly anchored to the table and the position adjusted, the parts were scrubbed properly for about 10 minutes and then the parts were painted with 10 % povidone iodine solution. Maintaining strict asepsis entire lower limb was draped freely with sterile linen. Then second layer of draping was done with disposable Hip U drape. OPSITE® transparent incise drape was directly applied over incision site.

All patients were operated using standard moore's posterior approach. Posterior dislocation of hip was achieved by flexing, adducting and gently internally rotating the hip. If the hip could not be easily dislocated, the femur was never forcibly internally rotated. Instead, it was ensured that the superior and inferior portions of the capsule had been released as far anteriorly as possible and Gluteus maximus was released near its insertion on the femur. Any osteophytes along the posterior rim of the acetabulum that may be

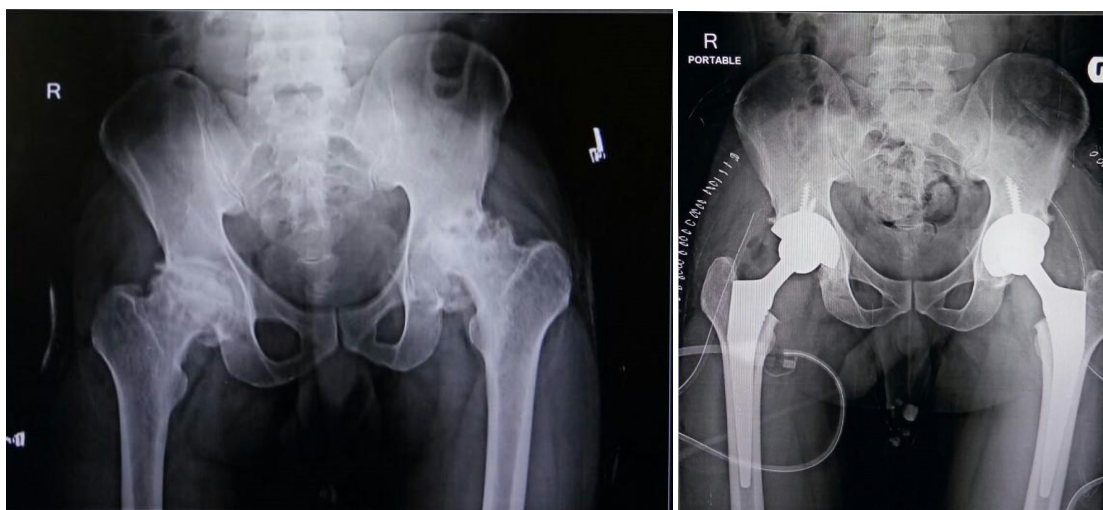
incarcerating the femoral head were removed. Lastly Ilio-Psoas muscle release was done at the lesser trochanter. If the hip still could not be dislocated without undue force, the femoral neck was divided with an oscillating saw at the appropriate level and it was divided into several pieces and removed piecemeal. Adequate reaming was judged by "PAPRIKA SIGN". Uncemented acetabular and femoral components were implanted. Appropriate femoral head was chosen after assessing stability and mobility of hip. After reduction of femoral head, posterior soft tissue envelope: capsule & external rotators were repaired. A negative suction drain was kept under fascia lata and layered closure of the wound was done. Same procedure was repeated on the opposite side. Intra-operatively, Packed Cell Volume (PCV) was transfused according to anaesthetist's advice.

Post-operative protocol

Injection tranexamic acid (1000 mg) was repeated at 4 hours post-operatively. Intravenous antibiotics were given for 5-7 days followed by oral antibiotics. Usual protocol was

Injection Teicoplanin (400mg) for 3 days, Injection Cefosulbactam (1.5gm) twice a day and Injection amikacin (500mg) thrice a day for 5 days. Oral or intravenous Diclofenac or Tramadol was used for analgesia. Catheters, IV line and other foci of infection were removed as early as possible. All patients under this study received prophylaxis for deep vein thrombosis, pulmonary embolism with 10 mg of oral rivaroxaban tablet for 21 days from the day of surgery. Usage of rivaroxaban was delayed if epidural catheter was kept in situ. Rivaroxaban was started 6 hours post epidural catheter removal. Post-operative Haemoglobin was assessed on first post-operative day. According to clinical profile of patient, allogenic blood transfusion in form of Packed Cell Volume (450 ml) were given if required. Closed suction drain was removed 2-3 days after surgery, depending upon the drain output.

X-ray was done when patient was shifted to ward from operation theatre. Sutures were removed on 14th - 18th day after surgery routinely depending on the status of the dressing and the local part.



Pre-operative xray

Post-operative Xray

Physiotherapy and rehabilitation

Weight bearing for each patient was individualised depending upon intra-operative fixation of implant to the bone. Some patients were allowed full weight bearing with walker from first post-operative day onwards. While in other patients, weight bearing was delayed for 4 to 6 weeks. Weight bearing with walker was gradually shifted towards walking with stick and walking without any support as per patient's comfort. Patients were instructed not to squat, sit cross-legged for at least 6 months. They were advised to use western style toilets. As all the patients were of reproductive age group, advice regarding sexual activity was given. The patients were instructed to avoid sexual activity for a period of 1 to 2 months till healing of posterior stabilizing elements, skin and subcutaneous tissue occurs [12]. Patients were advised to avoid internal rotation, avoid flexing hip more than 90° and crossing ankles. Then gradual resumption of sexual activity was allowed. Supine position and standing position were recommended. Patients were advised to avoid lateral decubitus position [13]. Patient was discharged after two dressings if both dressings turned out to be dry. Patients were followed up at post-operative period of 1 month, 3 months and 6 months clinically and radiologically.

Results and Discussion

Majority of the patients in the study were of 41-50 years age

group. This clearly indicates that avascular necrosis of hip which was the indication for THR in most of the cases in present study is a disease of young. It has onset early in life and becomes debilitating by the time patient hits middle-age. Two patients who had inflammatory bilateral hip arthritis due to ankylosing spondylitis had mean age of 28 years. This concludes that inflammatory arthritis due to ankylosing spondylitis can progress rapidly in some cases requiring joint replacement at early age. The male to female ratio of present study was 2.3:1. Apart from two patients who had inflammatory arthritis due to ankylosing spondylitis, all patients were having avascular necrosis of hip. In one case, history of chronic steroid use due to skin disease was elicited which frequently leads to bilateral involvement. Despite mandatory screening by sickling test, only 15% (4 out of 27) of patients had sickle cell disease. In all 4 patients, sickle cell disease was diagnosed by high performance liquid chromatography (HPLC). In rest 85% (23 out of 27) patients, no cause was found for AVN and hence were labelled idiopathic.

Two patients with ankylosing spondylitis had involvement of spine. Treatment of ankylosing spondylitis in form of oral indomethacin and sulfasalazine was started after removal of sutures. Patient's hip pain was immediately relieved after surgery but pain due to spondylitis gradually subsided over a period of three months. Four patients with sickle cell disease

were managed with special care during peri-operative period to avoid sickling crisis. All the patients were encouraged to increase oral intake of fluid (at least 4 litres/day). All the patients were also given hydration by means of intravenous fluids during hospital stay. All the patients were given tablet sodamint to alkalinize blood.

Adequate availability of PCVs was ensured during peri-operative period in case the need for blood transfusion arises. None of the patient developed sickling crisis. This indicates that this type of special care provides reasonable protection against sickling crisis. Preoperative assessment was done using Harris hip score. Harris hip score for both hips was calculated independently and mean of both was taken. Mean preoperative score was 43.1. Average Harris hip score for patients of ankylosing spondylitis was 29. This is well below the average which indicates rapid progression of inflammatory arthritis in ankylosing spondylitis. Both patients of ankylosing spondylitis had fixed flexion deformity preoperatively. Another two patients had fixed flexion deformity on unilateral side preoperatively. 53% of patients in the study were operated under spinal and the rest were operated under epidural anesthesia. When spinal anesthesia was given, 5 micrograms of dexmedetomidine was used as adjuvant to bupivacaine for long lasting effect. When used, epidural catheter was kept in situ for 48 hours for pain relief. For simultaneous bilateral total hip arthroplasty, blood loss in relatively short time period is important concern. Intraoperative blood loss was measured in this study. Average blood loss was 890 ml. Maximum blood loss was 1300 ml. Blood transfusion in form of packed cell volume (PCV) was given during intraoperative and postoperative period. Average number of units transfused was 1.5. Only two patients required three or more units. Requirement of allogenic blood transfusion is important concern for simultaneous bilateral total hip arthroplasty. Allogenic blood transfusion exposes patient to risk of blood borne disease and blood transfusion reaction. However, this can be minimized by proper cross-matching and universal screening of donated blood. One of the means by which simultaneous bilateral total hip arthroplasty curtails cost in comparison of staged bilateral total hip arthroplasty is reduction in period of hospitalization. Average stay in our study is 7 days. Implant position was assessed on post-operative x-rays. Inclination of all acetabular shells was in the range of 30°-50°. Alignment of femoral stem was calculated.

Table: Alignment of femoral stem

Alignment	No. of cases	Percentage
Neutral	48	80
Valgus	09	15
Varus	03	05
Total	60	100

Only two patients developed intraoperative complication in form of hypotension due to acute blood loss. In both cases, patients were given vasopressor support with dopamine, noradrenaline with blood transfusion. Both patients were monitored post-operatively. Gradual tapering of vasopressor support was done. This highlights that simultaneous bilateral total hip arthroplasty is a major surgical procedure and availability of intensive postoperative monitoring along with anaesthetist and physician is must. Dedicated surgical intensive care unit is also desirable.

Two patients developed late postoperative complications. One patient developed surgical site infection on right side 3

months after surgery. Patient had developed swelling over hip with serous discharge and high-grade intermittent fever. Patient was treated with surgical debridement and injectable antibiotics postoperatively according to culture & sensitivity report. Other patient developed deep vein thrombosis 4 months after surgery. Patient presented with painful unilateral lower limb swelling. Diagnosis was confirmed by doppler study. Patient was admitted in surgery department where patient was kept on 0.6 milligrams of enoxaparin given subcutaneously per day. Patient recovered uneventfully. Average mean Harris hip score at final follow-up was 83.7. This is a drastic improvement over preoperative value of 43.1. This difference was further higher at 45 points in patients with ankylosing spondylitis.

Table: Result at final follow-up

Result (Harris hip score)	Final follow-up
Excellent(90-100)	7
Good(80-89)	16
Fair(70-79)	7
Poor(<70)	0
Total	30

83% of patients had moderate or severe pain with restriction of daily activities preoperatively. This improved dramatically with 80% of patients having no pain at final follow-up. While the rest had minimal or mild pain without any restriction of routine activities. This indicates that all the patients were able to restore their life to near-normal levels after surgery. All the patients had started sexual activity 2 months after surgery. All the patients were comfortable in regard of sexual intercourse at final follow-up.

Conclusion

One stage bilateral total hip arthroplasty is safe and cost-effective treatment modality for bilateral hip disease in our patients. Being a major surgical procedure, well equipped operation theatre, round the clock availability of physicians, functioning surgical intensive care unit are desirable. This procedure can also be performed safely in patients with sickle cell disease provided strict peri-operative care to avoid sickling crisis is taken. However, a large study for patients with sickle cell disease is required for better assessment.

References

1. Learmonth ID, Young C, Rorabeck C. The operation of century: total hip replacement. *Lancet*. 2007; 370:1508-19. DOI:10.1016/S0140-6736(07)60457-7
2. Campbell's operative orthopedics. 12th edition. Chapter 3. Arthroplasty of hip. 2013, p.207.
3. Babhulkar S. Osteonecrosis of the femoral head (in young individuals). *Indian Journal of Orthopaedics*. 2003; 37:2.
4. Jaffe WL, Charnley J. Bilateral Charnley low-friction arthroplasty as a single operative procedure: A report of fifty cases. *Bull Hosp Jt Dis*. 1971; 32(2):198-214.
5. Shao H, Chen C-L, Maltenfort MG, Restrepo C, Rothman RH, Chen AF. Bilateral Total Hip Arthroplasty: One-stage or Two-stage? A Meta-analysis, *The Journal of Arthroplasty*.
6. Yamasaki S, Masuhara K, Fuji T. Tranexamic Acid Reduces Postoperative Blood Loss in Cementless Total Hip Arthroplasty. *The journal of bone & joint surgery*. JBJS. Org. 2005; 87-A:4.
7. Gee A, Garino J, Lee G. Autologous blood reinfusion in

- patients undergoing bilateral total hip arthroplasty. *Journal of Orthopaedic Surgery*. 2011; 19(2):181-4.
8. Friederichs MG, Mariani EM, Bourne MH. Perioperative blood salvage as an alternative to predonating blood for primary total knee and hip arthroplasty. *The Journal of Arthroplasty*. 2002; 17(3):298-303. doi:10.1054/arth.2002.30409.
 9. Ashley Blom, Giles Pattison, Sarah Whitehouse, *et al.* Early death following primary total hip arthroplasty: 1727 procedures with mechanical thrombo-prophylaxis. *Acta Orthopaedica*. 2006; 77(3):347-350.
 10. Yoshi T, Jinno T *et al.* Postoperative hip motion and functional recovery after simultaneous bilateral total hip arthroplasty for bilateral osteoarthritis. *J Orthop Sci*. 2009; 14:161-166. DOI: 10.1007/s00776-008-1303-x
 11. Bhan S, Pankaj A, Malhotra R. One or two stage bilateral total hip arthroplasty. *J Bone Joint Surg [Br]*. 2006; 88-B:298-303. doi:10.1302/0301-620X.88B3.
 12. Zahi S, Mahir L, Tounsi J *et al.* *Physiother Rehabil*. 2017; 2:2. DOI: 10.4172/2573-0312.1000136.
 13. Charbonnier C, Chague S, Ponzoni M *et al.* Sexual activity after total hip arthroplasty: A motion capture study. *The Journal of Arthroplasty*. 2014; 9:640-647.