



E-ISSN: 2395-1958  
P-ISSN: 2706-6630  
IJOS 2019; 5(4): 698-702  
© 2019 IJOS  
www.orthopaper.com  
Received: 24-08-2019  
Accepted: 28-09-2019

**Dr. Rohit Kewat**  
MBBS, Diploma in  
Orthopaedics, A.F.I.H, Empire  
Estate, Old Mumbai-Pune  
Highway, Chinchwad, Pune,  
Maharashtra, India

**Dr. Vaibhav Patil**  
MBBS, Diploma in  
Orthopaedics, Vedant Hospital,  
Near Thermax Chowk, M.I.D.C,  
Chinchwad, Pune, Maharashtra,  
India

**Dr. Pratika Kawle**  
MBBS, Diploma in  
Orthopaedics, YCM hospital,  
Sant Tukaram Nagar, Pimpri,  
Pune, Maharashtra, India

**Corresponding Author:**  
**Dr. Rohit Kewat**  
MBBS, Diploma in  
Orthopaedics, A.F.I.H, Empire  
Estate, Old Mumbai-Pune  
Highway, Chinchwad, Pune,  
Maharashtra, India

# International Journal of Orthopaedics Sciences

## Percutaneous fixation of fractures of the calcaneus and its functional outcomes

**Dr. Rohit Kewat, Dr. Vaibhav Patil and Dr. Pratika Kawle**

**DOI:** <https://doi.org/10.22271/ortho.2019.v5.i4l.1757>

### Abstract

**Background:** Closed fractures of the calcaneum are common fractures of the lower limb and which usually result from by high velocity axial loading of the calcaneum. Open reduction and internal fixation methods have formed the mainstay of their treatment. However the associated wound complications have made the management of such injuries more difficult. Percutaneous fixation techniques provide an effective method of closed treatment of these fractures and can help avoid wound related complications.

**Methods:** Twenty- four patients with fractures of the calcaneum were treated with percutaneous reduction with Essex-Lopresti technique and fixation with Steinman pin and K-wires, followed by immobilization with a slab. The American orthopaedic foot and ankle score (AOFAS) was calculated at the final follow up. Also the heel width (with a vernier caliper) and the heel height (from lateral malleolus to the ground surface) were recorded at the final follow up.

**Results:** Of the total patients 8 had excellent, 10 had good and 6 had fair results. None of the patients had heel widening or loss of calcaneal height of more than 1 cm as compared to the contralateral limb. Complications seen were superficial pin tract infections (3) which were treated with early implant removal and appropriate antibiotics. The Bohler's angle at follow up was at a mean 30 degrees.

**Conclusion:** The percutaneous reduction of closed fractures of the calcaneum provides good functional results as per AOFAS score. It also helps avoid wound related complication seen in open techniques. The Essex-Lopresti technique of reduction of such fractures has a short learning curve and can be reproduced at most operative setups. Long term follow up studies and bigger sample sizes can help support our conclusions.

**Keywords:** Calcaneus; essex-lopresti, minimally invasive; AOFAS ankle score; functional outcomes

### 1. Introduction

Closed fractures of the calcaneum are injuries which commonly result in cases with history of a fall from height landing on the foot. These fractures result due to axial loading of the calcaneum, that is, fall from height, and therefore, many of these are bilateral or associated with pelvic or vertebral fractures<sup>[1, 2, 3]</sup>. The anatomy of the calcaneum, limited blood supply, limited soft tissue cover and the oedema resulting from the injury itself makes the treatment of such fractures more demanding. These fractures constitute of about 2 percent of all adult fractures and 60 percent of all fractures of the tarsal bones<sup>[1, 2]</sup>.

The treatment of such fractures is still debatable where the conservative management has been the mainstay of treatment in the past, while the open reduction and internal fixation have been suggested by many authors. Inadequate treatment leads to early subtalar arthrosis and painful ambulation<sup>[2, 3]</sup>. At the same time, open reduction and internal fixation methods have a very high rate of wound complications<sup>[4]</sup>. The sequelae for calcaneum fractures have a great socio economic impact as most of these injuries occur in the young and middle-aged male workers<sup>[5, 6]</sup>.

The use of percutaneous pinning in cases where closed reduction can be achieved has provided the benefit of achieving good results with minimal soft tissue complications. The most frequently used minimally invasive technique for the tongue type fracture was proposed in 1935 by Westhues, modified by Gissane, and studied extensively by Essex-Lopresti<sup>[7]</sup>. Essex-Lopresti classified the intrarticular fractures into joint depression- and tongue-type fractures.

The joint depression type is when the fracture line exits behind the posterior facet and anterior to attachment of Achilles tendon. Tongue-type fracture is when there is a secondary fracture line which exits distal to Achilles tendon attachment, and the articular fragment remains attached to the tuberosity fragment<sup>[8, 9]</sup>. The rates of infection and soft tissue complications have also found to be lower as compared to open fixations<sup>[10-13]</sup> the aim of this study is to evaluate the functional outcome of such fractures treated with percutaneous pinning and below knee cast application.

## 2. Methods

A total number of 24 patients with fractures of the calcaneum were included in this study. Skeletally mature patients with closed displaced calcaneal fracture, with no associated neurovascular injuries and with loss of Bohler's angle (Normal between 20-40 degrees) on lateral radiograph were included in this study. Patients with compound fractures, associated fractures of the ipsilateral lateral limb and undisplaced fractures were excluded from the study.

**2.1 Preoperative protocol:** All patients were evaluated clinically at the time of admission. The clinical presentation consisted complaints of pain, swelling, restricted range of motion and difficult to weight bear on the affected limb most commonly following a history of fall from height on the affected foot. The foot was further visualised under AP, lateral and Broden views. The foot was immobilized in a below knee slab and kept elevated to prevent further swelling. The anesthetic fitness was obtained as per general protocol. All patients were operated under spinal anesthesia. A regular fluoroscopy machine was made available and forms an important part of the surgery. The patient was explained the procedure and a general hand written consent was taken.

**2.2 Intra-operative protocol:** The patient was placed in lateral decubitus position with affected limb on top. Under all aseptic precautions, scrubbing, painting and draping of the limb was performed. Under guided fluoroscopy, a 4.5 mm Steinman pin was introduced from the calcaneal tuberosity. (Figure 1) Keeping the foot plantarflexed, the Essex-Lopresti maneuver was performed aiming to restore the Bohler's angle. (Figure 2) The steinman pin was then passed in to the distal fragment<sup>[7, 11, 12]</sup>. The reduction was then confirmed under fluoroscopy and an additional pin of about 3.5 mm was placed parallel to the first to further secure reduction. The pins were then cut and the ends covered with guaze soaked betadine dressing. A regular below knee slab was applied.

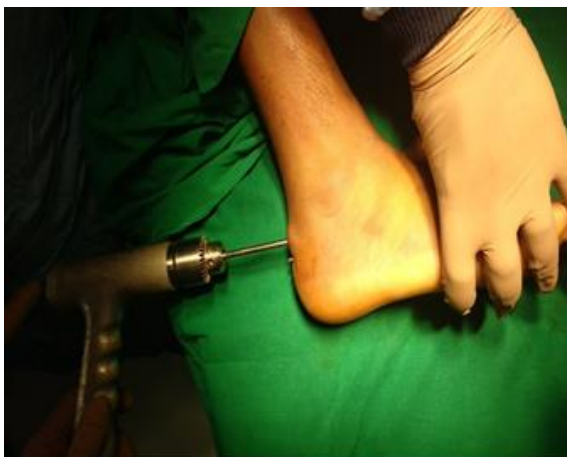

Fig 1: Demonstrating step one of Essex-Lopresti manoeuvre.

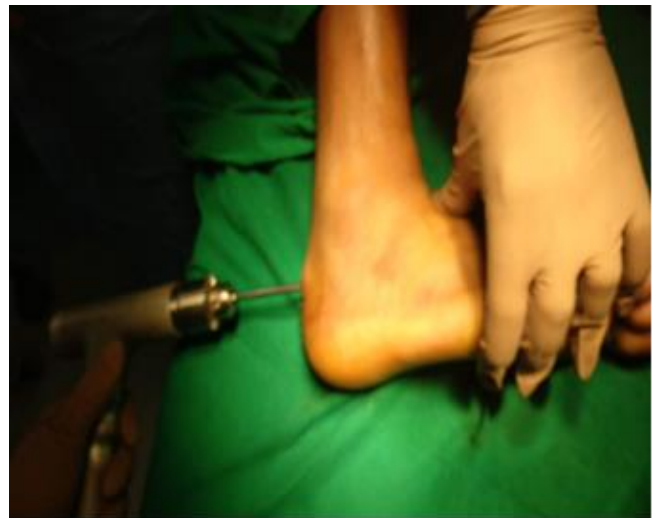

Fig 2: Demonstrating step two of Essex-Lopresti manoeuvre.

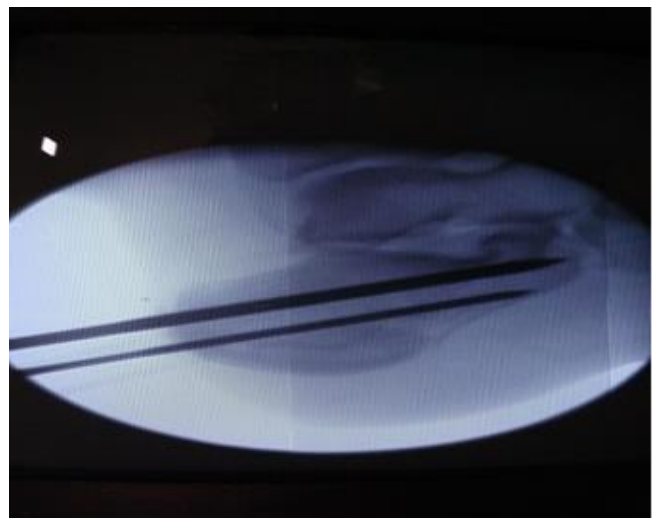
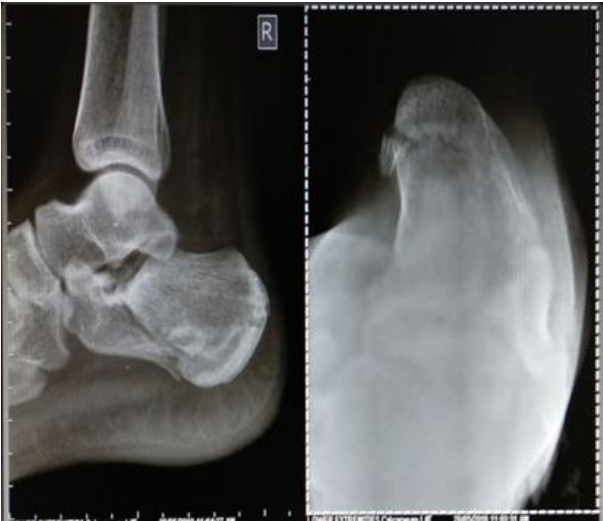
Fig 3: Intraoperative fluroscopic images

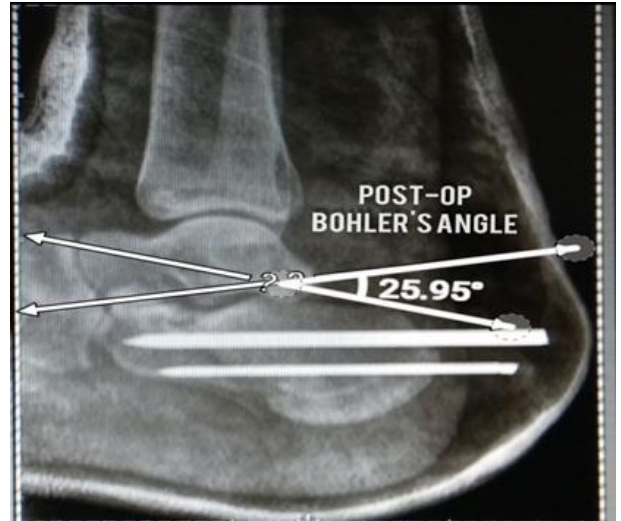
**2.3 Postoperative protocol:** Postoperatively, the affected limb is placed under elevation. Analgesics and other supportive treatment is started. No prophylactic antibiotics were given as part of this study. Toe movements are encouraged and the patient is allowed mobilization with a walker. The follow up is done at every week at which the dressing is changed, pin ends cleaned and the slab is reapplied under supervision. After two weeks, as the pin tracts appear healthy the slab is change to a below knee cast. After eight weeks the radiographs are repeated, and the external pins removed. Partial weight bearing is then started with a walker and the patient is shifted to full weight bearing as bearable over the following weeks. At 3,6 and 12 months follow-up radiographs were obtained to check for loss of the Bohler and Gissane angles. The American orthopedic foot and ankle score (AOFAS) was calculated at the final follow up<sup>[14]</sup>. Also the heel width (with a vernier caliper) and the heel height (from lateral malleolus to the ground surface) were recorded at the final follow-up.

## 2.4 Illustrative case

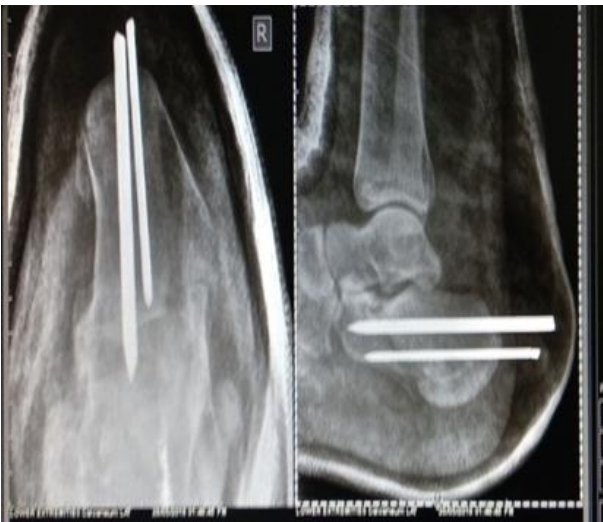A case of twenty-four year old male with trauma to the right foot following a history of fall at place of work. The patient was operated on day 2 following injury. The following images illustrate his radiology.



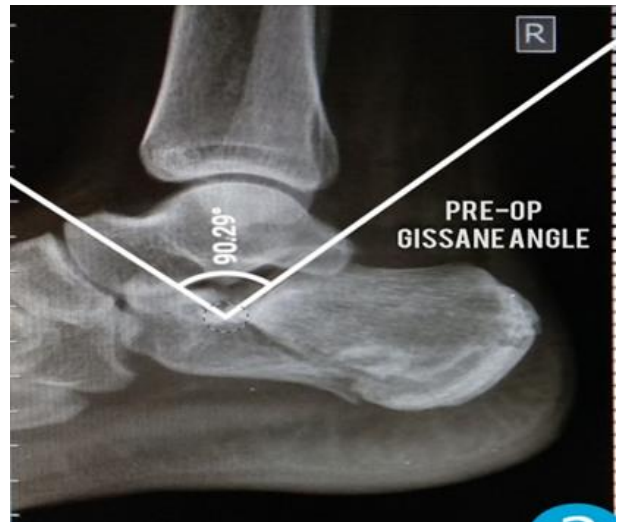
**Fig 4:** Preoperative image



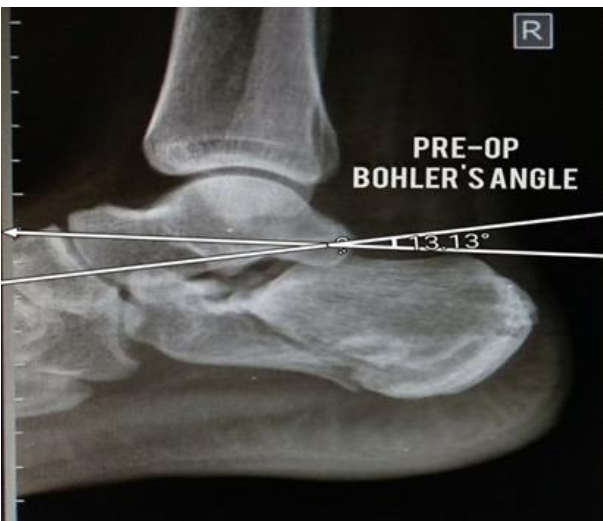**Fig 7:** Postoperative Bohler's angle



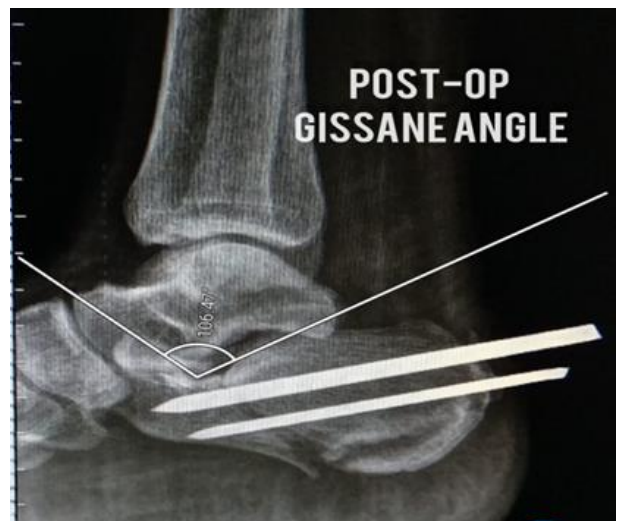**Fig 5:** Postoperative image



**Fig 8:** Preoperative Gissane angle



**Fig 6:** Preoperative Bohler's angle

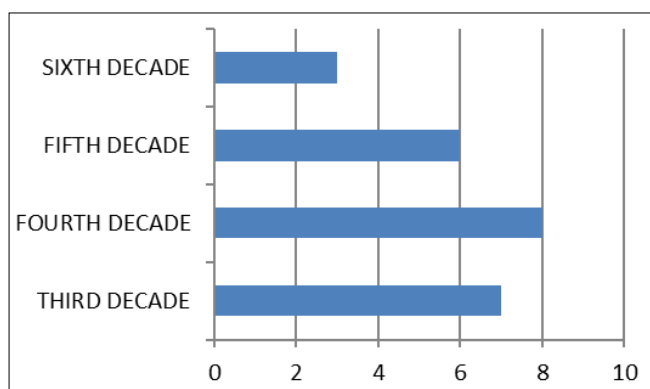


**Fig 9:** Postoperative Gissane angle

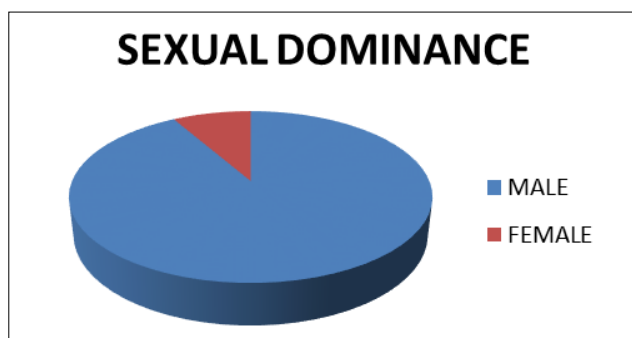
### 3. Results

In this series of 24 patients, 22 were male and 2 were female with average age of 36.2 years old (range 20 to 58). The injury was most common in the third, fourth decades of life with decrease in fifth and sixth decades of life. (Table 1) The most common mechanism of injury was fall from height in 19 patients and 5 patients of vehicular accidents. The average time of admission was from 2- 3 days (range 1-5 days). The average time full weight bearing was at 12 weeks (range from 8 weeks to 13 weeks).

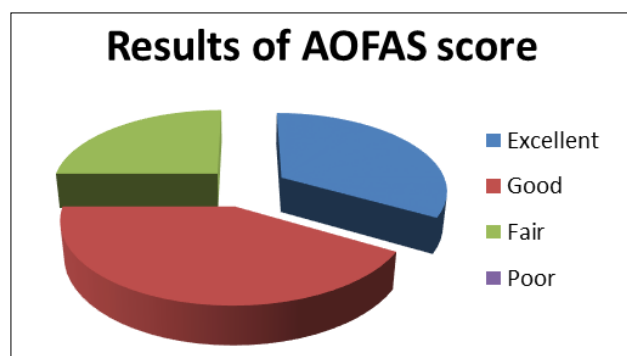
The AOFAS was collected at the one year follow-up following the injury. Of the total patients 8 had excellent, 10 had good and 6 had fair results. None of the patients had heel widening or loss of calcaneal height of more than 1 cm as compared to the contralateral limb. Of the 24 patients, 3 had superficial pin tract infections which were treated with early implant removal, appropriate antibiotics and continued immobilization for an additional two weeks. 3 patients had loss of reduction on follow-up as compared to the immediate postoperative x-rays. The Bohler's angle at follow up was at a mean 30 degrees. All patients achieved union and progressed to full weight bearing.



**Table 1:** Incidence of calcaneal fractures in life Decades.



**Table 2:** Indicating male predominance in fractures of the calcaneum.



**Table 3:** Depicting results of the AOFAS score

### 4. Discussion

The fractures of the calcaneus are high velocity injuries mostly resulting from fall from a height most commonly seen in the third and fourth decades of life. Being high velocity injuries there may be related injuries to the spine. Various authors report this fact occurring in percentages ranging from 8 to 46% of patients [15]. This is probably due to the transmission of forces of impact through the spine. Various studies have reported the same, Buckley (15 percent) and Nambiar *et al.* (21 percent) [5, 16]. In our study 3 out of 24 patients had such associated injuries.

Calcaneal fractures, if inadequately treated, do lead to considerable morbidity to the patient [2, 3]. Conservative or Operative treatment leading to poor calcaneal morphology and development of subtalar arthritis, may lead to persistent functional impairment requiring further treatment, such as subtalar arthrodesis [17]. Accurate intra-articular reduction of the subtalar joint and internal fixation with plate and screws has been advocated and well documented treatment modality of such fractures. A prospective, randomized, controlled multi centre trial of eighty-two patients comparing operative with non-operative treatments of displaced intra-articular calcaneal fractures was carried out. It showed the despite the increased risk of complications in operative treatment, it appeared to have some benefits at eight to twelve years, including a trend towards increased patient-reported primary visual analogue scale (VAS) scores for pain and function and a reduced prevalence of posttraumatic arthritis evident on follow-up radiographs [18].

However it also has been well established that such fractures of calcaneum being high velocity injuries have significant soft tissue trauma. It has been suggested that operative treatment be within three weeks after the injury prior to early consolidation of the fracture [19]. In our study the average time to surgery was 2-3 days which is similar to other such studies. The early percutaneous manipulation helps better closed reduction and also reduction of swelling and related complications. It also offers an alternative approach in patients who have significant medical co-morbidities (smokers, diabetics, and patients with peripheral vascular disease or intolerance to prolonged surgery), in whom open reduction would be hazardous and non-operative treatment would be inadequate [20].

At the same time, the associated wound complications such as plate exposure, skin edge necrosis and deep infections still remain high in open reduction techniques [21]. Stulik *et al.* reported the risk of deep infection and potential limb-threatening complications following open reduction and internal fixation of calcaneal fractures was significant [22]. DeWalt *et al.* described a deep infection rate of 14.3% and a minor wound complication rate of 21.4% in 41 patients treated with open reduction via an extensile lateral approach, with no deep infections and a 6% minor wound complication rate in 79 patients who underwent percutaneous treatment [23]. Despite the presence of advanced surgical techniques and more favourable designs and implant materials, the prevalence of wound complications remains high in open reduction [5]. Tornetta successfully performed percutaneous reduction maneuver suggested by Essex-Lopresti in 41 patients with tongue type IIC calcaneal fractures [11]. Thermann *et al.* advised minimally-invasive fixation for cases with severe soft-tissue contusion, compound and Sanders type-IV fractures, and in multiply-injured patients [24]. The AOFAS score collected showed that 8 had excellent, 10 had good and 6 had fair results. None of the patients had heel

widening or loss of calcaneal height of more than 1 cm as compared to the contralateral limb. Early complications noted were superficial infections in 3 patients and late complications were loss of reduction in 3 patients. However none of them required revision surgeries. Levine and Helfet, in their series of intra-articular fractures of the calcaneum treated with a minimally-invasive technique, were surprised that subtalar movement was almost completely preserved despite the articular surface reconstruction described as 'nearly anatomical'<sup>[25]</sup>.

Paley concluded that a Bohler's angle of 20 degrees and above co-related with good functional outcomes<sup>[26]</sup>. Buckley evaluated that the Bohler's angle improved with surgical treatment and as well the functional status. Treatment improved angle graduation as well as the functional status<sup>[5]</sup>. In this study, variations between 10 and 40 degree were found. The value of this angle showed a correlation with the quality of outcome. The mean Bohler's angle in our study was at 30 degrees and had good correlation with the functional outcomes of the patient.

## 5. Conclusions

Open reduction and internal fixation of the fractures of calcaneum require considerable expertise, have associated wound complications and the learning curve is rather steep. Percutaneous reduction and fixation to achieve essential radiological parameters such as Bohler's angle and Gissane angle helps achieve good functional results. However in patients where adequate fracture and articular reduction could not be achieved and maintained by closed methods, open reduction is warranted.

## 6. References

1. Fitzgibbons TC, McMullen ST, Mormino MA. Fractures and dislocations of the calcaneus. In: Bucholz RW, Heckman JD, editros. Rockwood and Green's Fractures in Adults. 5<sup>th</sup> ed., Philadelphia: Lippincott Williams & Wilkins. 2001; 3:2133-79.
2. Pendse A, Daveswar RN, Bhatt J, Shivkumar. Outcome after open reduction and internal fixation of intraarticular fractures of the calcaneum without the use of bone grafts. Indian J Orthop. 2006; 40:111-4.
3. Raymakers JT, Dekkers GH, Brink PR. Results after operative treatment of intra-articular calcaneal fractures with a minimum follow-up of 2 years. Injury. 1998; 29:593-9.
4. Folk JW, Starr AJ, Early JS. Early wound complications of operative treatment of calcaneus fractures: analysis of 190 fractures. J Orthop trauma. 1999; 13:369-72.
5. Buckley R, Tough S, McCormack R *et al*. Operative compared with nonoperative treatment of displaced intra-articular calcaneal fractures. J Bone Joint Surg [Am]. 2002; 84-A:1733-44.
6. Sanders R. Displaced intra-articular fractures of the calcaneus. J Bone & Joint surg (Am). 2002; 82-A:225-50.
7. Essex-Lopresti P. The mechanism, reduction technique and results in fractures of the os calcis. Clin Orthop. 1993; 290:3-16.
8. Mostafa MF, El-Adl G, Hassanin EY, Abdellatif MS. Surgical treatment of displaced intra-articular calcaneal fracture using a single small lateral approach. Strategies Trauma Limb Reconstr. 2010; 5:87-95.
9. Varela CD, Vaughan TK, Carr JB, Slemmons BK. Fracture blisters: Clinical and pathological aspects. J Orthop Trauma. 1993; 7:417-27.
10. Levine DS, Helfet DL. An introduction to the minimally invasive osteosynthesis of intra-articular calcaneal fractures. Injury. 2001; 32:51-4.
11. Tornetta P III. Percutaneous treatment of calcaneal fractures. Clin Orthop. 2000; 375:91, 6.
12. Rammelt S, Amlang M, Barthel S, Zwipp H. Minimally-invasive treatment of calcaneal fractures. Injury. 2004; 35(2):55-63.
13. Hammond WA, Crist BD. Percutaneous treatment of high-risk patients with intra-articular calcaneus fractures: A case series. Injury. 2013; 44:1483-1485.
14. Kitaoka HB, Alexander IJ, Adelaar RS *et al*. Clinical rating systems for the ankle-hindfoot, midfoot, hallux, and lesser toes. Foot Ankle Int. 1994; 15:349-53.
15. Koberle G, Oliveira AC, Sandoval PS. Fraturas intra-articulares do calcaneo. Rev Bras Ortop. 1996; 31:477-80.
16. Nambiar MR, Umesh SN, Kamath KR. Percutaneous pin fixation of calcaneal fractures. J Orthop Assoc South Ind. 2004; 1:64-7.
17. Radnay CS, Clare MP, Sanders RW. Subtalar fusion after displaced intraarticular calcaneal fractures: does initial operative treatment matter? J Bone Joint Surg Am. 2009; 91:541-6.
18. Agren PH, Wretenberg P, Sayed-Noor AS. Operative versus nonoperative treatment of displaced intra-articular calcaneal fractures. J Bone Joint Surg Am. 2013; 95:1351-7.
19. Kwon JY, Guss D, Lin DE, Abousayed M, Jeng C, Kang S *et al*. Effect of delay to definitive surgical fixation on wound complications in the treatment of closed, intra-articular calcaneus fractures. Foot Ankle Int. 2015; 36:508-17.
20. Zhang T, Su Y, Chen W, Zhang Q, Wu Z, Zhang Y. Displaced intra-articular calcaneal fractures treated in a minimally invasive fashion: longitudinal approach versus sinus tarsi approach. J Bone Joint Surg Am. 2014; 96:302-9.
21. Howard JL, Buckley R, McCormack R, Pate G, Leighton R, Petrie D *et al*. Complications following management of displaced intra-articular calcaneal fractures: a prospective randomized trial comparing open reduction internal fixation with nonoperative management. J Orthop Trauma. 2003; 17:241-9.
22. Stulik J, Stehlik J, Rysavy M, Wozniak A. Minimally-invasive treatment of intraarticular fractures of the calcaneum. J Bone Joint Surg Br. 2006; 88-B:1634-41.
23. DeWall M, Henderson CE, McKinley TO, Phelps T, Dolan L, Marsh JL. Percutaneous reduction and fixation of displaced intra-articular calcaneus fractures. J Orthop Trauma. 2010; 24:466-72.
24. Thermann H, Krettek C, Hüfner T, Schratt HE, Albrecht K, Tscherne H. Management of Calcaneal Fractures in Adults: Conservative Versus Operative Treatment. Clin Orthop Rel Res. 1998; 353:107-24.
25. Levine DS, Helfet DL. An introduction to the minimally invasive osteosynthesis of intra-articular calcaneal fractures. Injury. 2001; 32:51-4.
26. Paley D, Hall H. Intra-articular fractures of the calcaneum: A critical analysis of results and prognostic factors. J Bone Joint Surg. 1993; 75(3):342-54.