



International Journal of Orthopaedics Sciences

E-ISSN: 2395-1958
P-ISSN: 2706-6630
IJOS 2019; 5(4): 635-638
© 2019 IJOS
www.orthopaper.com
Received: 23-08-2019
Accepted: 25-09-2019

Dr. SF Kammar
Professor, Department of
orthopaedics Karnataka institute
of medical Sciences, Hubli
Karnataka, India

Dr. Mahesh MR
Junior Resident, Department of
orthopaedics Karnataka institute
of medical Sciences, Hubli
Karnataka, India

Dr. VK Bhasme
Associate Professor, Department
of orthopaedics Karnataka
institute of medical sciences,
Hubli, Karnataka, India

Dr. Prashanth Kumar
Senior Resident, Department of
Orthopaedics, Karnataka
institute of medical Sciences,
Hubli Karnataka, India

Corresponding Author:
Dr. SF Kammar
Professor, Department of
orthopaedics Karnataka institute
of medical Sciences, Hubli
Karnataka, India

Bipolar hemiarthroplasty in unstable intertrochanteric fractures in elderly: A prospective study

Dr. SF Kammar, Dr. Mahesh MR, Dr. VK Bhasme and Dr. Prashanth Kumar

DOI: <https://doi.org/10.22271/ortho.2019.v5.i4k.1746>

Abstract

Aim of the study: The aim of study is to analyse the functional outcomes of patients with comminuted intertrochanteric fracture treated by primary bipolar hemiarthroplasty and its complications.

Methodology: Thirty patients (17 males and 13 females- all were 60 years old or above) who underwent bipolar hemiarthroplasty for unstable intertrochanteric fractures were prospectively evaluated.

Results: In our study, mean age of the patient was 74.4 yrs, 24 cases were of type 2 fractures, 4 cases were type 3 fracture and 2 cases were type 4 fracture. 11 patients had limb shortening of less than 2 cms, whereas 2 patients had limb shortening of more than 2 cms. 5 patients had abductor weakness. At 12 months follow up in 21 cases (70%), 3 cases (10%) had poor results.

Conclusion: Our study, we concluded that bipolar hemiarthroplasty for unstable intertrochanteric fracture in elderly patients reduce the prolonged immobilisation, deformity, pain and provides better early ambulation and improved quality of life.

Keywords: Intertrochanteric fracture, bipolar hemiarthroplasty, elderly patients, cemented bipolar

Introduction

There is a worldwide increase in the incidence of intertrochanteric fracture among elderly patients. Trochanteric fractures are the most frequent fractures of the proximal femur and occurs predominantly in geriatric patient and are among the most devastating injuries in the elderly. This is due to the increased life expectancy of people and osteoporosis. These patients have a poor bone quality and the fractures are often associated with complications such as non union, metal failure and femoral head perforation. Most of the fractures occur from trivial trauma. Intertrochanteric fracture is defined as the fracture extending from the extra-capsular basilar neck region to region along the lesser trochanter before medullary canal development. Unstable fractures are those with comminution in the posteromedial cortex. Stable trochanteric fractures can be treated with internal fixation with predictable results. The management of unstable osteoporotic fracture is still controversial. Initially, in the past, fixation of unstable fractures with fixed blade plate and enders nail had high rate of cut through and fracture displacement. Subsequently sliding hip screw was used with much success and become the predominant method of fixation of these fractures. However, even with this device, early full weight bearing mobilisation of unstable osteoporotic fracture can result in rotational deformity and limb length shortening, due to uncontrolled telescoping, metal fracture, screw cut out through head. Early weight bearing following internal fixation of comminuted trochanteric fractures by various means in physiologically elderly and osteoporotic patients lead to fixation failure and poor results. Hence period of restricted mobilisation is suggested for this patient [6], which may cause complications like atelectasis, bed sores, pneumonia, deep vein thrombosis etc.

At present intramedullary interlocking devices shows better results in fixing unstable fractures. However long term outcome of these device is yet to be defined. Recently endoprosthetic replacements have shown to achieve early mobilisation of the patient and good long-term results. Although further prospective randomized trials are required before reaching to conclusion. Hence an ideal treatment method for unstable intertrochanteric fracture is still controversial. This study evaluates the role of primary hemiarthroplasty in treatment of

unstable intertrochanteric fracture in the elderly and physiologically elderly patients.

Materials and Methods

30 elderly and physiologically elderly patients with comminuted trochanteric fractures who met the inclusion criteria were studied prospectively in the Department of Orthopaedics, Kims hubli, Karnataka during the period from December 2016 to march 2018

Selection criteria

Inclusion criteria

1. Patient above 60 years of age.
2. Elderly patients with non united trochanteric fractures
3. Patients with trochanteric fractures treated by internal fixation which has gone for failure.

Exclusion criteria

1. Patient less than 60years.
2. Polytrauma patients.
3. Compound intertrochanteric fracture.

Patient 's average age was 74.4yrs [60-90yrs]. Both male and female patients were included in the study. 17 patients were male, 13 patients were female. All the patients had sustained fracture following a trivial trauma. 14 patients had left sided fracture. 16 patients had right sided fracture.

Fractures were classified under Boyd and Griffin classification. 24 patients had sustained Boyd & Griffin Type II intertrochanteric fracture, 4 patients had sustained Boyd & Griffin Type III intertrochanteric fracture and 2 patients had Boyd and Griffin Type IV intertrochanteric fracture. The mean number of days from sustaining fracture to surgery was 15 days. All the patients were treated with cemented bipolar prosthesis through posterior (Moore's) approach

Preoperative evaluation

After patient's admission detailed history regarding mode of injury, associated co-morbid condition was taken. Clinical assessment of the patients were done in detail. All patients were treated preoperatively with high tibia skeletal traction, with the aim of relieving pain preventing shortening and to reduce unnecessary movement of injured limb. Oral or parental NSAIDs were given to relieve the pain.

The following investigations were done routinely on all these patients preoperatively.

Blood investigations includes Haemoglobin %, blood grouping and Cross matching, fasting and Post prandial blood sugar, blood urea and Serum creatinine.

Radiograph

- Pelvis with both hips-AP
- Injured Hip with femur-AP (Traction and internal rotation view)
- Chest X ray PA view.

Pre-operative templating

Pre-operative templating of radiographs of the fractured side and contralateral side was performed to determine the approximate size and position of the stem and the approximate femoral neck offset.

The patients were operated on elective basis after overcoming the avoidable anaesthetic risks. Patients as well as the attenders were explained about the surgery and the risk factors; a written consent for the surgery was taken for all patients.

Approach: Moore's approach

Post-operative protocol

Post operatively Patients were made to sit up on the second day, stand up with support (walker) on the third day and were allowed to full weight bear and walk with the help of a walker on the fourth postoperative day, depending on his/her pain tolerance and were encouraged to walk thereafter. Sitting cross-legged and squatting were not allowed. Suture removal was done on the 12th postoperative day. Patients were followed up at an interval of 6 weeks, 3 months, 6 months and 12 months.

Patient was analysed clinically and Radiologically at each follow up. Radiologically the patient was assessed for position of stem, stem loosening, periprosthetic fracture.

Results

The following observations were made from the data collected during the study of 30 cases of intertrochanteric fractures treated by cemented bipolar hemiarthroplasty in the Department of Orthopaedics, KIMS, HUBLI hospital from December 2016 to march 2018 Out of 30 patients, 3 patients died within 8 months of surgery. Other 17 patients were followed up at 6 weeks, 3 month, 6 months and 12 months post operatively.

The most common associated comorbid medical problem was hypertension in 10 patients followed by type II diabetes mellitus in 9 patients. The mean time from injury to surgery was 12 days. All the cases were treated with cemented bipolar prosthesis. Tension band wiring of greater trochanter was done in 3 cases to hold the fragments together. Calcar reconstruction using cement was done in 15 cases. Intra operatively average volume of blood loss was 354.5 ml, mean operative time was 80.4mins 48secs. There was no hypotension following application of bone cement into femoral canal. Pre-operatively 5 patients (25%) had blood transfusion and post operatively 13 patients (65%) had blood transfusion, which were uneventful. The mean day of full weight bearing was on the 6th post operative day (chart 4). Postoperatively two patients had superficial infection which was treated with I.V. antibiotics (chart 8).

13 patients had shortening of the operated limb, of which 11 had less than 2cms, so they were given a heel raise. They walked with the help of a cane, 1 patient had shortening more than 2 cm, he had a slight limp (chart 6 & 9). 5 patients (25%) had abductor weakness at 12 months of following.

The mean number of days spent by the patient in the hospital in the postoperative period was 12 days. At the end of 12 months 4 patients walked without any support, 11 patients walked with the help of a cane, 4 patients complained of occasional anterior thigh pain on long distance walking, which was relieved on taking rest and analgesics, 3 patients died due to unrelated causes. There was no incidence of deep vein thrombosis, pneumonia, pressure sores or cardiovascular complication in the early post operative period.

Functional outcome analysis

The functional results were graded according to Harris Hip Scoring System. In our study, 7 patients had excellent results, 6 patients had good results, 11 patients had fair results, 3 cases had poor result. In our study, 15 cases (70%) had excellent to fair result as assessed by modified Harris hip score.

Radiological analysis

Bipolar Stem was fitted in valgus position in 3 cases, varus position in 2 patient, whereas the position of the stem was

centre (normal) in 25 patients. Cement filling was adequate in 22 cases, whereas it is inadequate in 4 cases. There was no prosthetic dislocation, stem loosening, acetabular erosion or periprosthetic fracture after a period of 12 months follow up in our series

Discussion

Internal fixation with dynamic hip screw is the treatment of choice for stable intertrochanteric fracture. However the scenario is different when comes to the management of unstable fracture. Failure rate of as high as 56% have been noted with internal fixation of unstable fractures. Early weight bearing following internal fixation of comminuted trochanteric fractures by various means in physiologically elderly and osteoporotic patients leads to fixation failure and poor results [6]. Hemiarthroplasty is a frequently employed alternative as it gives stability and allows early full weight bearing. Most of the complications associated with internal fixation are avoided with the use of prosthetic replacement. Initially hemiarthroplasty is used only in the treatment of failed fixation of Intertrochanteric fractures. In 1974 Tronzo⁹, was the first surgeon to use long- stem Matchett Brown endoprosthesis for the primary treatment of intertrochanteric fractures. Following this many other surgeons also reported good results with the use of various prosthesis. Pho. *et al.* [10], achieved good results with use of Thompson prosthesis.

Conclusion

In this study primary hemiarthroplasty, was performed for intertrochanteric fractures in 30 elderly patients of more than 60 years, in our hospital KIMS Hubli, Karnataka.

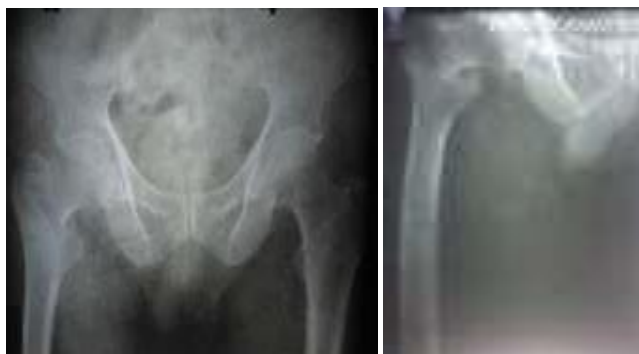This procedure offered excellent pain free mobile hip, with early mobilisation, easy rehabilitation and early return to functional level, when standard techniques were used.

The potential of the bipolar prosthesis in varied indications, shows its versatility. This speaks for the superiority of the procedure.

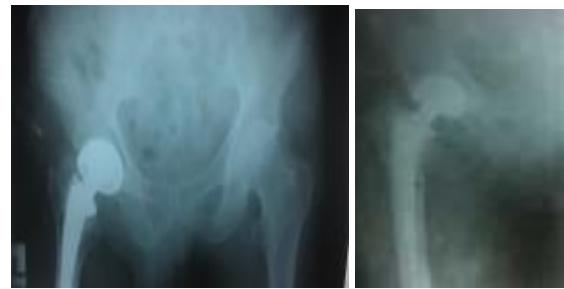
Bipolar hemiarthroplasty reduced the complications of prolonged immobilisation, prolonged rehabilitation, marked residual deformities and need for revision surgeries. The procedure offered, faster mobilization, rapid return to pre injury level, improved the quality of life and gave a long term solution in elderly patients with intertrochanteric fractures of the femur.

Case Illustration

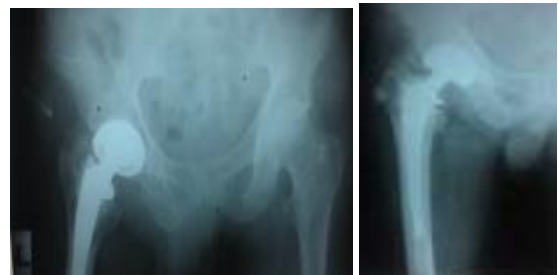
Case 1: Type Ii Boyd & Griffin Intertrochanteric Fracture



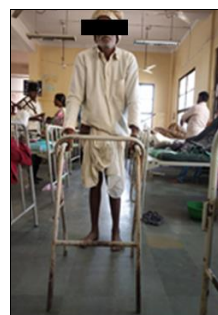Preoperative Radiograph



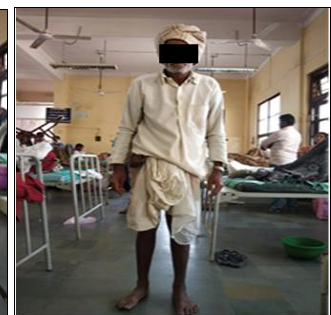Immediate Post-Operative Radiograph



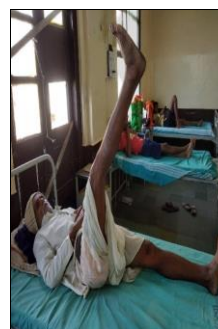After 1 Year Follow Up:



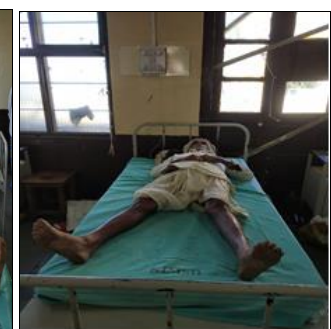Immediate Post Op



Full Weight Bearing



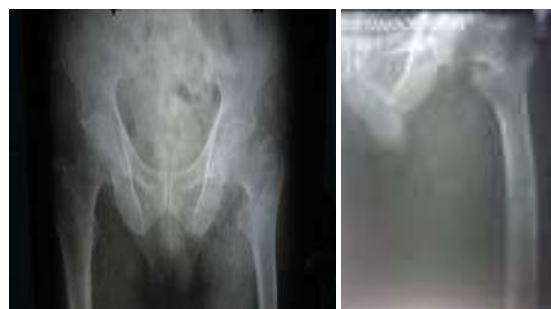Flexion



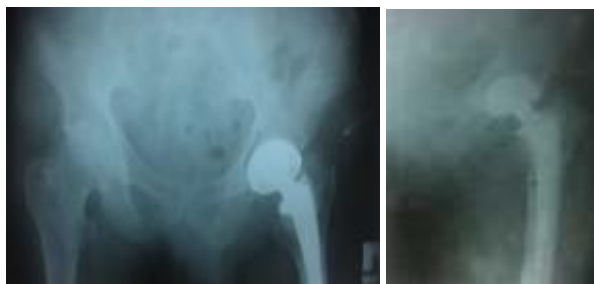Abduction

Case Illustration

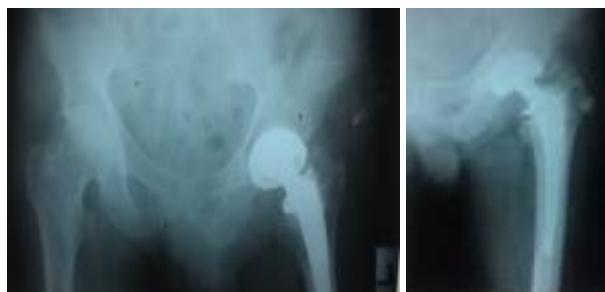Case 2: Type Ii Boyd & Griffin Intertrochanteric Fracture:



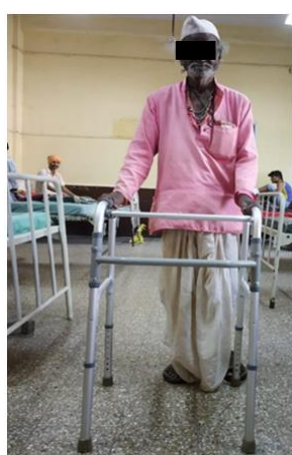Preoperative Radiograph



Immediate Post-Operative Radiograph



After 1 Yar Follow Up



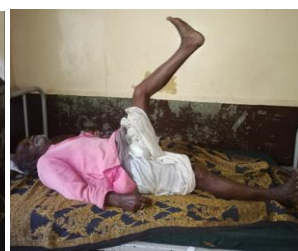Immediate Post Op



Full Weight Bearing



Abduction



Flexion

51:949-962.

6. Wolfgang GL, Bryant HH, O'Neill JP. Treatment of intertrochanteric fractures of the femur using sliding screw plate fixation. Clin Orthop. 1982; 163:148-158.
7. Suriyajakyuthana W. Intertrochanteric fractures of femur: Results of treatment with 95 degrees condylar blade plate. J Med Assoc Thai. 2004; 87:1431-1438.
8. Kyle RF, Gustilo RB, Premer RF. Analysis of six hundred and twenty two intertrochanteric hip fractures. J Bone Joint Surg Am. 1979; 61:216-221.
9. Tronzo RG. The use of an endoprosthesis for severely comminuted intertrochanteric fractures. Orthop Clin North Am. 1974; 5:679-681.
10. Pho RW, Nather A, Tong GO, Korku CT. Endoprosthetic replacement of unstable, comminuted intertrochanteric fracture of the femur in the elderly. J Trauma. 1981; 21:792-797.

Reference

1. Kannus P, Parkkari J, Sievanen H, Heinonen A, Vuori I, Jarvinen M. Epidemiology of hip fractures. Bone. 1996; 18:57S-63S.
2. Koval KJ, Zuckerman JD. Hip fractures are an increasingly public health problem. Clin Orthop Relat Res. 1998; 348:2.
3. Rockwood PR, Horne JG, Cryer C. Hip fractures: A future epidemic? J Orthop Trauma. 1990; 4:388-393.
4. Laros GS, Moore JF. Complications of fixation in intertrochanteric fractures, Clin. Orthop. 1994; 101:110.
5. Jensen J Steen, Tondevold E, Sonne-Holm. Unstable trochanteric fractures. A comparative analysis of four methods of internal fixation. Actaorthop. Sand. 1980;