



International Journal of Orthopaedics Sciences

E-ISSN: 2395-1958
P-ISSN: 2706-6630
IJOS 2019; 5(4): 623-628
© 2019 IJOS
www.orthopaper.com
Received: 15-08-2019
Accepted: 19-09-2019

Dr. Ruka Balaji Obula Reddy
Assistant Professor, Department
of Orthopaedics, Shanthiram
Medical College and General
Hospital Nandyal, Kurnool
Andhra Pradesh, India

Dr. Shaik Mannan
Post Graduate, Department of
Orthopaedics, Shanthiram
Medical College and General
Hospital Nandyal, Kurnool
Andhra Pradesh, India

A prospective and comparative study of Cephalomedullary nailing over dynamic Hip screw in the management of intertrochanteric fracture

Dr. Ruka Balaji Obula Reddy and Dr. Shaik Mannan

DOI: <https://doi.org/10.22271/ortho.2019.v5.i4k.1743>

Abstract

Introduction: Intertrochanteric fracture is a leading cause of hospital admissions in elderly people. Conservative methods of treatment results in malunion with shortening and limitation of hip movement as well as complications of prolonged immobilization like bed sores, deep vein thrombosis and respiratory infections.

Aims: To compare the results of surgical management of intertrochanteric fractures with Proximal Femoral Nail and Dynamic Hip Screw.

Results: Out of 60 patients, there were 33 female and 27 male. Age group between 20-80. Most of the people were between 40-80 years. Slip and fall accounted for 70% of cases. Right side was more common, accounted for 56.66% of cases. Boyd and Griffin type II fracture accounted for 53.3% of cases. Mean duration of hospital stay was 26 days in both PFN and DHS groups. Mean time of full weight bearing was 10.6 weeks for PFN group and 14.8 weeks for DHS group. Out of 60 cases 4 cases died. Good to excellent results were seen in 76.43% of cases in PFN group and 58.57% in DHS group.

Conclusion: We consider PFN as better alternative to DHS in the treatment of intertrochanteric fractures but is technically difficult procedure and requires more expertise compared to DHS. With experience gained from each case operative time, radiation exposure, blood loss and intraoperative complications can be reduced in case of PFN.

Keywords: Cephalomedullary nailing, dynamic Hip screw, intertrochanteric fracture

Introduction

Intertrochanteric fractures are commonly seen in elderly patients over the age of 70yrs. Incidence of these fractures has increased primarily due to increasing life span and more sedentary life style brought about by urbanization. In younger patients IT fractures occur due to high velocity trauma, where as in older patients it is due to trivial trauma. Incidence of Intertrochanteric fractures is common in females than in males, due to senile osteoporosis sets in female early. Intertrochanteric fractures can be managed by Conservative (or) Operative methods [1, 2]. Conservative methods resulted in higher mortality rates ranging between 15-20%, and also complications like, decubitus ulcers, urinary tract infections, pneumonia, Thrombo-embolic complications. The conservative methods are only indicated under conditions as age related chronic medical conditions unfit for surgery and Non-ambulatory patients before sustaining fracture. Early surgery is indicated to reduce the mortality and morbidity in elderly patients and to reduce the high cost care of patients, to bring him to functional recovery. This is only possible by early ambulation of injured & sick patients by minimally invasive surgical procedures [3, 4]. The exceedingly practiced and time tested surgical procedures for IT fractures are Extra-medullary (Eg: Sliding hip screw with Barrel Plate (DHS and its variants) and Intramedullary nailing procedure (Eg: PFN/TAN (Trochanteric antigrade nail). PFN with antirotation hip screw, DHS with side plate assembly is the most commonly used device, for fixation of intertrochanteric fractures. It is a no collapsible fixation device, which permits the proximal fragment to collapse or settle on fixation device seeking its own position of stability. The latest implant for management of I.T fractures is PFN. This implant is cephalomedullary and has potential advantages like, being intramedullary, load transfer is more efficient, shorter lever arm results in less transfer of stress and less chances of implant

Corresponding Author:
Dr. Shaik Mannan
Post Graduate, Department of
Orthopaedics, Shanthiram
Medical College and General
Hospital Nandyal, Kurnool
Andhra Pradesh, India

failure, Advantages of controlled impaction is maintained, the amount of sliding is limited by intramedullary location, therefore less chances of Shortening and deformity and Shorter Operative time, less soft tissue dissection and less blood loss. In view of these conditions, this study has been taken up to compare the results of DHS and PFN in treatment of I.T fractures.

Materials and Methods

The present study consists of 60 patients with intertrochanteric fractures of femur admitted to orthopaedic wards PESIMSR Hospital Kuppam, Chittoor (dt) during the period extending from JUNE 2009 to JUNE 2011. The study sample size is 60 patients between 20-80yrs with all the pre-operative variables, like age, sex, type of trauma, associated chronic medical conditions. We have selected these two groups; based on Preoperative variables like age, sex, mechanism of injury and radio graphically type of fracture and fracture geometry. Inclusion criteria: aged from above 20-80yrs with intertrochanteric fractures of femur. Exclusion criteria: Pathological fractures, Old fractures, Open fractures, Patients associated with poly trauma, Patients lost in follow-up. All the patients were subjected to pre-operative assessment for anaesthetic risk, medical management and preferable timing for surgical management. The surgical options selected for this study are

D.H.S (Sliding Hip Screw) - 30 cases

P.F.N (Intra-medullary device) -30 cases

Standard surgical techniques were selected separately for Group-A & Group-B. These techniques selected are on economical side of patient, benefitting the patients & their relatives as far as possible, we selected Indian made nails & sliding screw devices. Regular and periodic follow up done with respect to clinical and radiological union of fracture, recognition of post-surgical failures, also functional recovery recorded. The above findings were entered into standard Proforma. After the patient with intertrochanteric fracture was admitted to hospital all the necessary clinical details were recorded in Proforma prepared for this study. After the completion of the hospital treatment patients were discharged and called for follow up at outpatient level, at regular intervals for serial clinical and radiological evaluation. As soon as the patient with suspected intertrochanteric fracture was seen, necessary clinical and radiological evaluation was done and admitted to ward after necessary resuscitation and splintage with skeletal traction. All basic investigations were done routinely on all these patients preoperatively. In Urine Albumin, Sugar, Microscopic examination. Cardiac assessment done with ECG&ECHO, Pelvis with both hips AP view and Chest X ray PA view in all the patients to rule out any chest lesions. All the patients were evaluated for associated medical problems and were referred to respective department and treated accordingly. Preanaesthetic evaluation is to be done. Associated injuries were evaluated and treated simultaneously. The patients were operated on elective basis after overcoming the avoidable anaesthetic risks preferably after 2-5 days of trauma.

Dynamic hip screw technique

Length of Richard's screw is measured from tip of the head to the base of greater trochanter on AP view x ray subtracting magnification. Neck shaft angle is determined using goniometer on X- ray AP view on unaffected side. Length of

the side plate is determined to allow purchase of at least 8 cortices to the shaft distal to the fracture. The implant consists of lag screw, a compression screw barrel attached to the side plate. The lag screw is available in length from 60-110mm. 19mm compression screw allows a compression of 5mm. Barrel side plate available in angles of 125,130, 135, 140 degrees and from 2-12 holes. The key and slot mechanism of the implant prevents rotational movements of the proximal fragments. 4.5mm cortical screws are used to fix the side plate with shaft. Most proximal hole in the side plate allows insertion of 6.5 mm cancellous screw which can be used for fixation of lesser trochanter or a larger posteromedial fragment. In our study we used lag screw of 60-110mm and a side plate that allowed a purchase of atleast 8 cortices with shaft of femur and 125-135 degrees angled plate depending upon the neck shaft angle determined preoperatively. A minimum of 4 cortical screws were used to fix the side plate with the shaft.

Proximal femoral nail operative technique

The patient is placed in supine position on fracture table with adduction of the affected limb by 10-15 degrees and closed reduction of the fracture was done by the traction and internal rotation. The unaffected leg is flexed and abducted as far as possible or kept in wide abduction. The image intensifier was positioned so that anterior-posterior and lateral views of hip and femur could be taken. Open reduction is performed if closed reduction failed. The patient is then prepared and draped as for any standard hip fracture fixation. Prophylactic antibiotic is given in all patients 30 mins before surgery. The tip of greater trochanter was located by palpation in thin patients and in obese patients, we used image intensifier. 5cms longitudinal incision was taken proximal from the tip of the greater trochanter. A parallel incision was made in fascia lata and gluteus medius was split in line with the fibers. Tip of greater trochanter is exposed. In AP view on c-arm, the entry point is on tip or slightly lateral to the tip of greater trochanter. In lateral view, guide wire position is confirmed in the center of the medullary cavity. Medullary canal entered with a curved bone awl, the guide wire is inserted into the medullary canal. Using a cannulated conical reamer the proximal femur is reamed for a distance of about 7cms. After confirming satisfactory fracture reduction, an appropriate size nail as determined preoperatively is assembled to insertion handle and inserted manually. This step is done carefully without hammering by slight twisting movements of the hand until the hole for 8mm screw is at the level of inferior margin of the neck. Open reduction is performed in case satisfactory reduction is not possible by closed means. These are inserted with the help of aiming device lightly screwed to the insertion handle. A 2.8 mm guide wire is inserted through the drill sleeve after a stab incision. This guide wire is inserted 5mm deeper than the planned screw size. The final position of the guide wire should be in the lower half of the neck in AP view and in the centre of the neck in lateral view. A second 2.8 mm guide wire is inserted through the drill sleeve above the first one for hip pin. The tip of this guide wire should be approximately 25-20mm less deep than the planned neck screw. Drilling is done over 2.8mm guide wire until the drill is 8mm short of tip of the guide wire. Tapping is not done as neck screw is self-tapping. Neck screw is inserted using cingulated screw drive. Similarly appropriate length hip pin is inserted. Length and position of the screw is confirmed with c-arm image. Distal locking is usually performed with two cortical screws. A drill sleeve system is inserted through a

stab incision. A drill hole is made with 4mm drill bit through both cortices. Locking screw is inserted and position confirmed with image intensifier. After fixation is over, lavage is given using normal saline and incision is closed in layers. Suction drain is used in case open reduction is performed. Sterile dressing applied over wound and compression bandage applied. Postoperatively, patient's pulse, blood pressure, respiration and temperature were monitored. Antibiotics were continued in postoperative period through I.V for 5days and orally for 5days. Analgesics were given as per patients' compliance. Blood transfusion was given depending on the requirement. Suture removed on the 10th post-operative day. Patients were encouraged to sit in the bed after 24 hrs following surgery. Patients were taught Quadriceps static exercise and knee mobilization in immediate postoperative period. Patients were taught gait training before discharge from hospital. They were allowed to walk on well leg with walker (Non weight bearing) before

discharge. Only in very unstable fractures and comminuted fracture pattern, weight bearing was delayed till union progresses. All patients were followed up at an interval of 2 weeks until fracture union, at 12 weeks and at 6 months postoperatively. At each visit, patient was assessed clinically regarding hip and knee function, walking ability, fracture union, deformity and shortening. X ray of the pelvis with both hips was taken to assess fracture union and implant bone interaction. Anatomical and Functional Results assessed based following scoring system adopted.

Table 1: Anatomical Results assessment

Anatomical Results	Good	Fair
Shortening	<1cm	>1cm
Varus deformity	Absent	Present
Hip movements	Full range	Restricted
Knee movements	Full range	Restricted

Table 2: Functional result assessment

Hip pain	Scoring
No pain	2 points
Occasional pain	1 point
Constant pain	0 point
Ambulatory status	
Walking without aid	2 points
Walking with aid	1 point
Not able to walk	0 point
Ability to squat	
Able to squat	1 point
Unable to squat	0 point
Sitting crossed legged	
Able to sit	1 point
Unable to sit	0 point
Interpretation	
Excellent	6 points
Good	4-6 points
Fair	2-4 points
Poor	<2 points

Results

The following observations were made from the data collected during the study of 60 cases of intertrochanteric

fractures treated by proximal femoral nail and DHS. In our study we selected patients between 20 – 80yrs of age.

Table 3: Demographic details in study

Variables	Number of patients		Percent		P-value
Age Group	PFN	DHS	PFN	DHS	
0-20	0	0	0.00	0.00	
21-40	3	4	10.00	13.33	
41-60	11	12	36.67	40.00	0.72
61-80	16	14	53.33	46.67	
81-100	0	0	0.00	0.00	
Gender					
Male	14	13	46.67	43.33	0.79
Female	16	17	53.33	56.67	
Nature of violence					
slip and fall	22	20	73.33	66.67	0.84
fall from height	3	4	10.00	13.33	
road accident	5	6	16.67	20.00	
Side affected					
Right	18	16	60.00	53.33	0.62
Left	12	14	40.00	46.67	
Type of fracture					
Type I	10	8	33.33	26.67	0.57
Type II	14	18	46.67	60.00	
Type III	6	4	20.00	13.33	
Type IV	0	0	0.00	0.00	

Age distribution indicated that the two groups had no significant differences between them at 5% showing that the groups are comparable. Sex difference between the groups showed a P-value of 0.795 with chi-squared value of 0.067 and chi-squared table value of 3.841. This again showed that there were no significant differences in sex distribution of cases in either group to significantly affect comparison. Nature of violence was tested which gave a P-value of 0.848 with chi-squared value of 0.329 and chi-squared table value of 5.991. This showed that the two groups are comparable. Side affected was again tested for any difference between the two groups. It also showed that the two are comparable with no significant differences between the groups. P-value was 0.602 with chi-squared value of 1.01 and chi-squared table value of 3.841. Distribution of the type of fracture within the two groups showed no significant differences between the groups. P-value – 0.571, chi-squared value – 1.122 and chi-squared table value – 5.991.

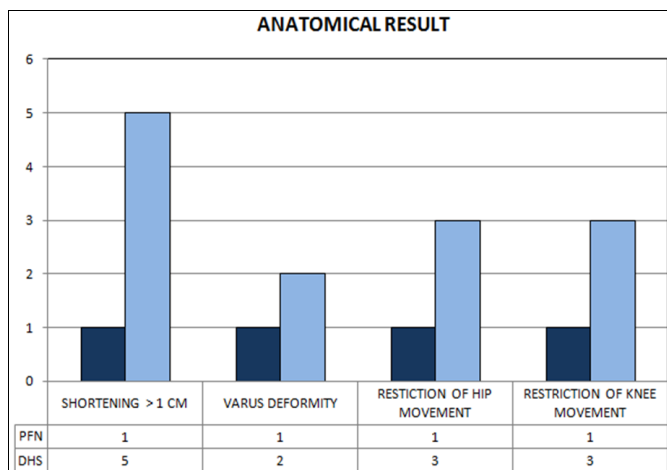
Table 4: Intraoperative details

Intraoperative Details		
	PFN	DHS
Mean Radiographic Exposure (times)	60	40
Mean Duration Of Operation (Min.)	90	80
Mean Blood Loss (In ml.)	230	320

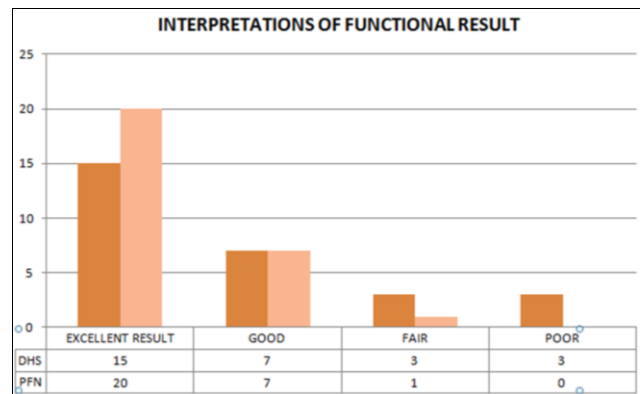
Table 5: Intraoperative complications of PFN and DHS

Intraoperative complications of PFN	Number of cases	Percentage
Failure to achieve closed reduction	4	40
Fracture of lateral cortex	1	10
Fracture displacement by nail insertion	3	30
Failure to put derotation screw	2	20
Failure to lock distally	0	0
Jamming of nail	0	0
Drill bit breakage	0	0
Total	10	100%
Intraoperative Complication DHS		
Improper positioning of Richard screw	3	50
Varus angulation	3	50
Drill bit breakage	0	
Total	6	100%

Small sample analysis of PFN complication had a chi-squared value of 0.115136 with lower limit of 9.6% and a upper limit of 55%.



P-value = 0.008906, chi-statistic = 6.841629, Chi-square table value = 3.841459 Odds ratio = 5.2 (at 95% CI 1.427 to 18.9489)

Fig 1: Anatomical Results

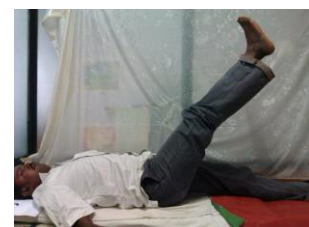P-value = 0.117319, chi squared stat = 5.885433, chi-square table value = 5.991465

Fig 2: Functional Results

To calculate the Odds ratio of the two methods, they were analysed as excellent and less than excellent. Above statistical tests showed that the two groups taken up for the study were comparable with no significant difference between the two samples.

Results show a significant difference between the two methods in the anatomical result. P-value = 0.008906 with Odds ratio of 5.2 (at 95% CI 1.427 – 18.9489). Since only 4 anatomical deformities were noted in the PFN group, small sample test was performed which showed probability of 0.1. Functional results of the two methods was not significantly different. P-value = 0.117, chi-squared stat = 5.885 with chi-squared table value = 5.991.

Finally, the two techniques were compared for excellent and less than excellent result which showed An Odds ratio of 2.1666 (at 95% CI 0.7167 – 6.5502).



Active straight leg rising

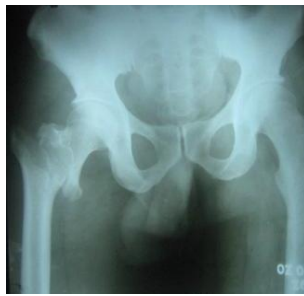

Sitting cross legged

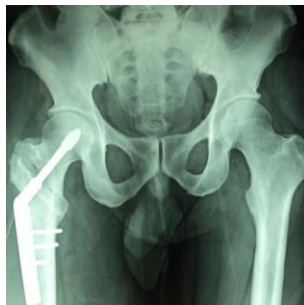

Squatting

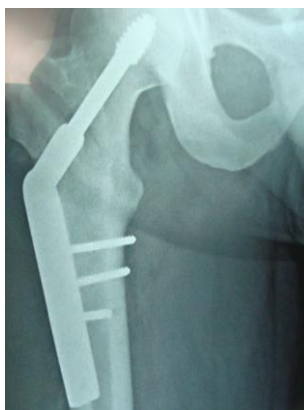Fig 3: Follow-up case of DHS



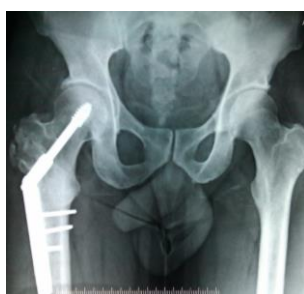Pre-operative x-ray



Immediate post-operative x-ray



6 weeks follow-up x-ray



6 months follow-up x-ray

Fig 4: Follow-up X-ray of a case of DHS

Discussion

The management of I.T fractures is still associated with many failures. The reason being attributed to, biomechanics of fracture and surgical technique variables. Due to high stress concentration that is subjecting to multiple deforming forces. For many years, research is going on to find out an ideal implant device for the fixation of I.T fractures; which are more common in elderly patients. But still an ideal implant has not yet being evolved. The development of sliding hip screw with a barrel plate is quite simple and biomechanically stable for fixation of I.T fractures.

Subsequently various intramedullary devices developed based on studying the fracture pattern, fracture geometry and for elderly which can offer stable fixation, less soft tissue

dissection, less blood loss and to minimise post-operative complications aiming at early ambulation.

Many of these devices starting from Enders pin, Gamma nail and its modified versions met with more failures and different learning curves. Further, various intramedullary devices are being developed according to the fracture geometry and patient variables. Thus the popular saying “The old begets the new” leading to the development of PFN (ex: TAN nail by AO GROUP).

In this endeavour we have made an attempt to compare the management of trochanteric # with the use of 1) sliding hip screw and 2) intramedullary nail device. We have grouped these fractures into 2 comprising 30 patients each; which were admitted to the orthopaedic wards.

Menez and Daneil conducted a study on 155 cases of intertrochanteric fractures treated with PFN, and found 2% failure of fixation and 0.7% of femur shaft fractures. However no such complications was reported in our study [5]. In a study, by Pajarein and Lindal, of 108 patients of per trochanteric fractures treated with DHS and PFN, found PFN allowed faster restoration of post-operative walking ability when compared with DHS [6]. In our study mean time for full weight bearing for DHS was 14.8 weeks while that for PFN was 10.6 weeks. 18 out of 30 patients treated with PFN had indecent mobility while 12 out of 30 patients of DHS had independent mobility. A study of 20 patients of unstable intertrochanteric fractures treated with PFN and DHS by Bhatti and Arshad, was conducted in 2004. They found duration of stay for PFN and DHS were 14 and 22 days, blood loss was 275 and 475ml, persistent hip pain was seen in 3% and 9% respectively. This correlated with our study where the duration of hospital stay was 26 days in both cases, average blood loss was 230ml and 320 ml, persistent hip pain was seen in 1/30 and 3/30 cases of PFN and DHS respectively [7]. Kuzyk, Paul Bhandari, Mohit there is grade B evidence that operative time is reduced and that fixation failure is reduced with the use of intramedullary implants for sub trochanteric fractures [8]. The skin-to-skin operative time of the procedure was significantly less with the intramedullary hip screw (46 minutes) compared to the compression hip screw (99 minutes). Estimated blood loss was also significantly less for the intramedullary hip screw group (144 cc) than for the compression hip screw group (290 cc). In our study duration of operation was 90 and 80min, mean blood loss was 230 and 320ml for PFN and DHS. In our study, intertrochanteric fracture was common due to slip and fall in the age ranged between 20-80 years. Females were common contributing to 55%. Right sided fractures were common accounting for 56.66% which are comparable with other authors. In our study, Type II Boyd and Griffin fractures were common, consisted of 53.3%. Type I and Type III were 30% and 16.6% respectively. Mean frequency of radiation exposure were 70 and 40 times, mean duration of operation 90 and 80 minutes, mean blood loss was 230ml and 320 ml for PFN and DHS respectively. Intraoperative 4 cases had to undergo open reduction, penetration of lateral cortex was seen in 1 case, 3 cases fracture got displaced by nail insertion, 2 cases antirotation screw could not be put in PFN group. Among DHS, intraoperatively had fewer complications which included improper placement of the screw in 3 cases, varus angulation in 3 cases. Post operatively no infection in cases of PFN and DHS. Mean duration of hospital stay was 26 days in both cases, mean time of full weight were 10.6 and 14.8 in PFN and DHS. All patients were mobile at the end of 6 weeks with or without walking aid except for one case of PFN. 18/28

and 12/28 cases of PFN and DHS had independent mobility. In our 60 cases, 4 patients died due to associated medical problems. Excellent results were seen in 53.57% and 71.43%, good in 5% and 6%, fair in 10.71% and 3.57%, fair in 10.71% and 0% cases of DHS and PFN respectively.

As reported, there were 46 patients suffered external wall fracture in a group of 214 having DHS internal fixation surgery, with 34 cases (74%) happened during the surgery [9]. so it is proper to choose intramedullary fixation for aged patients with osteoporosis. Intramedullary fixation has a variety of theoretical advantages, such as minimally invasiveness, stable centricity, better mechanical performance, and more prevalent [10, 11]. But all kinds of internal fixation methods and instruments have advantages and disadvantages. Doctors need to have sufficient theoretical foundation and practical ability, and choose their familiar and reliable technology and route according to the characteristics of patients. Also, they should make adequate preparation and individualized treatment scheme in order to achieve the ideal treatment effect [12, 13].

Conclusion

We concluded that I.T fractures are more common in elderly, especially in females in our series. All the patients underwent pre-operative assessment and operated with PFN and DHS. We met with fewer post-operative complications which are comparable with other studies. Functional outcome results in both methods are comparable but the PFN in its latest version has got an edge over the DHS. These benefits of PFN fixation offers stable fixation in elderly and in osteoporotic I.T & S.T.F #'s early ambulation with good functional results. The PFN is based on sound principles of Biological osteosynthesis; but technically the learning curve is steeper than DHS.

References

1. Su S, Liu H. The association between multiple sclerosis and fracture risk. *Int. J Clin Exp. Med.* 2014; 7:4327-4331.
2. Kouzelis A, Kravvas A, Mylonas S, Giannikas D, Panagopoulos A. Double axis Cephalocondylic fixation of stable and unstable intertrochanteric fractures: early results in 60 cases with the Veronail system. *Open Orthop J.* 2014; 8:60-68.
3. Liu C, Kuang L, Wang L, Tian J. Management of combination fractures of the atlas and axis: a report four cases and literature. *Int. J Clin Exp. Med.* 2014; 7:2074-2080.
4. Cheung JP, Chan CF. Cutout of proximal femoral nail antirotation resulting from blocking of the gliding mechanism during fracture collapse. *J Orthop Trauma.* 2011; 25:51-55.
5. Boyd HB, Griffin LL. Classifications and treatment of trochanteric fractures. *Arch Surg.* 1949; 58(6):853-866.
6. Menes Daniel, Gamulin Noesberg. Is proximal femoral nail a suitable implant for treatment of all trochanteric fractures Lipincott, Williams and Wilkins Inc. v October. 2005; 439:21-227.
7. Pajarinen J, Lindahl J, Michelsson O, Savolainen V, Hirvensalo E. Pertrochanteric femoral fractures treated with a dynamic hip screw or a proximal femoral nail A randomised study comparing post-operative rehabilitation B January. 2005; 87(1):76-81.
8. Bhatti Arshad Power, Dominic Qureshi, Sohail Khan, Ishrat Tan, Simon A prospective trial of proximal femoral nail versus dynamic hip screw for unstable and complex intertrochanteric fractures of the femur Supplement. 2004; 86(3):377.
9. Bhandari Mohit, Sprague Sheila, Schemitsch. Resolving Controversies in Hip Fracture Care: The Need for Large Collaborative Trials in Hip Fractures: *Journal of Orthopaedic Trauma.* 2009; 23(6):479-484.
10. Palm H, Jacobsen S, Sonne-Holm S, Gebuhr P. Hip Fracture Study Group. Integrity of the lateral femoral wall in intertrochanteric hip fractures: an important predictor of a reoperation. *J Bone Joint Surg Am.* 2007; 89:470-475.
11. Huang H, Xin J, Ma B. Analysis of complications of intertrochanteric fracture treated with Gamma intramedullary nail. *Int. J Clin Exp. Med.* 2014; 7(3):3687-3693.
12. Radcliff TA, Regan E, Cowper Ripley DC, Hutt E. Increased use of intramedullary nails for intertrochanteric proximal femoral fractures in veterans' affairs hospitals: a comparative effectiveness study. *J Bone Joint Surg Am.* 2012; 94:833-840.
13. Kaplan K, Miyamoto R, Levine BR, Egol KA, Zuckerman JD. Surgical management of hip fractures: an evidence-based review of the literature. II: intertrochanteric fractures. *J Am Acad. Orthop Surg.* 2008; 16:665-673.