



International Journal of Orthopaedics Sciences

E-ISSN: 2395-1958
P-ISSN: 2706-6630
IJOS 2019; 5(4): 537-542
© 2019 IJOS
www.orthopaper.com
Received: 08-08-2019
Accepted: 12-09-2019

Dr. Chandra Mouli G
Assistant Professor,
Department of Orthopaedics,
Dr. Pinnamaneni Siddhartha
Institute of Medical Sciences and
Research Foundation,
Chinnaoutpalli, Gannavaram,
Vijayawada, Andhra Pradesh,
India

Dr. Kopuri Ravi Kiran
Professor, Department of
Orthopaedics, Dr. Pinnamaneni
Siddhartha Institute of Medical
Sciences and Research
Foundation, Chinnaoutpalli,
Gannavaram, Vijayawada,
Andhra Pradesh, India

**Dr. Venkata Suresh Babu
Tummala**
Professor, Department of
Orthopaedics, G.S.L. Medical
College & General Hospital, NH
16, Lakshmi Puram,
Rajamahendravaram,
Andhra Pradesh, India

Corresponding Author:
Dr. Kopuri Ravi Kiran
Professor, Department of
Orthopaedics, Dr. Pinnamaneni
Siddhartha Institute of Medical
Sciences and Research
Foundation, Chinnaoutpalli,
Gannavaram, Vijayawada,
Andhra Pradesh, India

A retrospective study of sub trochanteric fractures of femur managed with dynamic hip screw system and cephalomedullary nail

Dr. Chandra Mouli G, Dr. Kopuri Ravi Kiran, and Dr. Venkata Suresh Babu Tummala

DOI: <https://doi.org/10.22271/ortho.2019.v5.i4j.1730>

Abstract

Background and objectives: Subtrochanteric fractures are sustained by elderly from trivial trauma such as slipping on stairs, or in the toilet, in younger patients they are caused due to high energy injuries. These fractures are complicated by mal-union, delayed union, non-union. Only recently understanding of biology, reduction techniques and biomechanically improved implants like Gamma nail, Russell-Taylor's nail, Proximal femoral nail allowed for these fractures to be addressed with consistent success. This led us to study sub trochanteric fracture fixation with Dynamic hip screw system (DHS) and cephalomedullary nail.

Materials and methods: Study consists of 40 patients of traumatic sub trochanteric fractures of femur, of which 20 patients are treated with DHS system and remaining 20 are treated with cephalomedullary nail.

Results: Mean time of bone union with DHS group was 19.8 weeks and with nail was 15.2 weeks. According to Kyle's criteria 30% patients were treated with DHS and 50% of patients were treated with nail showed excellent results. Good results were 50% in DHS and 40% in nail, Fair results 20% in DHS and 10% in nail. None of the patients showed poor results.

Interpretation and Conclusion: Cases treated with cephalomedullary nail have shown minimal blood loss, early rehabilitation, early rate of fracture union as compared with those cases treated with DHS as per our study.

Keywords: Subtrochanteric fracture, Dynamic hip screw system, cephalomedullary nail

1. Introduction

Sub trochanteric fractures are sustained by elderly from trivial fall such as slipping on stairs or in the toilet, in younger patients they are caused due to high energy injuries. In sub trochanteric region fracture proximal fragment is flexed, externally rotated and abducted and the Distal fragment displaces medially and further aggravates the deformity and that's why conservative methods of treatment results in mal-union with shortening and restricted hip movement. In addition to these complications due to prolonged immobilization such as bed sores, deep vein thrombosis and respiratory infections are commonly seen. The bone substance from intertrochanteric region to sub trochanteric region changes its consistency from vascular cancellous bone to the less vascular diaphyseal cortical bone of proximal femoral shaft^[1]. Of all the femoral fractures, sub trochanteric femur fracture incidence ranges about 7 to 34%.

These fractures are complicated by mal-union, delayed union or non-union, due to factors such as high stress concentration, muscle pull displacing fragments, Predominance of cortical bone and fracture comminution leading to difficulty in sound fracture reduction. As trochanteric region is a high stress prone region, amounting to 1200 pounds and the fracture geometry greatly varies. Many implants have been recommended for using sub trochanteric fractures because of high incidence of complications. The dynamic hip screw fixation system has been popular method for sub trochanteric fracture fixation. DHS is load sharing device between the bone and implant and provides compression along the femoral neck. Central and very deep lag screw placement achieved an optimal fracture fragment-implant construct in sub trochanteric and intertrochanteric fractures^[2]. Dynamic hip screw is still the implant of choice for sub

trochanteric fractures [3] With understanding of biology and incidence of complications, evolution of improved implants like Gamma nail, Russell-Taylor's nail, proximal femoral nail providing biomechanically stable reduction and improved union rate. High energy communitated proximal femoral fractures, low energy proximal femoral fractures in elderly and pathological fractures showed bio-mechanical stable fixation with Russel-Taylor's reconstruction nail [4]. High energy communitated proximal femoral fractures, low energy proximal femoral fractures in elderly and pathological fractures showed bio-mechanical stable fixation with Russel-Taylor's reconstruction nail [4]. Cut-out and rotation of the cervico- cephalic fragments were answered by addition of 6.4mm anti-rotation screw designing to the construct in PFN. In this respect, it should be born in the mind that the neck screw must be adjacent to the calcar, taking into account the need to place the anti-rotational hip screw [5]. This lead us to study sub trochanteric fracture fixation with Dynamic Hip Screw system and Cephalomedullary nail system.

2. Aims and Objectives

Assess the efficacy of operative management in treatment of sub trochanteric fractures.

3. Materials and Methods

The present study consists of 40 patients of traumatic sub trochanteric fractures of femur, of which 20 patients are treated with DHS system and remaining 20 are treated with cephalomedullary nail. All the 40 patients were followed at regular intervals up to fracture union.

3.1 Surgical technique

- A. DHS and Barrel plate: Patient on epidural/spinal anesthesia, positioned supine over the fracture table and reduction confirmed using C- arm image intensifier. Standard lateral, vastus lateralis splitting approach is used. Guide wire is passed under image intensifier. Reaming of the neck of femur using triple reamer with a desired length. Insertion of lag screw and plate, if more compression is desired, used a shorter screw and plate is fixed to the femur shaft using 4.5mm cortical screws. Incision is closed in layers leaving drain in situ.
- B. Cephalomedullary nail: Patient positioned on fracture table so that antero-posterior and medio-lateral views of trochanteric region of the affected femur can be easily visualized under image intensifier. Incision made over tip of greater trochanter and extended proximally, fascia lata incised and splitting the abductor muscles. Entry point broached using curved bone awl and guide wire passed through entry point under image intensifier and fracture reduced. Serial reaming done and selected nail with jig introduced through the entry point. Proximal and distal locking done under C-arm guidance. Wound closed in layers.

3.2 Postoperative Care

Antibiotics and analgesics were continued, quadriceps strengthening exercises started from day 1. Patient encouraged sitting on bed with back support. Drain removed after 48 hours. All patients were radiographed at regular intervals till the evidence of fracture union

4. Results

Out of 40 patients most of them were in the age group of 21 to 60 years, with mean average of 43.75 years. 30 patients were

male and 10 were female. Right side femur fracture in 24 patients, left femur fracture in 16 patients in our study. Of all 40 cases 24 were road traffic accidents, 16 cases with history of slip and fall.

Of all the fractures 18 cases (58.82%) were type III A, type II (29.40%) of Seinsheimer classification. 40% of cases in our study had full range of hip joint movements, of which 30% in DHS group and 50% in nail group. 15% showed gross limitation of hip movements, of which majority belong to DHS group. 70% of patients with both DHS and nail group showed full range of knee movement. Shortening was observed in 6 patients who had severe communitation among which 4 patients were treated with DHS and 2 patients with nails. Postoperative infection was seen only in 4 (10%) patients who were treated with DHS, none with cephalomedullary nail. Mean time of bone union with DHS group was 19.8 weeks and with cephalomedullary nail was 15.2 weeks. According to Kyle's criteria 30% patients were treated with DHS and 50% of patients were treated with cephalomedullary nail showed excellent results. Good results were 50% in DHS and 40% in nail, fair results 20% in DHS and 10% in cephalomedullary nail. None of the patients showed poor results. On the whole 40% showed excellent and 45% showed good results. Only 15% showed fair results.

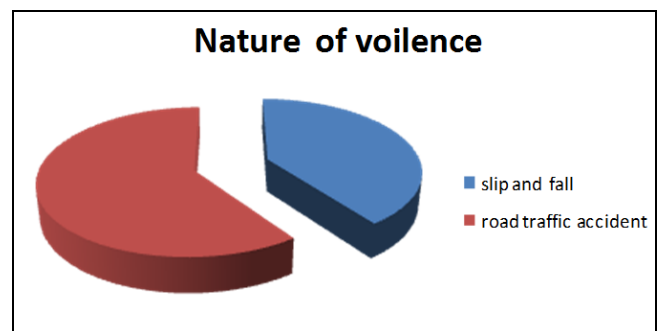


Chart 1: Nature of violence

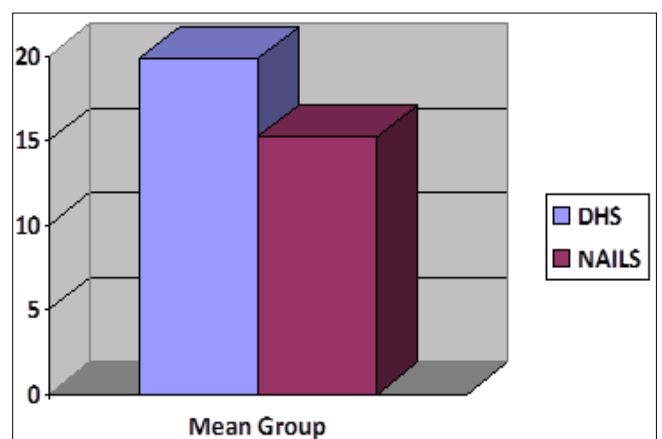


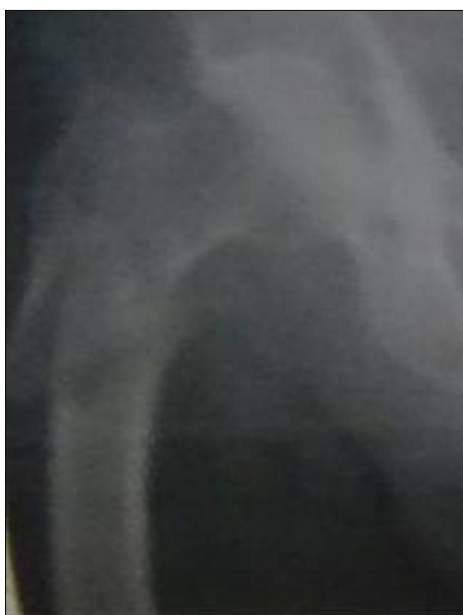Chart 2: Fracture union in weeks

5. Discussion

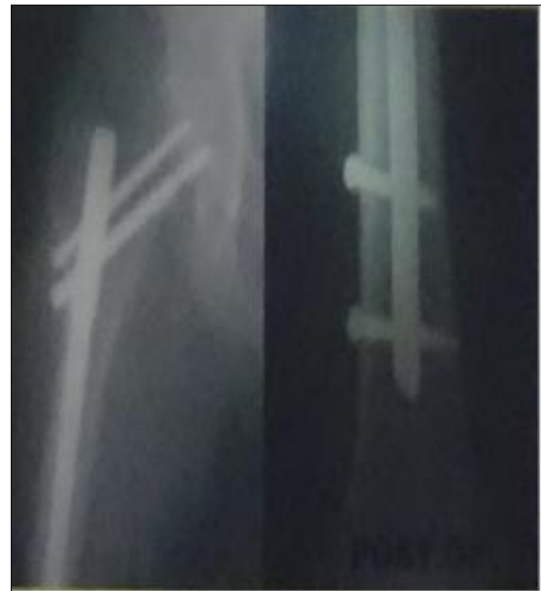Subtrochanteric fractures are difficult to manage due to its biomechanical stress and forces acting at fracture [6].

Lag screw positioning center-center in the femoral head to be achieved to minimize rotation of femoral head and to prevent further mechanical complications [7]. A review on tip apex distance by dynamic hip screw fixation of osteoporotic hip fractures, Concluded that DHS is superior to all other devices in terms of failure rates and functional outcome [8]. Studies have concluded that patients with tip apex distance less than

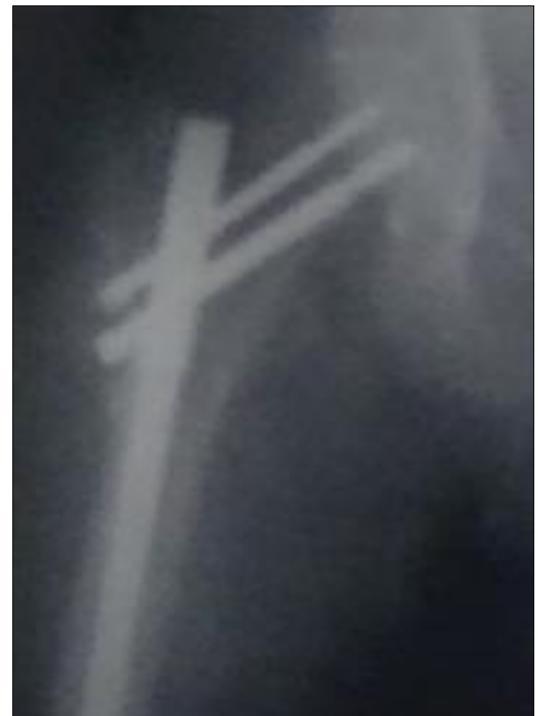2.5cm had given good results, once again strengthening the fact that tip apex distance is major predictor of good fracture union and cut-out failure [9]. DHS fixation achieved excellent results (24.66%) and good results (58.91%) [10]. The effect of lag screw position in trochanteric fractures using sliding hip screw and concluded that, when a lag screw is placed in the inferior part of femoral head in the frontal plane, a torque develops between the resultant force and lag screw head. The femoral head rotates upwards and laterally, lag screw displaces downwards and medially [11]. Our study average age of sub trochanteric fracture was 45.3 years which was comparable of other Indian authors but was less than most of the studies of western authors, in a study majority patients presented with fracture between 50-70 years [12]. Males contributed major share in our series which was comparable with other studies, similar study males were 66.25% and females contributed 33.75% [12]. Right sided fracture was more common than left side as seen in other series [13]. Majority of the fractures belong to class IIIA of seinsheimer's classification i.e, 52.94% and majority were unstable fractures 60%. Shortening was seen in 6 patients of which 2 patient of either group shortening of < 2cms was seen. Time of union among patients with DHS and barrel plate i.e, 19.8 weeks compared to that of fixed with cephalomedullary nail i.e 15.2 weeks. Average time of union was 18 wks in their study [14]. 4 patients treated with DHS showed coxa-vara deformity, another study they had coxa-vara in 05patients [15]. None of the patients in our series showed non-union, implant failure or fat embolism. 04 patients of those fixed with DHS and barrel plate showed superficial infection, in ananother study also 04 (10%) cases with DHS [12]. No mortality was seen in our study. Our outcomes were similar to other studies. Overall we had 90% excellent to good results in those treated with nail and 80% good to excellent results treated with DHS. Our results are comparable to results of other studies, in a study nails had excellent to good results of 83.3% and with DHS 40% [1]. Another study showed 70.8% good to excellent using cephalomedullary nails and 69.33% using DHS [16]. Similar study showed 95% outcome using cephalomedullary nails and 75% excellent to good outcome using DHS for sub trochanteric fracture fixation [17].



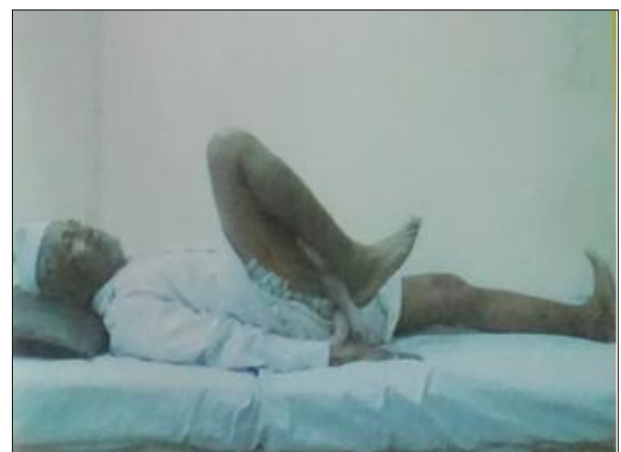1 A: Pre-operative



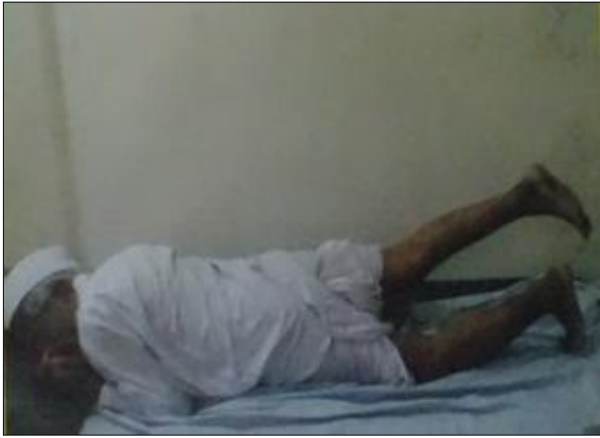1B: Post-operative



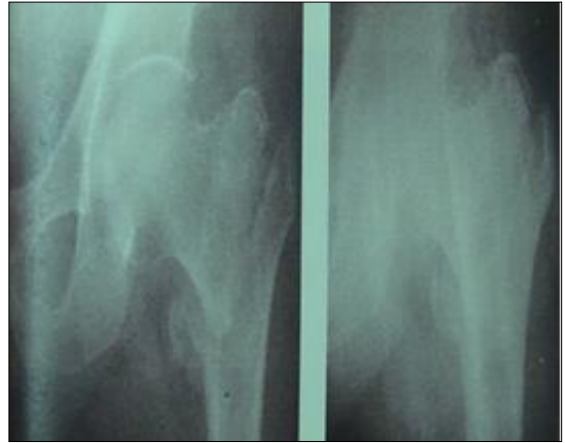1C: Fracture union



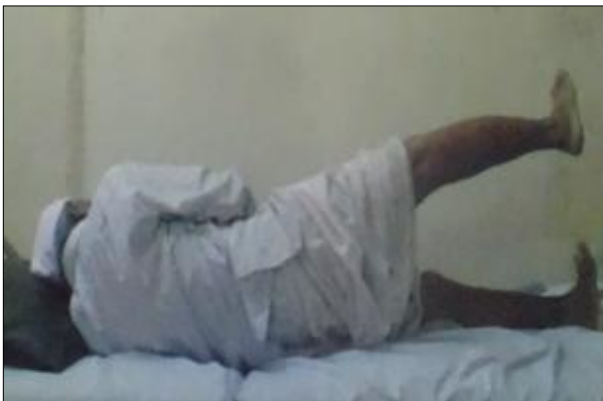1D: Hip and knee flexion



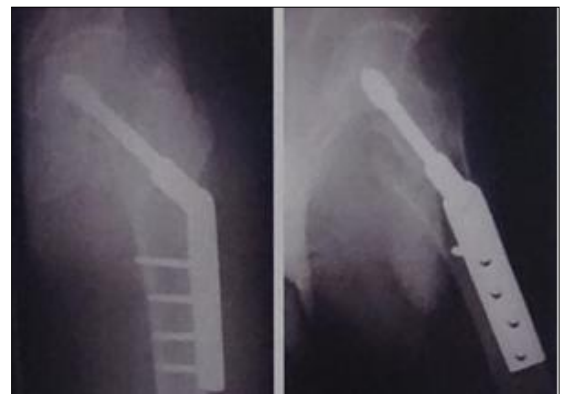1E: Hip extension



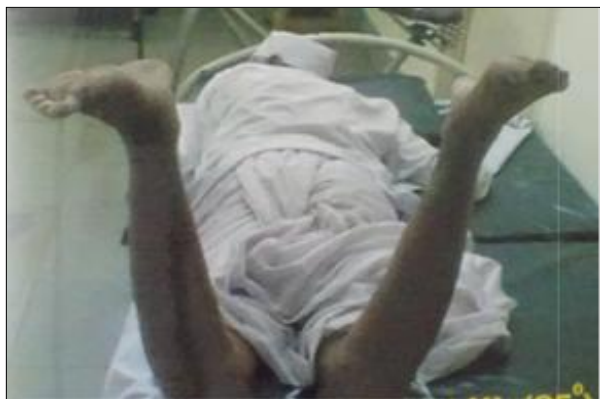2 A: Pre- operative



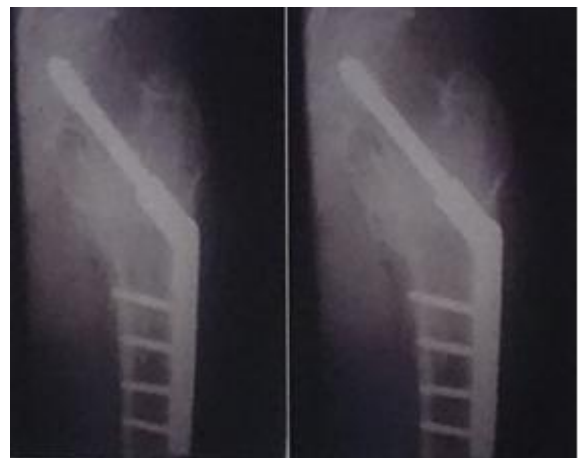1F: Hip Abduction



2B: Post- operative



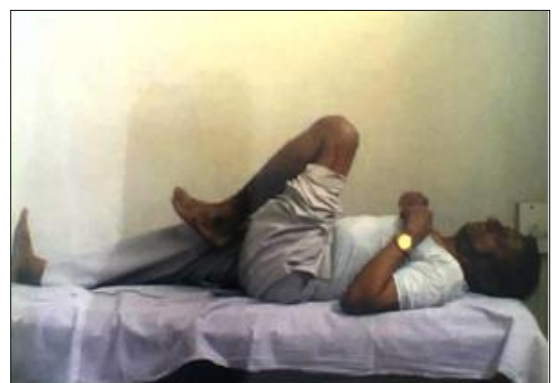1G: Hip internal rotation



2C: fracture union

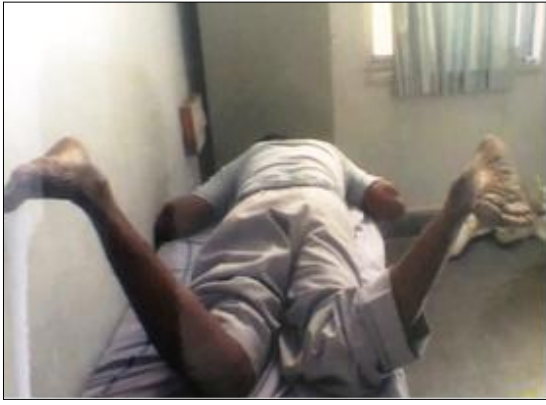

1H: Hip external rotation

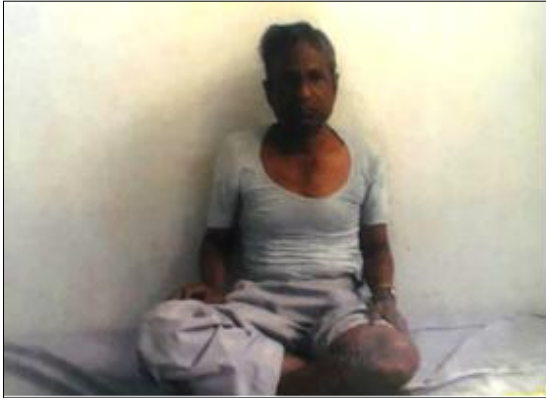

2D: Hip and knee flexion

Fig 1: RT Nail fixation and clinical photos

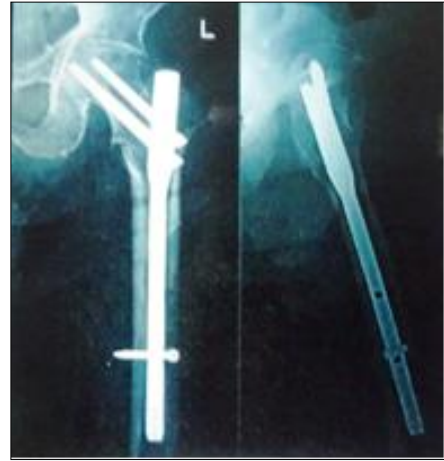

2E: Hip internal rotation

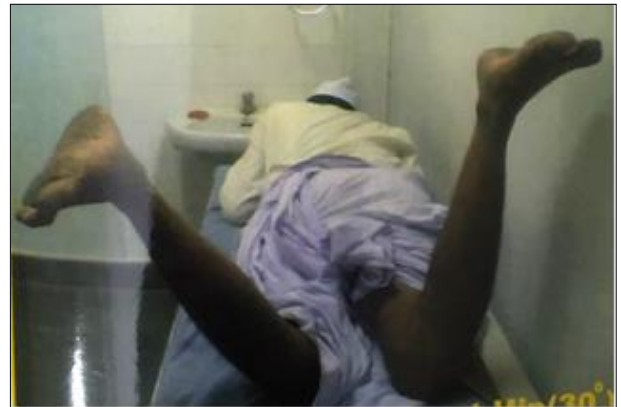

2F: Hip external rotation

Fig 2: DHS Fixation and clinical photos



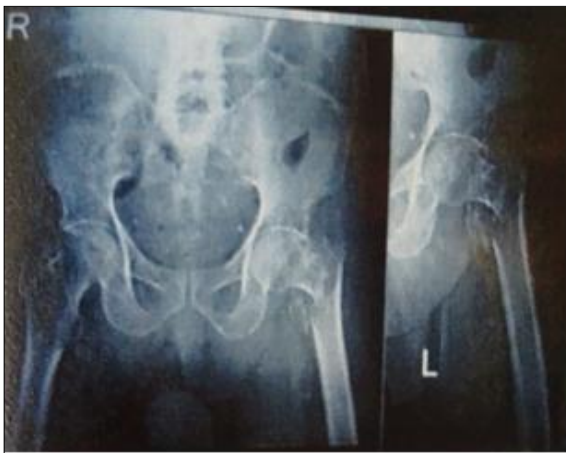3C: Fracture union



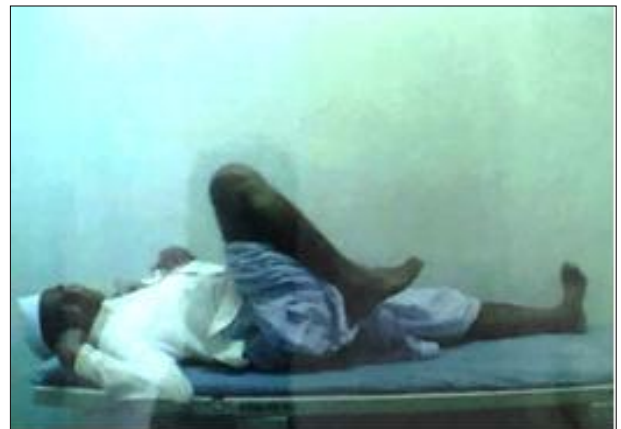3D: Hip internal rotation



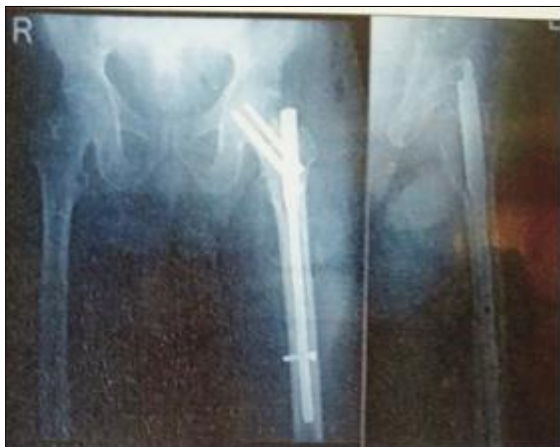3E: Hip external rotation



3A: Pre-operative



3F: Hip and knee flexion



3B: Post-operative

Fig 3: PFN fixation and clinical photos

6. Conclusion

In spite of evolution of various implants the incidence of complications is high even after surgical treatment. Cases treated with cephalomedullary nail have shown minimal blood loss, early rehabilitation, early rate of fracture union as compared those cases treated with DHS as per our study. With our sample study nail has given us encouraging results over the conventional DHS for sub trochanteric femur fractures. However further clinical studies in a larger sample size are needed to corroborate our results.

7. References

1. Gowda PR, Manjunath JA. Prospective comparative study in the clinical outcome of Trochanteric and Subtrochanteric fracture femur with proximal femoral nail versus dynamic hip screw. *Int. J Res Orthop.* 2017; 3(5):986-990.
2. Dodds S, Baumgaertner MR. The sliding hip screw. *Current Opinion in Orthopedics.* 2004; 15(1):12-17.
3. Kumar R, Singh RN, Singh BN. Comparative prospective study of proximal femoral nail and dynamic hip screw in treatment of intertrochanteric fracture femur. *J Clin or Thop trauma.* 2012; 3(1):28-36.
4. Raj D, Coleman NP. Role of Russel Taylor delta reconstruction nail in the management of complex proximal femoral fractures. *Indian J Orthop.* 2005; 39(2):99-103.
5. Tyllianakis M, Papadopoulos A, Papadopoulos A, Papisimos S, Mousafiris K. Treatment of extra capsular hip fractures with the proximal femoral nail (PFN): Long term results in 45 patients. *Acta Orthop Belg.* 2004; 70(5):444-54.
6. McLaurin T, Lawler AE. Treatment modalities of sub trochanteric fractures in elderly. *Techniques in Orthopedics.* 2004; 19(3):197-213.
7. Lenich, Bachmeier S, Prantl L, Nerlich M, Hammer J, Mayr E. Is the rotation of the femoral head a potential initiation for cutting out? A Theoretical and experimental approach. *BMC Musculoskelet Disord.* 2011; 12(1):79.
8. Imran Haruna AK. A Review of Tip Apex Distance by Dynamic Hip Screw Fixation of Osteoporotic Hip Fracture. *Niger Med J.* 2012; 53(14):184-191.
9. Tufescu T, Sharkey B. The lateral radiograph is useful in predicting shortening in 31 A2 per trochanteric hip fractures. *Can J Surg.* 2013; 56 (4):270-274.
10. Boyd HB, Griffin LL. Classification and treatment of intertrochanteric fractures. *Arch Surg.* 1949; 58:853-66.
11. Herscovia D, Pistel WL, Sanders RW. Evaluation and treatment of high sub trochanteric femur fractures. *Am J Orthop.* 2000; 29:27-33.
12. Qidwai SA, Singh R, Mishra AN, Trivedi V, Khan AA, Kushwaha SS *et al.* Comparative study of functional outcome of the intertrochanteric fracture of femur managed by Dynamic Hip screw and Proximal femoral nail. *Nat. J Clin. Orthop.* 2019; 3(1):26-30.
13. Hinton RY, Smith GS. The Association of Age, Race and Sex with the location of proximal femur fractures in the elderly. *J Bone J Surg Am.* 1993; 75(5):752-59.
14. Prasad DV, Kumar S, Rabari Y, Bhatt N, Jadhav A. Comparative study between Dynamic hip screw and proximal femoral nail in the management of trochanteric and sub trochanteric fractures. *International Journal of Orthopedics Sciences.* 2017; 3(4):106-108.
15. Ahmed HH, Bassiooni HA, Mohamady EM, Mostofa MA. A comparison study of proximal femoral nail and

dynamic hip screw devices in unstable trochanteric fractures. *Benha Med J.* 2018; 35:413-8.

16. Suranigi SM, Shetty N, Shah HM. Study comparing the Advantages of proximal femoral nail over Dynamic Hip screw among patients with sub trochanteric fractures. *Journal Medical thesis.* 2014; 2(1):35-38.
17. Tanay R. Prabhoo. Comparative study between Dynamic hip screw and proximal femoral nail in the management of trochanteric and sub trochanteric fractures. *International Journal of Contemporary Medical Research.* 2018; 5(10):12-17.