



International Journal of Orthopaedics Sciences

E-ISSN: 2395-1958
P-ISSN: 2706-6630
IJOS 2019; 5(4): 533-536
© 2019 IJOS
www.orthopaper.com
Received: 05-08-2019
Accepted: 08-09-2019

Dr. Shekhar Tank
Assistant Professor,
Department of Orthopaedics,
Maharaja Agrasen Medical
College, Agroha, Haryana, India

Dr. Nishant Verma
Assistant Professor,
Department of Orthopaedics,
Maharaja Agrasen Medical
College, Agroha, Haryana, India

Dr. Surender Singh
Senior Resident, Department of
Orthopaedics, Maharaja Agrasen
Medical College, Agroha,
Haryana, India

Dr. Puneet Kamra
Senior Resident, Department of
Orthopaedics, Maharaja Agrasen
Medical College, Agroha,
Haryana, India

Dr. Vijender Rawal
Senior Resident, Department of
Orthopaedics, Maharaja Agrasen
Medical College, Agroha,
Haryana, India

Corresponding Author:
Dr. Nishant Verma
Assistant Professor,
Department of Orthopaedics,
Maharaja Agrasen Medical
College, Agroha, Haryana, India

Comparative study of functional outcomes in intra-articular displaced calcaneum fractures managed with conservative versus operative treatment

Dr. Shekhar Tank, Dr. Nishant Verma, Dr. Surender Singh, Dr. Puneet Kamra and Dr. Vijender Rawal

DOI: <https://doi.org/10.22271/ortho.2019.v5.i4j.1729>

Abstract

Background: Displaced intra-articular fractures of the calcaneus are typically the result of high-energy trauma, such as a fall from a height or a motor vehicle accident. Fractures of the calcaneus remain among the most challenging for the orthopaedic surgeon. Comparative study was performed to evaluate the functional outcomes in intra-articular displaced calcaneum fractures managed with conservative versus operative treatment.

Material and Methods: This study was conducted as a Prospective, comparative, randomized controlled trial on 30 patients with displaced intra-articular calcaneal fractures. The patients had been randomly allocated to either conservative or operative treatment, 15 in each group. Radiological union and Clinical [Modified Rowe score] outcomes were measured at 1 year follow up.

Results: As per Modified Rowe's score at 1 year follow up, in operative group 6 patients (40%) had excellent, 8 patients (53.33%) had good and only 1 patient (6.66%) had satisfactory outcome. In conservative group, 1 patient (6.66%) had excellent, 7 patients (46.66%) had good, 5 patients (33.33%) had satisfactory and 2 patients (13.33%) had poor functional outcome. Major complications like subtalar arthritis, peroneal tendinitis and malunion were observed more in conservatively managed group whereas delayed wound healing was observed in 2 operated cases.

Conclusion: We concluded that Displaced Intra articular calcaneum fractures can be better and more effectively treated with open reduction and internal fixation with locking plates as compared to conservative treatment. Early rehabilitation, fewer complications, early weight bearing and better functional recovery was seen with operative treatment.

Keywords: Intra-articular calcaneum fracture, Lateral extensile approach, Locking calcaneum plate, Modified Rowe's score

Introduction

Calcaneal fractures account for approximately 2% of all fractures, with displaced intra-articular fractures comprising 60% to 75% of these injuries. Of patients with calcaneal fractures, 10% have associated spine fractures and 26% are associated with other extremity injuries^[1]. Displaced intra-articular fractures of the calcaneus are typically the result of high-energy trauma, such as a fall from a height or a motor vehicle accident. The clinical examination focuses on pain, swelling, hematoma and deformity at the hindfoot. Active or passive inversion and eversion of the foot is painful. The initial radiographic evaluation of the patient with a suspected calcaneal fracture includes a lateral radiograph series^[2]. The lateral radiograph of the hindfoot demonstrates two important angles: the tuber angle of Böhler and the crucial angle of Gissane^[3, 4]. CT scanning has vastly improved the understanding of calcaneal fractures. CT images are obtained in the axial, 30-degree semi coronal, and sagittal planes. The coronal views provide information about the articular surface of the posterior facet, the sustentaculum, the overall shape of the heel, and the position of the peroneal and flexor hallucis tendons^[5]. The articular fracture classification system of Sanders *et al.*^[6] is based on images in the coronal plane.

Fractures of the calcaneus remain among the most challenging for the orthopaedic surgeon. Nonoperative treatment consists of a supportive splint to allow dissipation of the initial

fracture hematoma, followed by conversion to a prefabricated fracture boot with the ankle locked in neutral flexion to prevent an equinus contracture, and an elastic compression stocking-to-minimize dependent edema. Early subtalar and ankle joint range-of-motion exercises are initiated, and non-weight-bearing restrictions are maintained for approximately 10 to 12 weeks, until radiographic union is confirmed [7].

The majority of displaced, intra-articular fractures of the calcaneus can be effectively treated via an Extensile lateral approach [8]. For internal fixation most surgeons use a single lateral plate that displays the anatomical features of the calcaneus, providing support to the tuberosity, the thalamic portion with the posterior joint facet and the anterior process. Screw placement within the plate can be facilitated with the use of polyaxially locked plate designs [9, 10].

Material and Methods

This study was conducted as a prospective, comparative, randomized controlled trial on 30 patients with intra articular displaced calcaneal fractures. The plan of study was duly approved by institutional ethical committee of our college. Randomization was done using computer generated random number table and then accordingly patients were allocated in either group A or group B. Group A (n=15) patients were managed conservatively and Group B (n=15) patients were managed with operative treatment. All patients included in our study were 15 to 70 years of age, Sander's type 2 and 3 closed fractures less than 3 weeks old and were having normal bipedal gait prior to fracture. Calcaneal fractures with associated spinal injuries, peripheral vasculopathies, pathological fractures, any medical contraindication to surgery and patients not giving consent were excluded in our study.

Radiological examination was performed to assess the type of fracture and important parameters (Bohler's angle and crucial angle of Gissane) and further classified as per coronal section CT images (Sander's classification).

For conservative treatment, closed reduction was attempted by plantarly displacing both forefoot and hindfoot to reverse the mechanism of injury which allows elevation of the posterior facet. For acute swelling over foot we temporarily splinted the foot with short leg POP back slab and advice limb elevation under cover of anti-inflammatory medication and analgesics. After subsidence of swelling, we applied short leg cast for 6 weeks followed by range- of- motion exercises. We started progressive weight bearing at 8 weeks with full weight bearing by 12 weeks once radiological union was confirmed.

Randomly selected patients for surgery, after taking detailed informed and written consent, patients were operated under spinal, epidural or general anaesthesia. Preferred surgical intervention, Open reduction and internal fixation with calcaneum locking plates through Lateral extensile approach was done within 2 weeks of injury, although may be safely performed up to 3 weeks from injury.

During post-operative period patients were managed in the hospital ward with analgesics and antibiotics and operated limb placed in a short-leg non-weight-bearing splint. Early subtalar joint range-of-motion exercises, out of the splint, were initiated; however, weight bearing was not permitted until 10 weeks postoperatively. Partial and full weight bearing ambulation was started depending upon the radiological union. Once weight bearing was initiated, the patient was gradually transitioned into regular shoes as per tolerance.

Regular follow up was done by clinical and radiological examination monthly upto 12 months. Final Functional

outcome at 12 months was assessed using Modified Rowe score [11].

Observations and Results

This study was started in Januray 2017 and completed in January 2019. 30 patients were included and randomly allocated for conservative and operative treatment, 15 cases each. The age of the patients ranged between 19 to 67 years with mean age 39.4 years in operative and 42.7 years in conservative group. There were 20 male (66.67%) and 10 female (33.33%) patients. 56.66% patients with calcaneum fractures were due to fall from height and 43.33% of cases were due to road traffic. 53.33% fractures were classified as Sander's Type II and remaining 46.66% were Sander's Type III. The average time to surgery after episode of trauma in the present study was 12.1 days ranging from 7 to 14 days.

Final assessment was done at 1 year follow up using modified Rowe's score (Pain, range of motion, gait activities and work). Radiological assessment was also done at final follow up.

Pain: 4 cases (26.66%) in operative group had exercise induced pain while other 11 cases (73.33) had no pain at 1 year follow up. Whereas, in conservative group 6 cases (40%) had exercise induced pain and 3 cases (20%) had pain due to mild daily activities and 2 cases (13.33%) had pain even on weight bearing. 4 cases (26.66%) had no pain which was statistically significant (P-value 0.034 at 95% confidence interval)

Range of motion: All operated cases (15) had good range of motion (75-100%) as compared to uninjured opposite side. Whereas in conservative group 12 out of 15 cases (80%) had good range of motion (75 – 100%) and remaining 20% cases had range from 50 to 74% as compared to opposite side which was statistically significant (P-value 0.048 at 95% confidence interval).

Gait: 8 cases (53.33%) in operative group had normal gait while 7cases (46.66%) had mild limp. In conservative group, 5 cases (33.33%) had normal gait, 4 cases (26.66%) had mild limp, 5 cases (33.33%) had moderate limp and 1 case (6.66%) had severe limp at 12 months follow up which was statistically significant (P-value 0.037 at 95% confidence interval)

Work: 11 cases (73.33%) in operated group had no restriction to work and 4 cases (26.66%) had some restrictions at usual occupation. In conservative group 6 cases (40%) had no restriction to work, 7 cases (46.66%) had some restriction to work at usual occupation while 2 cases (13.33%) had to switch over to other job.

Table 1: Final functional outcome (Modified Rowe's score)

Modified Rowe's score	Operative		Conservative	
	Number	Percentage (%)	Number	Percentage (%)
Excellent	6	40	1	6.66
Good	8	53.33	7	46.66
Satisfactory	1	6.66	5	33.33
Poor	0	0	2	13.33
Total	15	100	15	100

As per protocol, X-rays were done regularly at 4 weeks interval and it was observed that average radiological union

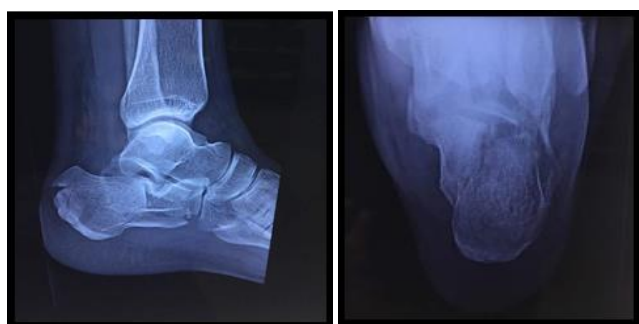time in operative group was 12 to 14 weeks with mean 12.13 weeks, whereas, in conservative group it was 12 to 16 weeks with mean 13.2 weeks which was not statistically significant (P-value 0.59 at 95% confidence interval).

Bohler's angle: Post operative mean Bohler's angle was 28.27 degree compared to opposite normal side which was 30.07 degree, whereas, in conservative group it was 11 degree as compared to 24.54 degree on opposite side with P- value 0.001 at 95% confidence interval in both groups which was highly significant.

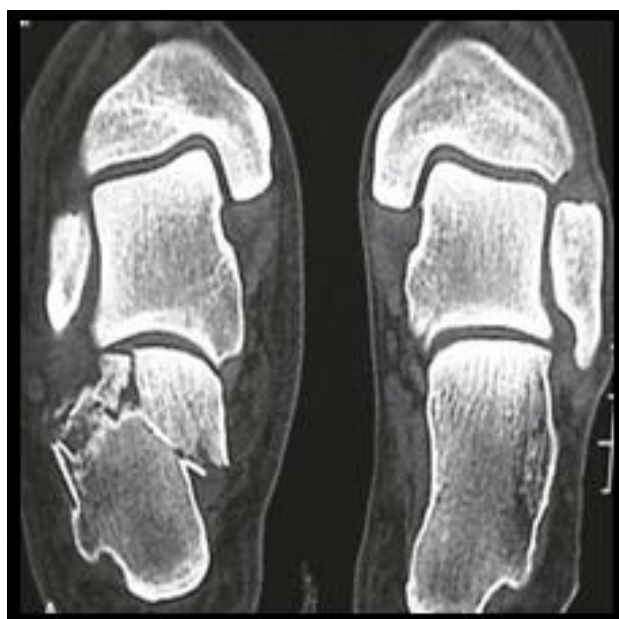
Crucial angle of Gissane: Post operative mean Gissane angle was 105.27 degree compared to opposite normal side which was 103.80 degree whereas in conservative group it was 124.73 degree as compared to 107.53 degree on opposite side with P- value < 0.001 at 95% confidence interval in both groups which was highly significant.

In operated group, 2 cases (13.33%) had delayed wound healing and 1 case (6.66%) developed subtalar arthritis at 1 year follow up. Whereas in conservative group 6 cases (40%) developed subtalar arthritis while calcaneum malunion was seen in 5 cases (33.33%), 3 cases (20%) had Peroneal tendinitis and 1 case (6.66%) developed heel exostosis at 1 year follow up which was significant (P-value 0.029 at 95% confidence interval).

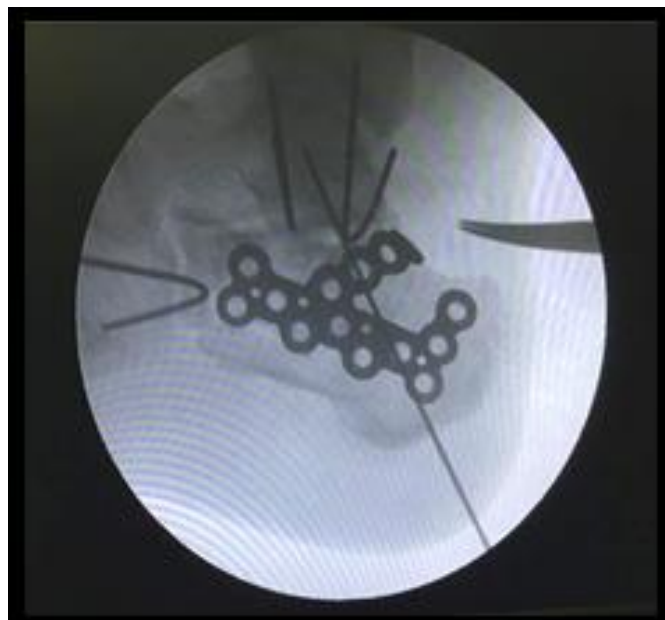
Case 1: Managed with operative procedure



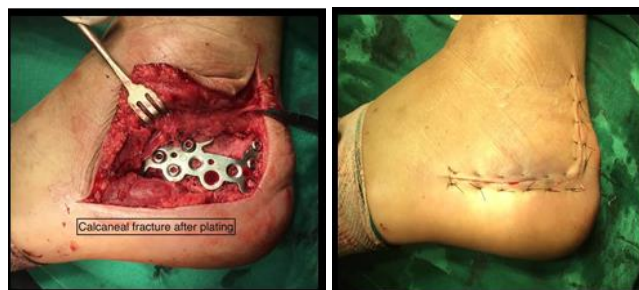Pre-Operative X-rays



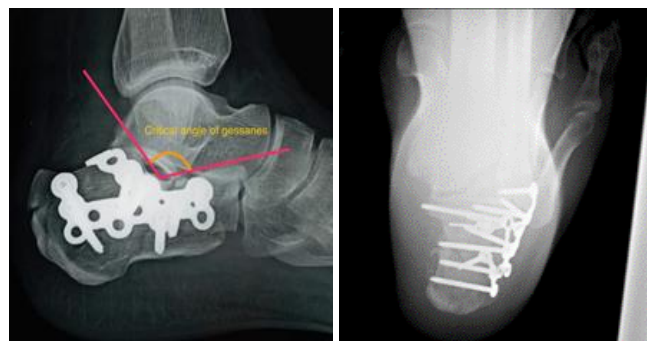
Coronal Section CT scan



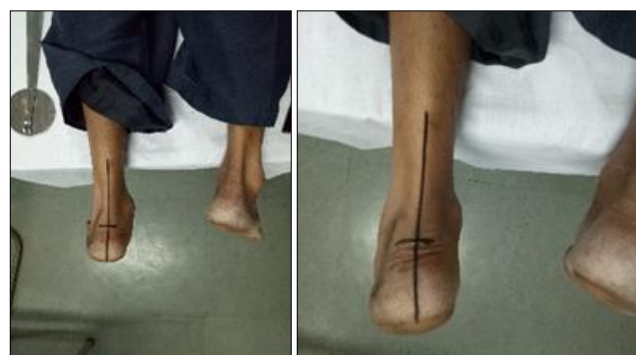Intra-operative fluoroscopy Approach



Exposure via Lateral Extensile

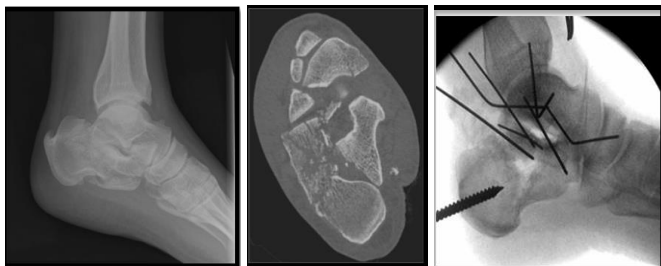


Post-Operative X-Ray

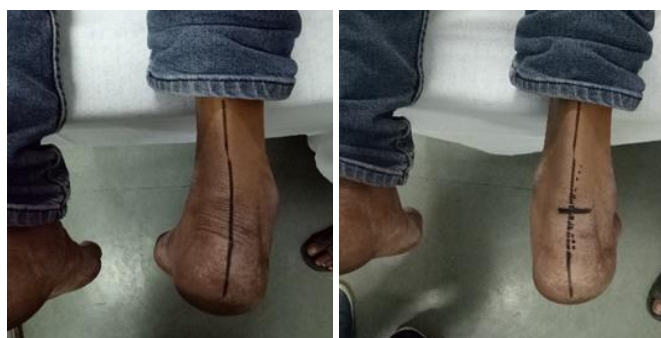
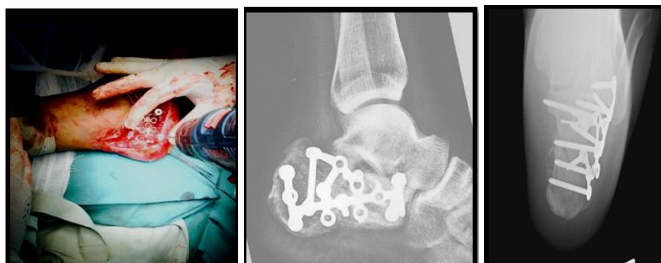
Subtalar Rom At 1 Year Follow Up

Case 2: Pre-Operative X-Rays, Coronal Section Ct Scan and Intra-Operative Fluoroscopy



Lateral Extensile Approach Post Operative X-Rays



Subtalar Rom at 1 Year Follow Up

Discussion

The management of intra-articular displaced calcaneum fracture has always been challenging for orthopaedic surgeons. The ultimate goal is to achieve proper anatomical reconstruction and early rehabilitation without any complications. The best treatment of this fracture remains controversial. Various studies have been conducted to compare the functional outcomes of operative and conservative treatment for these fractures but controversy still exists. The present study was therefore conducted in a prospective manner to compare the functional outcomes of conservative versus operative treatment.

Full weight bearing in all cases was started only after radiological union. Full weight bearing was started early in operative group with the mean 13.4 weeks and in conservative group it was delayed by 1 week compared to operative group. These findings were congruent with the radiological union time in both groups. Comparable results were seen in study by Sanders. R *et al.* [6] in which early full weight bearing was done in operative group with mean time of 13.3 weeks as compared to conservative group.

In our study, minor complications like delayed wound healing was observed in 2 patients (13.33%) and no major complications like deep wound infection, subtalar arthritis, peroneal tendinitis and calcaneum malunion was observed in operative group. Whereas in conservative group major complications like subtalar arthritis and calcaneum malunion were seen in 75% of the patients. These results were comparable with the study by Buckley R *et al.* [12], in which lesser complications were reported in cases with surgical interventions as compared to conservative group.

In the present study as per Modified Rowe's score, in operative group 40% had excellent score while 53.33% patients had good score and only 6.66% case had satisfactory outcome at 1 year follow up and observed mean Modified Rowe's score was 87 at 1 year follow up. These results were comparable with the study conducted by S. Rammelt *et al.* [13], in which good to excellent results were seen with open reduction and lateral plate fixation in 60 to 85 percent of cases. While in conservative group 46% had good whereas 54% cases had satisfactory to poor outcome at 1 year follow up.

Results obtained in the present study are similar and comparable to the results reported in previous literatures in terms of radiological union, complications and functional outcomes.

Conclusion

We concluded that Displaced Intra-articular calcaneum fractures can be better and more effectively treated with open reduction and internal fixation with precontoured calcaneum locking plate as compared to conservative treatment. Since we followed basic principle of anatomical reduction in intra-articular fracture, which holds true for intra-articular calcaneum fracture too, therefore it results in early rehabilitation, fewer complications, early weight bearing and better functional recovery.

References

1. Aaron AD. Ankle fusion: a retrospective review. *Orthopedics*. 1990; 13:1249-54.
2. Hermann OJ. Conservative therapy for fractures of the os Calcis. *J Bone Joint Surg*. 1937; 19:709-18.
3. Harty M. Anatomic considerations in injuries of the calcaneus. *Orthop Clin N Am*. 1973; 4:179-83.
4. Sarrafian SK. *Anatomy of the Foot and Ankle*. Philadelphia: JB Lippincott, 1983.
5. Broden B. Roentgen examination of the subtaloid joint in fractures of the calcaneus. *Acta Radiol*. 1949; 31:85-91.
6. Sanders R, Fortin P, DiPasquale T *et al.* Operative treatment in 120 displaced intra-articular calcaneal fractures. Results using a prognostic computed tomography scan classification. *ClinOrthop*, 1993, 87-95.
7. Zwipp H. *Chirurgie des Fußes*. Springer Verlag, Wien, New York, 1994.
8. Sangeorzan BJ, Ananthakrishnan D, Tencer F. Contact characteristics of the subtalar joint after a simulated calcaneus fracture. *J Orthop. Trauma*. 1995; 9:251-58.
9. Benirschke SK, Sangeorzan BJ. Extensive intraarticular fractures of the foot. Surgical management of calcaneal fractures. *Clin. Orthop*. 1993; 292:128-34.
10. Geel CW, Flemister ASJ. Standardized treatment of intra-articular calcaneal fractures using an oblique lateral incision and no bone graft. *J Trauma*. 2001; 50:1083-89.
11. Rowe CR, Sakellarides H, Freeman P *et al.* Fractures of os calcis: a long term follow-up study of one hundred forty-six patients. *JAMA*. 1963; 184:920.
12. Buckley RE, Meek RN. Comparison of open versus closed reduction of intraarticular calcaneal fractures: a matched cohort in workmen. *J Orthop Trauma*. 1992; 6:216-22.
13. Rammelt S, Amlang M, Barthel S *et al.* Minimally-invasive treatment of calcaneal fractures. *Injury*, 2004, 35.