



International Journal of Orthopaedics Sciences

E-ISSN: 2395-1958
P-ISSN: 2706-6630
IJOS 2019; 5(4): 486-489
© 2019 IJOS
www.orthopaper.com
Received: 10-08-2019
Accepted: 12-09-2019

Dr. M Venkataraman
Associate Professor,
Chettinad Health City and
Research Institute,
Kelambakkam, Tamil Nadu,
India

Dr. E Pradeep
Assistant Professor,
Orthopaedics, Chettinad
Hospital and Research Institute,
Kelambakkam, Tamil Nadu,
India

Dr. Prem Regis PA
Post Graduate Orthopaedics,
Chettinad Academy of Research
and Education, Kelambakkam,
Tamil Nadu, India

Corresponding Author:
Dr. M Venkataraman
Associate Professor,
Chettinad Health City and
Research Institute,
Kelambakkam, Tamil Nadu,
India

Role of arthroplasty in unstable trochanteric fractures in elderly patients

Dr. M Venkataraman, Dr. E Pradeep and Dr. Prem Regis PA

DOI: <https://doi.org/10.22271/ortho.2019.v5.i4i.1720>

Abstract

Objective: Unstable intertrochanteric fractures in elderly patients pose a challenge for treatment in view of coexistent medical problems and osteoporosis. Osteosynthesis in these group of patients often leads to implant failure and also does not allow early weight bearing. The objective of the present study is evaluate Arthroplasty as primary treatment of choice in these unstable intertrochanteric fractures in elderly.

Methods: Between January 2013 to Feb 2016, 25 elderly patients with unstable intertrochanteric fractures who had undergone arthroplasties (Hemi/THR) were followed up. Their fractures were classified according to the AO/OTA classification and their osteoporosis was evaluated by Singh's index and graded accordingly. After optimization of medical problems and pre-anesthetic workup, Arthroplasty was performed in all patients and the outcomes analyzed using the Harris hip score system.

Results: In these 25 patients, 17 were women, 8 were men and the mean age was 76 years (range, 68–88 years). At a mean follow-up of 1 year (range, 1-3 years), there were 18 excellent, 5 good, and 2 fair results according to the Harris hip score system.

Conclusion: In select elderly patients with unstable intertrochanteric fractures arthroplasty has a role instead of Osteosynthesis which allows early pain free mobilization of patients, thereby avoiding revision surgeries, prolonged morbidity and uncertainty associated with Osteosynthesis.

Keywords: Arthroplasty, intertrochanteric fractures, elderly, osteoporosis

Introduction

Trochanteric fractures in elderly patients are usually caused by trivial fall at home during their activities of daily living. This geriatric population has many co morbidities like cardiac, pulmonary and poor vision predisposing them to instability and fall. Even though Osteosynthesis is the routine recommended treatment of choice for trochanteric fractures, there are certain problems of Osteosynthesis persisting in these elderly patients. Common problems are fixation failures due to osteoporosis leading to delayed healing, loosening and implant failures. Further these elderly patients find it difficult to follow a non weight bearing walking protocols in the immediate post op rehabilitation and also not medically fit enough to undergo a revision surgery when Osteosynthesis fails. Further mobility becomes problematic due to illness like dementia, cerebrovascular accidents and other systemic comorbidities. Despite various modalities of treatment for intertrochanteric fractures there is a role for arthroplasty in certain selected groups of these patients [1, 2, 3].

Stable intertrochanteric fractures are usually easily treated with Osteosynthesis with the dynamic hip screws or proximal femoral nailing with predictable results. However, the management of unstable intertrochanteric fractures is a challenge because of difficulty in obtaining anatomical reduction and getting a stable fixation in these patients with poor bone stock [4, 5].

Hence, over the last three decades, for unstable osteoporotic fractures or comminuted trochanteric fractures in the elderly patients or in those with a less life expectancy, various types of arthroplasties were proposed as treatment options with a fairly acceptable results [1, 6, 7, 8, 9].

We did primary arthroplasty (Hemi +THR) in select group of these patients and studied their functional outcome.

Materials and Methods

We present 25 patients with unstable intertrochanteric fractures from January 2013 to February 2016 who underwent arthroplasty either hemi or total hip who were mobilized very early and could be discharged with a short period of hospital stay. All patients were started on DVT prophylaxis peri-operatively, compression stockings post-operatively. Patients were operated under spinal or general anesthesia by the same team of surgeons. They were prepared for surgery as for routine THR and positioned in lateral position. We used the poster lateral approach to the hip in most of the cases. Post-operatively the limb was kept in abduction by an abduction wedge. Hb level and PCV assessed after surgery. Blood transfusions were given wherever required. Drains were removed on second day and check X-rays taken. Deep Breathing exercises, calf pumps and quadriceps muscle exercises were started from the first day. Patients were mobilized early, allowed to sit and stand out of bed daily from second postoperative day and range of motion exercises begun. Patients were discharged after complete physiotherapy once they could mobilize themselves with walker support. Patients were followed every month for first 3 months, every three months for one year and every six months for 2 years.

Inclusion Criteria

- All patients above the age of 65 years with unstable intertrochanteric fractures AO types 31-A2.2, A2.3 and A3
- Singh's index < 4

Exclusion criteria

- Parkinson's patients with poor mobility
- Open fractures
- Severely moribund patients
- Any evidence of previous infection
- Patients - 17 Female 8 Male
- Jan 2013 -- Feb 2016
- Age:- 68 to 88 Mean Age 76
- Retrospective study

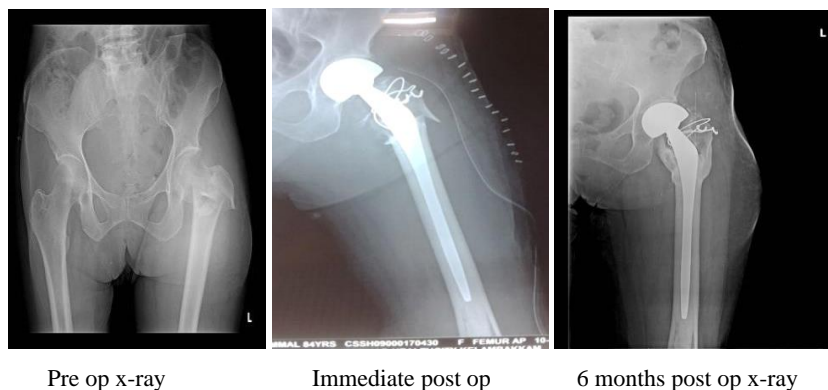
- Hemiarthroplasty 22 16 F 6 M
- Cemented 7 Uncemented 15
- THR 03 01 F 2 M
- Fracture to surgery mean time 3 days

The study was done between Jan 2013 to Feb 2016. Twenty five patients of which 17 females and 8 male patients in age group between 68 to 88 years with mean age of 76 years have been followed up. It is a retrospective study .Twenty two patients who underwent Hemiarthroplasty were followed up of which 16 were females and 6 were males and three patients who underwent THR were followed up of which 2 were males and 1 female. The mean operating period from fracture to surgery is three days. Inj Tranexemic acid acid was used in almost all the patients. Standard poster lateral approach was used. The mean operating time was 2 hours, the mean blood loss was estimated to be 300-500ml, average post operative drainage was 150 ml. Low molecular weight heparin was given for 5 days for all the patients, Blood transfusion was needed in about 7 patients. Most of patients underwent surgery under spinal/epidural anesthesia, were as three patients with cardiac complications underwent surgery under general anesthesia.

Post-operative rehabilitation and follow up

Post operatively chest physiotherapy and ankle pump exercises were started immediately, high sitting knee and ankle mobilization started on first post operative day. Patients were made to walk with walker support on second post operative day. TED stockings were given to all the patients, patients were discharged between fifth to seventh post operative days with osteoporotic medications. Wound healed primarily in all the patients .No infections were encountered. Bed sores were encountered in two patients which healed after mobilization. Deep vein thrombosis was not encountered in any of the patients. Patients were followed up on monthly basis for first three months followed by quarterly for one year.

Case 1: 86/F

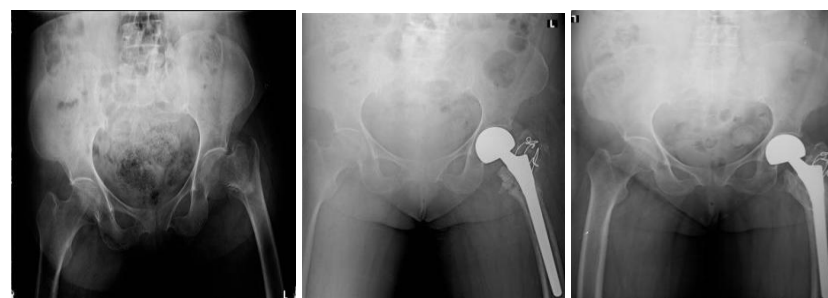


Pre op x-ray

Immediate post op

6 months post op x-ray

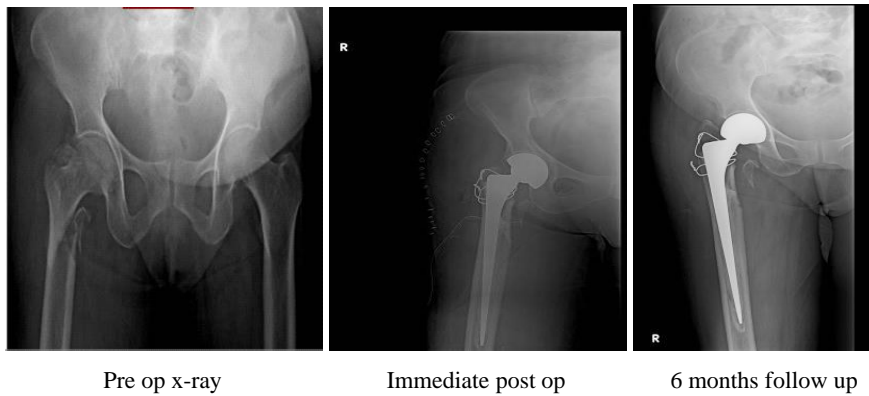
Case 2: 74/F



Pre op x ray

Immediate post op x-ray

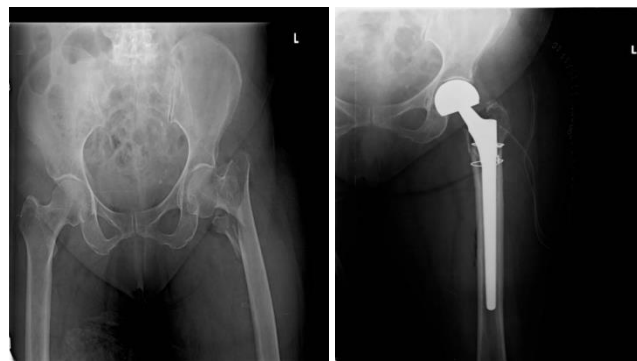6 months follow up

Case 3: 82/M

Pre op x-ray

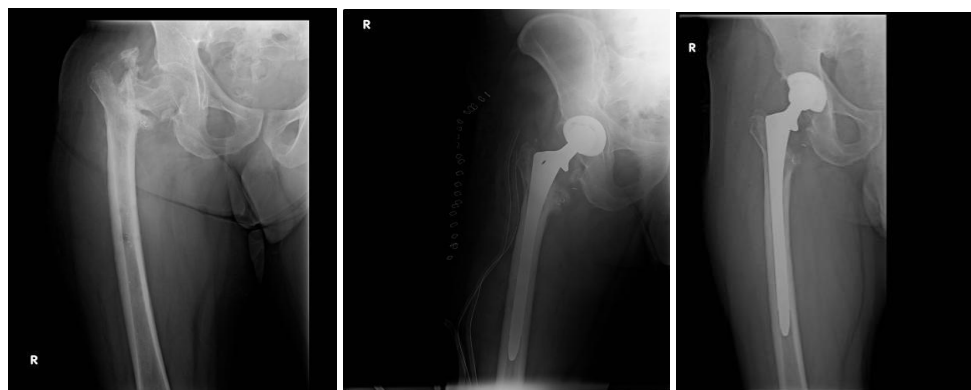
Immediate post op

6 months follow up

Case 4: 78/F

Pre Op X-Ray

Post Op X-Ray

Case 5: 68/M THR

Pre op x-ray

Immediate post op

6 months follow up

Results

In our study population of 25 patients, 17 were women, 8 were men and the mean age was 76 years (range, 68–88 years). At a mean follow-up of 1 year (range, 1–3 years), there were 18 excellent, 5 good, and 2 fair results according to the Harris hip score system. The mean operative time was 120 minutes and blood loss was 300–500ml. Average post operative drainage was 150 ml. Seven patients required blood transfusions. Patients were followed up for 2–3 years. In our study, hip arthroplasty was associated with better functional outcomes than those reported with use of internal fixation. None of patients reported with loosening of implant or infection until last follow-up visit. Three patients who lost follow up were excluded from study. In conclusion we state that these elderly patients with other co-morbidities and low functional demand there is a role for arthroplasty which is one time definitive surgery allowing early mobilization and short

hospital stay.

Discussion

The aim of treatment of Intertrochanteric fractures in this elderly population is early mobilization to prevent the complications and to return to day to day activities for their basic needs. Arthroplasty which is one time surgery helps in mobilizing patients early thus preventing complications. Arthroplasty patients can be allowed full weight bearing significantly earlier than patients treated with internal fixation. Primary hemiarthroplasty has been used as an alternative for unstable intertrochanteric fractures since 1971, allowing early mobilization in these patients and preventing postoperative complications [6]. Hip arthroplasty is a good alternative in patients with comminuted fractures of intertrochanteric region and osteoporotic patients [8, 10]. In our study we re-attached the trochanter and stabilized

posteromedial cortex with stainless steel cerclage wiring. We found cerclage wiring is the best way for reconstructing the abductor mechanism and postero medial cortex. Further adequate soft tissue tension can be achieved by distalizing the Greater trochanter to achieve better stability of the hip there by preventing post op dislocations and prevent Abductor lurch. In patients treated by means of arthroplasty, rehabilitation is much easier and faster, the incidence of bed sores and pulmonary complications are significantly lower^[7]. Faster return to pre-fracture levels of activity essentially prevents flare up of any existing co morbid medical problems in these elderly patients^[7, 11].

We also did pre-op templating of the normal hip which helps us in deciding normal offsets to avoid limb length discrepancy postoperatively in these patients. One difficulty in getting correct version of the components in the absence of lesser trochanter or calcar can be overcome by giving anteversion with respect to medial femoral condyle.

Conclusion

We believe that in selected very old patients, with comorbidities and obvious osteoporosis arthroplasty is much safer than internal fixation which can be compromised with poor bone stock. Given that that these fractures usually occur in the elderly patients, who are less ambulant and less demanding and therefore they put less strain on the endoprosthesis, we believe that this kind of treatment can be considered as an option for unstable trochanteric fractures in these group of patients. The goal of surgical treatment is to enable pre-fracture activity level with early mobilization and thereby increasing the life expectancy of these patients with a reasonable hip function.

References

1. Green S, Moore T, Proano F. Bipolar prosthetic replacement for the management of unstable intertrochanteric hip fractures in the elderly. *Clin Orthop*. 1987; 224:169-177.
2. Harwin SF, Stern RE, Kulick RG. Primary Bateman-Leinbach bipolar prosthetic replacement of the hip in the treatment of unstable intertrochanteric fractures in the elderly. *Orthopaedics*. 1990; 13:1131-1136.
3. Stappaerts KH, Deldycke J, Broos PLO *et al*. Treatment of unstable Peritrochanteric fractures in elderly patients with a compression screw or with a Vandeputte (VDP) endoprosthesis: A prospective randomized study. *J Orthop Trauma*. 1995; 9:292-297.
4. Evans EM. The treatment of trochanteric fractures of the femur. *J Bone Joint Surg Am*. 1949; 31:190-203.
5. Marsh JL, Slongo TF, Agel J, Broderick JS, Creevey W, DeCoster TA *et al*. Fracture and dislocation classification compendium: Orthopaedic Trauma. Association classification, database and outcomes committee. *J Orthop Trauma*. 2007; 21:S1-133.
6. Stern MB, Angerman A. Comminuted intertrochanteric fractures treated with a Leinbach prosthesis. *Clin Orthop Relat Res*. 1987; 218:75-80.
7. Haentjens P, Casteleyn PP, De Boeck H *et al*. Treatment of unstable intertrochanteric and subtrochanteric fractures in elderly patients. Primary bipolar arthroplasty compared with internal fixation. *J Bone Joint Surg Am*. 1989; 71:1214-1225.
8. Chan KC, Gill GS. Cemented hemiarthroplasties for elderly patients with intertrochanteric fractures. *Clin Orthop Relat Res*. 2000; 371:206-215.

9. Kayali C, Agus H, Ozluk S, Sanli C. Treatment for unstable intertrochanteric fractures in elderly patients: internal fixation versus Conehemi arthroplasty. *J Orthop Surg (Hong Kong)*. 2006; 14:240-244.
10. Kesmezacar H, Ogüt T, Bilgili MG *et al*. Treatment of intertrochanteric femur fractures in elderly patients: internal fixation or hemiarthroplasty. *Acta Orthop Traumatol Turc*. 2005; 39:287-294.
11. Vahl AC, Dunki Jacobs PB, Patka PB, Haarman HJ. Hemi arthroplasty in elderly, debilitated patients with an unstable femoral fracture in the trochanteric region. *Acta Orthop Belg*. 1994, 60:274-279.