



# International Journal of Orthopaedics Sciences

ISSN: 2395-1958  
IJOS 2019; 5(4): 498-506  
© 2019 IJOS  
www.orthopaper.com  
Received: 16-08-2019  
Accepted: 20-09-2019

**Dr. K Chittaranjan**  
Associate Professor,  
Melmaruvathur Adhiparasakthi  
Institute of Medical College  
Science Hospital and Research  
Institute, GS Troad,  
Melmaruvathur, Tamil Nadu,  
India

**Dr. D Venkatesh**  
Assistant Professor,  
Melmaruvathur Adhiparasakthi  
Institute of Medical College  
Science Hospital and Research  
Institute, GS Troad,  
Melmaruvathur, Tamil Nadu,  
India

## Retrograde supracondylar intramedullary nailing in the management of supracondylar fractures

**Dr. K Chittaranjan and Dr. D Venkatesh**

**DOI:** <https://doi.org/10.22271/ortho.2019.v5.i4i.1723>

### Abstract

To analyse the clinical and radiological outcome of retrograde supracondylar Intramedullary Nailing in supracondylar femoral fractures.

**Materials and Methods:** 23 patients with supracondylar fractures were included in this study. For all patients retrograde supracondylar nailing done. All cases chosen were the patients coming to Melmaruvathuradhiparasakthi institute of medical college science hospital and Research Institute, from June 2018 to June 2019. The injured limbs were initially immobilized with skeletal traction with Bohler-braun splint.

**Inclusion criteria:** Type A and type C of AO classification Grade I and II of Gustillo Anderson open fracture

**Exclusion criteria:** Type B of AO Fractures which are partially articular and doesn't have supracondylar extension in most cases. Nonunion of Supracondylar fractures.

**Keywords:** supracondylar fractures, nailing, traction

### Introduction

Road traffic accidents are increasing year after year. These are high velocity trauma and often cause complex fractures of distal femur. Supracondylar femoral fractures are the fractures that occur within 7.5 to 9 cms proximal to the articular surface of knee joint. These fractures predominantly occur in two patient populations: a younger male group with high-energy injuries and an older osteoporotic female group with low violence injuries. Treatment of these fractures has long been a controversial issue. Watson Jones noted "few injuries present more difficult problems than the supracondylar fracture of femur". The comminution, fracture extension into the knee joint, injury to quadriceps mechanism and vulnerable position of the popliteal artery cause difficulties in the treatment of these fractures.

Open reduction and internal fixation is now often performed with various implants like condylar plate, cancellous screws, dynamic condylar screws and intramedullary interlocking nail.

The problems in these fracture when they are surgically treated are, reduction and fixation of multiple fragments (Often in Osteoporotic bone), restoration of alignment in three planes and achieving equal limb length. Once all these are attained with good restoration of articular surface, stiffness may remain a problem. A compliant patient is required for early-supervised mobilization and range of movement exercises.

The intramedullary supra condylar nail was developed by Dr. Green, Seligson & Henry. Retrograde insertion of an intramedullary nail from the knee stabilizes the fracture below the isthmus and facilitates return of good function.

### Classification

#### AO classificaton

#### Extra articular fracture

- A1 Extra articular fracture, simple
- A2 Extra articular fracture metaphyseal wedge
- A3 Extra articular fracture metaphyseal Complex

**Corresponding Author:**  
**Dr. K Chittaranjan**  
Associate Professor,  
Melmaruvathur Adhiparasakthi  
Institute of Medical College  
Science Hospital and Research  
Institute, GS Troad,  
Melmaruvathur, Tamil Nadu,  
India

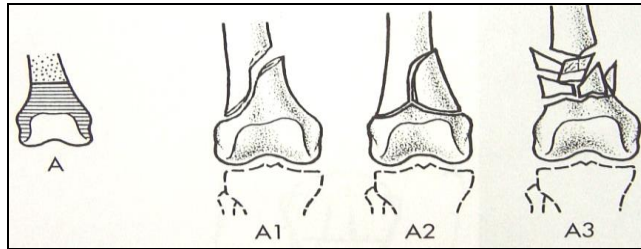
**B. Partial articular fracture**

- B1 Partial articular fracture, lateral condyle, Saggital
- B2 Partial articular fracture, medial condyle Saggital
- B3 Partial articular fracture, frontal

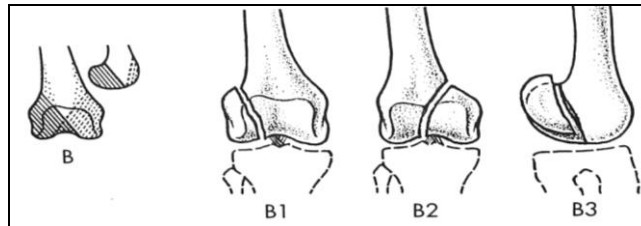
**C. Complete articular fracture**

- C1 Complete articular fracture, articular simple metaphyseal simple.
- C2 Complete articular fracture, articular simple metaphyseal multi fragmentary
- C3 Complete articular fracture mutli fragmentary

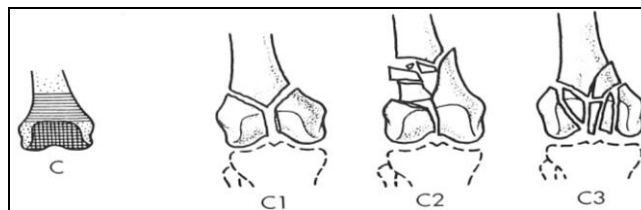
**AO classification**



**Fig 1: Extra Articular Fracture**



**Fig 2: Partial Articular Fracture**



**Fig 3: Complete Articular Fracture**

**Seinsheimer classification**

**1. Non displaced fracture**

Any fracture with less than 2 mm of displacement of fractured fragments.

**2. Fractures involving only the distal metaphysis without extension into the Intercondylar region.**

- A. Two part fracture
- B. Comminuted fractures

**3. Fractures involving the intercondylar notch in which one or both condyles are separate fragments**

- A. Medial condyle is a separate fragment, lateral condyle

remains attached to the femoral shaft.

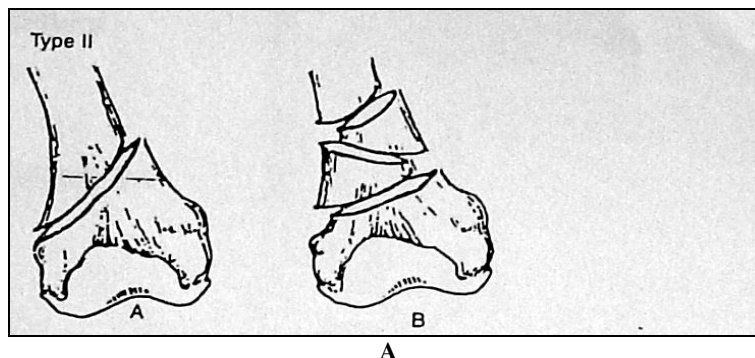
- B. The lateral condyle is a separate fragment, medial condyle is intact.

- C. Both condyles are separated from the femoral shaft and from each other.

**4. Fractures extending through the articular surface of the femoral condyles.**

- A. A fracture through the medial condyle [two parts are comminuted]

- B. A fracture through the lateral condyle [two parts are comminuted]



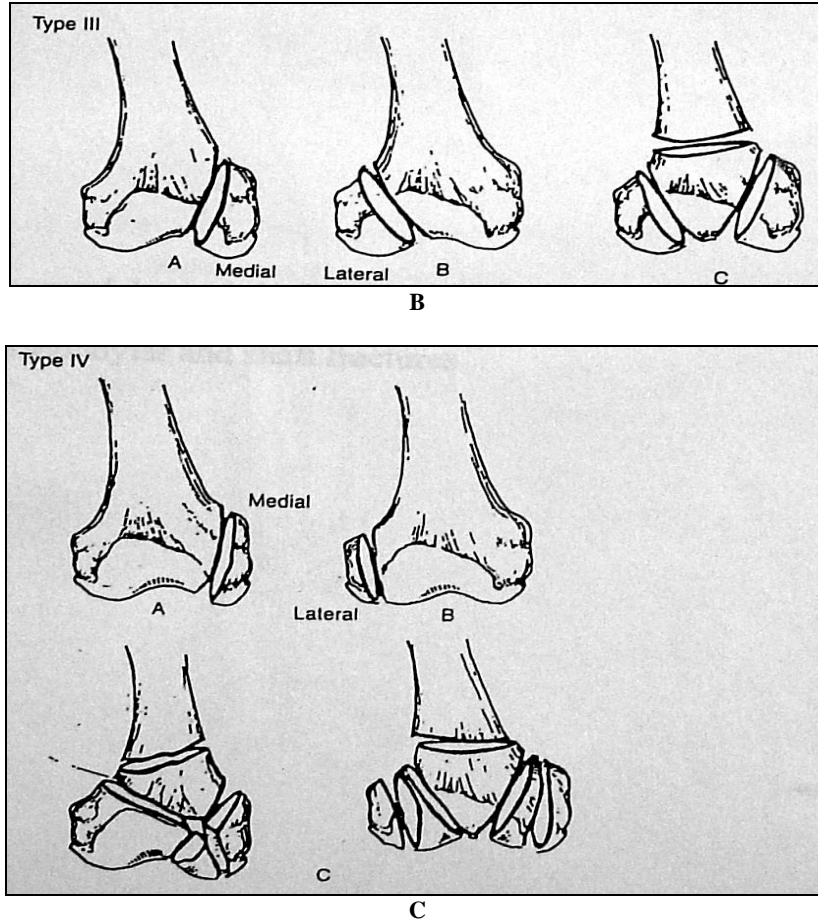


Fig 4: Types of Seinsheimer fractures

**Neers classification**

1. Minimal displacement
2. Displacement of condyles

- Medial
- Lateral
- 3. Concomitant supracondylar and shaft fractures.

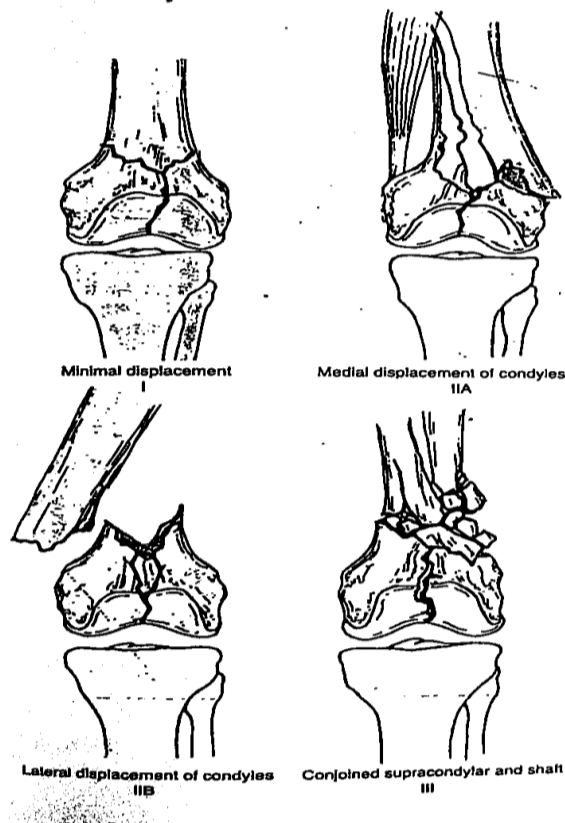


Fig 5: Types of Neers fractures

**Biomechanics of intramedullary nail**

Significant stresses on bone are generated just by activities of daily living. The bones are stressed as the muscles contract, bringing the origins and insertions close together to move the joints. Bending of bone cause compression on concave side of neutral axis, and tension on convex side.

An intramedullary nail helps to regain temporary stiffness followed by callus formation at periphery. Finally, a mature bony callus forms restoring the original stiffness. The nail serves to stabilize the fracture fragments and maintain alignment and permits motion at fracture site during functional activities. The nail acts by the principle of three point fixation and it acts as an internal splint and serves as a load sharing device permitting weight bearing across the fracture site and allows healing by peripheral callus. It allows axial loads to be transmitted between both ends of fracture fragments, non-intramedullary nails do not provide rotational stability, this lead to the development of interlocking nail.

**Non-interlocking nail**

The standard non locked nail is useful in the treatment of simple and minimally comminuted midshaft fractures of femur. In selected case early mobility and weight bearing can be achieved.

**Materials and Methods**

23 patients with supracondylar fractures were included in this study. For all patients retrograde supracondylar nailing done. All cases chosen were the patients coming to Melmaruvathuradhiparasakthi institute of medical college science hospital and Research Institute, the from June 2018 to June 2019. The injured limbs were initially immobilized with skeletal traction with Bohler-braun splint.

All cases were assessed preoperatively using antero posterior and lateral roentgenograms.

In this study we lost follow up of 3 Patients.

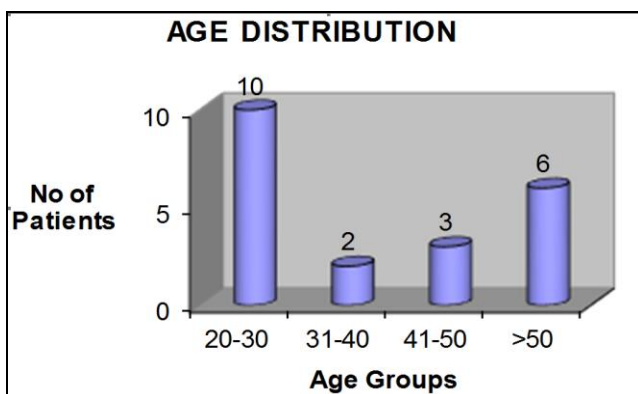
**Table 1: Sex**

Male	14
Female	6

Male preponderance is due the more active social life style of males.

**Table 2: Age Distribution**

Age group (Years)	No. of patients
20-30	10
31-40	2
41-50	3
>50	6
Total	20



**Graph 1: Age Distribution**

**Table 3: Side**

Right	15
Left	5

Right lower limb being dominant is commonly affected.

**Table 4: Mode of Injury**

Road traffic accident	14
Fall from height	6

Almost all fracture were due to high velocity trauma.

**Table 5: Associated Injuries**

Injury	3
Ipsilateral fracture neck of femur	1
Contralateral fracture shaft of femur	2
Fracture both bones leg	1
Fracture bone fore arm	1
Fracture trochanter	1
Fracture tibial condyle	1
Total	10

Being high velocity injuries, associated injuries were common.

**Table 6: Type of Injury**

Closed	18
Grade I compound	1
Grade II compound	1
Total	20

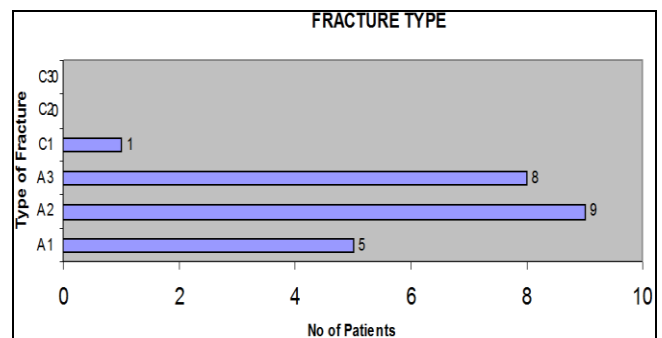
**Table 7: Fracture Type**

A1	5
A2	9
A3	8
C1	1
C2	0
C3	0

AO type A were the most common.

**Inclusion criteria:** Type A and type C of AO classification Grade I and II of Gustillo Anderson open fracture

**Exclusion criteria:** Type B of AO Fractures which are partially articular and doesn't have supracondylar extension in most cases. Nonunion of Supracondylar fractures.

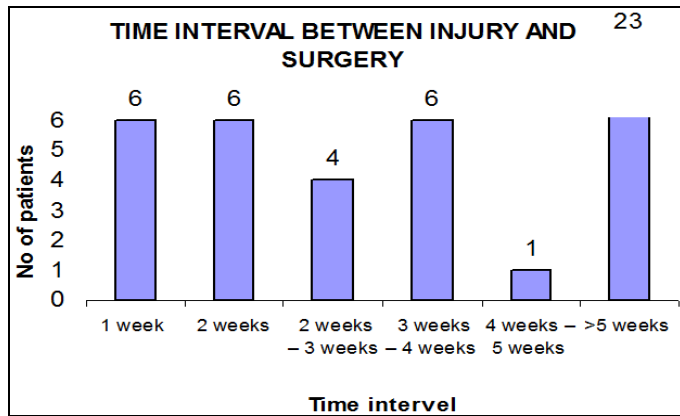


**Graph 2: Fracture Types**

**Table 8: Time Interval between Injury and Surgery**

Time interval	No. of cases
Below 1 week	6
Below 2 weeks	6
Between 2 weeks – 3 weeks	4
Between 3 weeks – 4 weeks	6
Between 4 weeks – 5 weeks	1
>5 weeks	23

The delay in taking up for surgery is due to non-availability of theatre days, compound nature of the wound or associated injuries.



Graph 3: Time Interval

**Mode of surgical management**

All patients were treated with. Intramedullary Supracondylar nailing.

**Method of Nailing**

**Table 9:** Method of nailing

<b>Open</b>	<b>13</b>
Closed	7

Bone grafting was used in 4 cases.

**Results**

In this study 23 cases were treated by retrograde intramedullary supracondylar nail. The follow-up period ranged from 3 months to 22 months. The follow up was lost for 3 patients. Other patients were regularly reviewed every 4 weeks until the fracture unites and there after every 2 months. Clinical parameters like tenderness at the fracture site, range of movements at knee, limb length measurements and pain on weight bearing were assessed. Radio logically callus formation and progression of union were looked for.

The union was quick and prompt in 18 cases. The callus formation was visible radio logically between 6 and 8 weeks and bony union was achieved between 12 and 13 weeks.

Fracture was considered united when bridging callus was evident on one or more radiographs and patient was able to walk full weight bearing without crutches. Patients were followed at 6 weeks interval till union and on 3 month, 6 month and 12 month.

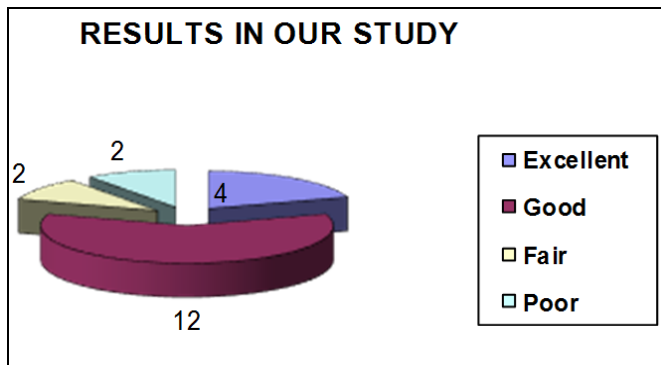
All patients were followed up until fracture union occurred. Patients were assessed using SANDERS ET AL scoring system (JBJS-1991:73 A) in this system patients were assessed with the range of motion, pain, walking ability, deformity and return to pre injury status.

**Table 10:** Function and Results

Function	Result	Points
Range of motion		
Flexion		
>25	Excellent	6
100-124	Good	4
90-99	Fair	2
<90	Poor	0
Flexion		
0	Excellent	3
<=5	Good	2
6-10	Fair	1
>10	Poor	0
Deformity Angulation		
0	Excellent	3
<10	Good	2
10-15	Fair	1
>15	Poor	0
Shortening (cm)		
0	Excellent	3
<1.5	Good	2
1.5 - 2.5	Fair	1
>2.5	Poor	0
Pain		
None	Excellent	10
Occasional or with changes in weather, or both	Good	7
With fatigue	Fair	5
Constant	Poor	0
Walking Ability		
Walking		
Unrestricted	Excellent	6
>30 minutes to < 60 minutes	Good	4
<30 minutes	Fair	2
Walks at home, or confined to wheelchair, or is bedridden	Poor	0
Stair Climbing		
No limitation	Excellent	3
Holds rail	Good	2

One stair at a time	Fair	1
Elevator only	Poor	0
Return to work (A or B)		
A. Employed before injury		
Returned to pre injury job	Excellent	6
Returned to pre injury job		
With difficulty	Good	4
Altered full time job	Fair	2
Part time job or unemployed	Poor	0
B. Retired before injury	Excellent	6
Returned to pre injury lifestyle	Good	4
Needs occasional help		
Needs assistance at home	Fair	2
with activities of daily living	Poor	0
Moved in with family or Nursing home		

**Results**



**Fig 6:** We had 16 patients with good to excellent results, 2 Poor and 2 fair results

**Table 11:** Outcome

<b>Excellent</b>	<b>20%</b>
GOOD	60%
FAIR	10%
POOR	10%

**Complications**

The following complications were encountered in our study.

**Table 12:** Complications

<b>Joint stiffness &lt;90 deg.</b>	<b>8</b>
Knee pain	7
Fixed flexion deformity	1
Varus deformity	2
Infection	2
Hardware failure	1
Missed screws	2
Limb length discrepenciness	1
Non union	1

**Knee stiffness**

This was the most frequently encountered problem in our study. Average knee flexion was 90°. The main reasons for knee stiffness were delay in taking up the case for surgery, opening of the knee joint for intraarticular starting point and to a lesser extent associated injuries. The range of movements in patients operated with 2 weeks was an average of 105°. Early surgery and early mobilization gave better results.

**Knee pain**

30% of the patients has mild or moderate knee pain at rest, 40% of patients had pain on walking, which was relieved by analgesics.

**Fixed flexion deformity**

One patient had insignificant (5°) fixed flexion deformity.

**Malalignment**

Two patients had mild (5°) varus deformity.

Infection Two patients developed infection three months after surgery, he had sinuses numbering two with seropurulent discharge. Radio logically the fracture went for solid union and showed no sequestrum. The infection was controlled with antibiotics and sinuses healed completely. Till last follow up (nine months) the patient was doing well.

**Limb length discrepancy**

We encountered 1 case of Limb length discrepancy of 2cm. Patient was treated with proper food wear to overcome the shortening.

**Missed screws**

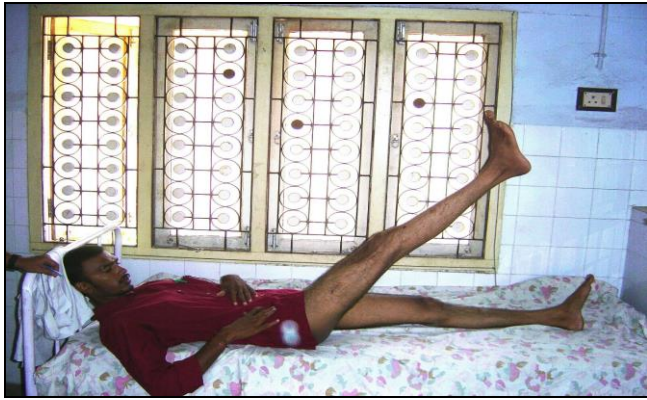We encountered 2 cases of missed screws while attempt to interlock in the proximal fragment with the gig. We try to take the screws. Intraoperatively but not possible due to lack of time. The screws were plan to remove during metal exit or they were trouble - some. For this reason the proximal locking was done with free hand technique in most instance

**Case illustration**

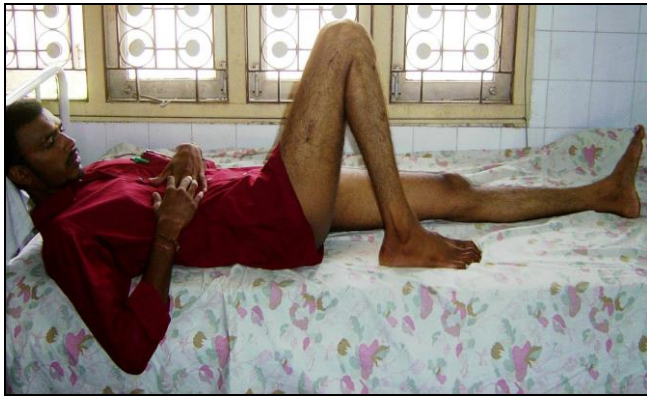27 years old gentleman [6], had AO type A2 supracondylar fracture with ipsilateral fracture neck of femur following a road traffic accident.

Upper tibial pin traction was applied and supracondylar nailing was done with bone grafting 3 weeks after injury. Cancellous screw fixation was done for fracture neck of femur 5 weeks after injury.

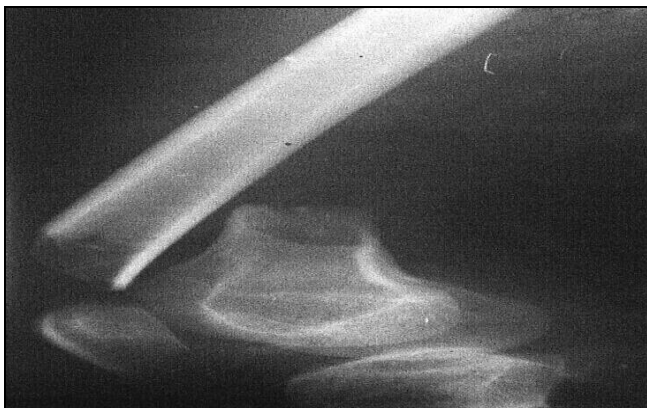
Knee mobilization was started 1 week after second surgery. Partial weight bearing was allowed after 10 weeks. Full weight bearing was allowed after 16 weeks. At the end of 16 weeks patient had solid union of fracture with excellent Functional results.



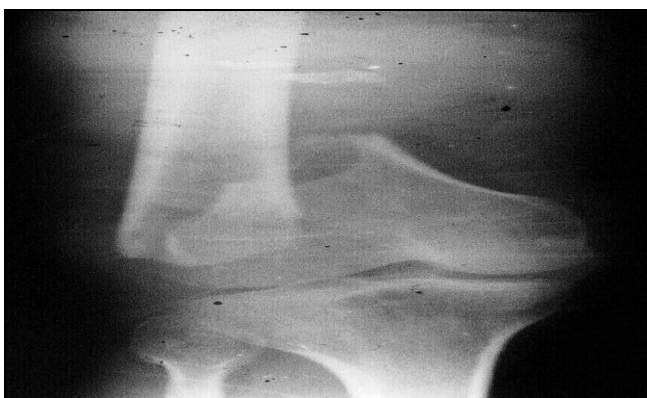**Fig 6:** post-op Hip Flexion



**Fig 7:** Post-op: Knee Flexion

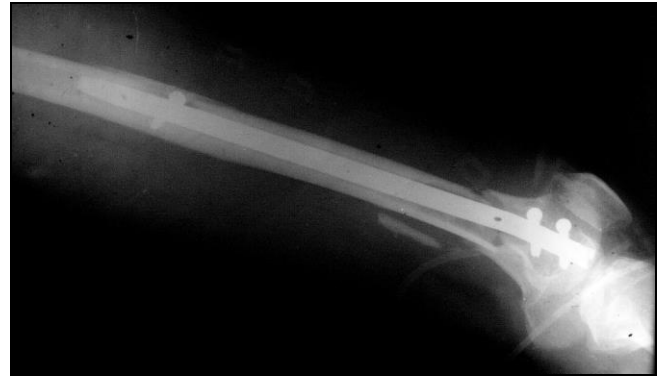

**A**



**B**

**Fig 8:** Pre-op X-rays (A, B)



**C**



**D**

**Fig 9:** Post-OP X-rays (C, D)

### Discussion

Fractures of the distal femur being high velocity injuries pose difficulties in the management. Ideally these fractures are managed surgically, so that the anatomy of the fractured bone is restored. Intra articular fractures require meticulous planning and execution in restoring the normal anatomy. Rigid internal fixation of these complex fractures also permits early mobilization of the adjacent joints thereby facilitating early rehabilitation.

Supracondylar nail provides rigid internal fixation for rapid healing of supracondylar fractures with a comparable functional outcome to lateral fixation devices and with a significant decrease in soft tissue dissection.

In this study, 23 patients with supracondylar and distal femur fractures underwent retrograde supracondylar nailing using intra articular starting point. The mean duration between injury and surgery was moderate in our study (2 weeks) due to

- Delay in the patient reporting to the hospital after native treatment,
- Non availability of the theatre time
- Time taken for the wound to heal in compound injuries and
- Management of associated injuries

This delay accounted for the difficulty in fracture reduction with consequent opening up of the fracture site in 55% of the patients. 45% of the patients underwent percutaneous supracondylar nailing.

Primary bone grafting was done in

- Patients who were taken up late for definitive management,

- Fractures with gross comminution and
- Fractures with gross osteoporosis.

The follow up period ranged from three months to two years. Radiological evidence of callus was seen at 6 to 8 weeks and union was achieved at 10 to 12 weeks in 19 patients. Union rate was 87% which is comparable to the result (89%) reported by Ostrum *et al.*

In our series of 20 patients we had 80% good to excellent results and 8% fair results. Excellent results were obtained in the patients which were operated earlier, and in patients with closed non-articular type of fractures.

In our study 80 % excellent to good results was achieved. This is comparable with the study of Richard Gellman et al where he had 82.7% of excellent to good results. We had 20 % fair to poor results, whereas in their study it was 17.2%. 16 patients had excellent to good result according to Sanders et al scoring criteria.

Moed and Watson reported better results with no infection, no implant failure, and only 3 non unions, although 6 patients had knee pain. They achieved 130 degrees range of motion. - Moed and Watson (JBJS vol77A:1520-1527, 1995).

Paterson et al reported with 5 nonunion, 3 implant failure, 1 deep infection, 1 patient had shortening, and an average ROM of 109 degrees in his series.

In 34 supracondylar fractures treated with IMSC nail, all fractures healed with an average ROM of 100 degrees. "The genucephalic nail is a good treatment for supracondylar femoral fractures". - Seligson D (J Clinic ortho, 296; 200-6, 1993) In our study, we had 1 implant failures, 1 case of nonunion, 2 sub clinical infection, 1 shortening and the average ROM was 100 degrees.

The reasons for knee stiffness in our study were

1. Delay in taking up the case for surgery
2. Open method of fracture fixation
3. Lack of patient compliance regarding knee mobilization
4. Opening of the knee joint for intraarticular starting point
5. Associated injuries

The patients operated within two weeks of injury showed good range of knee flexion, which indicates that early surgery and early mobilization give better results.

We have encountered 1 case of nonunion and the same patients has > 5° of varus malalignment. This probably due to delay in time of injury and operating time, improper preoperative treatment.

In our study 2 patients had infection, among them 1 patient, 45 years old male who had a grade II open injury, for this patient surgery was done after 3 weeks. He developed Subclinical infection after 3 months. The infection subsided with antibiotics after for 3 weeks. He is in regular follow up. In another patient clinical infection present without radiological evidence. Which is superficial 4 days after surgery, IV antibiotics given, wound healed well and his fracture united by 13 weeks.

He had 2 patients of varus malalignment. In one patient it is associated with malunion this is due to the result of the entry point being made laterally.

Incidence of knee pain in our study was 30 to 40%. Studies by various authors like Herscovici and Sanders (1993) have shown that the incidence of knee pain ranged from 7 to 60%. Significant knee pain probably represented occult traumatic injury to the knee at the time of injury and opening of the knee joint for intraarticular starting point.

We have not include type C<sub>2</sub> and C<sub>3</sub> AO Fractures because of

their intra articular extension and extensive comminution which do not favour retrograde nail insertion. This was tried in 1 patient with type C<sub>3</sub> AO Fracture the alignment was not good and the procedure was cumbersome and it was converted in to lateral fixation and bone grafting done.

We have not included type B AO Fractures, because they are partially intraarticular and the doesn't have true supracondylar involvement, these fractures can be fixed with screws alone, successfully in most instance.

Compared to plate osteosynthesis intramedullary fixation requires less extensive dissection and it is biomechanically more favourable. In the elderly patients, these characteristics seem important since bone quality, extensive procedures and bone grafting remain problematic. Good functional results are obtained in elderly patients.

### Conclusion

Supracondylar nail provides rigid internal fixation for rapid healing and comparable functional outcome to lateral fixation devices with significant decrease in soft tissue dissection which is proved from our study.

Supracondylar nailing serves to be a better option for AO Type A and type C1 supracondylar fractures.

In our study, even in patients with severe osteoporosis this means of fixation proved to be very efficient.

Patients who underwent early surgery had better results compared to the patients for whom the procedure was delayed.

We conclude that closed nailing will give better results compared to open nailing.

Early post-operative mobilization gave a better functional outcome compared to the patients in whom the mobilization was delayed due to various reasons We finally conclude that supracondylar nail is the best implant to treat extra articular distal femoral and intra articular fractures without comminution.

### References

1. Aglietti P, Insall Walker PS, A new patella prosthesis design. Clin Orthop. 1975; 107:175-87.
2. Bain GL, Zacest AC, Patterson DC. Abduction strength following intramedullary nailing of femur. J Orthop trauma. 1997; 11:93-7.
3. Benirschke SK, Melder I, Henley MB. Assessment of complications and functional outcomes of closed interlocking nailing in femoral shaft fractures. J Orthop trauma. 1993; 7:118-22.
4. Blacksin MF, Jurlo JV, Levy Internal dearrangement of the knee after femoral shaft fractures. Skeletal radiol. 1998; 27:434-9.
5. Brumback RJ, Ellison TS, Molligan H, Mahaffey SJ, wells D. Pudendal nerve palsy complicating intramedullary nailing of the femur. JBJS. 1992; 74:1450-5.
6. Buckwalter JA, Cruess RL. Healing of musculoskeletal tissues. In Rockwood. (Eds). Rockwood and Green's fracture in Adults Philadelphia: Lippincott, 1991, 181-185.
7. Campbell's operative orthopaedics by S. Terry Canale, M.D., 9<sup>th</sup> edition, Vol.2 and 3: P.1190.
8. Chin KR, Altman DT, Altman GT, Mitchell TM. Retrograde nailing of femoral fractures in patients with myelopathy and who are no ambulatory. Clin. Orthop, 2000, 218-26.
9. Elmaraghy AW, Richards RR. Femoral and cruciate



- blood flow after retrograde femoral reaming. *J Orthop trauma*. 1998; 12:253-8.
10. Gregory P, DiCicco J, Karpik. Treatment with retrograde femoral nailing and undreamed tibial nailing. *J Orthop trauma*. 1996; 10:309-316.
  11. Henry SL, Tragers S, Greens S. Management of supracondylar fracture with intramedullary nail. *Contem Orthop*. 1991; 22:631-641.
  12. Herscovici D, Whiteman. Retrograde nailing of the femur using an intercondylar approach. *Clin Orthop*. 1998; 332:98-104.
  13. Horne Blue. Intraarticular heterotrophic calcification in knee following retro grade femoral nailing.
  14. Innacone WM, Bennet FS, Delong WG. Initial experience with the treatment of supracondylar femoral fractures using the supracondylar intramedullary nail a preliminary report. *J Orthop trauma*. 1994; 8:322-327.
  15. Insall JN, Kelly MA. Fractures of femoral condyles, In Insall Jn (ed), *Surgery of the Knee*. New York; Churchill Livingstone, p.1017.
  16. Jabczenski, Crewford. Retrograde supracondylar nailing in femoral fractures above total knee arthroplasty. *J. Arthroplasty*. 1995; 10:95-101.
  17. Janzing HM, Stockman BV, Damme G, Rommens P, Boos PL. Retrograde intramedullary nail prospective experience in patients older than 65 years. *Arch Ortho Trauma Surg*. 1998; 118:92-5.
  18. Moed BR, Watson JT. Undreamed retrograde nailing of femur fractures. *J Orthop trauma*. 1998; 12:334.
  19. Morgan E, Ostum RF, Poka J. Effects of retrograde femoral intra medullary nailing on patello femoral articulation. *J Orthop trauma*. 1999; 13:13-16.
  20. Ostrum RF, Diccico J, Lakatos R, Poka A. Retrograde intramedullary nailing of femoral diaphyseal fractures. *J orthop Trauma*. 1998; 12:464-8.
  21. Patterson BM, Routt ML, Bainschke SK, Hansen ST. retrograde nailing of femoral shaft fractures. *J trauma*. 1995; 38:38-43.
  22. Ricci WM, Bellabarba C, Evanoff B. retrograde versus antegrade nailing of femoral shaft fractures.
  23. Sanders R, Koval KJ. Retrograde reamed femoral nailing. *J Orthop trauma*. 1993; 7:293-30223.
  24. Scheerlinck T, Krallis P, DesCampsPY. Preliminary experience of femoral supracondylar nailing. *Acta Orthop Belg*. 1998; 64:385-92.
  25. Schmeiser G, Vastman J, Potulski M, Hoffmann GO, Unfallchirurg. Supracondylar nailing in patients with spinal cord lesions. 2002; 105:612-8.
  26. Seligson D, Stephen LH, Green SA. Technique of intra medullary supracondylar nailing. *J Orthop trauma*. 1993; 7:325-6.
  27. Strecker W, Kinzl L, Keppler P, Corrective osteotomy of distal femur with retrograde intramedullary nailing. *Unfallchirurg*. 2001; 104:973-83.
  28. Swiontkowski MF, Hansen ST, Kellam J. Ipsilateral fractures of femoral neck and shaft. *JBJS (Am)*. 1984; 66:260-8.
  29. Vangeness CT, Decampos J. Arthroscopic evaluation of meniscal injuries associated with femoral shaft fractures. *JBJS (Br)*. 1993; 75:207-9.
  30. Walker DM, Kennedy JK. Occult knee ligament injuries associated with femoral shaft fractures. *Am J sports med*. 1980; 8:172-4.