



International Journal of Orthopaedics Sciences

E-ISSN: 2395-1958
P-ISSN: 2706-6630
IJOS 2019; 5(4): 384-387
© 2019 IJOS
www.orthopaper.com
Received: 19-08-2019
Accepted: 21-09-2019

Dr. Mohammed Jalal Mohiuddin
Assistant Professor, Department
of Orthopaedics, Deccan College
of Medical sciences, Hyderabad,
Telangana, India

Dr. C Shamsunder
Professor and Head, Department
of Orthopaedics, Deccan college
of Medical sciences, Hyderabad,
Telangana, India

Dr. Wasif Ishaqui
Post Graduate, Department of
Orthopaedics, Deccan college of
Medical sciences, Hyderabad,
Telangana, India

Dr. Feroz Ahmed
Post Graduate, Department of
Orthopaedics, Deccan college of
Medical sciences, Hyderabad,
Telangana, India

Corresponding Author:
Dr. Mohammed Jalal Mohiuddin
Assistant Professor, Department
of Orthopaedics, Deccan College
of Medical sciences, Hyderabad,
Telangana, India

Neglected CTEV and Ilizarov assisted correction: A case report

**Dr. Mohammed Jalal Mohiuddin, Dr. C Shamsunder, Dr. Wasif Ishaqui
and Dr. Feroz Ahmed**

DOI: <https://doi.org/10.22271/ortho.2019.v5.i4g.1702>

Abstract

Clubfoot or congenital Talipes equino-varus is a congenital foot anomaly with a fixed pattern of deformities which include Cavus, Adductus, Varus, and Equinus.

Neglected clubfoot can be related to situations of no treatment, inadequate, insufficient, or discontinued treatment presents in developing and underdeveloped countries. The options for treatment in such cases includes corrective osteotomies, arthrodeses, JESS fixator application or Ilizarov assisted correction

Described is the case of CTEV presented late with left foot deformity.

The left foot shows forefoot adduction, mid foot cavus and hind foot varus and Equinus at ankle joint. Callosities were present along the lateral border. Limited soft tissue release and Ilizarov fixator assisted distraction was done. Tibialis anterior lateralisation performed after correction in second sitting.

The result was painless plantigrade foot with minimal post op scarring.

Keywords: Ctev, club foot, Ilizarov, Tibialis anterior, callosities

1. Introduction

Clubfoot or congenital Talipes equino-varus (CTEV) is a congenital anomaly of foot characterised by a typical, fixed pattern of deformities which include Cavus, Adductus, Varus and Equinus. After the introduction of Ponseti technique of manipulation the prognosis has improved drastically ^[1].

Neglected clubfoot can be related to situations of no treatment, inadequate, insufficient, or discontinued treatment ^[2, 3]. Neglected clubfoot is a common problem in developing and underdeveloped countries, reason may be inadequate knowledge of parents and root care givers, myths associated with deformity and drop outs etc. Approximately 80% of children with congenital clubfoot are born in developing countries ^[4].

In neglected club foot problem is complicated by additional secondary changes in skin, bones, and joints due to weight bearing in deformed position ^[5].

There are various available modalities to attend the problem of neglected CTEV which includes corrective osteotomies by removing bony wedges, triple arthrodesis in extreme cases, JESS (Joshi's external stabilization system) and Ilizarov assisted correction ^[6]. The common complications associated with open surgeries and bony procedures include soft tissue fibrosis, vascular problems and surgical wound dehiscence and recurrence ^[7].

The Ilizarov method is being used increasingly to correct many orthopaedic deformities. The frames required for ankle and foot deformity correction are among the most difficult to construct owing to the complexity of the deformities which must be corrected ^[8, 9]. When performed with all precaution Ilizarov has better result in comparison to other modalities of treatment. The principle here is distraction histogenesis along with differential distraction ^[10]. There is less amount of fibrosis, tensioned wires has low friction at wire bone junctions which decreases chance of loosening and infection. The effected foot which is already smaller due to underlying pathology will not get further compromised; in reality the size of foot also increases considerably ^[11].

Presented case is the case of neglected CTEV treated with Ilizarov.

Case history

A 6 year old male child was brought by parent to the OPD with the complaints of deformity of the left foot since birth. He was applied POP cast after birth and abandoned further treatment after first cast when patient develop scratch over the skin at time of POP removal by machine.

Patient had limp since the time patient started walking. The child was unable to wear a normal shoe over left foot. He unable to ride a bicycle or participate in any sports activities.

Examination revealed change of Gait as patient walking on the lateral border of the left foot. Left foot was deformed as there was adduction at fore foot, cavus effecting the midfoot and the hind foot has equinovarus deformity.

There were callosities along the lateral border with deep plantar crease. Plantar surface was facing posteriorly. There is an associated atrophy of the calf and thigh muscles with LLD (limb length discrepancy) of three centimeters. Peronei muscles had 2/5 power. There were no associated hip and spine defects. Distal neuro-vascularity was normal.

Based on above patient diagnosed as a case of "Left side idiopathic, Congenital Talipes Equino Varus, neglected type (un-attended) with callosities with no neurovascular deficit".

Treatment

The main of any offered treatment is to have plantigrade, painless, functional, supple foot, cosmetically acceptable and fits into standard footwear. Considering that the decision of Ilizarov assisted correction was taken.

After pre anesthetic clearance patient was operated under general anesthesia. Open plantar fascia release (Steindler's release) was done to correct cavus foot. The Tendo Achilles lengthening by Z plasty and the posterior ankle joint capsule release was performed. Skin closed with 3-0 ethilon.

Ilizarov application with the two tibial rings and two foot rings (Calcaneum and metatarsals) done. The measure taken here is application of tibial rings along the proximal aspect of leg, the olive wires passed into the foot in lateral to medial direction for calcaneum and medial to lateral direction in metatarsals. There were no hinges used in the construct.

Distraction started after 10th day of surgery. Initially foot rings were distracted till cavus and inversion got corrected which took 3 weeks. Differential distraction with 1:2 ratio (medial side more than lateral side) was done. Distraction for equinovarus deformity started after foot correction and it also took 3 weeks. Frame was kept for 6 weeks after correction of complete deformity.

The Ilizarov frame removed in short General anesthesia noticed that patient had persistent metatarsus adductus and clawing of toes. To correct this deformity abductor hallucis release and percutaneoustenotomy of the Flexor hallucis longus and Flexor digitorum longus performed. After the closure of skin k wire was passed along great toe and above knee cast applied. Cast was kept for 6 weeks. After cast removal foot was Splinted with AFO (ankle foot orthosis).

During the follow-up it was found that patient is developing dynamic supination. There was tibialis anterior over activity. To come over this planned tibialis anterior lateralization to the third cuneiform.

After the Tendon Transfer, patient was kept on cast till tendon transfer healed. Advised AFO for 1 year after that normal shoes and he was started routine activities.

Results and Discussion

Ilizarov assisted correction is the extension of the manipulation steps by Ponseti as we do fore foot correction by

stretching the tissue followed by hind foot correction. The only difference is the amount of force needed which is more and given by mechanical help of Ilizarov frame tensioned wires.

It took almost 3 months for major correction in our case and there is he need of secondary procedures like abductor hallucis release and tibialis anterior lateralization. These are clinical based tailored decision to be performed staged wise. The end result we got is supple, painless, plantigrade foot which is help ful for performing daily and recreational activities and fit into standard foot wear.

Maqdoom et.al.in their study of CTEV correction by Ilizarov assisted distraction histogenesis in age group of 8 years to 12 years has shown excellent functional outcome in 71 percent of subjects. There was need of tendo Achilles lengthening and plantar fascia release as it was tight. Ilizarov construct was kept for mean time of 3.6 months; it was 3 months in our patient.

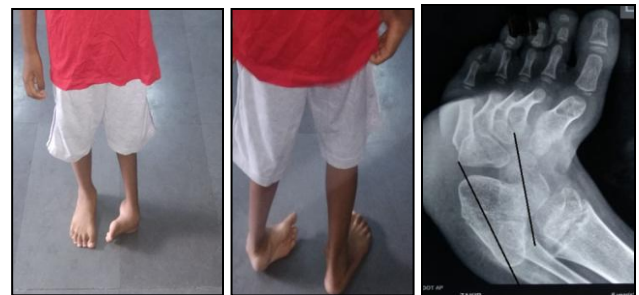

Fig 1: Pre-op photos and X ray

Kites angle

Angle between long axis of talus and calcaneum is 2 degrees (normal 20 to 40 degrees)

Talus-first metatarsal angle

50 degree (N= 0-20 degrees)

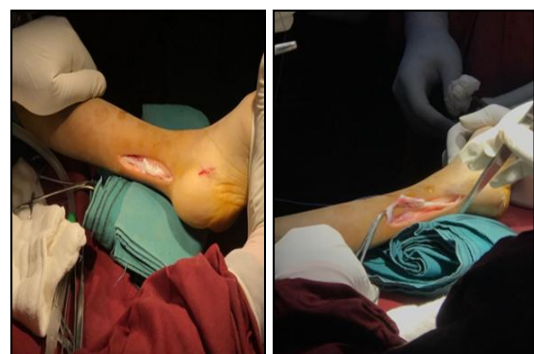

Fig 2: Steindlers Release

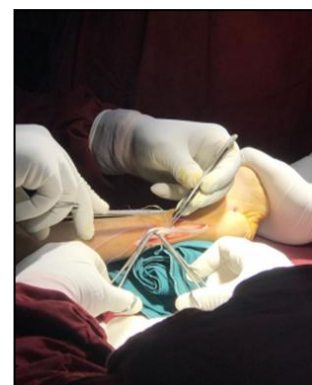
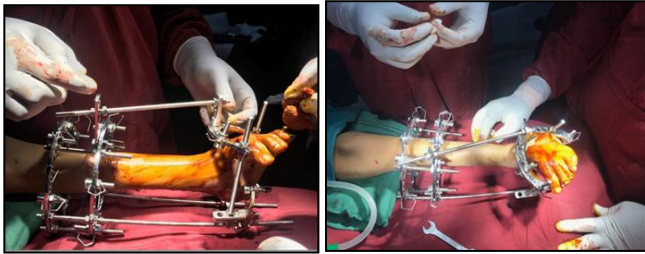
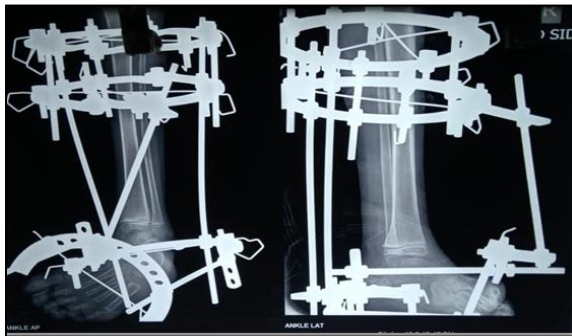
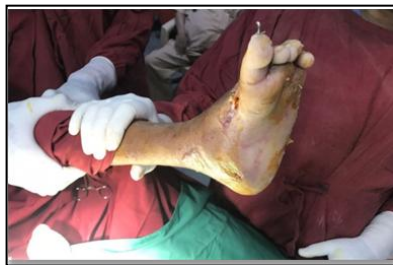
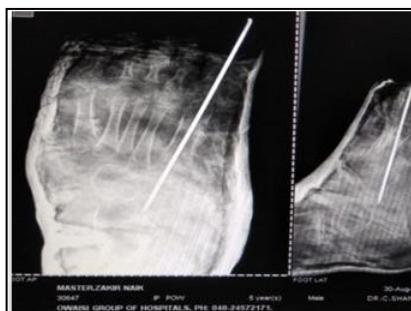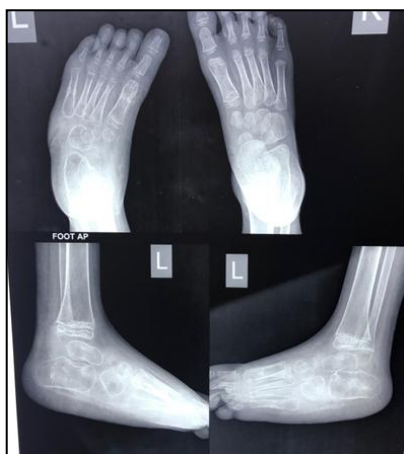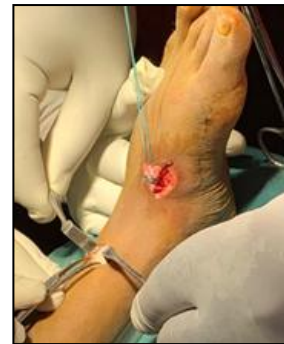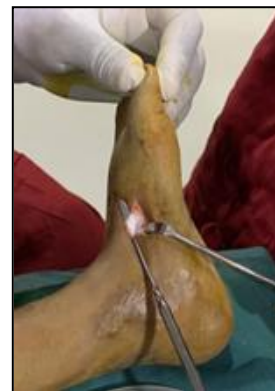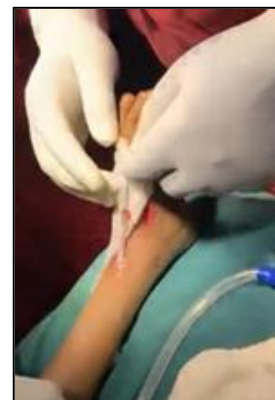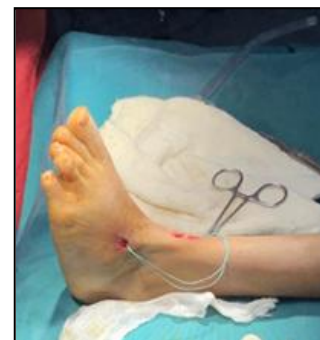Fig 3: Tendoachillies lengthning

**Fig 4:** Ilizarov frame fixation**Fig 5:** post op x ray**Fig 6:** Implant removal and FHL/FDL tenotomy and Abductor Hallucis release**Fig 7:** Post op X ray**Fig 8:** Post op X rays**Persistent fore foot adduction**

Contributed by unapposed Invertors (tibialis anterior) and weak everter (peronei).

Lateral view shows correction of equinus deformity (plantigrade foot).

Tibialis anterior lateralization**Fig 9:** Detached from insertion**Fig 10:** Identification of Tibialis**Fig 11:** Tendon re-rooted laterally long subcutaneous tunnel**Fig 12:** Tendon taken out from Extensor retinaculum proximally

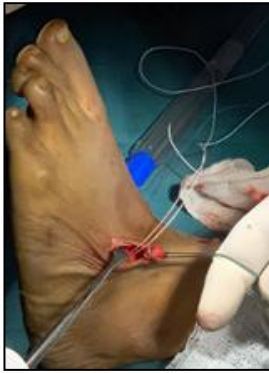

Fig 13: Tendon reinserted on third cuneiform bone

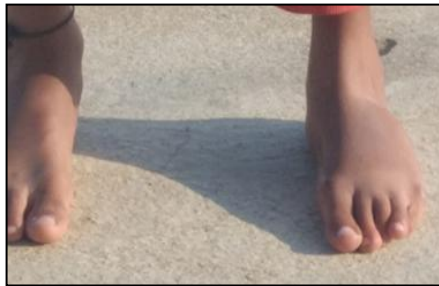

Fig 14: Final Post OP results

Conclusion

Neglected CTEV still exist in world even after availability of the medical services a root level. The reason as a hindrance between care giver and the patients can be inadequate timely diagnosis, inadequate counseling and motivation of parents to seek treatment, associated myths with the deformity and the plaster application. Proper training of primary care givers like Health workers and mid wives to diagnose problem early after birth, educate parents and refer them to the concern doctors will definitely decrease such incidences.

References

1. Ponseti IV. Treatment of congenital clubfoot. *J Bone Joint Surg (Am)*. 1992; 74:448-54.
2. Penny JN. The neglected clubfoot. *Techn Orthop*. 2005; 20(2):153-166.
3. Ganger R, Radler C, Handlbauer A, Grill F. External fixation in clubfoot treatment – a review of the literature. *J Pediatr Orthop B*. 2012; 21(1):52-58.
4. Ferreira RC, Stefani KC, Fonseca Filho FF, Santin RA. Correção do pé torto congênito inveterado e recidivado pelo método de Ilizarov. *Rev Bras Ortop*. 1999;

34(9/10):505-512.

5. Carroll NC, McMurtry R, Leete SF. The pathoanatomy of congenital clubfoot. *Orthop Clin North Am*. 1978; 9:225-32.
6. Shinde A, Kamble S, Shah S, Shinde R. A clinical study of ligamentoaxis using an external fixator, modified frame in the management of a neglected, relapsed, resistant older congenital Talipes Equinovarus child. *Med J DY Patil Univ*. 2013; 6:274-80.
7. Fernandes RM, Mendes MD, Amorim R, Preti MA, Sternick MB, Gaiarsa GP. Surgical treatment of neglected clubfoot using external fixator. *Rev Bras Ortop*. 2016; 51(5):501-508.
8. De la Huerta F. Correction of the neglected clubfoot by the Ilizarov method. *Clin Orthop Relat Res*. 1994; (301):89-93.
9. Rosman M, Brown K. Preoperative Ilizarov frame construction for correction of ankle and foot deformities. *J Pediatr Orthop*. 1991; 11:238-40.
10. Kirienko A, Villa A, Calhoun JH. Taylor & Francis; Philadelphia, PA. Ilizarov technique for complex foot and ankle deformities, 2004.
11. Ganger R, Radler C, Handlbauer A, Grill F. External fixation in clubfoot treatment – a review of the literature. *J Pediatr Orthop B*. 2012; 21(1):52-58.
12. Makhdoom A, Qureshi PA, Jokhio MF, Siddiqui KA. Resistant clubfoot deformities managed by Ilizarov distraction histogenesis. *Indian J Orthop*. 2012; 46(3):326-32.