



International Journal of Orthopaedics Sciences

E-ISSN: 2395-1958
P-ISSN: 2706-6630
IJOS 2019; 5(4): 310-313
© 2019 IJOS
www.orthopaper.com
Received: 14-08-2019
Accepted: 18-09-2019

Dr. D Ganesh
Post Graduate in Orthopaedics,
Rajah Muthiah Medical College
& Hospital, Annamalai
University, Tamil Nadu, India

Dr. R Neelakrishnan
Professor and Head, Department
of Orthopaedics, Rajah Muthiah
Medical College & Hospital,
Annamalai University, Tamil
Nadu, India

Dr. V Barathiselvan
Assistant Professor, Department
of Orthopaedics, Rajah Muthiah
Medical College & Hospital,
Annamalai University, Tamil
Nadu, India

Dr. PS Balamurugavel
Assistant Professor, Department
of Orthopaedics, Rajah Muthiah
Medical College & Hospital,
Annamalai University, Tamil
Nadu, India

Dr. K Parasuraman
Assistant Professor, Department
of Orthopaedics, Rajah Muthiah
Medical College & Hospital,
Annamalai University, Tamil
Nadu, India

Dr. R Ravikrishna
Assistant Professor, Department
of Orthopaedics, Rajah Muthiah
Medical College & Hospital,
Annamalai University, Tamil
Nadu, India

Corresponding Author:
Dr. R Neelakrishnan
Professor and Head, Department
of Orthopaedics, Rajah Muthiah
Medical College & Hospital,
Annamalai University, Tamil
Nadu, India

Analysis of displaced middle third clavicular fractures treated by anatomical locking plate

Dr. D Ganesh, Dr. R Neelakrishnan, Dr. V Barathiselvan, Dr. PS Balamurugavel, Dr. K Parasuraman and Dr. R Ravikrishna

DOI: <https://doi.org/10.22271/ortho.2019.v5.i4f.1691>

Abstract

Introduction: Fracture of the clavicle is common, accounting for 5 to 12% of all fractures. Displaced mid shaft clavicle fractures are common and are usually treated non-operatively. Open reduction and fixation with anatomical locking plating offers rigid fixation, early functional restoration.

Materials and Methods: The study performed in our hospital based totally on outcome of 25 cases of displaced mid third clavicular fractures, internally fixed through anatomical locking plate which was undertaken on the Department of Orthopaedics and Traumatology at Rajah Muthiah Medical College and Hospital, Annamalai University, Chidambaram.

Results: Out of 25 cases 16 cases united in fourteen weeks and by way of 18 weeks all cases united besides one. In one case there was nonunion because of infection. In our study 22 patients back to day to day activities after 8 weeks and 3 Patients after 12 weeks.

Conclusions: In our study open reduction and internal fixation of displaced midshaft clavicular fractures with anatomical locking plate have given fracture union and excellent outcome.

Keywords: Clavicle, anatomical locking plate, constant Murley shoulder score

Introduction

Fracture of the clavicle is common, accounting for five to twelve% of all fractures. About eighty to 85% of these fractures are in the middle third of the bone, wherein forces implemented to the shoulder and the narrow segment of the bone combines and bring about bony failure. Displaced mid shaft clavicle fractures are not unusual and are commonly treated non-operatively. Non-operative management of these fractures with axial shortening is associated with non union, delayed union, and symptomatic malunion^[1]. Other pitfalls are pain, neurological complications, loss of shoulder characteristic and protuberant callus forming swelling and stretching of skin that's cosmetically unacceptable.

Prompt fixation of unstable clavicle fractures gives patient comfort, and early shoulder mobility. If the patients have excessive physiological needs after surgical treatment, excessive pain, or desire for surgical operation early plate fixation gives advantages. In cases of related scapula fractures, fixation of the clavicle offers restoration of shoulder mechanics leading to good outcome. Operative treatment of displaced mid shaft clavicular fractures can be done effectively with the usage of plates or intramedullary implants like titanium elastic nails. Intramedullary nailing has disadvantages like nail breakage, nail migration, medial and lateral perforation, nail dislocation. Reconstruction plate were compared with intramedullary nailing and found to give rigid fixation but needs a 3 dimensional bending of the plate by the operating surgeon. Then locking compression plates were compared which gives good functional results. In recent studies a precontoured anatomical locking plate placed superiorly was compared with anteroinferior plating. Open reduction and internal fixation with superiorly placed anatomical locking plating provides stable fixation, early functional return, very low rates of non union.

Materials and Methods

The study carried out was time certain, hospital based, prospective study. In this study we analyze the results of 25 cases of closed displaced mid third clavicular fractures, internally

fixed through anatomical locking plate which was undertaken in the Department of Orthopaedics and traumatology at Raja Muthiah Medical College and Hospital, Chidambaram from June 2018 to Oct 2019

Patients with age among 18 years to 60 years and clavicle fractures with displacement of more than 2cm, shortening of greater than 2cm, fractures with comminuted fragments, segmental fractures, open fractures and impending compound fracture with tissue compromise are covered in our study. Patients with age of much less than 18 years, undisplaced or minimally displaced fractures and any medical contraindication to surgery (Heart illnesses, renal failure or lively chemotherapy) are excluded.

On admission resuscitation of the patients in the emergency room executed followed by radiographic examination was done which included the three-view trauma series of the shoulder devised by Neer and Rockwood. Radiographs of the chest were performed routinely to detect any concomitant fractures of the ribs, pneumothorax or hemothorax.

Operative Procedure

Under anesthesia the patient was placed in supine with sand bag in between the scapulae. Keeping the sand bag allows the shoulder girdle to fall backward. It restores the length and increases the exposure to clavicle. We made an incision alongside the axis of the clavicle, centering the fracture site. Subcutaneous tissue with platysma incised together and were mobilized. This will prevent implant prominence after wound closure. Myofascial layer incised and elevated from the fracture ends for exposure. After that fracture ends cleared of hematoma, fracture reduced using bone clamps. If there was a comminuted wedge fragment, it was fixed with a lag screw either through the plate or separately. Anatomical clavicular locking plate was used. The Plate is placed over the superior surface of the clavicle often restores rotation. Once the fracture alignment, length and rotation have been fine the screws had been inserted. Minimum of six cortical purchases attained on both segment of the fracture. The myofascial layer then skin and subcutaneous tissue sutured and immobilized in a shoulder immobilizer.

Rehabilitation of the affected arm commenced on the 3rd post operative day onwards. Gentle pendulum exercises to the shoulder in arm pouch were allowed. At 2 to 3 weeks gentle energetic range of motion of the shoulder was allowed however abduction is confined to 80 degrees. At 6 to 8 weeks active range of motion in all planes were allowed.

Results

In our study 25 cases of displaced mid third clavicular fractures have been fixed with anatomical locking plate. In our study of 25 cases 19 patients are male and 6 patients are woman. Age of the affected person varies from two decades to 50 years and maximum of them have been between 20 years to 30 years. Mean follow up was 12 months. Of the 25 patients 18 patients sustained injury to the right side and 7 patients on left side. In most of the cases road traffic injuries (19 cases) predominate followed by unintended fall. Regarding the mechanism the fall on outstretched hand (18 cases) followed by direct impact. The direct impact was associated with fragmentation on the fracture site. The time of presenting to hospital varies from 1 hour to 7 days with common time of 20 hours. The average period of surgical treatment was 50 minutes. The common blood loss throughout the surgical operation turned into less than 100ml. In our study out of the 25 cases 16 were united in 14 weeks

and by way of 18 weeks all of the cases united except one case. In our study 22 patients back to day to day activities after 8 weeks and three patients returned to work after 3 months. We had complications of hard ware irritation in one case, infection in another case. 2 patients had screw pullout. One nonunion and no refracture in our patients. We removed the plate and screws in 1 case after infection.

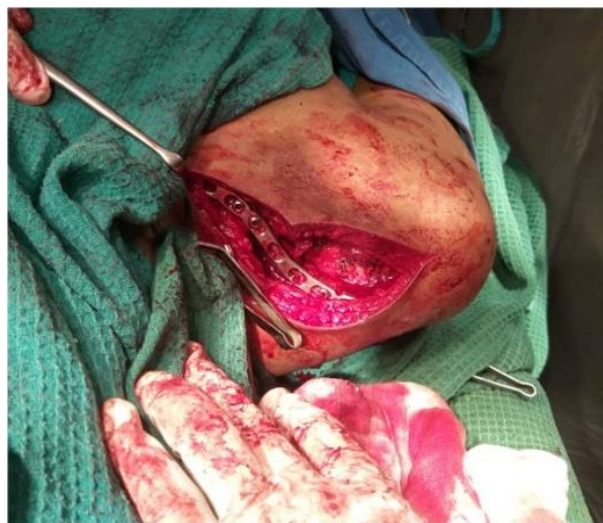

Fig 1: Intra operative photograph showing fixation with locking compression plate.

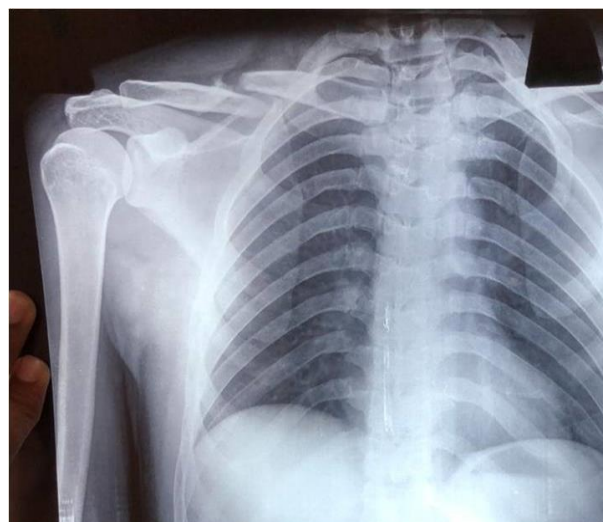


Fig 2: Pre operative x ray displaying fracture clavicle right side

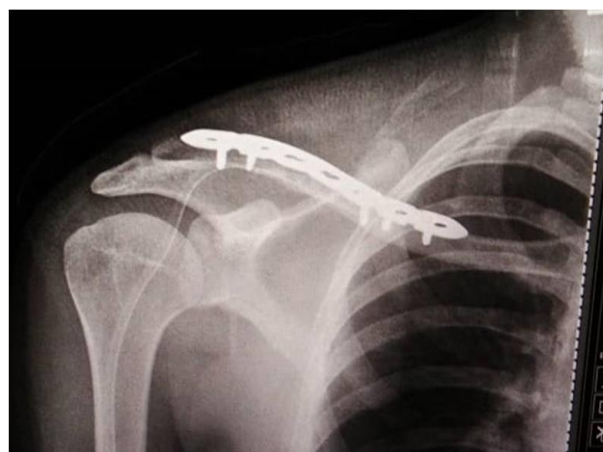

Fig 3: Post operative x ray displaying fracture clavicle proper facet fixed with locking plate.

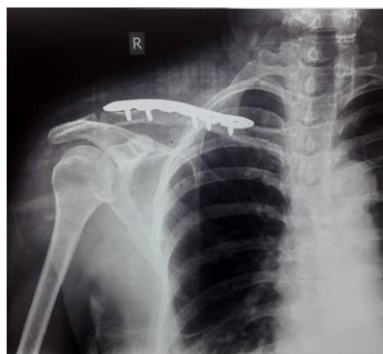

Fig 4: Follow up x ray showing fracture union clavicle proper aspect

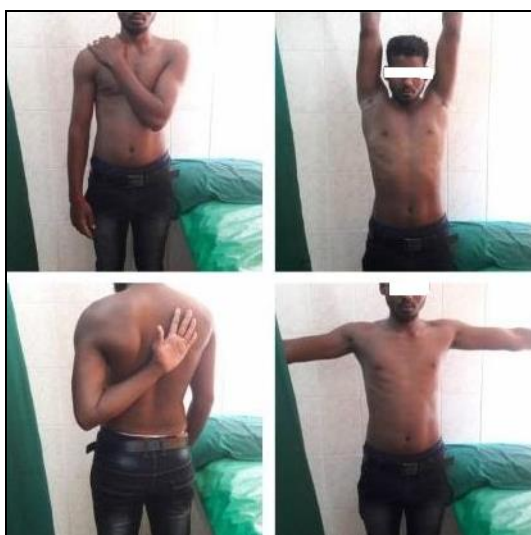

Fig 5: Follow up range of movements.

The mean time of union was 12.76 weeks.

Table 1: Time of Union

Time of Union	No. of Patients
10 weeks	02
12-14 weeks	14
16	6
18	2

Table 2: Complications

Hard ware prominence	1
Screw pullout	2
Infection	1
Delayed union	0
Nonunion	1
Mal union	0
Hard ware failure	0
Re fracture	0

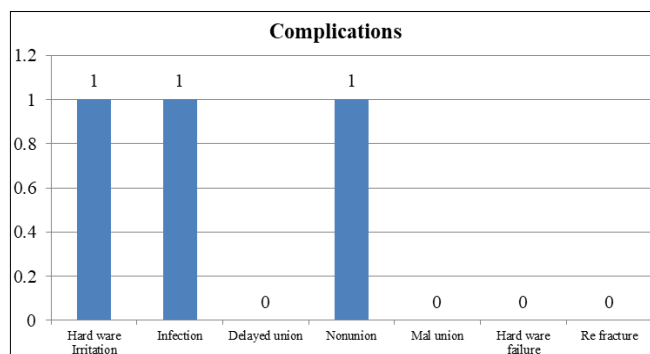


Chart 1: Complications

Discussion

Clavicle is the bony link from thorax to shoulder girdle and contributes to movements at shoulder girdle. Clavicle fracture is a not unusual disturbing injury around shoulder girdle because of their subcutaneous position [2]. It is due to either low- or high-energy effect. The management on clavicle fracture are first introduced by ancient Egyptians. Many non operative techniques of treatment for clavicle fractures were described despite the fact that a sling continually gave useful outcome. The traditional view that maximum of clavicular fractures heal with acceptable results following non operative treatment is now not valid [3]. Recent studies have showed nonunion and shoulder dysfunction in subgroups of patients with clavicle fractures [6, 7]. Because of this, these fractures should therefore be considered as a spectrum of injuries requiring cautious evaluation and individualized care. In the beginning clavicle fracture is given little importance and normally treated conservatively. But in the present fast moving world, morbidity as a result of clavicle fracture is a point of concern.

In a study by Hill [1] 31% results were unsatisfactory when mid third clavicle fractures were treated conservatively and 54% have cosmetic problems. Also shortening occurs when these fractures were treated conservatively.

The previous studies of outcome following clavicular fractures did not describe any power deficits following Nonoperative treatment of displaced mid shaft clavicular fractures and focused on radiographic and health care provider based results.

In a study performed by Canadian Orthopaedic trauma society on 111 patients of fracture clavicle confirmed not only improvement in shoulder function (at 365 days) in operated cases, but also early return of function and reduction in pain within the operative group.

The most predictable method to maintain anatomic reduction of displaced mid shaft clavicular fractures, which include length and rotation is in our opinion a plate and screw fixation. The choice to proceed with operative intervention for a displaced mid-shaft clavicular fracture might be a decision made between the surgeon and the affected person. So there is specific indication like displacement > 2cm, with or without comminution, shortening > 2cm middle third clavicle fracture (Robinson Type-2B1, 2B2).

The patients treated with early, stable fixation of clavicle fractures had a good postoperative constant score, early pain relief and early return to work and high patient satisfaction [9]. Plating has the benefits of retaining the length in particular in comminuted fractures. There is little risk for hard ware irritation.

In cases of clavicle fractures with more fragments we can put the plate as bridge plating otherwise known as biological plating. This lets in the indirect fracture healing with preservation of blood supply and soft tissue attachments while bridging the fracture site retaining the length, alignment and rotation.

Clavicle nailing [10] is a choice for mid third clavicle fractures. Intra medullary nailing is difficult in clavicle because of the anatomical form. Nailing has the advantages of less soft tissue dissection and periosteal disruption. The risks are no static locking is available, hard ware can break, nail migration, migration results in breakdown of skin or infraclavicular structure injury and in comminuted fracture shortening occurs over time.

The association of ipsilateral fracture of the clavicle and scapular neck has historically been called the “floating

shoulder". It is considered as an unstable injury and might require operative fixation. If operative intervention is selected, then anatomic reduction and internal fixation of the clavicle is done and the shoulder is then reimaged. If the fixation bring about indirect reduction of the glenoid no additional intervention is required. If the glenoid stays in unacceptable position then fixation of glenoid neck is needed. In our study the clavicle fracture are more common in male than females. There had been 19 male and six female patients. In our study right clavicle is involved more than left side.

In our study the average age group was 27.5 years.

In our study Road Traffic Accident was the most common cause for clavicle fractures. Fall on out stretched hand was the common mechanism of injury. We studied the fracture pattern (intra operative finding based on mode of injury and mechanism), from this Robinson type 2b2 (comminuted mid shaft fracture) is most common. In our study the common time taken for surgery was less than one hour. Average blood loss was much less than 100ml.

The average time of union turned into 12.76 weeks. Most of our patients return to work by 3 months. We assessed the outcome by constant score. In our study 2 had hard ware irritation due to screw pull out. There is no re fracture. One case had deep infection managed with implant removal, wound wash and antibiotics.

Superior plating^[4] has the advantage of plating over antero inferior plating. Superior plating^[11, 12] is the better method when there is inferior cortical comminution. We did superior plating which has less hardware irritation.

In our study we used anatomical locking compression plate. Patients where anatomical locking compression plate was used returned early to daily day to day activities. Anatomical Locking compression plate affords better biomechanical stability^[5, 8, 13]. So it is most desirable implant of choice in fractures with inferior cortical defects. Precontoured anatomical plates permits reduction to be maintained, improves the rates of union and gives good functional outcome. Low profile locking plates decrease the soft tissue irritation.

Conclusion

In our study Open reduction and rigid internal fixation of displaced midshaft clavicular fractures with anatomical locking plate resulted in good union and satisfactory functional results. Interfragmentary screws may be used wherever needed. All patients except one who got infection due to high blood sugar values showed an early return to daily activities and work. So we recommend the usage of anatomical locking plate for stable fixation of displaced middle third clavicle fractures. For a diabetic patient there should be a adequate control before surgery and the anatomical locking plate should be used very cautiously.

References

1. Hill JM, McGuire MH, Crosby L. Closed treatment of displaced middle-third fractures of the clavicle gives poor results. *J Bone Joint Surg (Br)*. 1997; 79:5.
2. Amit Bernat. Toon Huysmans the Anatomy of the Clavicle: A Three-dimensional Cadaveric Study clinical anatomy. 2014; 27:712-723.
3. By Michael D. Mckee, Deficits Following Nonoperative Treatment of Displaced Midshaft Clavicular Fractures. *The Journal of Bone & Joint Surgery· JBJS. Org.*, 2006, 88-A(1).
4. Ahsan Wani M, Mushtaq Ahmed Ganaie, Nuzhat Ul

- islam, Akther Rasool. Nisar Ahmed Dar Functional results of clavicle fractures in adults treated by open reduction and internal fixation using superior precontoured plate *International Surgery Journal Wani MA et al. Int. Surg J*. 2019; 6(7):2484-2490.
5. Tarun Goswami *et al*. Biomechanical evaluation of a pre-contoured clavicle plate (*J Shoulder Elbow Surg*. 2008; 17:815-818.
6. Robbin C. McKee others Operative Versus Nonoperative Care of Displaced Midshaft Clavicular Fractures: A Meta-Analysis of Randomized Clinical Trials *J Bone Joint Surg Am*. 2012; 94:675-84.
7. Cesare Faldini *et al*. Nonoperative treatment of closed displaced midshaft clavicle fractures *J Orthopaed Traumatol*. 2010; 11:229-236.
8. Tania Reisch *et al*. The first 100 patients treated with a new anatomical pre-contoured locking plate for clavicular midshaft fractures Reisch *et al*. *BMC Musculoskeletal Disorders*. 2019; 20:4.
9. Robinson CM *et al*. open reduction and plate fixation versus non operative treatment for displaced midshaft clavicular fractures *JBJS*. 2013; 95:1576-84.
10. Jamal EH. Assobhi Reconstruction plate versus minimal invasive retrograde titanium retrograde elastic nail fixation for displaced midclavicular fractures *J Orthopaed Traumatol*. 2011; 12:185-192.
11. Nathan Formaini *et al*. superior versus anteroinferior plating of clavicle fractures July, 2013, 36, haelio.com
12. Sinha A *et al*. A radiological study to define safe zones for drilling during plating of clavicle fractures *JBJS*. 2011; 93_B:1247-52.
13. Alexander Van Tongel *et al*. evaluation of straight plates and precontoured clavicle plates using automated plate to bone alignment *actaorthop, Belgium*. 2014; 80:301-308.