



ISSN: 2395-1958
IJOS 2019; 5(3): 815-821
© 2019 IJOS
www.orthopaper.com
Received: 16-05-2019
Accepted: 20-06-2019

Dr. Sandeep Roy
Senior Resident, North Bengal
Medical College, Sushrutanagar,
Siliguri, Darjeeling, West
Bengal, India

Dr. Rajeeb Banik
Assistant Professor Department
of Orthopaedics, North Bengal
Medical College, Sushrutanagar,
Siliguri, Darjeeling, West
Bengal, India

A comparative study between proximal femoral nail and proximal femoral locking plate in subtrochanteric femoral fractures: A prospective analysis of 36 cases

Dr. Sandeep Roy and Dr. Rajeeb Banik

DOI: <https://doi.org/10.22271/ortho.2019.v5.i3n.1632>

Abstract

Background: Subtrochanteric fractures constitute 10-30% of the hip fractures. Various implants were used to fix the fractures. Proximal femoral locking plate (PFLP) allows either direct anatomic reduction or indirect reduction and bridge plating techniques. Due to biomechanical advantage proximal femoral nails (PFN) have found superior to other implants.

Objectives: To compare the Radiological and Functional Outcome of Subtrochanteric Fractures treated with proximal femoral nail (PFN) and Proximal femoral locking plate (PFLP) and to find out the more appropriate implant for the specific fracture pattern.

Methods: 36 patients with Subtrochanteric femur fracture were operated and fixed by proximal femoral nail and proximal femoral locking plate (18 in each group). Follow up done for 24 months. Outcome was assessed by Harris Hip Score (HHS) and radiologically.

Results: The patients treated by proximal femoral nailing required significantly less time for full weight bearing (16.06 weeks) as compared to the patients treated by proximal femoral locking plate (21.41 weeks). Radiological union was significantly delayed in the patients treated by proximal femoral locking plate (mean time 21.41 weeks) as compared to the patients treated by proximal femoral nailing (16.39 weeks). Nailing group had slightly better average HHS (93) than in the plating group (89.44).

Conclusion: PFN have the advantage by taking less operative time, high rate of union, minimal soft tissue damage, less infection rate and early postoperative rehabilitation. In our study we found that both PFN & PFLP can be satisfactorily used in the treatment of Subtrochanteric fractures. There was significantly no major difference between implants with respect to anatomical alignment, limb length discrepancy, postoperative infection and most importantly the final outcome measured by Harris Hip Score.

Keywords: Subtrochanteric fractures, proximal femoral nail (PFN), proximal femoral locking plate (PFLP)

1. Introduction

Subtrochanteric fractures are generally defined as those fractures occurring within 5 cm of the distal extent of the lesser trochanter ^[1] and constitute 10-30% of the hip fractures. These fractures occur in three specific patient populations: Young patients involved in high-energy trauma, older osteoporotic patients involved in low-energy trauma, and patients exposed to chronic or high-dose bisphosphonate therapy due low energy trauma and also been reported as spontaneous fractures ^[2]. The mechanical stresses at this level are very high, as they occur at the junction between the trabecular and cortical zone and also because of the deforming forces due to peculiar muscle insertion to the proximal and distal fragments which are difficult to control. Surgical management of these fractures and the surgical implants has gone through an array of changes in their procedures and designs. Various upper femoral devices like 95° fixed angle device dynamic condylar screw, dynamic hip screw with barrel plate, gamma nail, proximal femoral nail, proximal femoral locking plate. etc are being used by various centres and each centre claims reasonably satisfactory results with each type of device ^[3, 4]. Intramedullary nails has its specific set of advantages, namely shorter operating times and less blood loss, as well as lower rates of infection, non-union, and implant failure ^[5, 6, 7]. Nails have a biomechanical advantages given their intramedullary location ^[8].

Correspondence
Dr. Rajeeb Banik
Assistant Professor Department
of Orthopaedics, North Bengal
Medical College, Sushrutanagar,
Siliguri, Darjeeling, West
Bengal, India

That decreases bending stresses, varus angulation, and prevents shaft medialization. As a result of these advances, recent studies of subtrochanteric femur fractures fixed with intramedullary nails have demonstrated high union rates and a low incidence of complications^[9,10].

Proximal femoral locking plates have been successfully used to treat selected subtrochanteric fractures and avoid many of the problems encountered during nailing¹¹. The use of these implants allows either direct anatomic reduction with internal fixation or indirect reduction and bridge plating techniques.

2. Materials & Methods

The study was performed after obtaining the approval from departmental committee, scientific review committee & institutional ethics committee of North Bengal Medical College & Hospital.

Patients admitted with Subtrochanteric fractures satisfying the inclusion criteria in the Department of Orthopaedics, NBMC&H during the study period.

3. Inclusion criteria

- Displaced Subtrochanteric fractures Russel Taylor type 1a & 1b.
- Patients in the age group 20-80 years.

4. Exclusion criteria

- All infected open fractures.
- Patients having medical co-morbidities.
- Patients who have refused surgical consent.
- Hemiplegic or quadriplegic patients.
- If associated with other fractures of ipsilateral femur.
- Fractures extending to the pyriform fossa.

Study period was two year (May 2016 - April 2018). Total 36 patients were selected for this study. The patients were classified into two groups:

Group A- Patients treated with Proximal Femoral Intramedullary Nailing

Group B- Patients treated with Proximal Femoral Locking Plate

5. Surgical technique

5.1 Technique of proximal femoral nail

After positioning the anaesthetized patient supine on fracture table closed reduction of fracture is performed. The uninjured limb is held in well leg holder so that it remains out of the way. Reduction is achieved by aligning distal fragment to flexed and externally rotated proximal fragment by rotating the foot of effected extremity. If Reduction is not achieved with ease, a unicortical 5mm threaded joystick is used to control proximal fragment after draping the patient. If closed reduction is not successful or not acceptable an open reduction is performed. A guide wire is then inserted into proximal fragment & using fluoroscopic assistance the guide wire is passed into distal fragment. Now medullary canal is reamed with reamers of increasing size. The reaming process is continued at 0.5 mm increments until 1mm more than the selected nail size is reached and the proximal fragment entry point is widened with entry point widener. Reaming must be carried out carefully in proximal fragment to avoid further comminution and lateral drift as the proximal nail diameter is 15mm. Loss of lateral portion of greater trochanter due to eccentric reaming precludes good proximal purchase and essential failure of fixation.

The selected nail is then assembled to jig and passed over the

guide wire and pushed manually by rocking movements and the terminal position is hammered to the desired level and anteversion is adjusted by comparing with opposite hip or setting the anteversion of 15°. Now a 3.2mm guide pin is inserted through inferior drill sleeves and checked under image intensifier so that it should be 4mm above the calcar and inferior in the neck. If not the position of nail is adjusted. Now sleeves are placed in proximal hole and guide pin is inserted and the final position of guide pins is checked under image intensifier in both AP & lateral view before drilling. Now the distal screw hole is drilled with 6.4 mm drill up to 5mm of subchondral bone. The length of screw to be inserted is read from calibrations on drill bit and it is tapped up to 5mm of subchondral bone and tapped with 8.0 mm tap and appropriate 8.0 mm screw is selected and inserted into the inferior hole of the nail. Now proximal screw site is drilled with 5.0 mm drill bit and tapped with cortical tap of 6.4 mm and the screw is inserted. Then the distal interlocking screws are inserted by freehand technique. This is checked on fluoroscopy in both anteroposterior and lateral views and appropriately sized screw is selected and inserted. Then the second interlocking screw is also inserted in the same manner.

5.2 Technique for proximal femoral locking plate

After proper anaesthesia and the patient is positioned supine on the fracture table. A lateral approach typically is performed by a straight incision from the greater trochanter, extending approximately 10 cm distally. Length restoration and fracture reduction was done by open method. The proximal fragment is first fixed to the plate, and the plate is then reduced to the femoral shaft. After ensuring perfect anatomic placement of the plate to the proximal fragment, a 2.5-mm drill tip guide wire is inserted through a wire sleeve that is threaded to the most proximal hole at a predetermined 95° angle. A second guide wire is then inserted through the drill sleeve of the second hole in a 120° angle. Finally, a third guide wire is inserted through the sleeve on the third hole above the calcar in a 135° angle. The plate was then distally fixed with bicortical locking head screws. After proper haemostasis a drain was placed at appropriate site and wound was closed in layers. The skin was closed with skin stapler.

Active toe and ankle movements, static quadriceps exercises, started post-operatively. Appropriate antibiotic given & drain removed after 48 hours.

Patient is made to sit on next post-operative day and knee bending exercises started, Stitches removed after two week and partial weight bearing allowed around 10 weeks in nail fixation & 14 weeks in plate fixation.

All patients were followed up at one monthly interval upto 6 months after discharge, then at 12 & 24 month. Final scoring was done by Harris Hip Score (HHS).

HHS has four components. Pain, function, functional abilities & physical exam. Maximum score of HHS is 100. Scores are categorized as follows: 0 - 69 poor, 70 - 79 fair, 80 - 89 good, 90 - 100 excellent.

6. Plan for the analysis of data

All data were entered in the excel sheet and were calculated with appropriate statistical method. The statistical analysis consisted of descriptive statistics (Percentage, range, mean, standard deviation) using the standard methods. The comparison of the variables between both treatment modalities was done using the chi-square test for the categorical variables and the student t test for the independent

samples in case of numerical variables.

7. Results and Analysis

In total, 36 patients of the subtrochanteric fractures falling within the inclusion criteria, who underwent treatment with either Proximal Femoral nail or Proximal Femoral Locking Plate in the department of Orthopaedic surgery, NBMCH, were studied.

The patients included in the series had an average age of 37.80 years. The mean age of the patients in group A was 38 years while that in group B was 37.61 years.

Male: female ratio was 1.4: 1

The number of patients treated with proximal femoral nail and the number of patients treated with proximal femoral locking plate were 18 in number each.

Group A included 11 male and 7 female patients and Group B included 10 male and 8 female patients.

The commonest mechanism of injury was found to be high energy (88.88%).

The commonest fracture pattern was Russel Taylor type 1B (72.22%).

Table 1: Distribution of fractures according to Russell Taylor classification

Russell Taylor type	Group A	Group B	P Value
1A	6	4	0.494
1B	12	14	
Total	18	18	

We can see that Pierson chi square coefficient is 0.488 and the p value is 0.494, therefore the two groups are similar with respect to the type of fracture.

Proximal femoral nailing required significantly shorter operative time as compared to the operative time required to do proximal femoral locking plate.

Table 2: Table showing the operative time in both the groups

	Operative time (Minutes)	P value
Group A	86.94 +/- 12.144	0.002
Group B	101.94 +/- 15.063	

Table 2 shows that the mean operative time in the group A patients was 86.94 min as compared to 101.94 min in the patients of group B (p value .002). This shows a statistically significant shorter operative time in the patients treated with proximal femoral nailing as compared to the patients treated with proximal femoral locking plate.

Table 3: Table comparing the time of partial weight bearing, complete weight bearing and radiological union in both the groups

	Group A	Group B	P Value
Partial Weight Bearing (weeks)	10.67 +/-2.058	14.44 +/-3.110	0.00
Full Weight Bearing (weeks)	16.06 +/- 2.960	21.41 +/-1.970	0.00
Radiological union (weeks)	16.39+/-1.914	21.41+/- 1.970	0.00

Table 3 shows the mean duration of partial weight bearing, full weight bearing and the radiological union in the both the group. From the table we can see that the patient treated with proximal femoral nail required statistically significant less time for partial weight bearing, full weight bearing. Time taken for radiological union is less in proximal femoral nailing as compared to the patients treated with proximal femoral locking plate.

The patients treated by proximal femoral nail were allowed partial weight bearing on an average 10.67 weeks post-surgery whereas the patients treated by proximal femoral locking plate was allowed partial weight bearing on average 14.44 weeks. There is a significantly earlier possibility of partial weight bearing in the patients treated by proximal femoral nailing.

Similarly patients treated by proximal femoral nailing required significantly less time for full weight bearing (16.06 weeks) as compared to the patients treated by proximal femoral locking plate.

Radiological union was significantly delayed in the patients treated by proximal femoral locking plate (mean time 21 weeks) as compared to the patients treated by proximal femoral nailing (16.39 weeks).

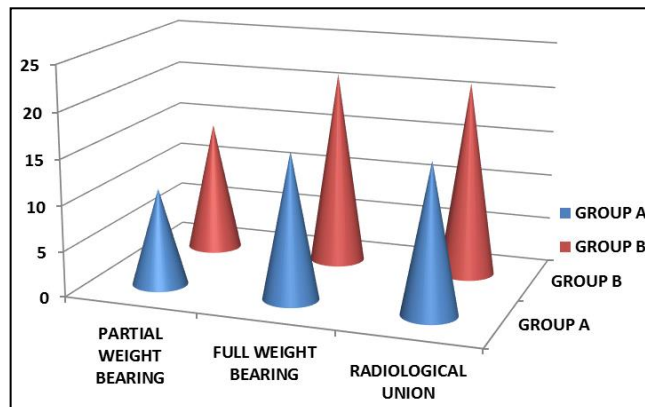


Fig 1: Bar diagram comparing the difference in partial and complete weight bearing and radiological union in both the groups

Table 4: Table comparing the final harris hip score in both the groups at the 24th month follow up

	Mean harris hip score	P value
Group A	93.00 +/- 7.436	0.343
Group B	89.44 +/-13.815	

From the above table we can see that the patients treated with proximal femoral nailing had better Harris hip score as compared to the patients treated with proximal femoral locking plate. However the results were not statistically significant.

Table 5: Comparison of results by harris hip score in both the groups

Result	Group A	Group B
Excellent	72.22% (13/18)	77.77% (14/18)
Good	27.77% (5/18)	11.12% (2/18)
Fair	0% (0/18)	5.56% (1/18)
Poor	0% (0/18)	5.55% (1/18)

Table 6: Anatomical alignment in both the groups

Group		Anatomical alignment		Total	P value
		Imperfect	Perfect		
Group A	Number	3	15	18	0.63
	% in the group	16.7%	83.3%		
Group B	Number	2	16	18	
	% in the group	11.1%	88.9%		
Total	Number	5	31	36	
	% in the group	13.9%	86.1%		

From the above table we can see that there is no statistically significant difference in the results of anatomical alignment,

treated by either of the methods.

Table 7: Table comparing the limb length discrepancy in both the group

Group		Limb length discrepancy		Total	P value
		Absent	Present		
Group A	Number	14	4	18	1.00
	% in the group	77.8%	22.2%		
Group B	Number	14	4	18	
	% in the group	77.8%	22.2%		
Total	Number	28	8	36	
	% in the group	77.8%	22.2%		

From the above table we see that there is no statistically significant difference in the post-operative limb length discrepancy between the two groups

Discussion

Among the femoral shaft injuries subtrochanteric fractures present a peculiar problem of securing effective neutralization of deforming forces. In addition a substantial demand is put on the implant hardware, as the subtrochanteric region of the femur experiences mechanical forces several multiples of the patient's weight. These factors have made subtrochanteric fractures demand special consideration in orthopaedic trauma, because defective union of this fracture can lead to high disability levels for an individual and thereby loss of valuable productive days. Various intramedullary and extramedullary implants are available with their own set of advantages and disadvantages.

The results of the studies has been discussed under the following heading--

1. Preoperative parameters of the subjects, trauma severity and classification, and surgical delay
2. Surgical time
3. Postoperative outcomes and complications

8. Preoperative parameters and patient background

8.1 Age of the patient

The patients included in the series had an average age of 37.80 years (Range 22-62 years). The mean age of the patients in group A was 38 years while that in group B was 37.61 years. From June 2009 to December 2010, a similar study was done in the Department of Orthopaedics and Traumatology, Tire State Hospital, Izmir, Turkey by Kayali, et al ^[12] (2008), where the mean age was 46 years (29-76 years).

Difference in mean ages of the patients in the two groups was not significant (p value=0.922). Thus we find that the age of the patients in the two groups could not have any significant influence on the results of the study.

8.2 Sex of the patient

Majority of the patients in our study are males (58.33%). Proximal femoral locking plate was done more in males (27.77%) than in females (22.22%) & proximal femoral nail was also done more in males (30.55%) as compared to the females (19.44%). There was no any statistically significant difference between the two study groups on the basis of gender.

8.3 Mechanism of injury

In this paper we found that in patients treated, a high energy mechanism of fracture was predominant (88.88%).

High energy mechanism of fracture was more predominant in

the younger age group. In the study conducted by Wei Ting Lee, Diarmuid Murphy, Fareed HY Kagda, Joseph Thambiah ¹³ (2014) most of the patients in the young age group sustained fracture due to the high mechanism injury.

8.4 Fracture pattern

The fracture was classified according to the Russel Taylor classification. Taking into consideration the inclusion criteria the common fracture type overall was 1B (72.22%) as compared to 1A (27.78%). Majority of fractures in group A was 1B (66.67%) as compared to 1A(33.33%). Similarly in group B the majority of fractures belonged to 1B (77.78%) as compared to 1A (22.22%). There was no statistically significant difference between the two groups on the type of fracture.

8.5 Surgical delay

The mean time interval between the admission and the surgery in group A patients was 15.22 days and that of group B was 14.83 days. However the surgical delay between the groups was statistically non-significant.

9. Operative time

The mean operative time required for proximal femoral nailing was 86.94 min as compared to 101.94 min required for proximal femoral locking plating. The patients who underwent proximal femoral nail required significantly shorter operative time as compared to their counterpart.

10. Post-operative outcomes

10.1 Post-operative mobilization

The patients of group A was given partial weight bearing with the help of bilateral axillary crutches after an average interval of 10.67 weeks whereas all the patients of group B was given partial weight bearing after a mean interval of 14.44 weeks.

The patients of group A require significantly less time (p value=0) as compared to the patients of group B for partial weight bearing.

Similarly the patients of group A required significantly less time to bear weight fully (16.06 weeks) as compared to the patients of group B (21.41 weeks).

One of the patients of group A borne full weight on the fractured limb against medical advice before the fracture union was complete. However there was no any complication because of that. One of the patients of group B was not allowed full weight bearing even at 24 weeks due the absence of satisfactory callus formation at the fracture site.

10.2 Radiological union

The patients of group A required on an average of 16.39 weeks for the radiological union & for the patients of group B it was on an average of 21.41 weeks. The results were statistically significant. In the study conducted by Jae Hoon Jang, Jae Min Ahn, Hee Jin Lee, Nam Hoon Moon ¹⁴ (2013) the average time of radiological union treated by proximal femoral locking plate was 5.4 months (21.6 weeks). Similarly in the average time of radiological union in the patients treated by nail was 19 weeks in the study conducted Rahul Kakkar. S. Kumar. A. K. Singh ¹⁵ (2005).

10.3 Harris hip score (HHS)

The patients of group A have a mean score of 93.00. Mirbolook *et.al* ¹⁶(2015) in their study also found similar result. In their study the average and HHS at 24 month follow up was 93.4. The patients of group B had a mean score

of 89.44. R Gokul Nath, Sah Ansari¹⁷ and Harindra Himanshu, Mani Bhushan Prasad, Ajay Kumar Verma, Lal Bahadur Manjhi¹⁸ (2017) also obtained similar HHS at 6 months follow up in the patients treated by proximal femoral locking plate.

Clearly the patients of group A had better results as compared to the patients of group B. However the results were not significant. In Mirbolook *et.al*¹⁶(2015) study, in the follow-up at 6 months after surgery using the locking plate and intramedullary nail, no significant differences were found between the Harris hip score of the two groups.

72.22 % of the patients of the patients of group A had Harris hip score of excellent grade as compare to the 77.77% patients of group B

10.4 Anatomical alignment

15/18 patients in group A had an acceptable alignment and 16/18 patients in group B had acceptable alignment. The data was statistically non-significant.

10.5 Limb length discrepancy

4/18 patients in group A & group B both had limb length discrepancy. However the results of the limb length discrepancy in both the groups was statistically insignificant.

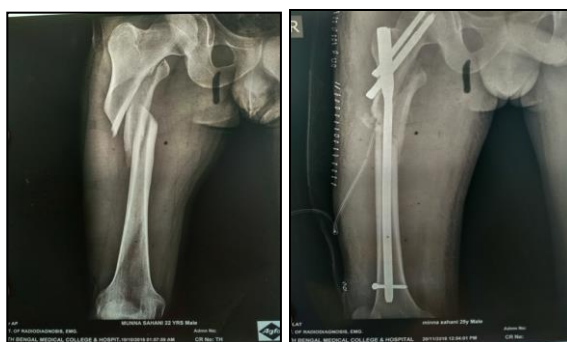10.6 Complication

One patient in proximal femoral nail had superficial infection at the incision site which was treated by debridement and antibiotics based on culture sensitivity. One of the patients of group A had backing of the anti-rotational screw at 8th week follow up which was removed giving a small incision.

Two patients of group B developed superficial infection which was treated by debridement and antibiotics based on culture sensitivity. One of the patients of group B showed absence of callus formation even at 24 weeks.

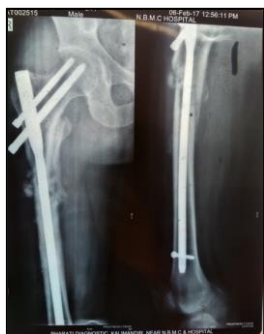X ray & Clinical photographs

Proximal femoral nail in subtrochanteric fracture

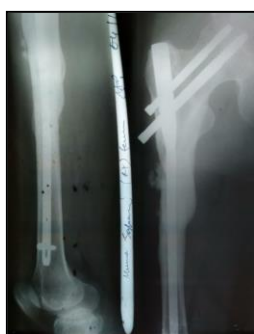

Pre-op X ray

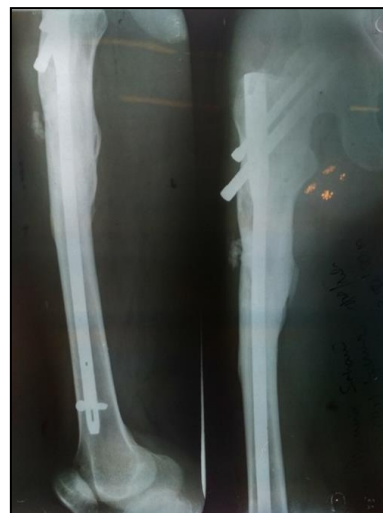Immediate post-op



Follow up after 3 months



Follow up after 12 months

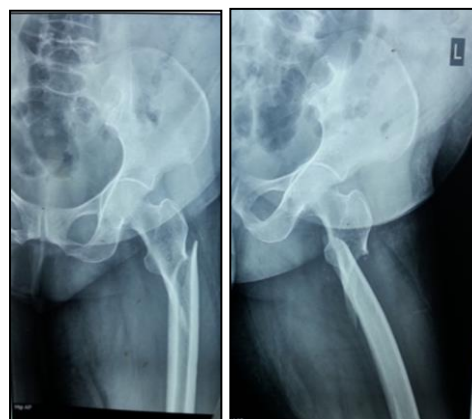

Follow up at 24 month

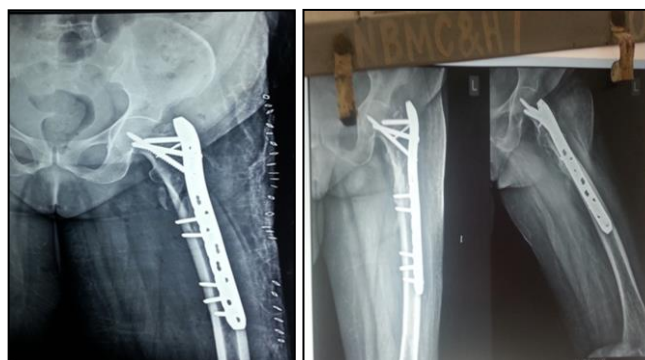

Clinical photograph in a PFN at 6 months post-op

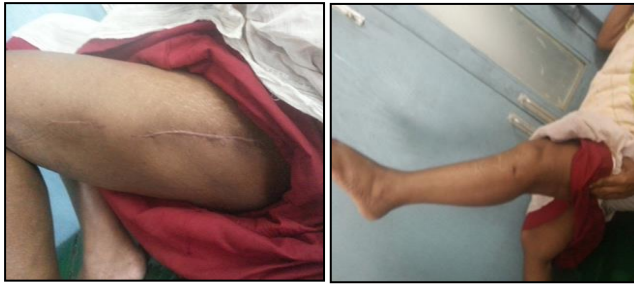Locking proximal femoral plate



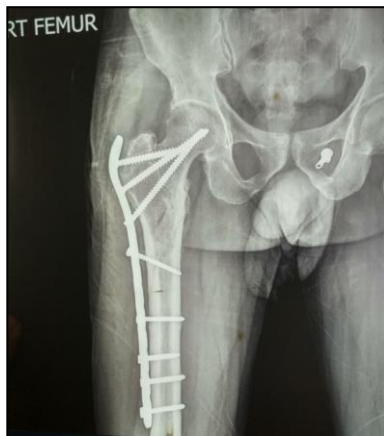Pre op X-ray



Immediate post op Follow up after 6 months



Clinical photograph of PFLP at 6 months of follow up



12 months follow up of Proximal femoral locking plate done in MIPO technique in subtroch femur fracture

11. Conclusion

The incidence of Subtrochanteric fractures of the femur is on the rise because of fast and high speed automobiles and modern lifestyles and increased life expectancy of the elderly age group patients. The deforming forces, high mechanical stresses and morbidity of the fractures in this region have always challenged the ingenuity and skills of the orthopaedic surgeon. Various devices have evolved in an attempt to effectively neutralize these forces.

This study was conducted to compare the results of Subtrochanteric fractures treated with this Proximal Femoral Nail and those treated by proximal femoral locking plate.

In our study we found that both proximal femoral locking plate and proximal femoral nail can be satisfactorily used in the treatment of Subtrochanteric fractures. There was significantly no major difference between implants with respect to anatomical alignment, limb length discrepancy, postoperative infection and most importantly the final outcome measured by Harris Hip Score.

However we found that proximal femoral nailing required shorter operative time as compared to proximal femoral plating. Also, there was significant delay in partial weight bearing, full weight bearing, radiological union in the patients treated with proximal femoral locking plate as compared to

patients treated with the proximal femoral nail.

The limitation of our study was the sample size was less and post operatively follow up was done for only 24 months. Large scale studies with longer follow up are essential requirement for an optimum outcome measurement. Though the study was small which may not represent the whole scenario but the results of the study can be utilized for future large study.

12. References

1. Rockwood and Green's Fractures In Adults, 7th Edition. Philadelphia; Lippincott Williams & Wilkins. 2010, 1641.
2. Thompson RN, Phillips JR, McCauley SH *et al.* Atypical femoral fractures and bisphosphonate treatment: Experience in two large United Kingdom teaching hospitals. *J Bone Joint Surg. Br.* 2012; 94(3):385-390.
3. Nieves JW, Bilezikian JP, Lane JM, Einhorn TA, Wang Y, Steinbuch M *et al.* Fragility fractures of the hip and femur: incidence and patient characteristics. *Osteoporos Int.* 2010; 21(3):399-408.
4. Ekstrom W, Nemeth G, Samnegard E, Dalen N, Tidermark J (Quality of life after a subtrochanteric fracture: a prospective cohort study on 87 elderly patients. *Injury.* 2009; 40(4):371-376.
5. Barquet A, Francescoli L, Rienzi D, Lopez L. Intertrochanteric-subtrochanteric fractures: treatment with the long Gamma nail. *J Orthop Trauma.* 2000; 14:324-8.
6. Lahoud JC, Asselineau A, Salengro S, Molina V, Bombart M. Subtrochanteric fractures. A comparative study between gamma nail and angular osteosynthesis with lateral cortical support [in French]. *Rev Chir Orthop Reparatrice Appar Mot.* 1997; 83:335-42.
7. Van Doorn R, Stapert JW. The long gamma nail in the treatment of 329 subtrochanteric fractures with major extension into the femoral shaft. *Eur J Surg.* 2000; 166:240-6.
8. Luo Q, Fang C, Shen WY, Lau TW, Leung F. A lesson from the failure of intramedullary fixation of atypical subtrochanteric fractures: a report of two cases. *JBJS Case Connect.* 2013; 3(1):1-4
9. Mereddy P, Kamath S, Ramakrishnan M *et al.* The AO/ASIF proximal femoral nail antirotation (PFNA): a new design for the treatment of unstable proximal femoral fractures. *Injury.* 2009; 40(4):428-432.
10. Simmermacher RK, Ljungqvist J, Bail H *et al.* The new proximal femoral nail antirotation (PFNA) in daily practice: results of a multicentre clinical study. *Injury.* 2008; 39(8):932-939.
11. Fielding JW, Magliato HJ. Subtrochanteric Fractures. *Surg., Gynec. Obstet.* 1966; 122:555-560.
12. Kayali C, Ağuş H, Zincircioğlu G. The role of biological fixation with bridge plating for comminuted subtrochanteric fractures of the femur. *Ulus Travma Acil Cerrahi Derg.* 2008; 14(1):53-8.
13. Lee TW, Murphy D, Kagda FH, Thambiah J. Proximal femoral locking compression plate for proximal femoral fractures. *Journal of orthopaedic surgery* 2014; 22(3):287-93.
14. Jang JH, Lee HJ, Moon NH. Surgical outcomes of biologic fixation for subtrochanteric fracture using locking compression plates. *Hip pelvis.* 2017; 29(1):68-76.
15. Kakkar R, Kumar S, Singh AK. Cephalomedullary

- nailing for proximal femoral fractures. *Int Orthop*. 2005; 29(1):21-24.
16. Mirbolook A *et al*. Subtrochanteric Fractures: Comparison of Proximal Femur Locking Plate and Intramedullary Locking Nail Fixation Outcome. *Indian J Surg*. 2015; 77(3):795-9.
 17. Nath RG, Ansari S. Role of proximal femoral plate in the treatment of subtrochanteric fractures; case series. *medpuse international journal of orthopaedics*. 2017; 3(1):01-07.
 18. Himanshu H, Prasad MB, Majhi LB. Proximal Locking Plate: An alternative implant for unstable proximal femoral fractures, *Iosr journal of dental and medical sciences*. 2017; 16(1):07-14.