

ISSN: 2395-1958
IJOS 2019; 5(3): 757-761
© 2019 IJOS
www.orthopaper.com
Received: 16-05-2019
Accepted: 20-06-2019

Dr. Vinod Kumar Singh
Professor, Department of
Orthopedics, AN Medical College
& Hospital, Gaya, Bihar, India

Posterolateral instability of elbow following radial head excision: A retrospective cross sectional study

Dr. Vinod Kumar Singh

DOI: <https://doi.org/10.22271/ortho.2019.v5.i3m.1622>

Abstract

Purpose: To study the occurrence of posterolateral instability of elbow joint following radial head excision in patients with radial head fracture and to determine the coexisting condition which contributes to instability.

Methods: A retrospective cross sectional study designed to assess the occurrence of posterolateral instability of elbow following radial head excision. 30 patients who had undergone radial head excision for Masons type 2, 3, and 4 fracture between March 2010 to July 2018 were included in the study. On their follow up visit persistent symptom of elbow pain, signs of elbow instability (pivot shift test and chair push up test), mayo elbow score and radiological features were assessed for diagnosing the posterolateral instability of the elbow.

Results: Of the 30 patients evaluated 2 of them had associated ulnar fracture and 1 had elbow dislocation. All 3 complained of pain and discomfort at the elbow joint. Pivot Lateral shift test and chair push up test were positive in these 3 cases, with an average Mayo elbow score of 70 in these 3 patients. The average arc of motion among these 3 patients ranged from 5° to 120° with pronation being 88° and supination of 86° as compared to the ones without instability. Two of the three patients showed radiological features of instability.

Conclusion: Most radial head fractures treated with radial head excision have good outcome clinically, provided it is not associated with any concomitant injury of the elbow and if immobilized properly for minimum of 3 weeks post-surgery to allow for soft tissue healing. A small proportion of patients who have concomitant elbow dislocation or ulna fracture with persistent elbow pain, should undergo further clinical and radiological evaluation in the form of MRI and decision should be taken regarding need for ligament reconstruction or radial head replacement. Hence existence of elbow dislocation or proximal ulna fracture should be a red flag sign for increased chances of posterolateral instability of the elbow.

Keywords: radial head excision, posterolateral instability, lateral pivot shift test

1. Introduction

Radial head fracture form about 30% of all elbow fractures [1]. Radial head fractures are many times subtle and can be easily missed in a busy set up. Radial head fracture may also be associated with dislocation, or concomitant ulna fracture or distal humerus fracture. Many time lateral or medial collateral ligament injuries may also coexist and might be missed.

The elbow is a trochleoginglymoid joint and consists of 2 primary motions: the ulnohumeral articulation is hinged- ginglymoid, and the radiocapitellar articulation is radial-trochoid. Distal humerus is composed of 2 articulations: the trochlea, along the long axis of the distal humerus, and the capitellum, a hemispheric structure lateral to the trochlea. The trochlea has a slight posterior tilt that prevents posterior translation by depending on the coronoid buttress [2, 3]. The proximal ulna consists of 2 articulations, the greater and lesser sigmoid notch. The trochlea and greater sigmoid notch have highly congruent anatomy and form 180 degree of articular contact during elbow range of motion. The lesser sigmoid notch articulates with the margin of the radial head at the proximal radioulnar joint. The radial head is a concave elliptical structure, covered with cartilage along the radiocapitellar joint and approximately 270 degree of the articular margin; it articulates with both the capitellum and the lesser sigmoid notch. The coronoid process of the proximal ulna forms anterior and varus buttress of the elbow composed of tip, body, anterolateral facet, and anteromedial facet [3, 5].

Soft tissue anatomy: The collateral ligaments of the elbow are medial and lateral capsular

Correspondence
Dr. Vinod Kumar Singh
Professor, Department of
Orthopedics, AN Medical College
& Hospital, Gaya, Bihar, India

thickenings that provide increased stability. The MCL, also known as the ulnar collateral ligament, made of 3 ligamentous portions: anterior bundle (AMCL), posterior bundle, and transverse ligament (Cooper ligament). The AMCL and the

posterior bundle originate from the anteroinferior medial epicondyle of the elbow. This origin lies behind the axis of the elbow, and therefore, elbow flexion increases ligament tension.

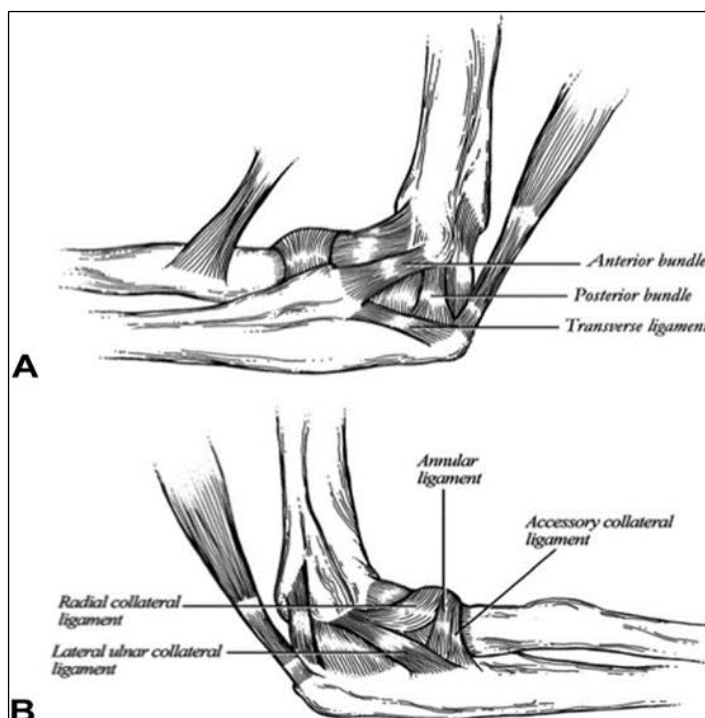


Fig 1: Medial and lateral ligamentous stabilizers of the elbow. A MCL complex. B LCL complex. (From Total elbow arthroplasty design. In: Williams GR, Yamaguchi K, Ramsey ML, et al, eds. *Shoulder and Elbow Arthroplasty*. (Philadelphia, Lippincott Williams & Wilkins, 2005:303)

The AMCL inserts at the sublime tubercle on the coronoid and the posterior bundle inserts on the medial olecranon [2, 5]. The lateral collateral ligament (LCL) is a complex with 4 primary ligamentous portions: Lateral ulnar collateral ligament (LUCL), radial collateral ligament (RCL), annular ligament, and accessory collateral ligament. The LUCL and RCL originate from an isometric point on the inferior surface of the lateral epicondyle, providing consistent tension through elbow motion. The LUCL attaches to the supinator crest of the proximal ulna and is a restraint to varus and posterolateral rotatory instability (PRLI). The annular ligament encircles the radial head and attaches to the anterior and posterior margins of the lesser sigmoid notch. The RCL attaches to the annular

ligament to stabilize the radial head. Muscles crossing the elbow compress the elbow joint, increasing the osseous stability of the elbow and functioning as dynamic constraints. The anconeus deserves specific attention because it is a major dynamic constraint to varus and PRLI [7, 8].

Classification of radial head fracture Mason’s criteria [9]

- Type 1:** Undisplaced radial head fracture
- Type 2:** Displaced fracture involving >30% but < 50% of the radial head
- Type 3:** Displaced comminuted radial head fracture
- Type 4:** Radial head fracture with ulno-humeral dislocation

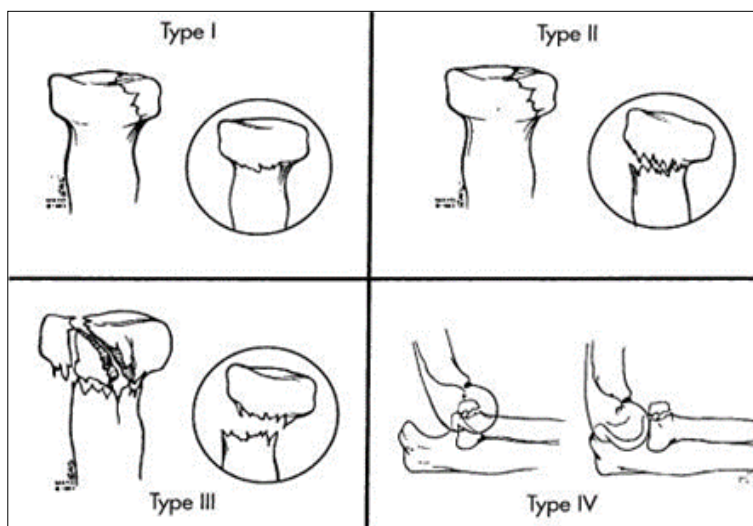


Fig 2: Classification of radial head fracture by masons criteria

O'Driscoll *et al.* described posterolateral rotatory instability of the elbow in 1991 [10]. This condition includes transient rotatory subluxation of the ulnohumeral joint along with subluxation or dislocation of the radiocapitellar joint as a result of lateral ulnar collateral ligament insufficiency [11]. In the spectrum of acute elbow instability, it is accepted that disruption of the lateral soft-tissue structures occurs initially and that the final stage is frank elbow dislocation [12]. With an intact MCL, radial head resection does not cause significant valgus instability; however, upon resection of the MCL, the joint subluxates, thus depicting that the radiocapitellar joint is a secondary restraint to valgus stress. In our study we assessed clinically and radiologically for posterolateral instability among patients who had undergone radial head excision.

2. Materials and Methods

A retrospective cross sectional study was conducted in the Department of Orthopedics of AN Medical College & Hospital, Gaya Bihar from March 2010 to July 2018. The Institutional Ethics Committee clearance was obtained for the same. After retrospective analysis 30 patients who had undergone radial head excision for fracture of the radial head were included in the study. There was 1 patient with mason type 2, 26 patients with Mason type 3 and 3 patients with Masons type 4 fracture.

The patients old X-rays and documents were retrieved and repeat X-rays were taken. History of persistence pain and instability of elbow was taken. Patients also underwent clinical evaluation by lateral pivot shift test and chair push up test. Based on their functional assessment MAYO scoring was calculated.

Radiological signs for posterolateral instability was also looked for.

The lateral pivot-shift test of the elbow was performed with the patient in the supine position, with the affected arm positioned overhead. The wrist and the elbow are lightly forced into supination while a valgus strain is applied to the elbow as it is moved from extension to flexion and back again [12]. A positive test result is an apprehension response by the patient and or frank subluxation or dislocation with a "clunk" as the radial head reduces during manipulation. A subcutaneous dimple can be seen just proximal to the radial head as the radial head subluxates posterolateral, and it disappears with radial head reduction [14]. These findings are often more readily appreciated during an examination with the patient under anesthesia because the patient is unable to guard against subluxation.

After radial head resection, posterolateral rotatory instability is difficult to identify as dimple is more subtle and distal because it is due to subluxation of the less prominent and more distal stump of the radial neck. Nonetheless, it can still be seen clinically as patients complain of apprehension and pain during the test as the ulna humeral joint begins to subluxate in forced supination and extension [13]. We have found it particularly useful to distinguish between the test in supination (which exacerbates posterolateral rotatory instability and increases pain) and the test in pronation (which reduces the radial head or neck and decreases pain) as away of detecting posterolateral rotatory instability. As a supinated position of the forearm helps to reduce valgus instability, this difference in forearm position also helps to distinguish posterolateral rotatory instability from valgus laxity [13]. 3 of our study patients showed positive findings. Following this patient underwent chair push up test. With the patient seated

and the elbows abducted from the body and flexed to 90° with the forearms in supination, patient is asked to place hand on the arms of a chair and pushes up as if to get of the chair. Elbow extension applies an axial and valgus load to the supinated elbow while the patient rises. These tests cause apprehension or radial head dislocation in patients with posterolateral instability [6]. Same three patients who were tested positive for lateral pivot shift test were tested positive for chair push up test also.

Mayo elbow performance score was calculated for all 30 patients by assessing the pain intensity, motion, stability and function (Table 1). A score of more than 90 was marked excellent and less than 60 as poor.

Table 1: Mayo elbow performance scale

Pain intensity	None (45)
	Mild (30)
	Moderate (15)
	Severe (0)
Motion	Arc of motion > 100° (20)
	Arc of motion 50° to 100° (15)
	Arc of motion < 50° (5)
Stability	Stable (10)
	Moderate instability (5)
	Grossly unstable (0)
Function	Can comb hair (5)
	Can eat (5)
	Can maintain hygiene (5)
	Can wear shirt (5)
	Can wear shoe (5)
Score	Excellent > 90
	Good 75 to 89
	Fair 60 to 74
	Poor < 60

The radiographic appearance of posterolateral rotatory instability among the patients were best demonstrated on the lateral view. Four separate stages have been described.

- (1) An increase in the ulnohumeral joint space,
- (2) Posterior subluxation/dislocation of the ulna,
- (3) Posterolateral rotation of the radial head such that the radial shaft and the capitellum are no longer in the same line, and
- (4) Frank posterolateral dislocation [14].

Figure 3 shows the X-ray and findings of a patient with posterolateral instability

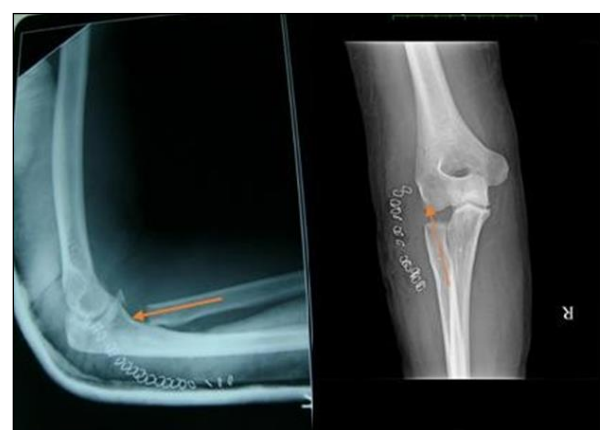

Fig 3A

Fig 3B

Fig 3A: Elbow lateral view showing axis of the remnant radial shaft directed posterior to the capitellum indicating subluxation. Fig 3B: Elbow AP view showing axis of the remnant radial shaft directed away from the capitellum indicating subluxation.

3. Results

Data was entered in Microsoft excel sheet, results were presented in the form of frequency tables and charts. 30 patients who had undergone radial head excision for fracture of radial head were included in our study. Of the study population 18 were male and 12 were females. The mean age of the patients was 43.84 years ranging from 21 years up to 68 years. There were 18 males and 12 females participants and the male-female ratio was 3:2. 17 right elbows and 13 left elbows were affected. The frequency distribution of Masons type fracture among patients is depicted in table number 2.

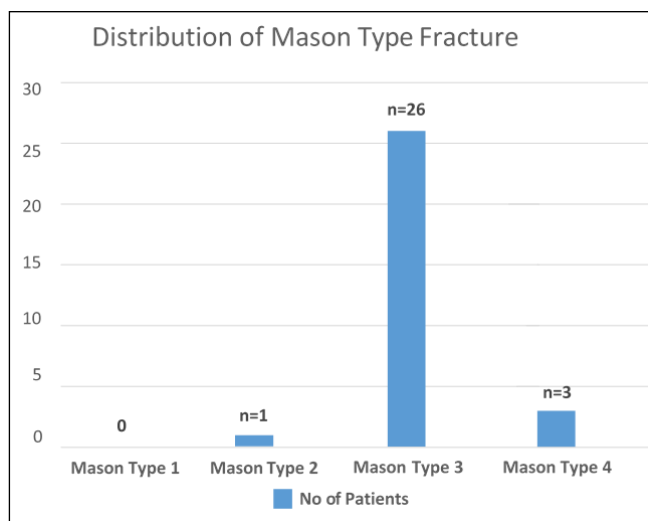


Fig 4: Distribution of masons type fracture

The average duration between radial head resection and the time of assessment was 3 years and 4 months with minimum of 1 year to maximum of 7 years 11 months.

Out of 30 patients 27 had pure radial head fracture of the remaining 3, two had associated ulnar fracture and one had associated elbow dislocation (figure 5)

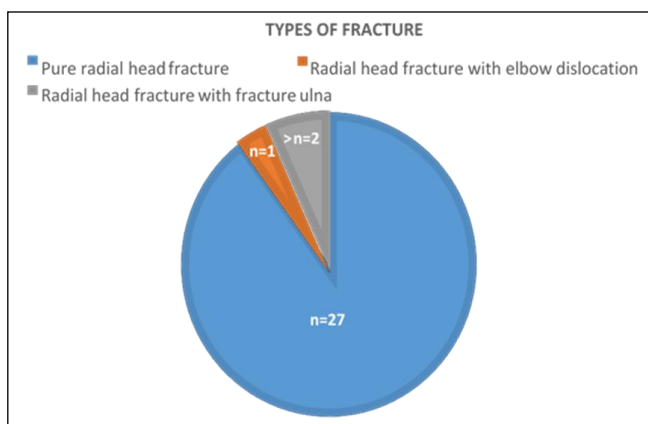


Fig 5: Type of fracture

Same three patients who had associated injuries when enquired complained of pain in the elbow, showed posterolateral elbow instability in the form of positive pivot shift test and chair push test. 2 of the patients had radiological

evidence of posterolateral instability in the form loss of collinearity between the axis of the remnant radial shaft and the capitellum. All 3 had average mayo score of 75 as compared to the patients who had pure radial head fracture who had good average score of 97. Also on retrospective analysis it was evident that these 3 patients who had posterolateral instability had undergone additional procedure along with radial head excision.

4. Discussion

Radial head forms an important secondary stabilizing factor of the elbow. Elbow instability following concomitant ligament injuries are masked due presence of intact radial head which becomes evident in cases with radial head fracture with excision. There is biomechanical evidence to support this theory [15, 16]. Schneeberger *et al.* evaluated the role of the radial head and coronoid as posterolateral rotatory stabilizers of the elbow on the basis of their clinical observations of posterolateral rotatory instability after elbow dislocation associated with radial head and coronoid fractures [17]. In a cadaveric study, they found that excision of the radial head significantly increased the mean posterolateral rotatory laxity to 18.6°, compared with 9° prior to the excision (p=0.0001). Although this degree of instability may not be apparent clinically, even greater instability was measured in the presence of concomitant coronoid defects. The authors concluded that both “the coronoid and the radial head contribute significantly to posterolateral rotatory stability”. Similar findings were reported by Jensen *et al.* Sixty percent of force transmission at the elbow goes through the radiocapitellar joint when the elbow is pronated and extended; radial head excision transmits that force to the ulnohumeral joint, increasing the joint stress and possibly causing more wear [11]. We did find evidence of early osteoarthritic changes in most of the postoperative elbows, which has also been shown in multiple other studies [19, 20, 21, 22]. This early degenerative wear could become a long-term problem in patients, especially in the younger age population. A study by Schiffen *et al.* conclude that posterior and medial drifting of the proximal radial stump commonly occurs after radial head resection for fracture. Excision of more than 2cm is associated more drift and hence resection should be planned less than 2 cm.

Another study by Jeremy Hall *et al.* which analysed 7 patients with posterolateral instability following radial head excision of which 4 patients were found to have lateral ulnar collateral ligament which was causing instability which is also supported by the findings from our study.

Sanchez-Sotelo *et al* reported the intermediate term results of lateral ligamentous repair or reconstruction for the treatment of posterolateral rotatory instability of the elbow in a study of forty-four patients who were followed for a mean of six years. One patient had previously undergone radial head resection and subsequently was diagnosed as having posterolateral rotatory instability. The authors noted the difficulty of diagnosing the condition in the setting of a radial head resection [23].

The persistence of elbow pain in patients following radial head excision and especially in patients with concomitant elbow injuries should raise the suspicion of ligament injuries resulting in the symptoms and such patients should be evaluated with alignment in X-rays, clinical tests like lateral pivot shift test and chair push test and if needed additional investigations in the form of MRI scan.

Magnetic resonance imaging (MRI) is able to characterize the

soft tissue structures, including collateral ligaments, and possible osteochondral fragments [24]. The lateral pivot shift test is difficult to interpret in the absence of radial head and will show only dimple as the proximal shaft of the radius subluxates posterolaterally. The chair push test will produce symptoms of elbow pain and instability.

Patients with posterolateral instability had low Mayo score compared to patients without any instability who had higher Mayo scores. There are many drawbacks of the study namely it being a retrospective many findings at the presentation if non-documented would be missed. Tests like pivot shift test and chair push test have interexaminer variability and so also the symptoms of elbow instability are quite subjective. Sample size is very small and due to financial constraints further investigations like MRI scan could not be carried out.

5. Conclusion

To conclude patients with radial head excision with persistent symptoms of elbow pain should be evaluated for features of elbow instability both clinically and radiologically. There should be suspicion in patients with concomitant injuries involving other bones forming the elbow and dislocation of the elbow at the first instance itself of higher chances of ligament injuries and the need for further investigation in the form of MRI scan to diagnose lateral ligament injury and primary repair rather than reconstruction on delayed diagnosis. The presence of ulna fracture or elbow dislocation should act as a pointer to the surgeon for detailed evaluation of the elbow injury and the need for ligament reconstruction or replacement of the radial head with prosthesis or any interposition.

6. References

- Harrington IJ, Tountas AA. Replacement of the radial head in the treatment of unstable elbow fractures. *Injury*. 1981; 12:405.
- Ring D, Quintero J, Jupiter JB. Open reduction and internal fixation of fractures of the radial head. *J Bone Joint Surg Am*. 2002; 84:1811-5.
- Morrey BF, AN KN. Stability of the elbow: osseous constraints. *J Shoulder Elbow Surg*. 2005; 14(1):174.
- Hausman MR, Lang P. Examination of the elbow: current concepts. *J Hand Surg Am*. 2014; 39(12):1.
- Bryce CD, Armstrong AD. Anatomy and biomechanics of the elbow. *Orthop clin north am*. 2008; 39(2):141-154.
- Safran MR, Baillargeon D. Soft-tissue stabilizers of the elbow. *J Shoulder Elbow Surg*. 2005; 14(1):179.
- Closkey RF, Goode JR, Kirschenbaum D, Cody RP. The role of the coronoid process in elbow stability. A biomechanical analysis of axial loading. *J Bone Joint Surg Am*. 2000; 82-A(12):1749-1753.
- Morrey BF, Tanaka S, AN KN. Valgus stability of the elbow. A definition of primary and secondary constraints. *Clin Orthop Relat Res*. 1991; 265:187-195.
- Mason ML. Some observations on fractures of the head of the radius with a review of one hundred cases. *Br J Surg*. 1954; 42:123-132.
- O'Driscoll SW, Bell DF, Morrey BF. Posterolateral rotatory instability of the elbow. *J Bone Joint Surg Am*. 1991; 73:440-6.
- Pomianowski S, Morrey BF, Neale PG, Park MJ, O'Driscoll SW, An KN. Contribution of monoblock and bipolar radial head prostheses to valgus stability of the elbow. *J Bone Joint Surg Am*. 2001; 83:1829-34.
- O'Driscoll SW, Morrey BF, Korinek S, An KN. Elbow subluxation and dislocation. A spectrum of instability. *Clin Orthop Relat Res*. 1992; 280:186-97.
- Regan W, Lapner PC. Prospective evaluation of two diagnostic apprehension signs for posterolateral instability of the elbow. *J Shoulder Elbow Surg*. 2006; 15(3):344-346.
- McKee MD, Schemitsch EH, Sala MJ, O'Driscoll SW. The pathoanatomy of lateral ligamentous disruption in complex elbow instability. *J Shoulder Elbow Surg*. 2003; 12:391.
- McKee MD, Schemitsch EH, Sala MJ, O'Driscoll SW. The pathoanatomy of lateral ligamentous disruption in complex elbow instability. *J Shoulder Elbow Surg*. 2003; 12:391-6.
- Schneeberger AG, Sadowski MM, Jacob HA. Coronoid process and radial head as posterolateral rotatory stabilizers of the elbow. *J Bone Joint Surg Am*. 2004; 86:975-82.
- Antuna SA, Sanchez-Marquez JM, Barco R. Long-term results of radial head resection following isolated radial head fractures in patients younger than forty years old. *J Bone Joint Surg Am*. 2010; 92:558-66.
- Goldberg I, Peylan J, Yosipovitch Z. Late results of excision of the radial head for an isolated closed fracture. *J Bone Joint Surg*. 1986; 68A:675-679.
- Ikeda M, Oka Y. Function after early radial head resection for fracture: a retrospective evaluation of 15 patients followed for 3-18years. *Acta Orthop Scand*. 2000; 71:191-194.
- Coleman DA, Blair WF, Shurr D. Resection of the radial head for fracture of the radial head. Long-term follow-up of seventeen cases. *J Bone Joint Surg Am*. 1987; 69:385-92.
- Goldberg I, Peylan J, Yosipovitch Z. Late results of excision of the radial head for an isolated closed fracture. *J Bone Joint Surg Am*. 1986; 68:675-9.
- Herbertsson P, Josefsson PO, Hassarius R, Besjakov J, Nyqvist F, Karlsson MK *et al*. Fractures of the radial head and neck treated with radial head excision. *J Bone Joint Surg Am*. 2004; 86:1925-30.
- Sanchez-Sotelo J, Morrey BF, O'Driscoll SW. Ligamentous repair and reconstruction for posterolateral rotatory instability of the elbow. *J Bone Joint Surg Br*. 2005; 87:54-61.
- Binaghi D. MR Imaging of the elbow. *Magn Reson Imaging Clin N Am*. 2015; 23(3):427-440.