



International Journal of Orthopaedics Sciences

ISSN: 2395-1958

IJOS 2019; 5(3): 621-625

© 2019 IJOS

www.orthopaper.com

Received: 10-05-2019

Accepted: 14-06-2019

Abhinav Jogani

Senior Registrar, Department of
Orthopedics, Seth GS Medical
College and KEM Hospital,
Mumbai, Maharashtra, India

Tushar Rathod

Associate Professor, Department
of Orthopedics, Seth GS Medical
College and KEM Hospital,
Mumbai, Maharashtra, India

Chetan Shende

Registrar, Department of
Orthopedics, Seth GS Medical
College and KEM Hospital,
Mumbai, Maharashtra, India

Morphometric analysis of the hip joint in Western Indian population: Relevance in designing of various hip implants & prosthesis

Abhinav Jogani, Tushar Rathod and Chetan Shende

DOI: <https://doi.org/10.22271/ortho.2019.v5.i3k.1600>

Abstract

Background: Proximal femur bears significant functional impact on gait and posture. Numerous proximal femoral parameters have been reviewed in the Western literature. In turn this knowledge was implemented in the designing of various prostheses. These implants which have been manufactured for the Western population are being utilised rampantly without modifications in our Indian patients undergoing hip replacements.

Materials and Methods: The study was carried out in 250 patients (500 hips) with an otherwise normal hip joint after ethical committee clearance. Computed tomography scanning of proximal femur was carried out. The following parameters were calculated: Neck-shaft angle (NSA), neck width (NW), head diameter (HD), acetabular angle (AA), horizontal offset (HO), vertical offset (VO), medullary canal diameter at the level of lesser trochanter (MDLT), and acetabular version (AV). Results were compared with various populations and statistically analysed.

Results: The mean values of NSA was 133°, NW 25 mm, femoral HD 41.9 mm, AA 35.1°, HO 36 mm, VO 47 mm, MD LT 19 mm, and AV 18.13°. These values are in contrast with those of the Western population. There was difference in the results when compared with contemporary Indian studies carried out in Northern and Northeast Indian population. There were significant differences in the parameters with respect to sex and side of the hip joint.

Conclusion: We conclude that there are significant differences in the morphometric parameters of proximal femur among the Western Indian population when compared with the world population. Also comparison within the Indian population reveals that the morphometric parameters show variation from region to region.

Keywords: Morphometric, hip joint, Western Indian population

Introduction

Proximal femur bears significant functional impact on gait and posture. The proximal femoral anatomy, esp. the relationship between proximal and the shaft of femur is an intriguing topic for research. It has been theorised that genetic as well as environmental factors such as age, race, sex, and lifestyle have a bearing on the geometry of the proximal femur [1-3]. There may exist a variation among morphometric dimensions reported for proximal femur in Western population as compared to that of Indian population [1]. Hence, the information concerning anatomy of proximal femur is vital for comprehending the biomechanics of the hip as well as surgical planning. Morphometric evaluation of the proximal femur will be helpful in the management of the pathological disorders surrounding the hip joint like osteoarthritis of the hip, fracture neck of femur, and peritrochanteric fractures.

Optimum functional outcome of fractures around the hip joint and osteoarthritis which happen to be fairly regular in elders necessitates ideal fixation.

A previous study by Siwach and Dahiya had done comparison of parameters of Indian cadaveric femurs with those of Western and Hong Kong Chinese population [1]. They found out that the implants tended to be oversized probably because of the general built of the Western population, and their various angles and orientations had a significant mismatch. This can inadvertently lead to complications such as splintering and fractures [1]. The study of cephalomedullary nails by Pathrot *et al.* recommended certain design alterations for the Indian

Correspondence

Abhinav Jogani

Senior Registrar, Department of
Orthopedics, Seth GS Medical
College and KEM Hospital,
Mumbai, Maharashtra, India

population as they had lesser neck width (NW) [5].

The objective of any surgery on the hip is to acquire a stable and fully functional hip joint post operatively. The routine implants utilised in the treatment of pathology around proximal femur include dynamic hip screws, proximal femoral nail, cannulated cancellous screws, and bipolar or total replacement prosthesis.

Since the data describing various parameters of proximal femur anthropometry for the Indian population is deficient [6], the designers of different prostheses have to rely on the published literature about proximal femur geometry of the Western population while designing them for Indian population also. Consequent to lack of options, the very same implants that had originally been designed for the Western population have to be used for Indian patients also.

It is also vital to In order to avoid complications like aseptic loosening, improper load distribution, and discomfort subsequent to mismatch it becomes imperative to match the sizes of the implant carefully with those of native femur [6, 7]. In uncemented hip replacement prosthesis insertion the secondary biologic integration of the hip implant with the femur would depend largely on the quality of its primary stability. [6, 8-10] In the early postoperative period there occurs micromotion of the implants consequent to the mismatch between bone and prosthesis which will adversely affect the bone ingrowth. A very important principle to be kept in mind by the designer while designing a prosthesis would be to

design it in such a way that through it sufficient loads must be transferred onto the nearby femoral bone to avoid stress shielding. [6, 11] Our study was designed with an aim to acquire sufficient knowledge about proximal femur geometry among Western Indian population using computed tomography (CT) scans.

Materials And Methods

250 patients belonging to both sexes in the age group between 18 and 72 years reporting to the Hospital between 2016 and 2019 were inducted in the study group. After getting ethical committee clearance patients with normal hips on preliminary examination, who had undergone abdominal CT scan for other reasons (not specially for this study) were evaluated. Exclusion criteria included patients with pre-existing hip disorders like osteoarthritis, old fracture or dislocations of hip, tumors of the proximal femur, tuberculosis of the hip, deformities of the lower limb were excluded from the study. For each patient both the hip joints were studied. During scanning the patient was placed in supine position with both lower limbs in neutral rotation. Each CT slice was 2 mm thick. Attempts were made to avoid superimpositions and motion artefacts. The following parameters were measured: neck-shaft angle (NSA), head diameter (HD), neck width (NW), acetabular angle (AA), horizontal offset (HO), vertical offset (VO), medullary canal diameter at the level of lesser trochanter, and acetabular version (AV). [Figure 1]

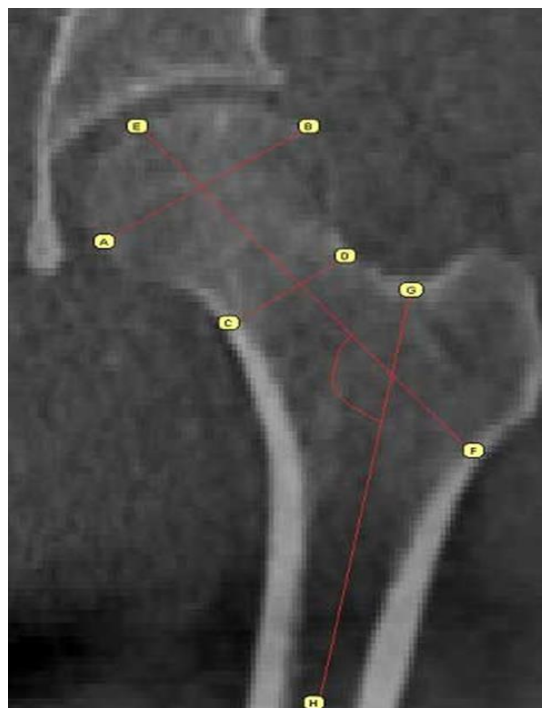


Fig 1: Sagittal cut of ct scan of hip showing how calculation of various parameters was done

Neck-shaft angle

it is defined as the angle formed by the intersection of the long axis of the femoral shaft and the long axis of the neck of the femur. Femoral shaft axis can be drawn by connecting through two points at the centre of medullary canal with respect to the mediolateral surface of femoral shaft. Similarly neck axis is drawn by joining the two points at the centre from the superior and inferior surface of femoral neck [11].

Head diameter

The mid-point of the widest diameter of the femoral head is measured and called as head diameter.

Neck width

The distance at the narrowest part of the femoral neck of a line that is drawn perpendicular to the neck axis is measured [5, 12].

Acetabular angle

the angle formed between the line intersecting pelvic teardrop and edge of the acetabulum and the horizontal in the coronal sections of the CT scan is known as the acetabular angle [13].

Horizontal offset

Horizontal offset is the exact distance from the centre of

femoral head to a line bisecting the long axis of shaft of femur [14].

Vertical offset

Vertical offset is the vertical distance from the centre of femoral head to the tip of lesser trochanter [Figure 2b] [15].

Medullary canal diameter at the level of lesser trochanter

At the level of middle of the lesser trochanter mediolateral diameter of the medullary canal was measured.

Acetabular version

A line connecting both the posterior ischia of the hip bone & a line connecting the posterior lips of the acetabulum is drawn and the angle is measured between them [13].

Two independent observers made the observation to reduce the error of calculation. The values were tabulated, and the measured parameters were compared with the Western population.

Results

Femoral head diameter

the mean of the femoral HD in our study was 42.2 mm. The mean femoral HD among male and female was 43.8 and 41.3 mm respectively. The values ranged from 37 to 49 mm among male and 38–48 mm in female. Between the right and left sides, the mean value was 41.88 and 43.16 mm, respectively. There was statistically significant difference (p value <0.05). The femoral HD values between the two sides were compared to each other.

Neck width

The mean of the NW was 27.1 mm. In the male, it varied between 17 and 35 mm, and for the females, between 19 and 31 mm. The mean value was 28.5 mm among male, and it was 25.7 mm among females.

On the right side, the NW ranged from 18 to 38 mm, and on the left side, it was 21–34 mm. The mean value was 26.5 mm on the right side and it was 27.7 mm on the left side.

Neck-shaft angle

The mean value of the NSA in our study was 135.1°. Among males and females, the range of NSA was 127°–145° and 120°–143° respectively. The mean value was 136.2° in male and 133.79° in females which showed a statistically significant difference (p value <0.05). The right side varied between 120° to 143° whereas the left side between 122°–144°. The mean value was 134.12° on the right side and it was 135.87° on the left side. There was statistically

significant difference (p value <0.05)

Horizontal offset

The mean value of HO was found to be 37.2 mm. Among males, it varied between 34 & 46 mm and for the females between 32 & 41 mm. The mean value for the males was 39.52mm, and for the females, it was around 35.07 mm. On the right side, the HO varied between 32 & 43 mm, and on the left side, between 31–44 mm. The mean value was 37.29 on the right side, and on the left side, it was 37.11 mm.

Vertical offset

The mean value of the VO was 46.63 mm. Among males, it varied between 41 & 63 mm and for the females 34 & 53 mm. The mean value for the males was 49.71 mm, and for the females, it was 43.51 mm. On the right side the VO range was 33–62 mm, and on the left side, it was 39–59 mm.

The mean value was 47.71 on the right side, and on the left side it was 46.04 mm. There was statistically significant difference (p value <0.05).

Acetabular angle

the mean value of AA was 35.1°. Among males and females, the range of AA was similar and was 22°–39°. The mean value among male and female was 34.97° and 35.46°. Among the right and left sides, the range was 23°–41° and 28°–44°. The mean value among the right and left sides was 37° and 35.83°.

Medullary canal diameter at lesser trochanter

The mean value of the medullary canal diameter at the level of lesser trochanter (MDLT) in our study was found to be 19.9 mm. Among males and females, range was 14–29 and 12–26 mm, respectively. The mean value among males and females was 20.29 and 20.19 mm. Among the right and left sides, the range of values was 12–30 and 14–29 mm. The mean value among the right and left side was 20.31mm and 19.49 mm respectively. There was statistically significant difference (p value <0.05)

Acetabular version

The mean value of the AV in our study was 18.39°. Among males and females, range was 9°–31° and 12°–34°. The mean value among male and female was 17.49° and 19.06°. Among the right and left sides, the range of values was 10°–31° and 12°–32°. The mean value among the right and left side was 18.43° and 19.19°. There was statistically significant difference (p value <0.05)

Table 1: Comparative analysis of the morphometry of the hip joint reported in different studies

Parameter	Present study (Indian), n=500	Rawal <i>et al.</i> [6]. (Indian), n=98	Ravichandran <i>et al.</i> [19]. (Indian), n=578	Saikia <i>et al.</i> [13]. (Indian), n=104	Rubin <i>et al.</i> [17]. (Swiss), n=32	Mahaisavariya <i>et al.</i> [18]. (Thai), n=108	Noble <i>et al.</i> n=80 (mean) (Caucasian),	Husmann <i>et al.</i> [16, 8]. (France), n=310
Femoral head diameter (mm)	42.2	45.41±3.6	-	-	43.4±2.6	43.98±3.47	45.9	-
Neck width (mm)	27.1	-	30.99	-	-	-	-	-
Neck-shaft angle (°)	135.1	124.42±5.49	126.55	139.5±7.5	122.9±7.6	128.04±6.14	125.4	129.2±7.8
Horizontal offset (mm)	37.2	40.23±4.85	-	-	47±7.2	-	-	40.5±7.5
Vertical offset (mm)	46.63	52.33±7.19	-	-	56.1±8.2	48.94±4.95	-	57.3±8.1
Acetabular angle (°)	35.1	-	-	39.2±4.9	-	-	-	-
Medullary canal diameter at the lesser trochanter (mm)	19.9	-	-	-	27.9±3.6	-	-	-
Acetabular version (°)	18.39	-	-	18.2±5.6	-	-	-	-

SD=Standard deviation

Discussion

The Indian diaspora encompasses a diverse collection of population with varied morphological and genetic features. It includes an amalgamation of local as well as immigrated population [13], is very essential, as it will help Improved understanding of the varied pathogenesis of hip disorders such as primary osteoarthritis of the hip joint can be had with thorough awareness of the anatomical parameters of the bony components of the hip joint [13].

The lifestyle and the social traditions of the Indian population differ widely from that of the Western population. As our population is more adept to floor level activities with increased external rotation of the hip the hip joints of Indian population are evolutionally quite dissimilar to that of their Western counterparts [13]. CT has greatly helped in the advancement and detailed analysis of the hip joint. For morphometric analysis studies, plain radiographs were utilised by Husmann *et al.* and Noble *et al.* [8, 16] whereas Rubin *et al.* [17] and Mahaisavariya *et al.* [18] utilised CT scans. Rubin concluded that CT scan values were more precise than plain radiographs [17].

In a study by Rubin in Swiss population, the femoral HD was 43.4 mm. [17] A study among the Caucasian population by Noble *et al.* the femoral HD was reported as 45.9 mm. [16] In our study, the femoral HD was 42.2 mm (range 37–49 mm) which was found to be lower than the Western counterparts.

Value of Femoral HD among Western Indian population was lower as compared to data from a similar study done in New Delhi by Rawal *et al.* [6] [Table 1]. Routinely femoral neck is reported to form an angle with the shaft about $135^{\circ} \pm 7^{\circ}$ in the normal adult. Functional relevance of this neck shaft angle is that consequent to the displacement of the femoral shaft away from the pelvis, hip joint motion freedom is greatly enhanced [20].

Regarding the NSA, on comparing our results with that of the Western studies [6, 16, 17], it was found that the NSA of the Western studies was lower than our study results. On comparing our study results with other Indian studies [6, 13], it was found that the NSA among Western Indian population was more than north Indian population [Table 1], whereas it was less than Northeastern population done by Saikia *et al.* The neck stem angle of the routine femoral prosthesis used in hip replacement is 131° . The mean NSA according to our results was around 135° . Hence non restoration of native angles while performing hip replacements may lead to altered hip biomechanics.

The NSA among male was statistically significantly higher than that of females in our study, similar to results of Rawal *et al.* [6] This study concluded that the surgeon would face some relative amount of trouble while inserting the same femoral stem in a male or female patient during hip replacements in order to reinstate the natural biomechanics of the joint by bearing in mind both extra and intramedullary parameters of the femur.

Routinely Available cephalocervical diaphyseal angles in proximal femoral nail are 130° and 135° . In our study, value of NSA varied between 120° & 147° . Hence, use of a routine proximal femoral nail may not reproduce the original NSA following surgical fixation and may not suffice in all patients.

AA is most commonly utilised to identify the presence of acetabular dysplasia. The values of more than 43° are considered dysplastic [11].

We found out the angle to be 35.1° . Studies by Stuberg and Harris [21] quoted the mean AA to be around 32.2° and 32.1° in males and females, respectively. Nakamura *et al.* [22]

reported mean AA to be 38° in the Japanese population. On comparing the AA of our study with the study done by Saikia *et al.* [13] in Northeast India, we found out that the AA was less among the West Indian population compared to Northeast Indian population [Table 1].

Restoring the leg length (VO and HO) helps to reinstate appropriate hip biomechanics and enhances overall post-operative patient satisfaction in hip Arthroplasty [23, 24]. The horizontal and vertical femoral offsets in our study were 37.2 mm (range 34–43 mm) and 46.63 mm (41–64mm) respectively, which were much lesser than the values observed by Western studies of Rubin *et al.*, [17] & Husmann *et al.* [8] Our results on comparison with a similar Indian study done on North Indian population by Rawal *et al.* [6] revealed that the HO and VO are less among Western Indian population [Table 1].

In our study, mean value of medullary canal diameter measured at the level of lesser trochanter was 20.29 mm (range 14–29 mm) among males [Table 2]. Among the females, the mean values were 20.19 mm (range 12–28 mm).

When compared with data from north Indian people in a study by Rawal *et al.* [6] the mediolateral canal diameter at the level of lesser trochanter is lower among Western Indian population. The mean value of the femoral HD, NW, NSA, HO, VO, and MDLT for males was found to be statistically significantly higher than females. AV was higher in females and was statistically significant. Variation in HO between the males and females was around 4 mm. The range of femoral head offset for females of the population is reportedly smaller by around 36% in comparison to males of the same population. [6] The inherent differences in size, shape, and load distribution variations at the hip joint between the male and female lead to the finding of linear fit in the male and female data being approximately 10 mm apart. NW, NSA, AA, AV, on the left side were significantly higher. VO and MDLT on the right side were statistically significantly higher. Our study findings were comparable to those with Saikia *et al.* [13] with regards to that the AV differs with the side of the acetabulum and gender in the Indian population.

Routinely a minimum of three cancellous screws are being used while fixing the fracture neck of femur. The diameter of these screws is 6.5 mm. The lowest value of the NW in our study was found to be around 19 mm; consequently, fixation with three screws may become troublesome in these patients with narrower canal. Findings of Pathrot *et al.* regarding cephalomedullary nails also recommended certain design modifications for the Indian population with lesser NW. [5]

Conclusion

This study accomplishes that there exist significant differences in morphometric parameters of hip joint among the Western Indian population as compared with the Western World literature. Due to the large variations of the morphometry of various population groups of the world, the ethnic groups with an inherently smaller built, especially Indians, are prone to suffer technical faults in hip replacement surgeries with majority of the commercially currently available prostheses in the market because of the non-availability of smaller and appropriately-sized implants. From our findings we can suggest that within the Indian population, the morphometric parameters tend to have a variation from region to region.

Hence, this study would prove to be useful for designing the total hip prosthesis among the Indian population. However, we accept the limitation that our sample size was small with

only 250 persons. A large multicentric study in western India is necessary to confirm our results.

Financial support and sponsorship: Nil.

Conflicts of interest: There are no conflicts of interest.

References

1. Siwach RC, Dahiya S. Anthropometric study of proximal femur geometry and its clinical application. *Indian J Orthop.* 2003; 37:247-51.
2. Najjar EI, McWilliams ER. Forensic anthropology: The structure, morphology and variations human bone and dentition. Springfield, IL: Charles C Thomas, 1978.
3. Ericksen MF. Aging changes in the medullary cavity of the proximal femur in American Blacks and Whites. *Am J Phys Anthropol.* 1979; 1:563-9.
4. Gullberg B, Johnell O, Kanis JA. World-wide projections for hip fracture. *Osteoporos Int.* 1997; 7:407-13.
5. Pathrot D, Ul Haq R, Aggarwal AN, Nagar M, Bhatt S. Assessment of the geometry of proximal femur for short cephalomedullary nail placement: An observational study in dry femora and living subjects. *Indian J Orthop.* 2016; 50:269-76.
6. Rawal B, Ribeiro R, Malhotra R, Bhatnagar N. Anthropometric measurements to design best-fit femoral stem for the Indian population. *Indian J Orthop.* 2012; 46:46-53.
7. Engh CA. Hip arthroplasty with a Moore prosthesis with porous coating. A five-year study. *Clin Orthop Relat Res.* 1983; 176:52-66.
8. Husmann O, Rubin PJ, Leyvraz PF, de Roguin B, Argenson JN. Three-dimensional morphology of the proximal femur. *J Arthroplasty.* 1997; 12:444-50.
9. Engh CA, Bobyn JD, Glassman AH. Porous-coated hip replacement. The factors governing bone ingrowth, stress shielding, and clinical results. *J Bone Joint Surg Br.* 1987; 69:45-55.
10. Morscher EW. Cementless total hip arthroplasty. *Clin Orthop Relat Res.* 1983; 181:76-91.
11. Jasty M, Henshaw PM, O'Connor DO. Strain alterations in the proximal femur with an uncemented femoral prosthesis emphasizing the effect of component fix. Atlanta, GA: Proceeding Orthopaedic Research Society Meeting, 1988, 335.
12. Calis HT, Eryavuz M, Calis M. Comparison of femoral geometry among cases with and without hip fractures. *Yonsei Med J.* 2004; 45:901-7.
13. Saikia KC, Bhuyan SK, Rongphar R. Anthropometric study of the hip joint in northeastern region population with computed tomography scan. *Indian J Orthop.* 2008; 42:260-6.
14. Roy S, Kundu R, Medda S, Gupta A, Nanrah BK. Evaluation of proximal femoral geometry in plain anterior-posterior radiograph in eastern-Indian population. *J Clin Diagn Res.* 2014; 8:AC01-3.
15. Preoperative Templating and Biomechanics in Total Hip Arthroplasty. Available from: <http://www.healio.com/orthopedics/hip/news/online>. [Last accessed on 2005 Aug 01].
16. Noble PC, Alexander JW, Lindahl LJ, Yew DT, Granberry WM, Tullos HS *et al.* The anatomic basis of femoral component design. *Clin Orthop Relat Res.* 1988; 235:148-65.
17. Rubin PJ, Leyvraz PF, Aubaniac JM, Argenson JN, Estève P, de Roguin B *et al.* The morphology of the proximal femur. A three-dimensional radiographic analysis. *J Bone Joint Surg Br.* 1992; 74:28-32.
18. Mahaisavariya B, Sittthiseripratip K, Tongdee T, Bohez EL, Vander Sloten J, Oris P. Morphological study of the proximal femur: A new method of geometrical assessment using 3-dimensional reverse engineering. *Med Eng Phys.* 2002; 24:617-22.
19. Ravichandran D, Muthukumaravel N, Jaikumar R, Das H, Rajendran M. Proximal femoral geometry in Indians and its clinical applications. *J Anat Soc India.* 2011; 60:6-12.
20. Anderson JY, Trinkaus E. Patterns of sexual, bilateral and interpopulational variation in human femoral neck-shaft angles. *J Anat.* 1998; 192(Pt 2):279-85.
21. Stenberg SD, Harris WH. Acetabular dysplasia and development of osteoarthritis of hip. The Hip. Proceedings of the Second Open Scientific Meeting of the Hip Society. St. Louis: C.V. Mosby. 1974, 82-93.
22. Nakamura S, Ninomiya S, Nakamura T. Primary osteoarthritis of the hip joint in Japan. *Clin Orthop Relat Res.* 1989; 241:190-6.
23. Sugano N, Noble PC, Kamaric E. Predicting the position of the femoral head center. *J Arthroplasty.* 1999; 14:102-7.
24. Ranawat CS, Rodriguez JA. Functional leg-length inequality following total hip arthroplasty. *J Arthroplasty.* 1997; 12:359-64.