



# International Journal of Orthopaedics Sciences

ISSN: 2395-1958  
IJOS 2019; 5(3): 505-507  
© 2019 IJOS  
www.orthopaper.com  
Received: 06-05-2019  
Accepted: 10-06-2019

**Dr. Mohammed Jalal Mohiuddin**  
Assistant Professor, Department  
of Orthopedics, Deccan College of  
Medical sciences, Hyderabad,  
Telangana, India

**Dr. Lalith Mohan**  
Associate Professor, Department  
of Orthopedics, Deccan college of  
Medical sciences, Hyderabad,  
Telangana, India

**Dr. C Shamsunder**  
Professor and Head, Department  
of Orthopedics, Deccan college of  
Medical sciences, Hyderabad,  
Telangana, India

**Dr. Aslam Mohsin**  
Post Graduate, Department of  
Orthopedics, Deccan college of  
Medical sciences, Hyderabad,  
Telangana, India

**Dr. Sajid Salman**  
Post Graduate, Department of  
Orthopedics, Deccan college of  
Medical sciences, Hyderabad,  
Telangana, India

## Correspondence

**Dr. Mohammed Jalal Mohiuddin**  
Assistant Professor, Department  
of Orthopedics, Deccan College of  
Medical Sciences, Hyderabad,  
Telangana, India

## Role of guided growth in deformity correction around the knee using stevens 8 plate

**Dr. Mohammed Jalal Mohiuddin, Dr. Lalith Mohan, Dr. C Shamsunder,  
Dr. Aslam Mohsin and Dr. Sajid Salman**

DOI: <https://doi.org/10.22271/ortho.2019.v5.i3i.1578>

### Abstract

Angular deformities of knee which includes genu varum, valgum, recurvate and procurator are common presentation in paediatric orthopaedics OPD. These are the developmental deformities if attended on time can be managed with minimal invasive procedures (Hemi epiphysiodesis). The various methods described for epiphysiodesis and Stevens 8 plate assisted growth modulation is the best among them. Though Hemi epiphysiodesis correct the deformity over the period of time, it gives correction at CORA level without any complication. Timely done procedure can avoid need of invasive surgeries in future like corrective osteotomies.

**Keywords:** angular deformities, genu, hemiepiphysiodesis, osteotomies

### Introduction

The knee joint alignment changes with the age as the child grows, it start as varum at time of birth and the varus decreases during the course of development till age of 24 to 36 months. It start deviating towards valgus till the age of 5 years to 6 years with maximum value at 6 years (Around 11 degrees). It starts decreasing after that and comes to adult value at 11 years of age. There are various regional and racial and familial deviation from the normal developmental procedures many times <sup>[1, 2, 3]</sup>.

Deformities around the knee joints are one of the commonest presentations in the paediatric orthopaedics <sup>[4]</sup>. They present as Genu Varum, Genu Valgum, Genu Recurvatum, genu procurvatum and Fixed Flexion Deformities <sup>[5]</sup>. These angular deformities around the knee alter the biomechanics and cause distorted stress distribution. Pain, limitation of activity, joint instability, and growth disturbance may develop in significant number of children, in whom physiological correction of bow legs and knock knees doesn't occur <sup>[6]</sup>.

They may be unilateral or bilateral depending on the aetiology. Systemic causes like idiopathic, rickets, epiphyseal dysplasia, etc presents mostly as bilateral deformity and trauma, infection and tumour presents as unilateral deformity. Long standing spastic cerebral palsy presents with Fixed Flexion Deformity.

Using the advantage of open and active physics, growth modulation by the principle of temporary hemi-epiphysiodesis is the good option to correct deformities around knee <sup>[7, 8]</sup>. This first time described by Phemister in 20th century, it was permanent method. There were many methods described after that with different principle and associated complication, important being the permanent retardation of epiphyseal plate. These method described are Metaizeau's transphyseal screws, Blount's staples <sup>[9]</sup> and malleable plates <sup>[8]</sup>.

Among these, Stevens "8-plate" is a low-profile, easy to use and relatively inexpensive implant and had the biggest advantage of causing minimal disturbance of physeal and periosteal blood supply- thus making it an ideal choice for temporary hemi-epiphysiodesis for correction of angular deformities at any age before skeletal maturity <sup>[10]</sup>.

The present study is based on above method, where 8-plates are being used for correction of deformities around the knee.

### Aims and Objectives

- To evaluate the results of angular correction by Stevens 8-plates in children between age group 5yrs to 16 yrs.
- To calculate the rate of deformity correction in various age group and gender.
- To get the information regarding the latest possible age where this principle can be applied.
- To evaluate the various reasons for angular deformities at knee.

### Material and Methods

The study done after Institutional Review Board clearance, at our institute. 10 patients (18 Knees) were selected for the above procedure after clinical and radiological evaluation. Radiological parameters used are Tibio-femoral angle, mean axis deviation, mechanical lateral distal femoral angle (mLDFA), medial proximal tibial angle (MPTA) and lateral distal tibial angle (LDTA). Patients evaluated thoroughly for the aetiology of angular deformity.

Regular post-op follow-up done, measuring angle at knee clinically with goniometer and measuring intermalleolar distance or intercondylar distance. Final X-rays taken once clinical correction obtained to recheck the angles and position of implant. Implant removal done once required correction is achieved.

### Operative procedure

The choice of anesthesia depends on preference of anesthesiologist. Tourniquet used for clear vision. The level of epiphysis localized under C arm and the 1 mm K wire placed at the level of physics. Incision along the either side of target K wire was given. The layer wise dissection lifting each layer was done and the layer which is adherent to bone (Cannot be lifted) was periosteum with the vessels seen over it. The Stevens 8 plate sided over k wire and position of the holes check in relation to the epiphysis. Screw of the epiphyseal side placed followed by metaphysic after drilling the near cortex. 3.5 mm cortical screws were used and precaution taken to restrict the screws passing half the width. They were kept parallel.

The final position checked under image intensifier and the closure done layer wise. Subcuticular Monocryl (3-0) sutures applied for the skin.

### Inclusion criteria

- Patient willing to participate in study

- Children with Angular deformity and open epiphyseal plate.
- Deformities of any pathological origin.
- Age 5 years to 15 years.

### Exclusion criteria

- Angular deformities with rotational deformity.
- Angular deformities treated in past with other means.

### Results

The number of patient included in our study were 10 patients, contributing 18 knees. 6 were females and 4 were males. Genu varum was seen in 2 patients (4 knees), Genu Valgum was seen in 6 patients (12 knees), 2 knees with knee fixed flexion deformity (1 knee–Cerebral palsy and 1 knee – proximal focal femoral deficiency).

Considering the aetiology, 6 patients had nutritional rickets (5 Genu Valgum and 1 Genu varum), hypophosphatemia rickets (Genu Valgum), Blount's disease, CP (Cerebral palsy) and 1 PFFD (Proximal focal femoral Deficiency) one each.

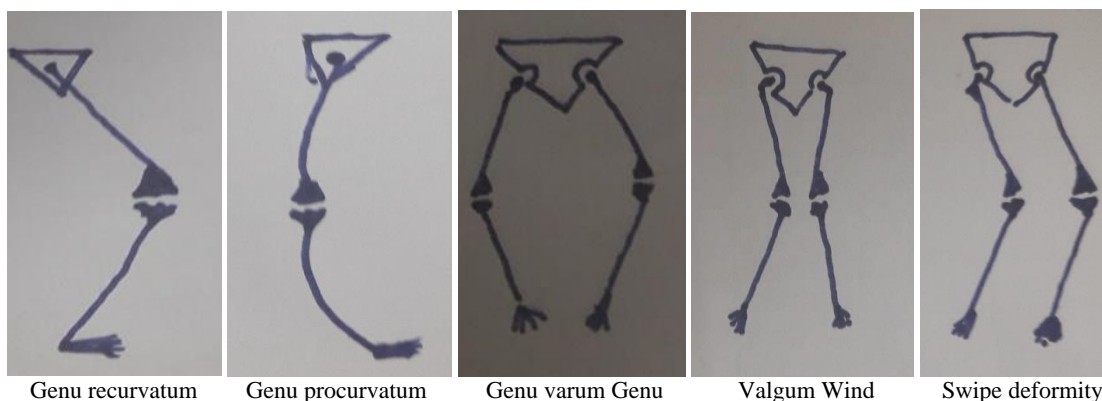
Age group ranged between 5 years to 15 years, mean age: 10.7 years. The calculated deformity radio logically was 15 degree to 60 degree with Mean 27 degrees. Clinically measured deformity was 15 degrees to 60 degrees with Mean of 30.5 degrees.

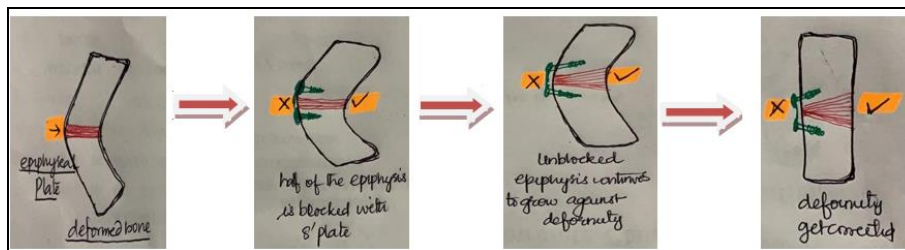
Period for which implant was kept inside 8 months to 24 months, Mean period: 19.2 months. 8 patients got complete correction. 2 attained skeletal maturity after partial correction and underwent corrective osteotomies later on. There were no post op complications.

Mobilisation started on second post-op day. All patient attained complete range of movement after 2 weeks. There was no permanent damage to physics noticed in these patients during follow-up. One patient has screw breakage and needed revised surgery.

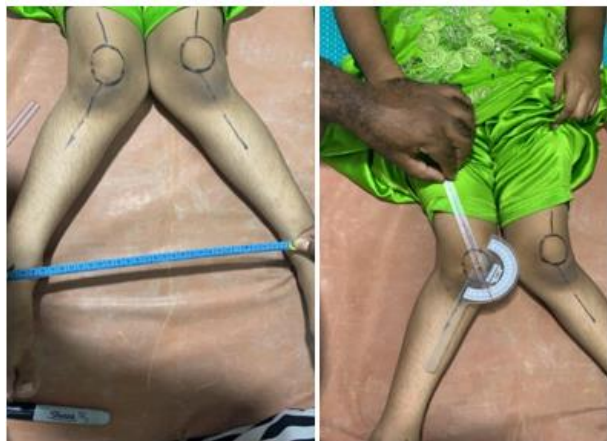### Discussion

Nutritional rickets is common cause for knee angular deformity. mLDFA (Mechanical lateral distal femoral angle) and MPTA (Medial proximal tibia angle) is the standard parameters to quantify the amount of deformity. Stevens' 8 plates is the simple method among all available implants for epiphysiodesis. There is no post-operative rehabilitation necessary for this procedure. Follow-up shows no permanent damage to epiphysial plate.

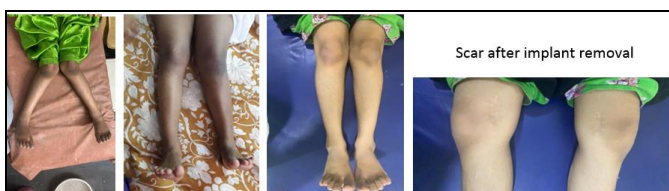




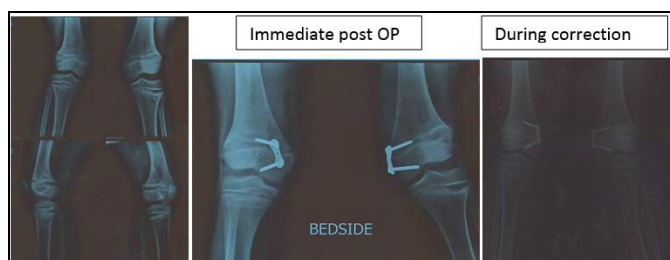The physiology of epiphysis and correction of deformity when hemiepiphysodesis is done



Clinical measurement



Radiological follow-up.



Radiological follow-up

## Conclusion

Stevens's 8-plate assisted temporary hemi-epiphysodesis is the safe, effective and reversible procedure for deformity correction around the knee. This can avoid more complicated procedure – *Corrective osteotomy* in future. Parents should be educated that vitamin D production occurs in UV light that is between 10am to 2pm.

Early diagnosis of the deformities by the paediatrician (As they are the primary physicians for kids) is very important as it helps to prevent the delay in treatment and invasive surgeries. There should be a screening program in schools to identify patients with deformities and perform necessary timely intervention.

In India, Deformities are neglected in girl child until they reach the marriageable age. When, osteotomy becomes the ultimate treatment. Hence, community education can prevent such a scenario later on.

## References

1. Uttam sainsi *et al.* Normal development of the knee angle in healthy Indian children: A clinical study of 215 children. *Journal of Childrens Orthopedics*. 2010; 4(6):579-86.
2. Westhoff B, Jager M, Krauspe R. Axes of the legs in childhood. What is pathologic? *Orthopade*. 2007; 36:485-498.
3. Westhoff B, Wild A, Krauspe R. Development of the leg axis in childhood and treatment options for deformities near the knee joint. *Orthopade*. 2002; 31:1198-1208.
4. Stevens P. Guided growth: 1933 to the present. *Strategies Trauma Limb Reconstr*. 2006; 1(1):29-35.
5. Brooks WC, Gross RH. Genu varum in children: diagnosis and treatment. *J Am Acad Orthop Surg*. 1995; 3(6):326-335.
6. K Venkataramana *et al.* Role of hemi-epiphysodesis using 8-plate system in the correction of coronal plane deformities around the knee. *Indian Journal of Orthopaedics Surgery*. 2018; 4(2):209-213.
7. Stevens PM. Guided growth for angular correction: a preliminary series using a tension band plate. *J Pediatr Orthop*. 2007; 27:253-259.
8. Muayad Kadhim, Luke Gauthier, Karl Logan, Ron El-Hawary, Benjamin Orlik. Guided growth for angular correction in children: a comparison of two tension band plate designs. *J Pediatr Orthop B*. 2017; 27(1):1-7.
9. Me'taizeau JP, Wong-Chung J, Bertrand H, Pasquier P. Percutaneous epiphysodesis using transphyseal screws (PETS). *J Pediatr Orthop*. 1998; 18(3):363-369.
10. Guided growth for angular correction: a preliminary series using a tension band plate. Stevens PM *J Pediatr Orthop*. 2007; 27(3):253-9.
11. Paley D. *Principles of Deformity Correction*. Ed. Herzenberg JE. Berlin, Heidelberg: Springer-Verlag, 2002.