



## International Journal of Orthopaedics Sciences

ISSN: 2395-1958  
IJOS 2019; 5(3): 512-514  
© 2019 IJOS  
www.orthopaper.com  
Received: 11-05-2019  
Accepted: 15-06-2019

**Dr. Prasad Chaudhari**  
Associate professor, Dr D Y Patil  
Medical College, Nerul, Navi  
Mumbai, Maharashtra, India

**Dr. Gaurav Kanade**  
Assistant Professor, Dr D Y Patil  
Medical College, Nerul, Navi  
Mumbai, Maharashtra, India

**Dr. Sachin Kale**  
Professor, Dr D Y Patil Medical  
College, Nerul, Navi Mumbai,  
Maharashtra, India

**Dr. Vatar Arvind Janardhan**  
MBBS, M.S Orthopedics,  
A.F.I.H, Consultant Orthopedic  
Surgeon (MPCT Hospital  
(Sanpada), Appollo Spectra  
Hospital (Chembur),  
Maharashtra, India

**Dr. Sanjay Dhar**  
Professor, Dr D Y Patil Medical  
College, Nerul, Navi Mumbai,  
Maharashtra, India

**Dr. Aditya Gunjotikar**  
Senior Resident, Dr D Y Patil  
Medical College, Nerul, Navi  
Mumbai, Maharashtra, India

### Percutaneous trigger finger release or steroid injection- which is better in trigger finger treatment

**Dr. Prasad Chaudhari, Dr. Gaurav Kanade, Dr. Sachin Kale, Dr. Vatar Arvind Janardhan, Dr. Sanjay Dhar and Dr. Aditya Gunjotikar**

DOI: <https://doi.org/10.22271/ortho.2019.v5.i3i.1580>

#### Abstract

**Introduction:** Trigger finger is caused due to impaired tendon gliding at the level of A1 pulley.

**Material and Methods:** The study was a prospective randomised control trial with 104 trigger fingers in 98 patients. 52 trigger fingers underwent percutaneous trigger finger release using No 16 Needle (Group A) and other 52 patients were enrolled in Steroid injection group (Group B). Patients were assessed based on Visual Analogue Pain scores (VAS) at the end of 1 month and 6 months.

**Results:** The study had 96 patients. 33 were male patients and 63 were female patients. 50 trigger fingers in group A and 49 trigger fingers in group B were studied till end of study. We lost patients with 2 trigger fingers in Group A and 3 trigger fingers patients in Group B, during followup period. Satisfaction levels of Group A far exceeded Group B.

**Conclusion:** Percutaneous Release of A1 pulley has better results than local steroid injection.

**Keywords:** Trigger finger, steroid injection, percutaneous release, A1 pulley, VAS score

#### Introduction

Primary Trigger finger is a degenerative disorder in which the smooth gliding of flexor tendon is impaired at the level of A1 pulley. Various reasons have been attributed to this problem. These include proliferation of surrounding synovium and fibrosis of flexor sheath<sup>[1]</sup>.

Secondary Trigger finger is caused by hand trauma, mainly by partial injury flexor tendon<sup>[2]</sup>. Conservative treatment consists of NSAIDs, Rest, Splinting and steroid injections<sup>[2, 3]</sup>. Surgical treatment is to release of A1 pulley<sup>[4]</sup>. Open surgical release is associated with complications like nerve injury, scar tenderness, infection and joint contractures<sup>[5]</sup>. Percutaneous release is considered cost effective, safe and outpatient clinic procedure<sup>[5, 6, 7]</sup>. Steroid injections in trigger fingers have shown good results of 92% by Marks *et al.*<sup>[8]</sup>. We aim to do a randomised control trial comparing results of Percutaneous release of A1 pulley by No 16 needle and Steroid injection in trigger fingers.

#### Material and Methods

104 trigger fingers in 98 patients were included in our study. Patients were investigated to rule out diabetes. Patients suffering from Grades 3-5 of Quinell staging of trigger finger were included in the study. Patients were randomly allocated to either group A or group B. Informed Consent was taken from patients. All procedures were done in outpatient clinics. VAS scores were recorded at 1 month and 6 months postoperatively.

#### Correspondence

**Dr. Vatar Arvind Janardhan**  
MBBS, M.S Orthopedics,  
A.F.I.H, Consultant Orthopedic  
Surgeon (MPCT Hospital  
(Sanpada), Appollo Spectra  
Hospital (Chembur),  
Maharashtra, India

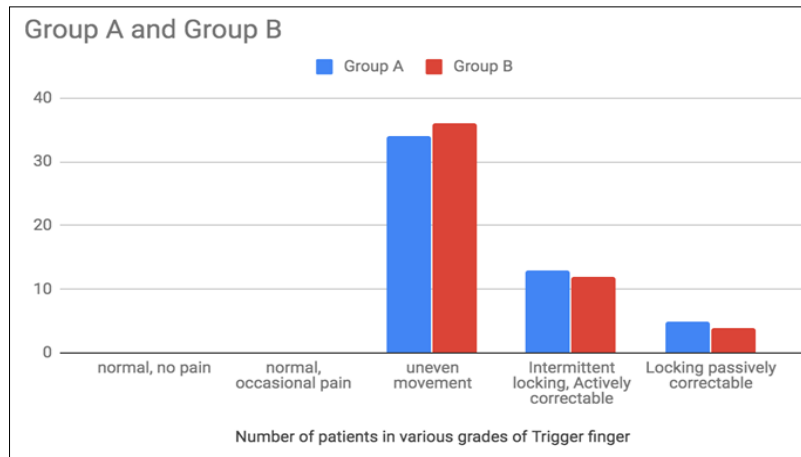


Fig 1: Number of trigger fingers in patients enrolled based on grades of trigger finger in Group A and B.

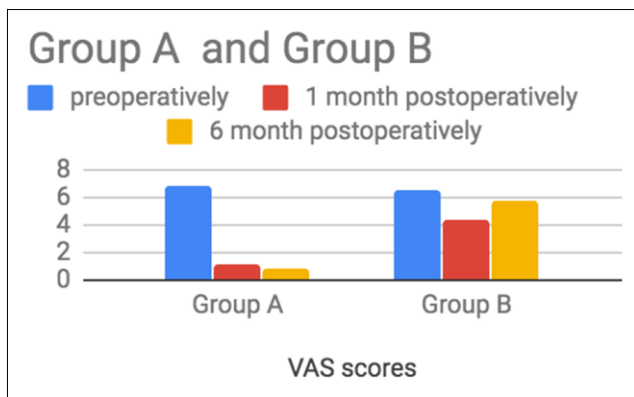


Fig 2: Changes in Pain scores in patients in Group A and B at various stages of treatment.

**Technique of percutaneous release of trigger finger:** The patients is administered 1 ml of 0.2% lignocaine through 25 gauge needle and syringe. The patient is asked to move the finger and the nodule of prominent A1 pulley is palpated at the base of finger. The needle is inserted with the axis of bevel parallel to the axis of finger. The needle is moved along the axis of finger to cut the A1 pulley. The procedure is completed when grating sensation of cutting of A1 pulley ceases. The patient is asked to move his finger and free movement of finger without clicking is confirmed. A tincture benzoin soaked gauze piece applied with pressure to stop bleeding.

**Steroid injection technique:** 1 ml of 40 mg Triamcinolone (Inj Kenacort) along with 1 ml of 2% lignocaine is aspirated in a 5 ml syringe. A 25 gauge needle is inserted on volar side through the A1 pulley and tendon till it stops at the

metacarpal bone. The needle is slightly retracted and the drug is injected. This drug spreads in the region between flexor sheath and flexor tendon.

NSAIDs and paracetamol are given to patients for 5 days after the procedure.

11 patients were given additional steroid injection who had persistent pain and clicking at the end of 3 days after 1st steroid injection. No additional procedure was required in Group A patients.

Visual Analogue pain score was used to assess pain at the end of 1 month and 6 months.

Fisher exact test was used to analyze data of satisfactory cases at the end of 1 month and six months. The difference in pain scores after treatment in each group were further normalised. The formula used was - percentage change = [(score after treatment - score before treatment)/score before treatment] \*100.

After normalisation, the pain score difference of 2 groups were evaluated by independent samples t-test. The level of significance was taken as p value <0.05. All data were analysed using SPSS Inc. version 25.

Results- The study had Patients had a high success in Group A. At the end of 1 month and 6 months, 48 and 50 trigger fingers in patients respectively had satisfactory results. Contrary to that, Group B had worsening of results in due course of time. At the end of 1 month, 28 trigger fingers in patients were satisfied with steroid injection, which went further down to only 12 trigger fingers in patients at the end of 6 months. The Fisher exact test showed statistically significant improvement in normalised pain score of the Group A over group B. No complications of injury to nerve, vessel, tendon were seen in any of the patients.

Table 1: Chart showing changes in pain scores at 1 month and 6 months

	Baseline	baseline	1 month	1 month	1 month	1 month	6 months	6 months	6 months	6 months
	Number	VAS	Satisfaction	Dissatisfaction	VAS	% change	Satisfaction	Dissatisfaction	VAS	% change (Negative)
Group A	50	6.9	48	2	1.1	75.53	50	1	0.8	98.68
Group B	49	6.6	28	21	4.3	34.21	12	37	5.8	10.34
p value						<0.001				<0.001

Chart 2- Data showing satisfaction levels of group A= Percutaneous A1 pulley release and Group B- Steroid injection, at 3 stages- Baseline-before procedure, and 1 month and 6 month after procedure.

**Discussion**

Percutaneous method has been first used by Lorthioir *et al.* [9]. In 1958. Since then many modifications and improvements have been done in this technique.

The following table shows the results of percutaneous release of trigger finger by various investigators.

**Table 2:** Previous similar studies with results

Investigator	Trigger Finger numbers	Technique notes	Satisfaction rates
Eastwood <i>et al.</i> [10].	35	21 gauge needle	94%
Ragoowansi <i>et al.</i> [7].	240	Lift cut technique 19 gauge needle	94%
Park <i>et al.</i> [11].	118	Special hook with cutting edge	91%
Sato <i>et al.</i> [13].	76	Percutaneous technique	96%
Blumberg <i>et al.</i> [14].	30	Percutaneous technique	97%

Our study showed 98% satisfaction levels at the end of 6 months, with technique of percutaneous release of A1 pulley. Marks *et al.* [8]. And Frieberg *et al.* [3]. Had 92% and 77% satisfaction levels in their patients with only steroid injections for trigger fingers. Studies later showed, Sato *et al.* [11-13]. And Chako *et al.* [6]. Showed 86% and 26% satisfactory results with steroid injection.

Adverse outcomes like steroid flare, tendon ruptures, local infection and subcutaneous fat atrophy have been reported in different studies [15, 16].

The reason for our study to show poor results in steroid injection group may be due to our selection criteria in which we only included patients with grade 3, 4 and 5 cases.

The higher success rate of our percutaneous technique can be attributed to active flexion extension done by patient to assess complete release of A1 pulley, before we end the procedure.

There were few limitations to our study. We have not blinded the investigators. The sample size could have been more. The followup period could have been more in order to evaluate the long term effects of such procedures.

In conclusion, we think percutaneous release of A1 pulley in cases of trigger finger is better than steroid injection. Percutaneous release can be done as an outpatient clinic procedure with good success rates.

## References

1. Quinell RC. Conservative management of trigger finger. *Practitioner.* 1980; 224:187-190.
2. Lee M, Jung YR, Lee YK. Trigger finger secondary to a neglected flexor tendon rupture. *Medicine.* 2019; 98:e13980.
3. Freiberg A, Mulholland RS, Levine R. Nonoperative treatment of trigger fingers and thumbs. *The journal of hand surgery.* 1989; 14:553-558.
4. Matthews A, Smith K, Read L, Nicholas J, Schmidt E. Trigger finger: An overview of the treatment options. *JAAPA.* 2019; 32:17-21.
5. Carrozzella J, Stern PJ, Von Kuster LC. Transection of radial digital nerve of the thumb during trigger release. *The journal of hand surgery.* 1989; 14:198-200.
6. Chao M, Wu S, Yan T. The effect of miniscalpel-needle versus steroid injection for trigger thumb release. *J Hand Surg. Eur.* 2009; 34:522-525.
7. Ragoowansi R, Acornley A, Khoo CT. Percutaneous trigger finger release: the lift-cut technique. *British Journal of Plastic Surgery.* 2005; 58:817-821.
8. Marks MR, Gunther SF. Efficacy of cortisone injection in treatment of trigger fingers and thumbs. *The journal of hand surgery.* 1989; 14:722-727.
9. Lorthioir J. Surgical treatment of trigger-finger by a subcutaneous method. *The journal of bone & joint surgery.* 1958; 40:793-795.
10. Eastwood DM, Gupta KJ, Johnson DP. Percutaneous release of the trigger finger: An office procedure. *The journal of hand surgery.* 1992; 17:114-117.
11. Park MJ, Oh I, Ha KI. A1 pulley release of locked trigger digit by percutaneous technique. *J. Hand Surg. Br.* 2004; 29:502-505.
12. Sato ES, dos Santos JBG, Belloti JC, Albertoni WM, Faloppa F. Treatment of trigger finger: randomized clinical trial comparing the methods of corticosteroid injection, percutaneous release and open surgery. *Rheumatology.* 2012; 51:93-99.
13. Sato ES, dos Santos JBG, Belloti JC, Albertoni WM, Faloppa F. Percutaneous release of trigger fingers. *Hand clinics.* 2014; 30:39-45.
14. Blumberg N, Arbel R, Dekel S. Percutaneous release of trigger digits. *Journal of hand surgery.* 2001; 26:256-257.
15. Stahl S, Kanter Y, Karnielli E. Outcome of trigger finger treatment in diabetes. *Journal of diabetes and its complications.* 1997; 11:287-290.
16. Taras JS, Iilams GJ, Gibbons M, Culp RW. Flexor pollicis longus rupture in a trigger thumb: A case report. *The journal of hand surgery.* 1995; 20:276-277.