



International Journal of Orthopaedics Sciences

ISSN: 2395-1958
IJOS 2019; 5(3): 441-445
© 2019 IJOS
www.orthopaper.com
Received: 09-05-2019
Accepted: 12-06-2019

Dr. Rajesh Bobba
Assistant Professor, Department
of Orthopedics, Karpaga
Vinayaga Institute of Medical
Sciences and Research Centre,
Madhuranthagam, Tamil Nadu,
India

Dr. Aravind Kumar
Assistant Professor, Department
of Orthopedics, Karpaga
Vinayaga Institute of Medical
Sciences and Research Centre,
Madhuranthagam, Tamil Nadu,
India

Fixation of displaced midshaft clavicle fractures using precontoured locking compression plate in adults

Dr. Rajesh Bobba and Dr. Aravind Kumar

DOI: <https://doi.org/10.22271/ortho.2019.v5.i3h.1569>

Abstract

Background: Fractures of the clavicle are one of the injuries which are often inadequately treated. Non-union, malunion and shortening arising out of nonoperatively treated clavicular fractures cause significant disability due to pain, impaired function of the shoulder joint and limitations of activities. To evaluate the functional outcome following precontoured locking compression plate fixation in displaced midshaft clavicle fractures in adults using Constant and Murley scoring and to assess interrelationship among different covariates.

Materials and Methods: Study was conducted at Karpaga Vinayaga Institute of Medical Sciences, Madhuranthagam, Tamil Nadu. Forty patients with displaced midshaft clavicular fractures operated using precontoured locking compression plates were recruited for the study. They are followed up for a period of six months and the outcome was noted. The primary outcome was assessed by Constant-Murley Scoring system and the results were analysed with statistical tools.

Results: In our study the mean Constant and Murley scoring was 89.60 at the end of six months. Average time taken for radiological union was 13.45 weeks. We found a statistically significant difference (p value <0.001) in Constant and Murley scores between the first month, third month and sixth months indicating improvement in functional status of the patient over a period of six months after surgery. There were no cases of implant removal due to hardware prominence despite having had this complication in four of our cases (20%).

Conclusion: Based on our study, we recommend the use of precontoured locking compression plates for displaced midshaft clavicular fractures. These plates also avoid the need for intra operative contouring and potentially eliminate the necessity of a second surgery for implant removal. Sterile precautions, early surgery, perfect anatomical reduction and early postoperative rehabilitation are needed to achieve favourable results.

Keywords: Clavicle fractures, midshaft fractures, precontoured locking, surgical fixation, rehabilitation

Introduction

Clavicular fractures are one of the most common bony injuries accounting for 2.6% to 4% of all fractures caused by either low-energy or high-energy impact. About 70-80% of clavicular fractures occur in the middle third of the bone and less often in the lateral third (12-15%) and medial third (5-8%) [1-4]. Fractures of the clavicle have traditionally been treated non-operatively [3]. In literature there are various studies which advocate non-operative management of displaced clavicle fractures by closed reduction methods and non-operative immobilization [3, 4]. Although many methods of closed reduction have been described, it is recognized that reduction is impossible to maintain without surgical fixation. Hence non-operative methods of treatment cause residual deformity and disability [3, 4]. More recent data, based on detailed classification of fractures, suggest that the incidence of non-union in displaced comminuted midshaft clavicular fractures in adults is between 10 and 15% [5-8]. Surgery is accepted more and more as a primary treatment for displaced midshaft clavicular fractures, mainly because the outcome of non-operative treatment is inferior to operative treatment both clinically and functionally [6, 8-13].

Though enormous data from global orthopaedic literature on the effect of functional outcome of plate osteosynthesis is available, Indian evidence regarding the role of precontoured locking plate in clavicle fixation is still growing. This study was carried out to analyse the functional outcome and early rehabilitation following clavicular fixation using precontoured locking plate

Correspondence

Dr. Rajesh Bobba
Assistant Professor, Department
of Orthopedics, Karpaga
Vinayaga Institute of Medical
Sciences and Research Centre,
Madhuranthagam, Tamil Nadu,
India

in Indian population. Also to understand the time taken for radiological union of clavicular fractures following fixation.

Materials and Methods

Present study was conducted in department of Orthopedics of Karpaga Vinayaga Institute of Medical Sciences and Research Centre, a tertiary care hospital. Study population includes 40 patients from the surrounding places of our tertiary care hospital. All the patients who have been operated with precontoured locking compression plate for displaced midshaft clavicular fractures in the Department of Orthopaedics, at Karpaga Vinayaga Institute of Medical Sciences and Research Centre, Madhuranthagam, Tamil Nadu. All the patients operated during the period of March 2015 to April 2017 were followed up prospectively for a period of 6 months. A written informed consent was obtained from all the subjects. The study was approved by the ethical committee of the Hospital.

Inclusion criteria

Adult male and female patients above 18 years and below 60 years who require surgical intervention for acute displaced middle third clavicular fractures (Robinson Type 2 B).

Exclusion criteria

Patients less than 18 years of age and above 60 years of age, Patients with pre-existing shoulder diseases affecting assessment of functional outcome following surgery, Patients with severe co-morbidities affecting post-operative rehabilitation, Pathological fractures, Open fractures.

At the time of admission, demographic data collection regarding age, gender, occupation, mode of injury and functional status of the patient were noted. On clinical examination the following findings were noted at the time of admission - side of injury, overlying skin condition, respiratory status, associated injuries and neurovascular examination of the affected side. Radiological analysis includes - Standard anteroposterior radiograph of the involved clavicle with the patient lying in supine position was done at the time of admission. The fracture displacement and comminution was noted based on these X-rays. Length of the plate to be used during surgery was assessed provisionally. Functional outcome was assessed by Constant and Murley scoring [14].

Surgical method

Open reduction and internal fixation with pre contoured clavicle plate. Surgical procedure was carried out under general anaesthesia.

Statistical analysis

The socio demographic factors like age, gender of the patient, mode of injury, side of injury and initial type and classification of injury were considered as primary explanatory variables. The functional outcome as assessed by Constant and Murley score was the primary outcome. Complications which occurred in the study group, including the hardware prominence, were the other outcomes considered for analysis. Initial descriptive analysis of all the variables was done using frequencies and percentages for categorical variables and means and standard deviations for quantitative variables. The association between the explanatory and outcome variables was done by using the difference in proportions or means. IBM SPSS version 21 was used for data analysis.

Results

Out of 40 patients in our study, majority (70%) belonged to the age groups 20-30 years and 41-50 years. Out of 40 patients, 30 patients were males. Males comprised 75% and females were 25%. Left clavicle was involved in 24 of our patients (60%) and right clavicle was involved in 16 of our patients (40%).

Road traffic accident was the mode of injury in majority of our cases (n=26, 65%) while accidental fall (n=10, 25%) and direct injury (n=4, 10%) were the other causes in rest of our cases. Based on Robinson classification, 28 cases (70%) belonged to Type 2 B1 and 12 (30%) cases belonged to Type 2 B2. In our study, hardware prominence was reported to be the significant complication in 8 patients (20%) which required no intervention during the study period. At the time of first month follow-up, majority (65%) had fair outcome. At the end of third month, 17 patients (85%) showed good outcome. During the last follow-up at sixth month, majority (n=14) showed excellent outcome (70%).

Radiological union occurred at an average of 13.45 weeks (SD 1.432) in our study. One patient had delayed union at a period of 18 weeks post-operatively. In our study, the overall outcome at the end of six months was excellent in 14 patients (70%), good in 5 patients (25%) and fair in one patient (5%).

The proportion of patients with excellent outcome was 80% in males, whereas it was only 40% in females. 40% of females and 20% of males had good outcome. Only one female had fair outcome (20%). The association between gender and outcome was not statistically significant (p value 0.108). [Table 1 and Table 2]

The proportion of subjects with excellent outcome was lesser in people who had developed any of the complications (55.6% vs 81.8%), when compared with subjects who had complication-free post-operative period. But the difference in the proportion of subjects with various outcomes between the two groups was not statistically significant.

The mean Constant Murley score was 71.85 at the first month of follow up. It was 83.05 and 89.60 at third and sixth month of follow up respectively. The differences in the mean values of the score during the different follow up periods were statistically significant (p value <0.001). Paired sample t-test was used to assess the statistical significance, considering the first month score as baseline. [Table 3 and Table 4]

The present study demonstrates a significant improvement in functional score over a period of six months. [Figure 1]

Table 1: Descriptive analysis of functional outcome using Constant and Murley scoring system after every follow-up

| Parameter | Frequency | Percentage |
|--------------------|-----------|------------|
| First Month | | |
| Poor | 14 | 35.0 |
| Fair | 26 | 65.0 |
| Third Month | | |
| Fair | 6 | 15.0 |
| Good | 34 | 85.0 |
| Sixth Month | | |
| Fair | 2 | 5.0 |
| Good | 10 | 25.0 |
| Excellent | 28 | 70.0 |

Table 2: Association of gender with outcome in study population

| Gender | Outcome | | | Chi Square Value | p Value |
|--------|-----------|---------|---------|------------------|---------|
| | Excellent | Good | Fair | | |
| Female | 4 (40%) | 4 (40%) | 2 (20%) | 4.457 | 0.11 |
| Male | 24 (80%) | 6 (20%) | 0 | | |

Table 3: Association between complications and outcome in study population

| Complication | Outcome | | | Chi Square Value | p Value |
|--------------|------------|-----------|-----------|------------------|---------|
| | Excellent | Good | Fair | | |
| Yes (18) | 10 (55.6%) | 6 (33.3%) | 2 (11.0%) | 2.165 | 0.339 |
| No (22) | 18 (81.8%) | 4 (18.2%) | 0 (0%) | | |

Table 4: Comparison of Constant Murley scores during the follow up period in study population

| Month | Mean of Constant Murley Score | Mean Difference | p-Value | 95% CI | |
|------------------------|-------------------------------|-----------------|---------|--------|-------|
| | | | | Lower | Upper |
| First Month (Baseline) | 71.85 | - | - | - | - |
| Third Month | 83.05 | 11.20 | <0.001 | 9.28 | 13.11 |
| Sixth Month | 89.60 | 17.75 | <0.001 | 15.66 | 19.83 |

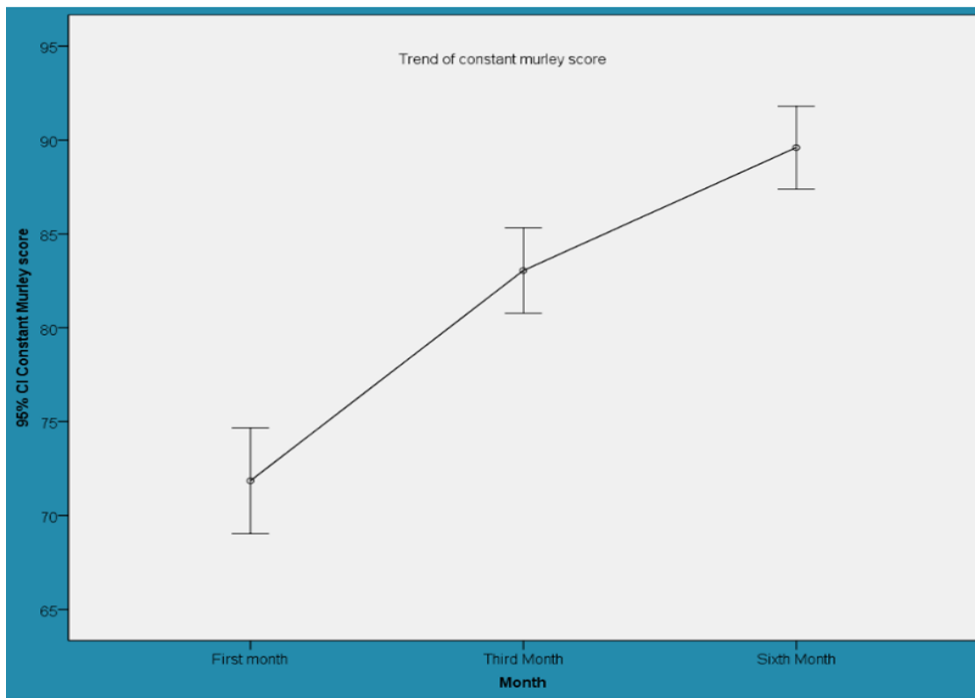


Fig 1: Error bars representing the trend of mean Constant – Murley score during the follow up period

Discussion

Clavicle fractures have been historically treated conservatively since the times of Hippocrates. “Watchful expectancy and skilful neglect” has been the basic principle in managing these fractures, resulting in malunion, shortening and in some cases non-union [13 - 17]. Various studies have now shown that shortening more than 2 cm influences the outcome in the midshaft clavicle fractures [18 – 22].

Conservative treatment still remains the treatment of choice for undisplaced midshaft clavicle fractures (Robinson Type 2A) with a reported incidence of 5.9% of non-union. But at the same time, displaced fractures (Robinson Type 2B) have non-union rates as high as 15.1% when treated nonoperatively [18, 23].

Recent literature suggests that the operative management of displaced middle third clavicle fractures resulted in lower non-union rates, improved functional outcome, faster mobilisation, better cosmesis and increased patient satisfaction with results supported by several studies including that of the Canadian Orthopaedic Trauma Society which reported higher rates of complications following conservative management of displaced fractures [8, 17, 18].

The advent of anatomically precontoured locking compression plates has been a boon to the management of these fractures where a considerable amount of intra operative time is used to contour the conventional plates. Also

precontoured plates have a theoretical advantage of reduced plate fatigue fracture compared to non-contoured plates which are subjected to intra operative bending [24-28].

At our institute we conducted a prospective study in 40 patients with midshaft displaced clavicle fractures who underwent operative fixation in the form of precontoured locking plate osteosynthesis. The analysis of results was made in terms of age of patients, mode of injury, type of fracture, associated injuries, time taken for radiological union, complications and functional outcome. The ability to compare our results to the results of other studies is limited because there are few reports dealing with the same implant and because of differences in the study cohorts distribution and outcome measurements. Hence, the sample size was estimated based on conventional statistical formulas.

In the present study, functional scoring was done using Constant-Murley scoring system which showed an average score of 89.6 at the end of six months. This is comparable to the study published by Choudhari *et al.* [10], which showed a mean Constant score of 89.3. In the final follow-up, outcome was excellent in 14 cases (70%), good in 5 cases (25%) and fair in 1 case (5%). The cause of fair outcome in one patient was due to the fact that she developed post-traumatic stiffness following surgery due to non-adherence to our physiotherapy protocol [29-31]. This study has shown significant improvement in mean Constant score over a period of six months follow up

($p < 0.001$). This is in concordance with the study conducted by Canadian Orthopaedic Trauma Society which showed significant p values ($p < 0.01$) over a period of six months follow up [8]. The trend in improvements in functional score over a period of six months indicates that patients tend to do well over a period of time following surgery provided they are compliant to the post-operative physiotherapy protocol.

Regarding the mode of injury, road traffic accidents (RTA) were the cause of highest number of fractures in our study population (65%) followed by accidental fall from height (25%). This is consistent with the study conducted by Kulshrestha *et al.* [26], which reported 75% of cases due to RTA and another study by Hundekar [31], which reported 70% cases due to RTA.

Based on age analysis, the highest incidence of fractures in our series has occurred in the age group of 20-30 years (35%) which is comparable to the study conducted by Kulshrestha *et al.* [26], which reported an age group of 21-46 years. Based on gender analysis, males were shown to be more affected with 75% of fractures in men. This is consistent with the study conducted by Hundekar [31], which reported 80% fractures occurring in males. Based on side analysis, more number of fractures occurred in left side (60%) which has been shown to be of no statistical significance. Radiological union, as assessed by complete cortical bridging between proximal and distal fragments on X-rays, was found to be at an average of 13.5 weeks (SD-1.432). Hundekar reported radiological union over a period of 10-16 weeks which was closest to our series. Kulshrestha *et al.* and Jeffrey *et al.* [26], showed much better results with union occurring over a period of 8-9 weeks. In the study conducted by the Canadian Orthopaedic Trauma Society, radiological union was reported at an average of 16.4 weeks [8].

In the present study, there were no non-union, malunion, hardware failure and deep infection. This is consistent with the studies by Hundekar and Jeffrey *et al.* which reported similar results [26]. The complications in our study were hardware prominence in 4 patients (20%), superficial haematoma in 1 patient (5%), superficial wound infection in 1 patient (5%), delayed union in 1 patient (5%) in whom radiological union occurred at 18 weeks after surgery which was against our series average of 13.45 weeks for union, hypertrophic scar in 1 patient (5%) and prolonged hypoesthesia around operated site in 1 patient (5%) which improved over a period of 16-18 weeks. Hardware prominence occurred in 32.1% of cases in the study reported by Van Beek *et al.* [25], warranting plate removal after fracture union. Chandrasenan *et al.* [2], reported hypoesthesia in 3 out of 15 patients (20%). McKee *et al.* [6], reported superficial wound infection in 3 out of 62 patients and numbness in 18 out of 62 patients. The results of these studies are consistent with the complications reported in our study.

Interestingly, implant removal was not done in any of the patients during the period of study including the patients in the hardware prominence group ($n=4$). This is due to the fact that all the plates used were anatomically precontoured and moreover the patients were satisfied with the final functional outcome after surgery and hence did not want to undergo a second surgery for implant removal. This is consistent with the results published by Chandrasenan *et al.* [2], which report 0% implant removal in patients treated using precontoured locking compression plate. In other series which used implants other than locking plates, the removal rate ranged from 41% as reported by Jeffrey *et al.* (7 out of 17 cases) [19], to 64.3% removal rates as reported by Van Beek *et al.* (9 out

of 14 patients) [24]. Hence this reiterates the fact that use of precontoured locking compression plate avoids the potential for a second surgery to remove the implant.

Conclusion

It is concluded that the functional outcome following precontoured locking compression plate fixation of displaced midshaft clavicle fractures in adults has produced excellent results in majority of cases with acceptable complications with no additional need for implant removal after union. The pre contoured locking compression plate for clavicle is a good implant to use for displaced midshaft clavicle fractures. We recommend use of this implant in Robinson Type 2 B fractures of the clavicle where it should be considered as the treatment of choice.

Based on this study results in terms of time taken for radiological union and final functional outcome are satisfactory. Also, the union rate was 100%, with acceptable complications like hardware prominence and superficial infection which did not affect the outcome of our study. Proper selection of cases, early surgery, accurate positioning and fixation, good and early postoperative rehabilitation and regular follow up are needed to achieve favorable results. We recommend aggressive rehabilitation therapy to regain complete range of motion of shoulder so that better functional outcomes are achieved in a shorter period.

Conflict of interests: None

Financial Support: We would like to thank our Managing Director, Dr. Reguapthy Annamalai for his encouragement and for financial support in accomplishing this project.

Acknowledgements

I would like to thank Dr. Amar Nagesh Kumar, Department of Biochemistry of Karpaga Vinayaga Institute of Medical Sciences and Research Centre, for his help in statistical analysis and in drafting the manuscript.

References

1. Stegeman SA, de Jong M, Sier CFM *et al.* Displaced Midshaft Fractures of the Clavicle: Non Operative Treatment Versus Plate Fixation (Sleutel-TRIAL). A Multicentre Randomised Controlled Trial. BMC Musculoskeletal Disorders. 2011; 12:196.
2. Chandrasenan J, Espag M, Dias R, Clark DI. The use of anatomic precontoured plates in the treatment of midshaft clavicle fractures. J Bone Joint Surg Br. 2009; 91-B (Sup. I):179-180.
3. Zenni EJ Jr., Krieg JK, Rosen MJ. Open reduction and internal fixation of Clavicular fractures. J Bone Joint Surg Am. 1981; 63(1):147-151.
4. Jupiter JB, Leffert RD. Non-union of the clavicle. Associated complications and surgical management. J Bone Joint Surg Am. 1987; 69(5):753-760.
5. Iannotti MR, Crosby LA, Stafford P, Grayson G, Goulet R. Effects of plate location and selection on the stability of midshaft clavicle osteotomies: A biomechanical study. J Shoulder Elbow Surg. 2002; 11:457-462.
6. McKee MD, Wild LM, Schemitsch EH. Midshaft malunion of the clavicle. J Bone Joint Surg Am. 2003; 85(5):790-797.
7. McKee MD, Pedersen EM, Jones C, Stephen DJ, Kreder HJ, Schemitsch EH *et al.* Deficits following non-operative treatment of displaced midshaft clavicular fractures. J Bone Joint Surg Am. 2006; 88(1):35-40.

8. Canadian Orthopaedic Trauma Society. Non-operative treatment compared with plate fixation of displaced midshaft clavicular fractures. A multicenter randomized clinical trial. *J Bone Joint Surg Am.* Jan. 2007; 89(1):1-10.
9. Huang JI, Toogood P, Chen MR, Wilber JH, Cooperman DR. Clavicular anatomy and the applicability of pre-contoured plates. *J Bone Joint Surg Am.* 2007; 89(10):2260-2265.
10. Choudhari, Chhabra. Displaced Mid-Shaft Clavicle Fractures: A Subset for Surgical Treatment. *Malaysia Orthopaedic Journal.* 2014; 8(2):1-5.
11. Chul-Hyun Cho, Kwang-Soon Song, Byung-Woo Min, KiCheor Bae, Kyung-Jae Lee. Reconstruction Plate versus Reconstruction Locking Compression Plate for Clavicle Fractures. *Clinics in Orthopaedic Surgery.* 2010; 2:154-159.
12. Darren Drosdowech S, Biomechanical analysis of fixation of middle third fractures of clavicle. *J Orthop Trauma.* 2011; 25(1):39-43.
13. Kaisa Virtanen J, Antti Malmivaara OV, Ville Remes M, Mika Paavola P. Operative and non-operative treatment of clavicle fractures in adults-A systematic review of 1,190 patients from the literature. *Acta Orthopædica.* 2012; 83(1):65-73.
14. Mohammed Yasin N, Syed Naqui Z, Lindsay TSW. Muir. The reliability of the Constant–Murley shoulder scoring system. *Shoulder and Elbow.* 2010; 2:259-262.
15. Ban I, Branner U, Holck K, Krashennikoff M, Troelsen A. Clavicle fractures may be conservatively treated with acceptable results – a systematic review. *Dan Med J.* 2012; 59(7):A4457.
16. Evaniew N, Simunovic N. Cochrane in CORR: Surgical Versus Conservative Interventions for Treating Fractures of the Middle Third of the Clavicle. *Clin Orthop Relat Res.* 2014; 472(9):2579-2585.
17. Millett PJ, Hurst JM. Complications of clavicle fractures treated with intramedullary fixation. *J Shoulder Elbow Surg.* 2011; 20(1):86-91.
18. Wijdicks RFJG, Houwert M. Systematic review of complications after intramedullary fixation for displaced midshaft clavicle fractures. *Can J Surg.* 2013; 56(1):58-64.
19. Zlowodzki M, Zelle BA, Cole PA, Jeray K, McKee MD. Evidence Based Orthopaedic Trauma Working Group. Treatment of acute midshaft clavicle fractures: systematic review of 2144 fractures. *J Orthop Trauma.* 2005; 19(7):504-507.
20. Jonathan Bravman T, Michal Taylor L, Todd Baldini, Armando Vidal F. Unicortical versus bicortical locked plate fixation in midshaft clavicle fractures. *Orthopedics.* 2015; 38(5):411-416.
21. Yaron Brin S, MD, Ezequiel Palmanovich MD. Displaced Mid-Shaft Clavicular Fractures: Is Conservative Treatment Still Preferred? *IMAJ,* 2014, 16.
22. Grechenig W, Heidari N, Leitgoeb O, Prager W, Pichler W, Weinberg AM. Is plating of mid-shaft clavicular fractures possible with a conventional straight 3.5 millimeter locking compression plate? *Acta Orthop Traumatol Turc.* 2011; 45(2):115-119.
23. Robert Hillen J, Bart Burger J. Malunion after midshaft clavicle fractures in adults -Current view on clavicular malunion in the literature. *Acta Orthopaedic.* 2010; 81(3):273-279.
24. Demirhan M, Bilsel K, Atalar AC, Bozdog E, Sunbuloglu E, Kale A. Biomechanical comparison of fixation techniques in midshaft clavicular fractures. *J Orthop Trauma.* 2011; 25(5):272-278.
25. Van Beek C, Boselli KJ, Cadet ER, Ahmad CS, Levine WN. Precontoured plating of clavicle fractures: Decreased hardware-related complications? *Clin Orthop Relat Res.* 2011; 469(12):3337-3343.
26. Wg Cdr V. Kulshrestha. Primary Plating of Displaced Mid-Shaft Clavicular Fractures. *Med J Armed Forces India.* 2008; 64(3):208-211.
27. Frans-Jasper G, Wijdicks Olivier AJ, Van der Meijden, Peter Millett J, Egbert Verleisdonk JMM, Marijn Houwert R. Systematic review of the complications of plate fixation of clavicle fractures. *Arch Orthop Trauma Surg.* 2012; 132(5):617-625.
28. Lazarides S, Zafiroopoulos G. Conservative treatment of fractures at the middle third of the clavicle: The relevance of shortening and clinical outcome. *J Shoulder Elbow surg.* 2006; 15(2):191-194.
29. Goswami T, Markert RJ, Anderson CG, Sundaram SS, Crosby LA. Biomechanical evaluation of a pre-contoured clavicle plate. *J Shoulder Elbow Surg.* 2008; 17(5):815-818.
30. Hamman D, Lindsey D, Dragoo J. Biomechanical analysis of bicortical versus unicortical locked plating of mid-clavicular fractures. *Arch Orthop Trauma Surg.* 2011; 131(6):773-778.
31. Hundekar B. Internal fixation of displaced middle third fractures of clavicle with precontoured locking plate. *Journal of Orthopaedics.* 2013; 10(2):79-85.