



International Journal of Orthopaedics Sciences

ISSN: 2395-1958

IJOS 2019; 5(3): 418-425

© 2019 IJOS

www.orthopaper.com

Received: 22-05-2019

Accepted: 26-06-2019

Dr. Muralidharan R

First Year MS Orthopaedics PG,
Department of Orthopaedics,
Sree Balaji Medical College and
Hospital, BIHER, Works Road,
New Colony, Chromepet,
Chennai, Tamil Nadu, India

Dr. Venkatachalam K

Professor and Unit Chief,
Department of Orthopaedics,
Sree Balaji Medical College and
Hospital, BIHER, Works Road,
New Colony, Chromepet,
Hennai, Tamil Nadu, India

A prospective study of the effectiveness of Ilizarov ring fixator in the surgical treatment of tibial fracture infective none: Unions in adults

Dr. Muralidharan R and Dr. Venkatachalam K

DOI: <https://doi.org/10.22271/ortho.2019.v5.i3g.1565>

Abstract

Infective non-unions of the tibia are a surgical challenge because of their compromised bone vascularity and are prone to limb shortening when treated by conventional methods. In this prospective case series done between January 2016 to December 2018, we treated 21 patients, reporting with infective non-union of the tibia by the application of Ilizarov external ring fixator. Surgical management of infective non-unions has drastically changed in the last two decades. The ring fixation device offers acute docking of the fracture non-union site and maintains compression, meanwhile any shortening that might have occurred due to either towards loss of comminuted fracture fragments or that lost during freshening of fracture non-union site can be addressed simultaneously, by doing a corticotomy and bone transport simultaneously as the non-unions progresses successfully to union. An additional benefit of the ring fixation device used to treat these non-unions is that patients can resume ambulatory status as early as within two weeks, from the date of surgery and can remain ambulant throughout the treatment time. The consolidation time in our series was anywhere between 9 months to 14 months, depending upon the length of transport that was needed to compensate for limb shortening. All 21 cases went on to successful union. We had 42.86% of minor complications and 18.98 % of major complications. As per the ASAMI grading, we had 52.5% excellent, 25.5% good, 17% fair and 5% of poor grading in our series, by averaging the bony and functional results. Hence our study concluded that the Ilizarov external ring fixator system is a versatile tool to surgically address infective tibial non- unions with or without bone length shortening.

Keywords: Ilizarov fixator, infective non-union tibia, distraction Osteogenesis

1. Introduction

The management of infected non-union of the tibia is demanding, particularly with part bone loss, many draining sinuses, unhealthy soft tissue cover, porotic bone, sub-adjacent joint stiffness, deformation, or poly drug-resistant poly-microbial infection [1-2]. It results in a permanent deficit in function, requires long recovery time and even sometimes results in amputation [3]. Even following proper guidelines and sterile technique, infection following the open fracture is still common [4-8]. Cost for management of the infective fracture is two to three times high compared to non-infected fracture [9-10]. Towards achieving control of infection, it is necessary to remove all necrosed and infected tissue and bone segments [11-12]. This results in the loss of some segment of bone. Ilizarov ring fixator uses the theory of 'distraction osteogenesis' which allows for the growth of bone, thus restoring the defect following excision [13-14] and also used in the treatment of non-union [15-21]. Ilizarov ring fixator helps in the treatment of non-union and also deformity correction by mono-focal and bi-focal technique [22]. Since by definition, non-unions can only be diagnosed retrospectively, when at least nine months have elapsed since the occurrence of fracture and when there is no evidence in the last three months that union will progress both clinically and radiologically. Infection under these conditions tends to become chronic, often with multi-drug resistant organisms. Infected non-union of the tibia is usually associated with deformation, loss of bone, leg-length inequality and loss of soft-tissue coverage. The aim is to target bony union, removal of infection and return of the functional use of the extremity through thorough debridement, coverage of soft tissue defects with flaps or skin grafts, use of antibiotic cement, autologous bone transplantation and free tissue transfer including bone transplants.

Correspondence

Dr. Venkatachalam K

Professor and Unit Chief,
Department of Orthopaedics,
Sree Balaji Medical College and
Hospital, BIHER, Works Road,
New Colony, Chromepet,
Hennai, Tamil Nadu, India

The procedure is done in stages, one at a time, this fail to correct LLD, prevents early rehab and delays recovery. Prof. Gavril Abramovich Ilizarov from the Siberian town of Kurgan in Russia, in 1950, developed a circular external fixator system which employed the principle of distraction osteogenesis to attain union, correct deformities and eradicate the infection in infected non-union. This modality of treatment has become a promising solution for infected non-unions since it was introduced world-wide. The Ilizarov technique of distraction osteogenesis enables to regenerate and cover extensive loss of bone and elimination of infected non-union at the same time, as well as permits early load-bearing.

1.1 Aims and Objectives

This prospective work aims to study and analyze the outcomes of Ilizarov ring fixator in the treatment of infected non-union in adult tibial fractures.

2. Materials and Methods

This prospective study was conducted at Sree Balaji Medical College and Hospital, Chrompet during the period from January 2016 to December 2018 in the Department of Orthopaedics. Written consent from all the patients was taken to publish their clinical and radiological data. Necessary clearance was also sought from the institution's research and ethical committee for the conduct of this study.

2.1 Inclusion criteria

- Both sexes in the age group 26 to 50 years.
- Bone loss of up to 7.5 cm.
- Infective causes of adult tibial Non-unions alone.
- Patients willing and fit for surgery.

2.2 Exclusion criteria

- Smokers, Immuno-compromised individuals and patients on blood-thinning drugs.
- Tuberculous non-unions.
- Non-union arising out of a primary pathological fracture.

2.3. Instrumentation

2.3.1 Primary Components

These are the standard parts that join the skeleton to the frame.

1. Trans-osseous wires – These are of three types.
 - a. Wire with trocar point.
 - b. Wire with bayonet point.
 - c. Olive wires.
2. Rings: These are of two types.
 - a. Full ring.
 - b. Half ring.
3. Wire fixation bolts.
4. Schanz pin.

2.3.2 Secondary Components

These are special elements used in the construction of the frame of the apparatus.

1. Threaded rods.
2. Support posts.
3. Hinges.
4. Connecting plate.

2.4 Operative Management

All patients conforming the inclusion criteria were taken up for study. All were assessed pre-operatively. The patients were explained about the procedure and consent was obtained pre-operatively. The pre-assembled ring was shown to all the patients well before surgery. They were explained about the additional procedure if needed.

In the elected infective non-unions of the tibia, the pus discharge from the sinuses, if any was sent for pus swab culture and sensitivity and appropriate parenteral antibiotics were initiated. The dressing was done daily with a silver stream solution (containing colloidal silver ions) for 2 to 3 weeks. After the discharge had minimised, the patient was taken up for operation. The patient was given suitable anaesthesia. Antiseptic painting and surgical drape of the affected limb was done. Debridement of the non-union site was done after removal of any previously secured hardware. The curetted material was sent for culture and sensitivity. At the non-union site, nibbling of the fracture ends was done until fresh bleeding was encountered. The medullary canals were thoroughly curetted and reamed. An autoclaved reconstructed Ilizarov ring frame was used. The number of rings was decided pre-operatively based on the fracture site and the site of proposed corticotomy. The frame was kept free between the internal part of the ring and the soft tissues all round over the thickest part of the leg. The limb was secured in the centre of the construct.

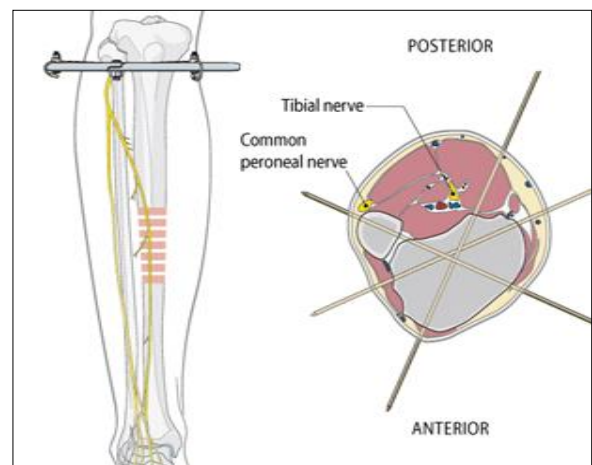


Fig 1: Proximal ring placement.

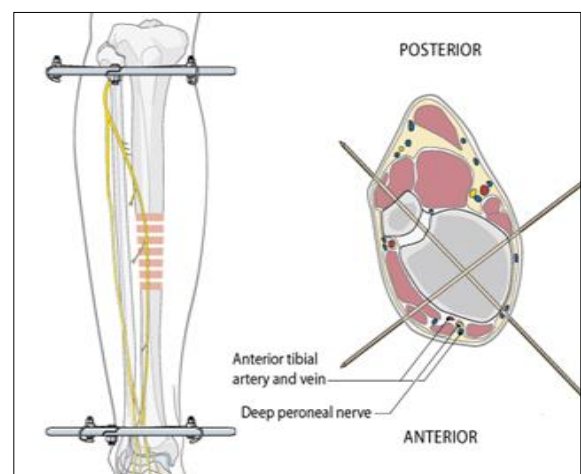


Fig 2: Distal ring placement.

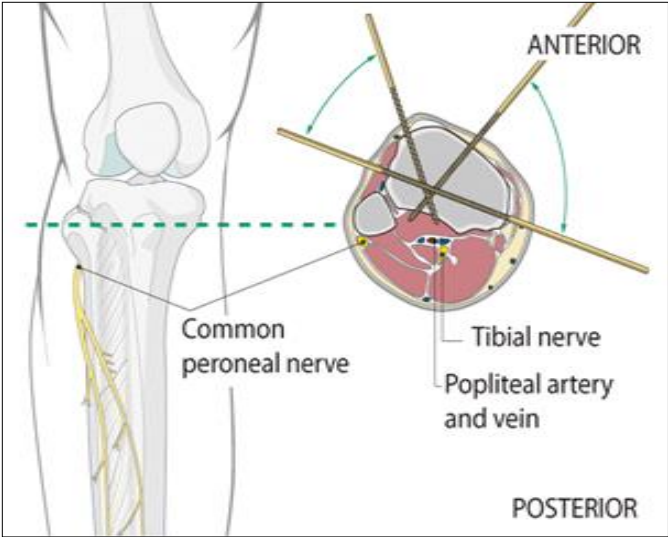


Fig 3: Safe zones for pin insertion.

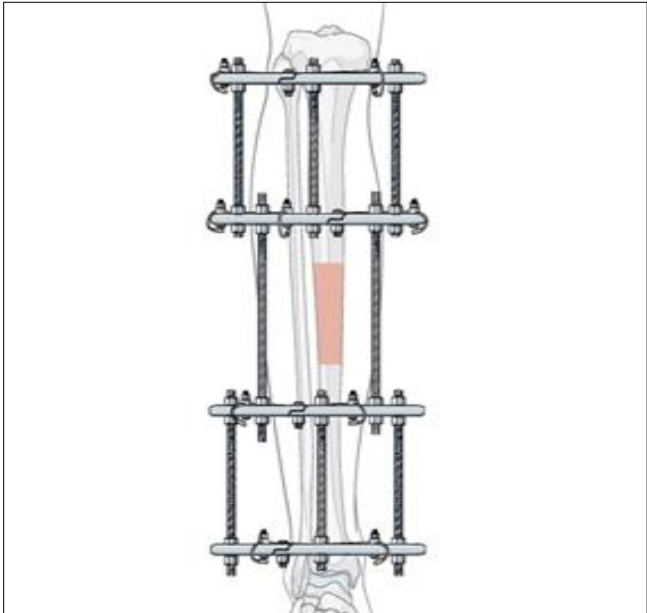


Fig 6: Reduction and final fixation.

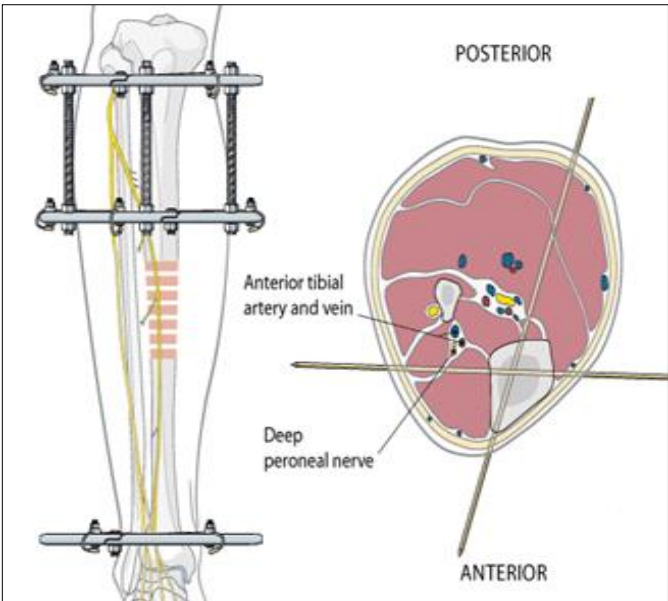


Fig 4: First intermediate ring.




Fig 7: Dynamometer tensioner.

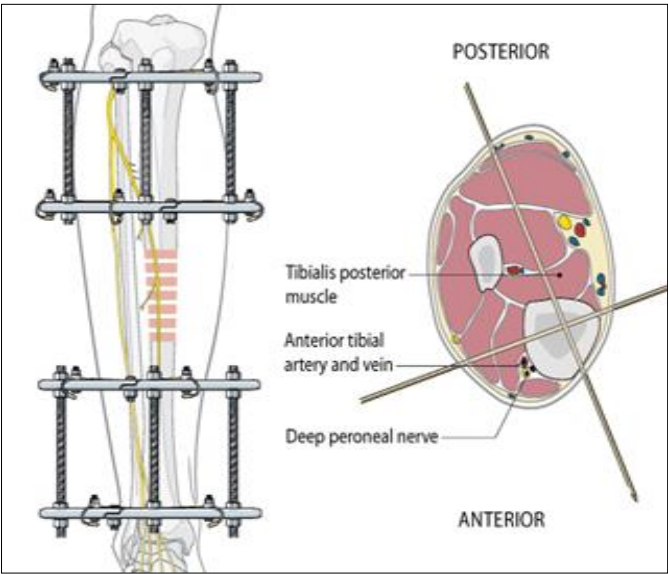


Fig 5: Second intermediate ring.



Fig 8: T-handle

and the parallelism of the distal ring (Fig. 2) was to the ankle joint. 1.8 mm wires were used for adults. Trocar pointed one were used for metaphyseal bone and bayonet pointed one for diaphyseal bone. Correct placement of wires is essential to control the movement of bone during the various procedures. The following rules are to be followed during wire insertion. The understanding of the axial section anatomy of the limb is used to pass the wires through safe corridors (Fig. 3), so that neuro-vascular structures are not injured. Before wire insertion, the skin should be shifted in such a direction as to allow adjacent joint motion. At areas of distraction maximum skin should be left loose. Shift the skin distally when mounting a ring proximal to the osteotomy. After insertion of wire, check for evidence of tissue tension while the limb is in its most functional position. If there is tension in the skin the wire is withdrawn below the skin surface, and the skin is adjusted to avoid tension, and then the wire is advanced so that it passes through the skin in a better position. If any vessel is injured while inserting wire as evident by a spurt in blood or local soft-tissue change, drilling is stopped, and local pressure applied. The distal pulses should be felt. A new entry is made, and drilling is done. The wires should be inserted from the more vulnerable side, and drilling should be started only after reaching the bone. The wire should be placed at 90-degree angles to each other for maximum stability. The wires of each pair should be in parallel planes about 0.5 mm apart so that each one should be on either side of each ring. The ends of the wire were tensioned with dynamometer tensioner (Fig. 7). The proximal ring was secured with wires at first to the limb. Then, the distal-most rings were secured by the wires proximal to the ankle joint. Depending upon whether or not there exists an element of limb shortening an appropriate level in the upper tibial metaphysis was chosen for subperiosteal corticotomy. Afterwards, depending upon the fracture geometry, full rings (Fig. 6) were secured with wires having a level of axial section anatomy in mind. The fibula was not secured with any of the wires. Proper tension was applied. Schanz pin, if needed were secured with necessary posts and bolts to the Ilizarov ring. A half centimetre incision was done and proceeded with drilling. A hybrid construct was mostly preferred. Half Schanz pin was inserted with the help of a T-handle (Fig. 8) manually. Conversely, an intact fibula contributes to the stability of the non-union. The fracture site was docked and compressed. Sterile pin-skin interface dressing was done with povidone-iodine. Distal limb vascularity was checked, post-operatively in all cases.

2.5 Post-op Protocol

The patients were advised to load-bearing with the use of axillary crutches on POD1. Distraction was initiated after a latency period of 72 to 120 hours, which is to allow for the ingrowth of vaso-formative elements and capillaries, for the restoration of blood supply, which was disrupted at the time of corticotomy. Distraction was taught to the patient and his relatives and they were treated on an outpatient basis with fortnightly reviews. The quality and quantity of the regenerate depend on the rate and rhythm of distraction. A distraction of 0.1 cm in 24 hours in four instalments was used during this study. For angular distraction also 0.1 centimetre per day is

the recommended rate; for delayed mineralization, the rate may be slowed to 0.75 mm per day or 0.5 mm per day. For soft tissue correction, a rate of 0.1 cm per 24 hours is used. Clearing of the rings and the wires using betadine and hydrogen peroxide was done by the patient. Any problems or obstacles that arose during treatment were managed accordingly.

2.6 Frame removal

The healing time is moderate with the Ilizarov techniques as it is a biological method of healing. In the X-ray, the regenerate should be remodelled with the cortex and medullary canal of almost equal cross-sectional girth to the mother bone corticotomy surfaces before frame removal.

Dynamisation – The nuts of the frame are loosened and the patient is allowed to walk in the frame. If the patient complains of no pain, then he is allowed to ambulate in the dynamised frame for about 15 days. Then the frame is removed, and a Plaster of Paris functional cast is applied for about a month. To sum up the various stages:

- Corticotomy.
- Latency.
- The distraction period.
- The consolidation period.
- The remodelling period.

2.7 Grading: ASAMI grading

The results are subdivided results of the bone and functional results.

2.7.1 Bone results:

1. Union.
2. Infection.
3. Deformity.
4. Leg length discrepancy.

Excellent: union, no infection.

Deformity < 7 degrees.

Leg length discrepancy < 2.5 cm.

Good: union plus any two or other criteria.

Fair: union plus any one of the other criteria.

Poor: non-union or refracture or union with none of the other criteria.

2.7.2 Functional results

Based on five criteria.

1. Significant limp.
2. Equinus rigidity of ankle.
3. Soft tissue dystrophy (skin hypersensitivity/insensitivity of Sole or decubitus).
4. Pain.
5. Inactivity.

Excellent: Active individual with none of the other four criteria.

Good: An Active individual with one or two of the other four criteria.

Fair: Active individual with three or four of the other four criteria.

Poor: Active individual poor result regardless or other criteria.

3. Results

Table 1: Age and Sex distribution.

Age in years.	Number of patients. 'n'			Percentage of patients.
	Male	Female	Total	
26 to 30 Years	1	0	1	5
31 to 35 Years	3	1	4	19
36 to 40 Years	5	2	7	33
41 to 45 Years	2	1	3	14
46 to 50 Years	4	2	6	29
Total	15	6	21	100%

Table 2: Treatment duration table. (For regenerate formation and consolidation)

Sex.	Bone Defect Shortening In cm.	"n"	Duration Of Treatment in Months (Lengthening, Regeneration Time).	Duration till Consolidation In Months.
Male	1 -3	5	6	9
	3-5	4	7	10
	5-7.5	6	9	12
Female	1-3	1	6.5	9.5
	3-5	1	8	11
	5-7.5	4	9	12

Table 3: Complication table.

Type.	Description.	"n"	Percentage of Patients.
Minor	Pin Loosening	4	19.05
	Pin Tract Infection	5	23.81
Major	Pin Removal or Exchange	3	14.28
	Fixator Removal	1	4.7
Total		13	61.84

Table 4: ASAMI grading: Bone Result.

Grade.	Number.	Percentage.
Excellent	12	57
Good	5	23
Fair	3	15
Poor	1	5

Table 5: ASAMI grading: Functional Result.

Grade.	Number.	Percentage.
Excellent	10	48
Good	6	28
Fair	4	19
Poor	1	5

Twenty-one patients satisfied our inclusion criteria. Of these 21 patients, there were 15 (71 %) males and 6 (29 %) females. Most of the patients were in the age group of 36 to 40 (33 %) followed closely by patients in the age group 46 to 50 (29 %). The average duration of the treatment ranged from 24 weeks to 36 weeks in the male category and 6.5-10 months in the female category. The average duration for consolidation was 9 to 12 months in the male category and 9.5 to 14 months in the female category. All cases went in for sound union. Our outcomes lead to the logical conclusions that in carefully selected cases and under scrupulous medical supervision, the Ilizarov ring fixator is an excellent choice for treating infective non-union of the tibia with a reasonable bone defect. As per the ASAMI grading, we had 52.5% excellent, 25.5% good, 17% fair and 5% of poor rating in our series, by averaging the bony and functional results.

4. Case Illustrations

4.1 Case Illustration 1

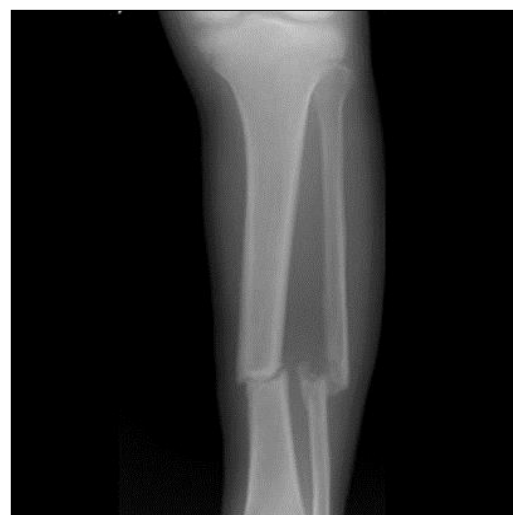

Fig 9: X-ray showing Non-Union Fracture Tibia and Fibula, six months post-injury.

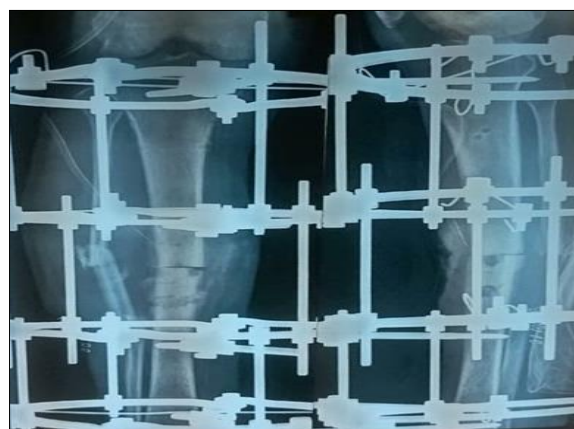

Fig 10: X-ray showing Non-Union Fracture Tibia and Fibula with Ilizarov fixator in-situ.

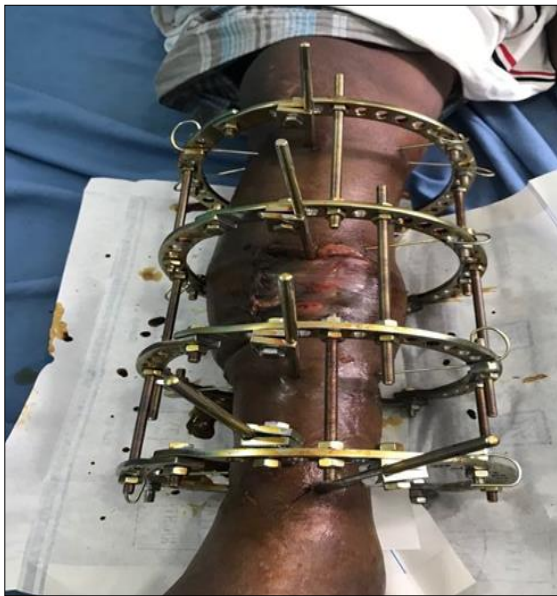


Fig 11: Clinical picture of the patient lower limb with Ilizarov fixator in-situ.

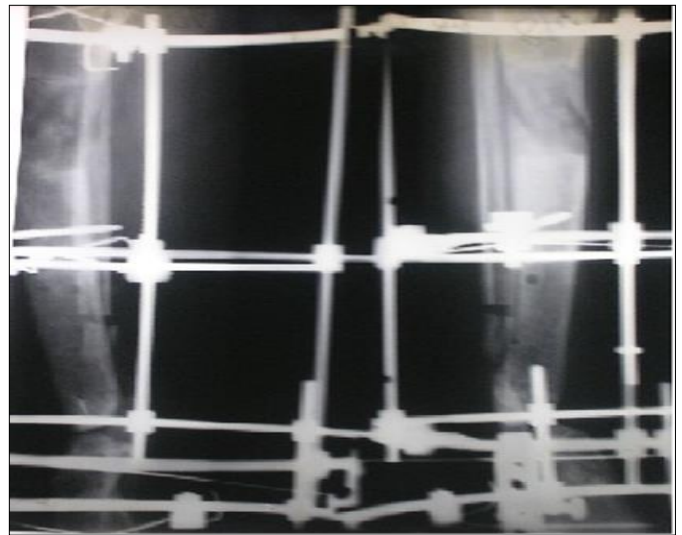


Fig 14: X-ray showing completion of transport with regenerate.

4.2 Case Illustration 2

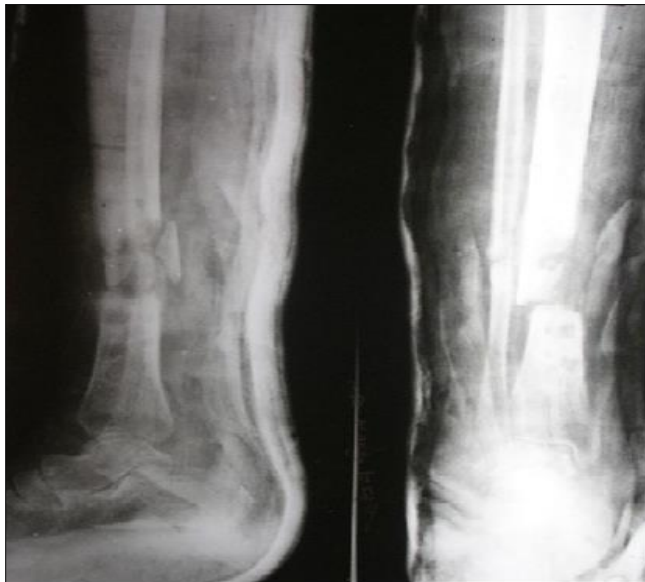

Fig 12: Pre-operative X-ray showing Non-union tibia.

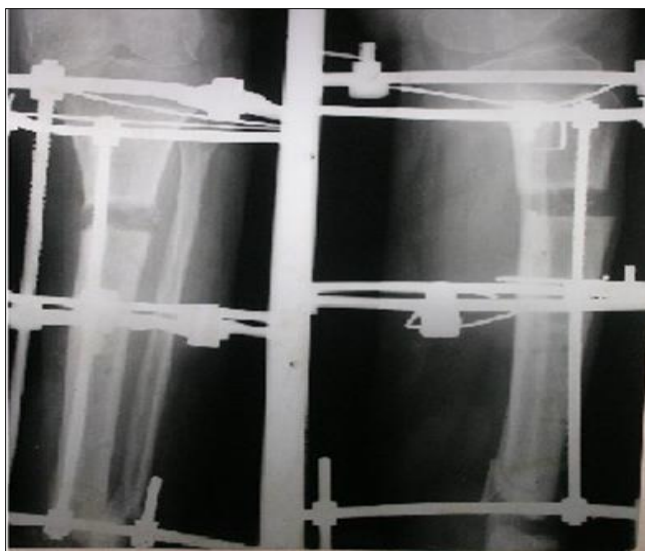

Fig 13: X-ray showing three weeks of gap Post transport.

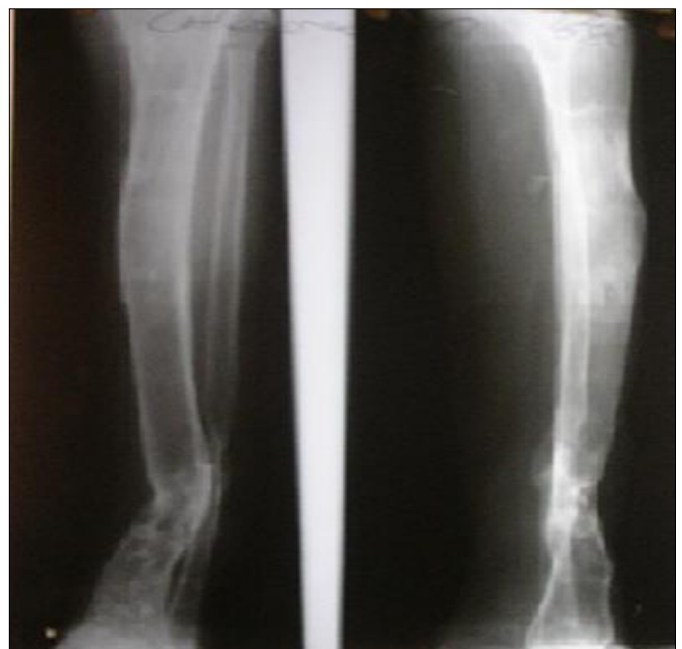


Fig 15: X-ray showing post ring Removal with the consolidation of regenerate.

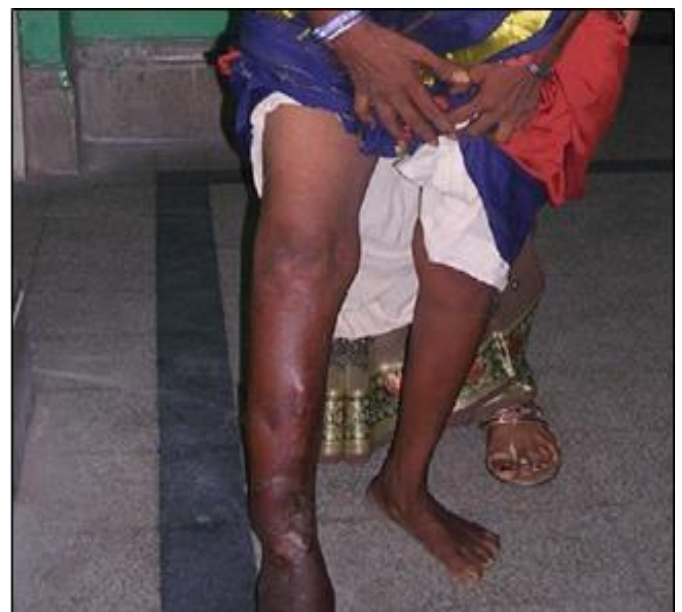

Fig 16: Clinical picture showing post ring removal.

5. Discussion

The series includes the study of 21 patients treated for infected non-union using the Ilizarov ring fixator during the period from January 2016 to December 2018 in the Department of Orthopaedics at Sree Balaji Medical College and Hospital. In this study, vehicular accidents accounted for 90% of injuries, while 10% were due to domestic accidents and falls. Most of the injuries had resulted in considerable soft tissue injury and bone loss, making the injury to be classified as non-union before the mandatory six-month period as defined by the FDA. Superficial pin-track infection occurred in 23.81% of cases. They were treated by parenteral and local antibiotic preparations. Pain during treatment was almost universal in occurrence. It was seen more at sites of a pin-track infection and the distraction site. Pain interfered with ambulation in some patients. The pain was controlled using oral Tramadol. Once the pain was relieved, almost all patients were made to ambulate. During the study, it was noted that pain tolerance and psychological profile of this patient was very important for the implementation of ambulation and physiotherapy. Two patients were employed in light occupations, while on treatment. The one failed case of our series was due to poor compliance resulting in premature decision to remove the apparatus before it has served the purpose. Thus, the patient selection criteria become one of the most important decisive factors in instituting this form of treatment. The multiple scars were cosmetically acceptable to all patients. After follow-up, it was noted that ankle movements never returned to normal. This was mostly due to contracture of the posterior soft tissue following prolonged

immobilization before treatment and poor compliance with load-bearing and exercise. The soft tissue healing was notably accelerated by increased vascularity in the limb. Soft tissue defects which were left open quickly granulated and skin cover was achieved without skin grafting in 17 cases. Three cases required a rotation flap cover and 1 case required SSG. Sinuses draining healed spontaneously on the application of the apparatus and restoration of stability. The stability in a properly applied Ilizarov frame is excellent and aids union. Non-union presents a therapeutic task to the orthopaedic surgeon. When traditional methods of managing these non-union fail, our study shows that the Ilizarov technique provides excellent results for the majority of patients when the infection is the cause for non-union. Thus in our series assessment by the ASAMI grading, we had 80% (n=17) of excellent to good bone result and 76% (n=16) of excellent to good functional result. We had 5% (n=1) of the poor result, which was due to poor patient compliance with the fixator, necessitating early removal of the fixator.

Table 6: Mean time for bony union in various studies compared with our study.

Author	Number of patients	Mean time for union (in months)
Present study	21	11.5
G.K. Dendrinios <i>et al.</i> [24]	28	12.4
S. Patil <i>et al.</i> [31]	41	14.1
J.J. Mellupuram <i>et al.</i> [32]	42	15.2
Dror Paley <i>et al.</i> [25, 28-30]	25	13.6

Table 7: ASAMI Bony results comparison of other studies with ours.

Results	Excellent	Good	Fair	Poor
Present study	57%	23%	15%	5%
Lalit <i>et al.</i> [27]	70%	10%	0%	20%
Madhusudhan <i>et al.</i> [26]	22%	36.34%	22%	18.18%
Dendrinios <i>et al.</i> [24]	50%	29%	3.6%	17.4%
Paley <i>et al.</i> [25, 28-30]	60.87%	26.09%	8.7%	4.35%

Table 8: ASAMI Functional results comparison of other studies with ours.

Results	Excellent	Good	Fair	Poor
Present study	48%	28%	19%	5%
Lalit <i>et al.</i> [27]	26.7%	40%	10%	28.3%
Madhusudhan <i>et al.</i> [26]	5.56%	22.22%	33.33%	38.89%
Dendrinios <i>et al.</i> [24]	25%	39.2%	14.3%	2.15%
Paley <i>et al.</i> [25, 28-30]	64%	28%	4%	4%

5.1 The following outcomes and observations were drawn up from the study

1. The Ilizarov technique allows the early function of the limb resulting in adequate stimulus for soft tissue and bone healing.
2. Selection of proper patients by avoiding extremes of age and assessing compliance by the patients is required for the successful application of the Ilizarov. Smokers must be excluded.
3. Proper placement of K wires and rings is essential for maintaining adequate rigid fixation.
4. Fast healing of soft tissues associated with distraction osteogenesis reduces the need for plastic surgery for obtaining skin coverage.
5. Bone grafting is supplemented in attaining union when the Ilizarov technique is used in special situations where the ends of bones are too narrow to be docked. We had

found bone grafting to be useful.

6. Dror Paley's classification is applied only after radical debridement of an infected fracture.
7. Infection can be eradicated by radical debridement of the infected fracture, surrounding soft tissue and by increasing the vascularity of the limb.
8. Pin tract infection, soft tissue contractures and refracture can be prevented by adequate supervision and proper post ring protected weight-bearing for six months with polypropylene tibial braces if needed.
9. Duration of treatment is relatively moderate while considering the complexity of the problems.
10. A trial of loosening of the ring for one month before removal of the apparatus and external splintage for one or two months after the removal of the fixator is very important to prevent refracture.
11. Physiotherapy and functional use of the limb from the first week after application of the fixator is essential for successful treatment of the non-union.
12. The Ilizarov technique is the treatment of choice for infected non-union of long bones.
13. Proper understanding of the biomechanical and biological principles of the Ilizarov method and their careful application gives excellent results in most cases of infected non-union.

6. Conclusion

The permutations and combinations of the Ilizarov ring fixator make it a versatile tool and almost a salvage procedure, it addresses all the problems of open or infected musculo-skeletal injuries and achieves union in up to 90 percent cases. However, it needs a steep learning curve. The few complications which occurred in our earlier cases did not recur later. The main way to avoid mistakes and complications in external ring fixation is to follow the advice from the master Prof G.A. Ilizarov. Prior to embarking on this treatment, as emphasized by J.J. Mellupuram *et al.* [32] both the surgeon and the patient should be completely aware of the lengthy treatment time and the considerable number of complications.

7. Reference

- Jain AK, Sinha S. Infected nonunion of the long bones. *Clin Orthop Relat Res.* 2005; 431:57-65.
- Bose D, Kugan R, Stubbs D *et al.* Management of infected nonunion of the long bones by a multidisciplinary team. *Bone Joint J.* 2015; 97-B:814-817.
- Metsemakers WJ, Kuehl R, Moriarty TF *et al.* Infection after fracture fixation: current surgical and microbiological concepts. *Injury*, 2016.
- DeLong WG, Born CT, Wei SY *et al.* Aggressive treatment of 119 open fracture wounds. *J Trauma Acute Care Surg.* 1999; 46:1049-1054.
- Malik MHA, Harwood P, Diggle P *et al.* Factors affecting rates of infection and nonunion in intramedullary nailing. *J Bone Joint Surg Br.* 2004; 86:556-560.
- Harley BJ, Beaupre LA, Jones CA, *et al.* The effect of time to definitive treatment on the rate of nonunion and infection in open fractures. *J Orthop Trauma.* 2002; 16:484-490.
- Audigé L, Griffin D, Bhandari M *et al.* Path analysis of factors for delayed healing and nonunion in 416 operatively treated tibial shaft fractures. *Clin Orthop Relat Res.* 2005; 438:221-232.
- Antonova E, Le TK, Burge R *et al.* Tibia shaft fractures: costly burden of nonunions. *BMC Musculoskelet Disord.* 2013; 14:42.
- Thakore RV, Greenberg SE, Shi H *et al.* Surgical site infection in orthopaedic trauma: a case-control study evaluating risk factors and cost. *J Clin Orthop Trauma.* 2015; 6:220-226.
- Pollard TCB, Newman JE, Barlow NJ *et al.* Deep wound infection after proximal femoral fracture: consequences and costs. *J Hosp Infect.* 2006; 63:133-139.
- McNally M, Nagarajah K. Osteomyelitis. *Orthop Trauma.* 2010; 24:416-429.
- Yin P, Ji Q, Li T *et al.* A systematic review and meta-analysis of ilizarov methods in the treatment of infected nonunion of tibia and femur. *PLoS One.* 2015; 10:e0141973.
- Ilizarov GA. The tension-stress effect on the genesis and growth of tissues: Part I. The influence of stability of fixation and soft-tissue preservation. *Clin Orthop Relat Res.* 1989; 238:249-281.
- Ilizarov GA. The tension-stress effect on the genesis and growth of tissues: Part II. The influence of the rate and frequency of distraction. *Clin Orthop Relat Res.* 1989; 239:263-285.
- Paley D, Catagni MA, Argnani F *et al.* Ilizarov treatment of tibial nonunions with bone loss. *Clin Orthop Relat Res.* 1989; 241:146-165.
- Pearson RL, Perry CR. The ilizarov technique in the treatment of infected tibial nonunions. *Orthop Rev.* 1989; 18:609-613.
- Green SA, Jackson JM, Wall DM *et al.* Management of segmental defects by the ilizarov intercalary bone transport method. *Clin Orthop Relat Res.* 1992; 280:136-142.
- Cattaneo R, Catagni M, Johnson EE. The treatment of infected nonunions and segmental defects of the tibia by the methods of ilizarov. *Clin Orthop Relat Res.* 1992; 280:143-152.
- Saleh M, Royston S. Management of nonunion of fractures by distraction with correction of angulation and shortening. *Bone Joint J.* 1996; 78:105-109.
- Maini L, Chadha M, Vishwanath J *et al.* The ilizarov method in infected nonunion of fractures. *Injury.* 2000; 31:509-517.
- Kocaoglu M, Eralp L, Sen C *et al.* Management of stiff hypertrophic nonunions by distraction osteogenesis: a report of 16 cases. *J Orthop Trauma.* 2003; 17:543-548.
- Shevtsov VI, Makushin VD, Kuftyrev LM. In: *Defects of the Lower Limb Bones. Treatment Based on Ilizarov Techniques.* New Delhi, India: BI. Churchill Livingstone, 2000, 227-438.
- Nirup NC *et al.*, *Sch. Acad. J Biosci*, 2017; 5(10):713-719.
- Dendrinis GK, Kontos S, Lyritsis E. Use of the Ilizarov technique for treatment of non-union of the tibia associated with infection. *J Bone Joint Surg. Am.* 1995; 77(6):835-46.
- Paley FB, Chirstianson D. An analysis of Illizarov and external fixators. *Clin Orthop Relat Res.* 1989; (241):195.
- Madhusudhan TR, Ramesh B, Manjunath K, Shah HM, Sundaresh DC, Krishnappa N *et al.* Outcomes of Ilizarov ring fixation in recalcitrant infected tibial non-unions - a prospective study. *J Trauma Manag Outcomes.* 2008; 2(1):6.
- Lalit M, Chadha M, Vishwanath J, Kapoor S, Mehtani A, Dhaon BK *et al.* The Ilizarov method in infected nonunion of fractures. *Injury.* 2000; 31(7):509-17.
- Paley D. Current techniques of limb lengthening. *J Pediatr Orthop.* 1988; 8(1):73-92.
- Paley D. Problems obstacles, and complications of limb lengthening by the Ilizarov technique. *Clin Orthop Relat Res.* 1990; (250):81-104.
- Paley FB, Chirstianson D. An analysis of Illizarov and external fixators. *Clin Orthop Relat Res.* 1989; (241):195.
- Patil S, Montgomery R. Management of complex tibial and femoral nonunion using the Ilizarov technique, and its cost implications. *The Journal of bone and joint surgery. British volume.* 2006; 88(7):928-32.
- Jimmy Joseph Meleppuram and Syed Ibrahim. Experience in fixation of infected non-union tibia by Ilizarov technique – a retrospective study of 42 cases. *Rev Bras Ortop.* 2017; 52(6): 670-675.