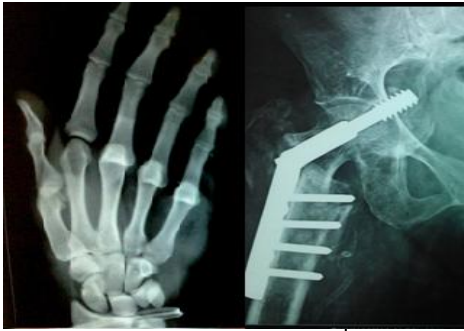

International Journal of Orthopaedics Sciences

ISSN: 2395-1958
IJOS 2019; 5(2): 1032-1037
© 2019 IJOS
www.orthopaper.com
Received: 01-02-2019
Accepted: 03-03-2019

Dr. Anshul Gupta
Associate Professor, Department
of Orthopaedics, Government
Medical College, Surat, Gujarat,
India

Dr. Shahrukhkhan Pathan
Senior Resident, Department of
Orthopaedics, Government
Medical College, Surat, Gujarat,
India

Dr. Jitender Singh
Resident, Department of
Orthopaedics, Government
Medical College, Surat, Gujarat,
India

Dr. Ankur Mali
Resident, Department of
Orthopaedics, Government
Medical College, Surat, Gujarat,
India

Correspondence
Dr. Shahrukhkhan Pathan
Senior Resident, Department of
Orthopaedics, Government
Medical College, Surat, Gujarat,
India

Outcome of operative management of degenerative compressive myelopathy of cervical spine

Dr. Anshul Gupta, Dr. Shahrukhkhan Pathan, Dr. Jitender Singh and Dr. Ankur Mali

DOI: <https://doi.org/10.22271/ortho.2019.v5.i2p.1475>

Abstract

Cervical spondylotic myelopathy is a serious complication of cervical spondylosis. Surgery is increasingly recommended as the preferred treatment strategy for patients with CSM as it can effectively halt disease progression and improve neurological outcomes. Aims of the study were to determine functional outcomes, perioperative complications and to compare for safety and efficacy of different surgical treatments available for CSM. Prospective case series included all consecutive patients with CSM who underwent cervical decompressive surgery from August 2015 to March 2017 at the Orthopaedic Department, New Civil Hospital, Surat. Functional disability was assessed on the basis of the mJOA score, European Myelopathy Score and Nurick's grading. 3 Women and 17 men with ages ranging from 37 to 65 years underwent surgical spinal cord decompression. Discectomy with anterior fusion (n = 7), corpectomy with anterior fusion (n = 2), decompressive laminectomy (n = 3), laminectomy with lateral mass fixation (n = 2) and laminoplasty (n = 6) were the operative procedures in study. Preoperative functional scorings of the patients were mJOA (12.20±2.76), EMS (11.70±3.10) and Nurick's grade (3.15±1.3). There was a statistically significant improvement in mean scores at 6 months in The Nurick's grades (2.0±1.21) (p <0.0015), mJOA (14.85±2.35) (p < 0.0009), EMS (15.35±2.3) (p < 0.0001). Complications like chronic cervical pain (axial or radicular) and C5 radiculopathy occurred in 3 patients operated anteriorly. Intraoperative excessive bleeding occurred in 3 patients operated posteriorly required packing with hemostatic agent. While comparing the functional outcome for anterior and posterior procedures using 6month, 1 year and 2 year postoperative mJOA score and European myelopathy score, result is significantly better for posterior procedures (p values <0.05). Surgery for CSM is associated with significant functional recovery. Posterior decompression shows significantly better results but more postoperative complication than anterior decompression.

Keywords: Cervical spondylotic myelopathy, mJOA score, European myelopathy score, nurick's grading

1. Introduction

Cervical spondylosis is widespread in all cross sections of the adult population; it has been estimated that 50% of the population over the age of 50 years and 75% over the age of 65 years have the disease [1]. It is indeed fortunate that only a small proportion develop the most serious complication of the disease, namely, cervical spondylotic myelopathy (CSM). CSM can lead to devastating and crippling neurological deficits [2]. Surgery is increasingly recommended as the preferred treatment strategy for patients with CSM as it can effectively halt disease progression and improve neurological outcomes, functional status and quality of life [4-9]. Predicting surgical outcome and perioperative complications in these patients are increasingly important research topics. This information is valuable to clinicians because it provides decision-making support to surgeons; it allows surgeons to identify high-risk patients and institute rigorous preventative strategies and it gives surgeons a tool to counsel their patients and discuss relative risks and benefits of the procedure. The Orthopaedics department at NCH, Surat is receiving large number of patients with spinal cord disorders from whole of South Gujarat and periphery of Maharashtra.

2. Material and methods

Approval was obtained from institutional ethical research committee before undertaking the study. All patients operated for CSM between Aug 2015 to March 2017 were included in the

study with the following inclusion criteria.

2.1 Inclusion criteria

2.1.1 An age of eighteen years or older,

2.1.2 Presentation of symptomatic cervical spondylotic myelopathy with at least one clinical sign of myelopathy

2.2 Exclusion criteria:

2.2.1 Asymptomatic cervical spondylotic myelopathy

2.2.2 Previous history of cervical spine surgery and trauma to cervical spine

2.2.3 Tumors or any other pathology involving cervical spine

All patients presenting with clinical signs and symptoms of compressive cervical myelopathy were evaluated and recorded clinically and radiologically. The age, gender, duration and intensity of symptoms and deficits and the disability status at the time of presentation were recorded. The patients were graded for their functional disability on the basis of the mJOA score, European Myelopathy Score and Nurick's grading (figure 1, 2 and 3). Cervical spine AP and lateral radiograph and MRI was done as a preoperative investigation in all the cases. Xray and MRI was evaluated for level of disease, spinal cord intensity changes, OPLL, hypertrophy or buckling of ligamentum flavum, osteophytes, translation or instability, Pavlov ratio (figure 4) and changes in curvature of spine. Patients meeting with inclusion criteria

were offered a surgery and patients giving consent to participate in study were included. Patients were operated by any of the following surgical techniques: anterior (southwick robinson approach) or posterior (laminectomy, laminectomy with instrumentation, laminoplasty) or combined anterior and posterior approach according to patient profile, number of levels involved and implant availability in hospital supply. Post operatively every patient was immobilized with Philadelphia cervical collar up to the period of 8 to 12 weeks. First postoperative dressing and drain removal was done 48 hrs after surgery. Suture removal was done at 11th postoperative day. Passive physiotherapy for peripheral joints were started on next day of surgery and neck mobilization was started after 8 to 12 weeks. X-rays of cervical spine were obtained Immediate postoperatively and at subsequent follow-up (3month, 6month, 1yr and 2yr) for assessment of spinal alignment, implant positioning, Pavlov ratio and bony fusion. Postoperative MRI of cervical spine was obtained at 6 month follow up for cord changes in T1 & T2 weighted images and canal diameter. Every patient was assessed for functional improvement by mJOA score, European Myelopathy Score and Nurick's grading immediate postoperatively and at subsequent follow-up. Univariate analyses were carried out using a chi square test for categorical variables and student t test for continuous variables. Any association having $p < 0.05$ was considered as statistically significant. Analysis was done by using SPSS ver 19 software.

Scale for clinical evaluation of myelopathy – Japanese Orthopedic Association (JOA): 0 to 17 points	Points
I – Motor function of the upper limb	
-Impossible to eat with cutlery or to button shirt	0
-Possible to eat with cutlery, impossible to button shirt	1
-Possible to button shirt, with great difficulty	2
-Possible to button shirt, with difficulty	3
-Normal	4
II – Motor function of the lower limb	
-Impossible to walk	0
-Needs cane or assistance on flat surface	1
-Needs assistance on stairs	2
-Walks unaided, but slowly	3
- Normal	4
III – Sensory function	
Upper limb	
-Apparent sensory disorder	0
-Minimal sensory disorder	1
-Normal	2
Lower limb	
-Apparent sensory disorder	0
-Minimal sensory disorder	1
-Normal	2
Trunk	
-Apparent sensory disorder	0
-Minimal sensory disorder	1
-Normal	2
IV – Bladder function	
-Urinary retention or incontinence	0
-Sensation of retention, loss of slight flow	1
-Urinary retention and/or increase in urinary frequency	2
-Normal	3

Fig 1: Joa Score Simplified By Thiago *et al.* (2012)

Score	Definition
Gait Function	
1	Unable to walk, wheelchair
2	Walking of flat ground only with cane or aid
3	Climbing stairs only with aid
4	Gait clumsy, but no aid necessary
5	Normal walking and climbing stairs
Bladder and Bowel Function	
1	Retention, no control over bladder and/or bowel function
2	Inadequate micturition and urinary frequency
3	Normal bladder and bowel function
Hand Function	
1	Handwriting and eating with knife and fork impossible
2	Handwriting and eating with knife and fork impaired
3	Handwriting, tying shoelaces or a tie clumsy
4	Normal handwriting
Proprioception and Coordination	
1	Getting dressed only with aid
2	Getting dressed clumsily and slowly
3	Getting dressed
Paraesthesia / Pain	
1	Invalidity due to pain
2	Endurable paraesthesia and pain
3	No paraesthesia and pain

Score of 17 to 18 - Normal function
 Score of 13 to 16 - Grade 1
 Score of 9 to 12 - Grade 2
 Score of 5 to 8 - Grade 3

Fig 2: European Myelopathy Score

Grade	Level of Neurological Involvement
Grade I	No difficulty in walking
Grade II	Mild gait involvement not interfering with employment
Grade III	Gait abnormality preventing employment
Grade IV	Able to walk only with assistance
Grade V	Chairbound or bedridden

Fig 3: Nurick's Grading

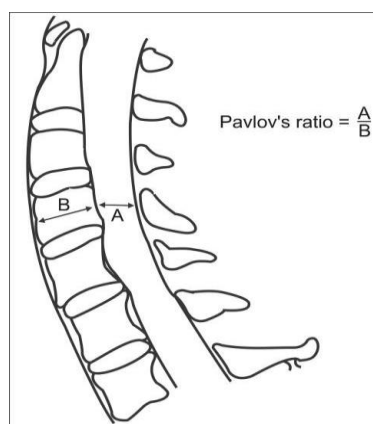


Fig 4: Pavlov Ratio: It is the ratio of the diameter of cervical canal to the width of cervical body. Ratio of <0.8 on the lateral view taken as an indication of cervical stenosis.

3. Results

During the study period, 3 women and 17 men with ages ranging from 37 to 65years underwent surgical spinal cord decompression for treatment of CSM. In this study 60%

patients were from the age group 41-60 yrs (n = 7), 30% were from the age group 21-40 yrs (n = 6) & 10% were from the age group more than 61 yrs (n = 2). (Table 1)

Table 1: Age Distribution of Patients

Age Group (in years)	No. of patients	Percentage %
21-40	6	30
41-60	12	60
>61	2	10
Total	20	100

With respect to the procedures performed, we found discectomy with anterior fusion (ACDF) (n = 7), corpectomy with anterior fusion (ACCF) (n = 2), decompressive laminectomy (n= 3), laminectomy with lateral mass fixation (n = 2) and laminoplasty (n = 6). (Table 2)

Table 2: Number and Percentage of Patients Operated with Different Techniques

Type of Operation		Patients	Percentage (%)
Anterior	Cervical Discectomy	7	35
	Cervical Corpectomy	2	10
Posterior	Decompression Laminectomy	3	15
	Laminectomy With Lateral Mass Fixation	2	10
	Laminoplasty	6	30

The mean Nurick’s grades at 6 months after surgery were significantly lower than the mean preoperative Nurick’s grade

Table 4: Postoperative Complications In ACDF, ACCF, Posterior Fusion, Laminectomy, Laminoplasty And Combined Procedure

Variables	Number of Patients					
	ACDF	ACCF	Laminectomy	Laminectomy With Fixation	Laminoplasty	Combined
Chronic Pain	1	1	-	-	1	-
Wound Complicati on	-	-	-	-	-	-
Intraop Excessive Bleeding			1		2	
Dvt	-	-	-	-	-	-
Pulmonary Complicati On	-	-	-	-	-	-
Neurologic Al Worsening	1	-	-	-	1	-

While comparing the functional outcome for anterior and posterior procedures using 6month postoperative m JOA

(p <0.0015; Table 3). The mean mJOA scores at 6 months after surgery were significantly higher than the mean preoperative mJOA score (p < 0.0009; Table 3). Also, the mean EMS at 6 months after surgery significantly increased in comparison with the mean preoperative EMS (p < 0.0001; Table 3)

Table 3: Comparison of Preoperative and Postoperative Mean Mjao, Ems and Nurick’s Grading

	Preop	Postop (6 Month)	P Value
Mjao	12.15±2.7	14.85±2.35	0.0009
European Myelopathy Score	11.7±3.0	15.35±2.30	0.0001
Nurick’s Grading	3.15±1.3	2.00±1.21	0.0015

Based on the Nurick’s grading, mJOA score and EMS neurological deterioration within the first year after surgical treatment was observed in 2 patients (9.09%). Minor complications like chronic pain and C5 radiculopathy occurred in 3 patients operated anteriorly which resolved over 6 months in 2 patients. Intra-operative excessive bleeding occurred in 3 patients operated via posterior approach and required packing with haemostatic agent. Wound complication and infection was not seen in any patients. Complications like thromboembolism, DVT or pulmonary complications were also not seen in any patients. No patients were put on prophylaxis for DVT

Table 5: Mean Mjao Score and Ems After 6 Months Of Anterior And Posterior Decompression

	Anterior Decompression	Posterior Decompression	P VALUE
Mjao	15.67± 1.87	14.18±2.56	P= 0.0164
European Myelopathy Score	16.56±1.88	14.36±2.20	P= 0.0297

During follow up period, postoperative MRI was done in 8 patients (40%) after 6months, who showed increase in AP diameter of canal and persistence of cord changes in both T1 and T2 weighted images. There isn’t any direct relation between preoperative cord changes and postoperative functional recovery. (Table 6) Comparison of preoperative

score and European myelopathy score, result is significantly better for posterior procedures (p values <0.05), (Table 5).

and postoperative x-rays of cervical spine showed increase in Pavlov ratio (canal to body ratio) in anterior procedures and laminoplasty. 2 patients showed preoperative OPLL on x-ray and MRI, both were operated by decompressive laminectomy and showed significant functional improvement.

Table 6: Relationship Between Cord Changes And Postoperative Functional Recovery

	Spinal Cord Changes In Both T1 And T2 Weighted Images On Mri	Spinal Cord Changes In Only T2 Weighted Images On Mri
Number Of Patients	7	13
Average Preop Joa Score	11.86	12.31
Average 6month Postop Joa Score	15	14.76
Average Preop Nurick Grading	3.71	2.84
Average 6month Postop Nurick Grading	2	2

4. Discussion

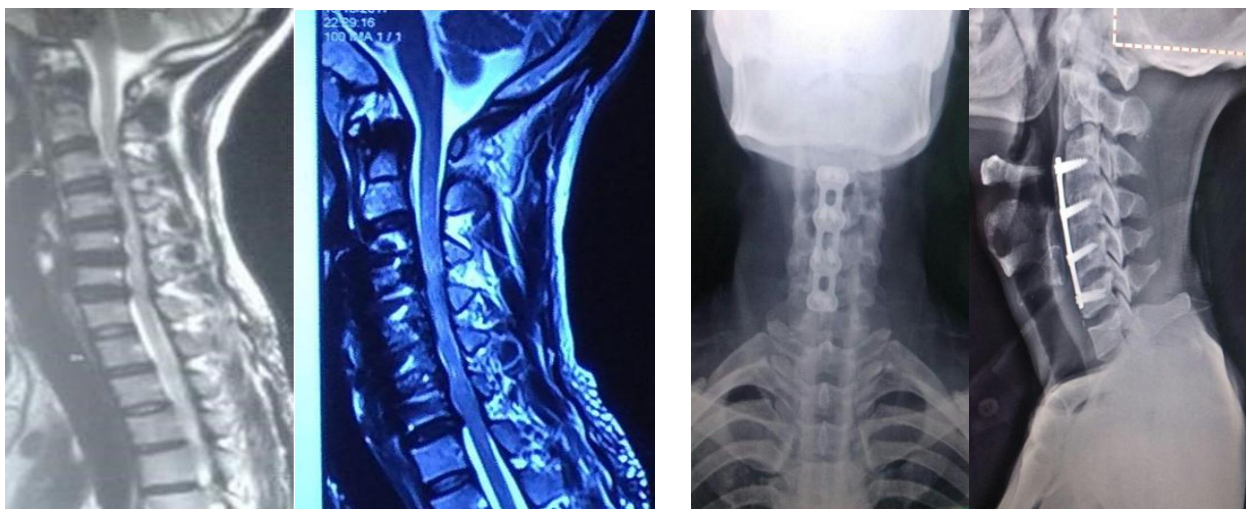
Cervical spondylotic myelopathy is a common pathological entity that can result in significant disability in the adult population. It can present in a variety of ways but the most

common presentations are gait disturbance and functional deficits of the upper extremity, particularly the hand. In this study we have analyzed the data from a group of 20 patients followed for minimum 6 months duration with a diagnosis of

CSM. We have used the Nurick score, mJOA score and European myelopathy score as a primary outcome measure as it is specific for the disease. However, the degree of improvement (i.e. the functional change) did not show a significant correlation with the initial preoperative score. The cord signal change, as an indicator of the pathological severity of the disease did correlate with a worse functional outcome in our study and of Suri *et al.* who has reached similar findings [10]. In our study functional recovery reached maximum at 6 months after decompressive spine surgery in comparison with the 1-year and 2-year follow-up assessments. This finding is similar to the findings of a prior prospective study that assessed functional recovery using the JOA score within the first year after surgical decompression of the spinal cord in patients with CSM [5]. This data suggest that the most relevant functional improvements occur within the first 6 months after surgical treatment in this group of patients. None

of those potential confounders like age, sex, duration of symptoms preoperatively, number of levels involved, and preop myelopathic severity were significantly associated with clinically relevant functional improvement as assessed by the Nurick grading, mJOA score, and EMS in our study. This may be due to small sample size. This study shows male preponderance for CSM but, sex is not associated with final outcome after surgery. In this study, the overall perioperative complication rate was (22.72%). There was a 18.18% incidence of major complications with cohort study by fehlings *et al* [4]. Patients with predominantly dorsal compression due to ligamentum flavum infolding and patients with multisegmental stenotic disease may be better suited for a posterior procedure in the setting of a neutral to lordotic alignment. Anterior surgery is generally recommended for patients with disease limited to a few segments and patients with a fixed cervical kyphosis.

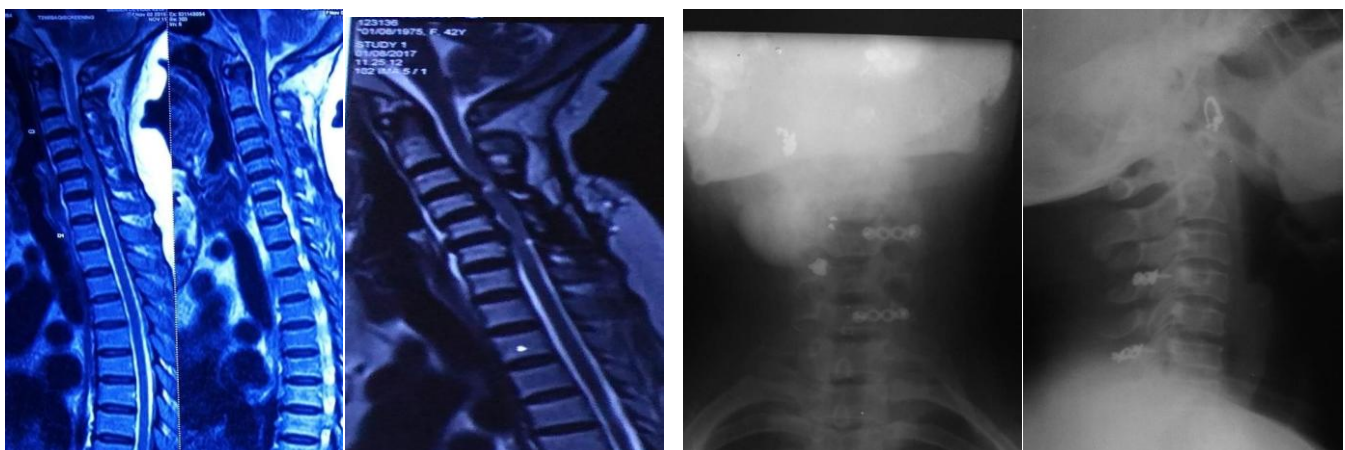Case 1



Preoperative and Postoperative Mri Of 35 Yr Male Operated With 3 Level Discectomy And Bone Grafting With Anterior Cervical Plating

Month Postoperative Xray Of Same Patient Showing Fusion

Case 2



Preoperative And Postoperative Mri Of 46 Yr Old Female Presented With Symptoms Of Myelopathy Since 18 Months, Operated With C3 To C7 Laminoplasty With Mini Plates

12 Month Postoperative Xray Of The Same Patient

5. Conclusion

Our study indicates that surgery for CSM is associated with significant functional recovery. Posterior decompression shows significantly better results than anterior decompression. Posterior decompression is associated with more

postoperative complications than anterior.

6. Limitation

One of the most important limiting factors for the study is small sample size (n = 20). Study with bigger sample size and

longer follow up could yield better results.

7. Reference

1. Rowland LP. Surgical treatment of cervical spondylotic myelopathy: time for controlled trial. *Neurology*. 1992; 42:5-13.
2. Ball P, Saunders RL. Subjective myelopathy. In: Saunders RL, Bernini PM, editors. *Cervical spondylotic myelopathy: contemporary issues in neurological surgery*. Blackwell Science, Inc., Boston, 1992, 48-55
3. Fehlings MG, Tetreault LA, Wilson JR, Skelly AC. Cervical spondylotic myelopathy: current state of the art and future directions. *Spine (Phila Pa 1976)* 2013; 38(22 Suppl 1):S1-8.
4. Fehlings MG, Wilson JR, Kopjar B *et al*. Efficacy and Safety of Surgical Decompression in Patients with Cervical Spondylotic Myelopathy: Results of the AOSpine North America Prospective Multi-Center Study. *J Bone Joint Surg Am*. 2013; 95(18):1651-8.
5. Cheung WY, Arvinte D, Wong YW, Luk KD, Cheung KM. Neurological recovery after surgical decompression in patients with cervical spondylotic myelopathy - a prospective study. *Int Orthop*. 2008; 32(2):273-8.
6. Gok B, Scubba DM, McLoughlin GS *et al*. Surgical treatment of cervical spondylotic myelopathy with anterior compression: a review of 67 cases. *J Neurosurg Spine*. 2008; 9(2):152-7.
7. Latimer M, Haden N, Seeley HM, Laing RJ. Measurement of outcome in patients with cervical spondylotic myelopathy treated surgically. *British journal of neurosurgery*. 2002; 16(6):545-9.
8. Al-Tamimi YZ, Guilfoyle M, Seeley H, Laing RJ. Measurement of long-term outcome in patients with cervical spondylotic myelopathy treated surgically. *Eur Spine J*. 2013; 22(11):2552-7.
9. Ebersold MJ, Pare MC, Quast LM. Surgical treatment for cervical spondylitic myelopathy. *J Neurosurg*. 1995; 82(5):745-51.
10. Suri A, Chhabra RP, Mehta VS, Gaikward, S Pandey Rm. Effect of intramedullary signal changes on the surgical outcome of patients with cervical spondylotic myelopathy. *Spine J*. 2003; 3:33-45.