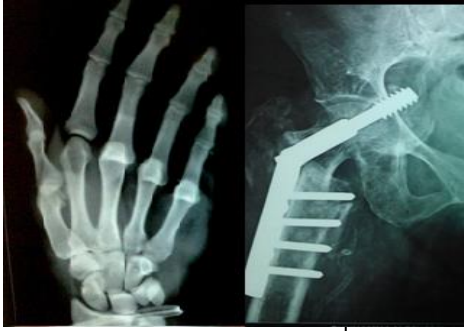

# International Journal of Orthopaedics Sciences

ISSN: 2395-1958  
IJOS 2019; 5(2): 1038-1041  
© 2019 IJOS  
www.orthopaper.com  
Received: 04-02-2019  
Accepted: 06-03-2019

**Dr. Vinod Kanithi**  
Junior Resident, Department of  
Orthopaedics, NRI Academy of  
Sciences, Chinakakani, Andhra  
Pradesh, India

**Dr. K Adithya**  
Junior Resident, Department of  
Orthopaedics, NRI Academy of  
Sciences, Chinakakani, Andhra  
Pradesh, India

**Dr. K Satya Kumar**  
Professor, Department of  
Orthopaedics, NRI Academy of  
Sciences, Chinakakani, Andhra  
Pradesh, India

## Role of locking plate in fractures of shaft of humerus in elderly patients

**Dr. Vinod Kanithi, Dr. K Adithya and Dr. K Satya Kumar**

DOI: <https://doi.org/10.22271/ortho.2019.v5.i2p.1476>

### Abstract

Fractures of humeral diaphysis constitute 3% of all the bony injuries. Operative technique which have been devised for the treatment of humeral diaphyseal fractures include ORIF with plate osteosynthesis, intramedullary nailing and External fixation using ilizarov ring fixators or AO tubular fixators. Open reduction and internal fixation with plate osteosynthesis supplemented with bone grafting has been the gold standard for treatment of the humeral diaphysis when other methods are compared. The key to this new generation of plates is the locking mechanism of the screw to the plate, which provides angular stability and avoids compression of the plate to the periosteum. Loss of screw purchase is an important factor related to the failure of fixation in osteoporotic bone. Fracture plating technology recently has evolved to include locked plating. The main goal is to obtain the most rigid fixation possible. It is a prospective study of 30 elderly patients who attended either the outpatient department or emergency room who had sustained injury to the arm and diagnosed as fracture shaft of humerus in NRI Medical college and general hospital during the period of 2 years (November 2016 to October 2018). All the cases followed at 6weeks, 3 months and at 12months. The results are assessed by Constant and Murley's scoring system. Post-menopausal osteoporotic females accounted for 40% of patients. In our study internal fixation using locking compression plating techniques achieved union in all cases. 95% of fractures united within 16 weeks. The functional outcome was more than 90%. These results are comparable with those obtained by R Vander Griend *et al* open reduction and internal fixation using AO plating techniques (97%). Treatment of long bone fractures with osteoporosis in elderly patients is technically challenging in terms of fracture fixation, maintenance of reduction and achieving bony union with good clinical outcome. Locking Compression Plate offers higher weight bearing capacity than the conventional plates in terms of good fixation and stability. In osteoporosis or poor bone quality, bicortical engagement of screws is recommended.

**Keywords:** Fracture shaft of humerus, LCP, elderly patients, AO principles.

### Introduction

Fractures of humeral diaphysis constitute 3% of all the bony injuries <sup>[1]</sup>. Operative technique which have been devised for the treatment of humeral diaphyseal fractures include

- Open reduction and internal fixation with plate osteosynthesis
- Open or closed reduction and internal fixation with intramedullary fixation
- External fixation using ilizarov ring fixators or AO tubular fixators

Some amount of shortening is functionally acceptable. But a rotational deformity is not acceptable. Open reduction and internal fixation with plate osteosynthesis supplemented with bone grafting has been the gold standard for treatment of the humeral diaphysis when other methods are compared <sup>[2, 3, 4]</sup>. There are several practical advantages to the use of locking compression plates over standard compression plates. The key to this new generation of plates is the locking mechanism of the screw to the plate, which provides angular stability and avoids compression of the plate to the periosteum. Loss of screw purchase is an important factor related to the failure of fixation in osteoporotic bone. Fracture plating technology recently has evolved to include locked plating. The main goal is to obtain the most rigid fixation possible.

### Aim and objectives of the study

To evaluate radiological and functional outcome of management of fracture shaft of humerus in elderly patients with locking plate.

### Correspondence

**Dr. K Satya Kumar**  
Professor, Department of  
Orthopaedics, NRI Academy of  
Sciences, Chinakakani, Andhra  
Pradesh, India

## Materials and Methods

It is a prospective study of 30 elderly patients who attended either the outpatient department or emergency room who had sustained injury to the arm and diagnosed as fracture shaft of humerus in nri medical college and general hospital during the period of 2 years (november 2016 to october 2018). The patients are evaluated as per the history, mode of injury. Necessary radiological investigations and hematology profile done on admission. All the cases were followed up at 6 weeks, 12 weeks, and 6 months.

### Inclusion criteria

1. Patients above 50 yrs.
2. Polytrauma patients
3. Patients who gave consent for study.

### Exclusion criteria

1. Compound humerus fractures
2. Patients with comorbid conditions and medically not fit for anesthesia.
3. Patients who didn't gave consent for study

## Results

In past two years from November 2016 to November 2018, 30 cases of fracture shaft of humerus treated in NRI academy of medical sciences. The analysis is as follows.

**Table 1:** Age Distribution (N=30)

S. No	Age group	No. of patients	Percentage
1	51-60	10	33
2	60-70	13	45
3	>70	7	22

**Table 2:** Sex distribution (N=30)

S. No	Sex	No. of patients	Percentage
1	Males	12	40
2	Females	18	60

**Table 3:** Mode of Injury

S. No	Mode of Injury	No. of Patients	Percentage
1	Fall at ground level	14	47
2	RTA	10	33
3	Fall from height	6	20

**Table 4:** Occupation

S. No	Occupation	No. of patients
1	Laborer	14
2	House wife	8
3	Skilled worker	6
4	Professional	1
5	Business	1

**Table 5:** Side

S. No	Side Involved	No. of patients
1	Dominant(right)	20
2	Non-dominant(left)	10

**Table 6:** Type of fracture

S. No	Ao-Type	No. of Patients	Percentage
1	A1.2	7	23
2	A2.2	8	26
3	A3.2	6	20
4	B1.2	3	10
5	B2.2	3	10
6	B3.2	1	3.3
7	C1.2	1	3.3
8	C2.2	0	0
9	C3.2	1	3.3

**Table 7:** Early Complications

SL No	Complications	No. of patients
1	Skin necrosis	1
2	Wound gaping	2
3	Radial nerve palsy	1
4	Infection	1

**Table 8:** Late Complications

SL No	Complications	No. of patients
1	Shoulder stiffness	2
2	Elbow stiffness	0
3	Delayed union	2

**Table 9:** Functional outcome

S. No.	Functional outcome	No. of Patients
1	Good	16
2	Fair	12
3	Poor	2

**Table 10:** Over All Results

S. No.	Rating	No. of patients	Percentage
1	Excellent	24	80
2	Satisfactory	5	16.6
3	Unsatisfactory	1	3.3
4	Failure	0	0

## Discussion

There was female preponderance in our study 18 (60%) A study conducted by R. Ekholm *et al* involving 401 diaphyseal fractures there was a female preponderance.<sup>5</sup> Mc Cormack RG, Brain D *et al* involving 44 humeral shaft fractures there was a female preponderance. In Rose SH, Melton *et al* study of 586 humeral fractures there was a female preponderance. In our study the average age of patients was 67.15 years which was comparable with the reports by R. Ekholm *et al* <sup>[6]</sup> and J. Adami, J. Tidermarknd, K. Hansson, H. Tornkvist, S. Ponzer.

The OTA classification is the most widely used classification for humeral diaphyseal fractures. It has gained wide clinical acceptance by orthopaedic surgeons and radiologists is considered to have important implications for both treatment options and outcomes. Several authors have reported low level of inter- and intra-observer reliability for subgroup classification.

In order to properly employ this classification, precise radiographic evaluation is of paramount importance. For the typical humeral shaft fracture it is rarely necessary to obtain further imaging.

There was a predominance of Type-A fractures in our study followed by Type-B and Type-C. The rate of union in Conservative methods (Functional cast bracing) is 97% - 100% 7,8 and the union time is 11.5wks.<sup>9</sup> The rate of union in Intra medullary nailing technique is 80%-100% and the union time is 18-24 weeks.<sup>5</sup> Although the nailing technique is simpler, lesser exposure and least damage to soft tissues nailing technique is associated with nonunions, delayed union, impingement syndrome, injury to rotator cuff, shoulder instability and pseudarthrosis.

The rate of union in Plate osteosynthesis is 93% -100% and the time of union is 4 – 6.7 months, and more than 90% united in 19 weeks. Vander Griend *et al* reported union in 35 of 36 plated humeral fractures with no shoulder or elbow morbidity and one temporary radial nerve palsy <sup>[7]</sup>. Bell *et al* had similar results ie., union in 37 of 39 fractures.

Tingstad *et al* had union in 78 of 83 fractures. The union rate following open reduction and internal fixation of humeral shaft fractures averages 96% in number of large series [6].

Complications are infrequent and include radial nerve palsy (2-5%) usually neuropraxic injuries which usually recover, *Infection* (1-2%) for closed fractures, 2% to 5% for open fractures and *refracture* is 1%. We have followed the three phase rehabilitation protocol of Hughes and Neer in all our patients and this has provided good results. We had a full range of motion in shoulder and elbow joint in more than 90% of cases.

Plate fixation according to the Muller’s technique is a reliable osteosynthesis method with few initial failures or malunions as evidenced by data in the literature. Infection is also rare. Although the radial nerve risk makes this technique rather difficult, excellent functional results can be achieved.

In our study internal fixation using locking compression

plating techniques achieved union in 28 of 30 fractures (95%) and delayed union in two cases. These results are comparable with those obtained by R Vander Griend *et al* open reduction and internal fixation using AO plating techniques (97%). The incidence of operative and post-operative complications was low and the return of function was good except in patients with associated injuries.

The functional outcome of the patients were assessed by Constant and Murley’s scoring system. The score was more than 90%.

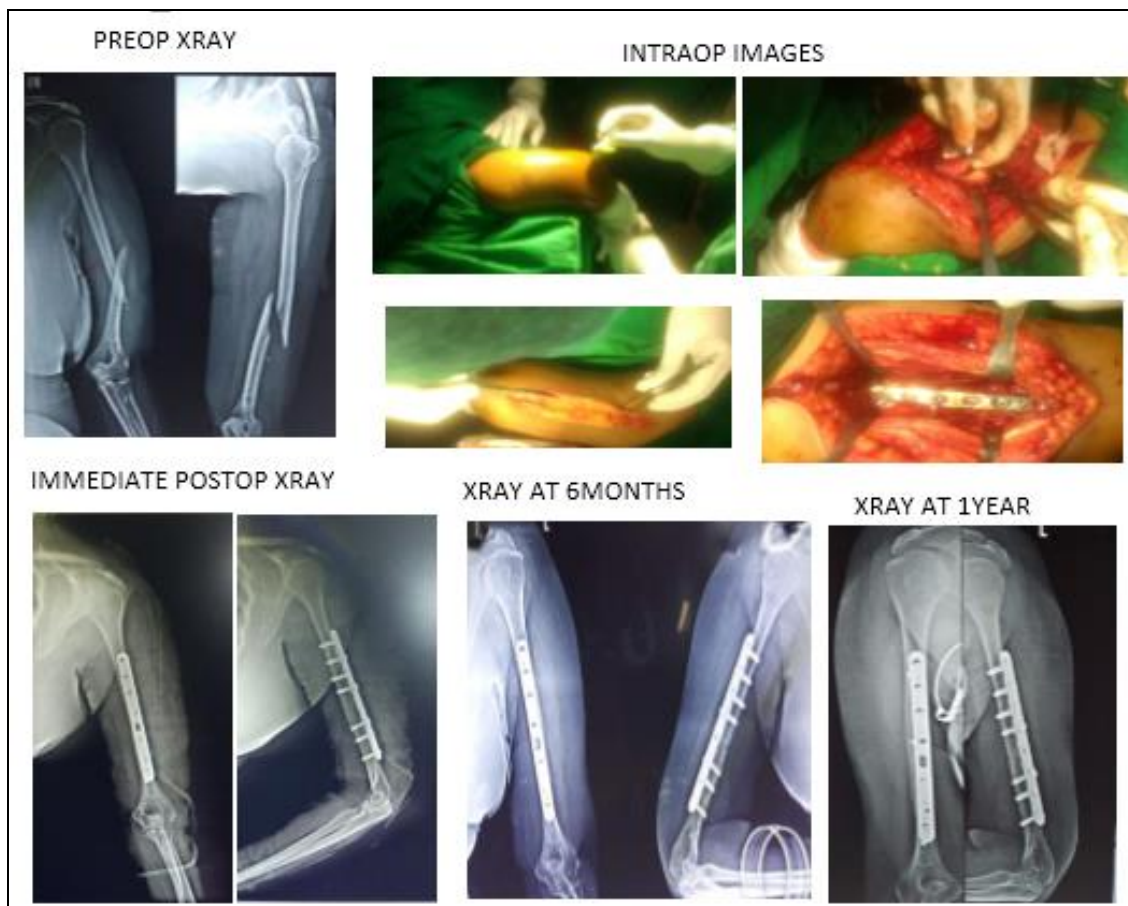
In summary, management of fracture shaft of humerus in elderly may be extremely demanding. There are many pitfalls for the unwary patient and surgeon to avoid during the course of treatment. Emphasis is placed on complete and accurate diagnosis and preoperative planning for formation of safe and simple techniques for restoration of normal anatomy, fracture healing and patient care, full range of motion and strength.

**Fracture union rate obtained as compared to other studies**

Series	Total no of patients	Delayed union	Non union	Overall results
Bell MJ <i>et al</i> (1985)	34	-	1(3%)	33(97%)
Griend RV, Tomasin J, Ward <i>et al</i> (1999)	36	5(14.6%)	1(3%)	35(97%)
Gongol T, Mracek D (2002)	32	-	1(3.1%)	31(96.9%)
Present study (2018)	30	2(6.6%)	-	28(93.3%)

**Range of mobility of elbow & shoulder as compared to other studies**

Study	No of patients	Good range of mobility	Percentage
Bell MJ <i>et all</i> (1985)	39	38	97%
Griend RV, Tomasin J, Ward <i>et al</i> (1986)	36	30	85.4%
McCormack RG <i>et al</i> (2000)	44	44	100%
Gongol T, Mracek D (2002)	32	31	97%
Present Study (2018)	30	28	93.3%



**Fig 1:** Clinical Pictures



**Fig 2:** Range of movements at final follow up

### **Conclusion**

Treatment of long bone fractures with osteoporosis in elderly patients is technically challenging in terms of fracture fixation, maintenance of reduction and achieving bony union with good clinical outcome. Locking Compression Plate offers higher weight bearing capacity than the conventional plates in terms of good fixation and stability. In osteoporosis or poor bone quality, bicortical engagement of screws is recommended. In severely comminuted fractures where the anatomy cannot be restored without extensive soft tissue dissection, fixation with LCP will give better fracture union and good functional outcome. Results are best when stable fixation allows early passive mobilization which is possible only with locking compression plate.

### **References**

1. Gregory PR, Sanders RW. Compression plating Vs IM fixation of humeral shaft fractures. *JA Orthop Surgery*. 1997; 5(4):215-223.
2. Anand J Thakur. *The elements of fracture fixation*, 2nd edition, 96-124.
3. Rosen H. Treatment of non-union & Pseudoarthrosis of humeral shafts. *Ortho clinics of North America*. 1990; 21(4):725-42.
4. Hagel Maier C, Von Aproth B. Osteosynthesis of diaphyseal humeral fractures, indications-Risks-Results *Akthulli Traumatology*. 1993; 23:3642.
5. Seibert CH, Heinz BL, Hofler HR, Hansis M. Plate osteosynthesis management of humeral shaft fractures. *Unfall chirurg*. 1996; 99:106-11.
6. Winker H, Vosberg W, Cyris A. Results of treatment of humeral shaft fractures. *Aktulli Traumatol*. 1993; 23(1):36-41.
7. Bleeker WA, Nijsten MW, Ten duis HJ, *et al*. Treatment of humeral shaft fractures related to associated injuries: a retrospective analysis of 237 patients. *Acta orthop. scand*. 1991; 62:148-53.
8. Ostermann PAW, Ekkernkamp A, Muhr G. Functional bracing of shaft fractures of the humerus. An analysis of 195 cases. *Orthop. Trauma*. 1993-1994; 17:937.