



## International Journal of Orthopaedics Sciences

ISSN: 2395-1958  
IJOS 2019; 5(2): 1010-1014  
© 2019 IJOS  
www.orthopaper.com  
Received: 16-02-2019  
Accepted: 18-03-2019

**Dr. Deepanshu Agarwal**  
Junior Resident, Department of  
Orthopaedics, Rohilkhand  
Medical College and hospital,  
Bareilly, Uttar Pradesh, India

**Dr. Fahad Bin Hamid**  
Assistant Professor, Department  
of Orthopaedics, Rohilkhand  
Medical College and hospital,  
Bareilly, Uttar Pradesh, India

**Dr. T Somashekarappa**  
Professor, Department of  
Orthopaedics, Rohilkhand  
Medical College and hospital,  
Bareilly, Uttar Pradesh, India

### Correspondence

**Dr. Deepanshu Agarwal**  
Junior Resident, Department of  
Orthopaedics, Rohilkhand  
Medical College and hospital,  
Bareilly, Uttar Pradesh, India

## A clinical study of surgical management of diaphyseal adult humerus fracture with plate osteosynthesis

**Dr. Deepanshu Agarwal, Dr. Fahad Bin Hamid and Dr. T Somashekarappa**

DOI: <https://doi.org/10.22271/ortho.2019.v5.i2o.1469>

### Abstract

**Background:** Diaphyseal fractures of the humerus and its complications are a major cause of morbidity in trauma patients, which result in significant burden to the society from loss of productivity and wages. Fractures of the humeral shaft account for 20% of all the humeral fractures and about 3-5 % of the fractures of the human body. The present study is an attempt to study the advantages & disadvantages of open reduction internal fixation with plate and screws for fracture shaft of Humerus, analyze the results & compare with the relevant standard studies.

**Material & Methods:** This study is a prospective study centered in Department of Orthopaedics at Rohilkhand Medical College and Hospital, Bareilly, U.P, from November 2016 to October 2017 in which 40 patients with diaphyseal humerus fractures are treated with plate osteosynthesis.

**Results:** Of the 40 patients in the study, 32 were males and 8 were females. The mean age was 36 years (range: 18–65 years). Twenty-one (52.5%) had the right side fractured. In this study, fractures of the middle third [Type III] (57.5%) were the commonest followed by the fractures at the junction of middle & lower third [Type IV] (32.5%). The mean radiological fracture union time was 11.8 weeks (range: 10–18 weeks). In our series we had 34 (85%) patients with excellent or good results out of 40 patients

**Conclusion:** Plate Osteosynthesis is a superior methods of surgical management of Diaphyseal fractures of Humerus. Early mobilization of the neighboring joints can be begun as the fixation is rigid. Procedure helps in regaining good range of movement of the shoulder & elbow joint.

**Keywords:** Diaphyseal humerus fractures, dynamic compression plate, screws

### Introduction

Diaphyseal fractures of the humerus and its complications are a major cause of morbidity in trauma patients, which result in significant burden to the society from loss of productivity and wages. Fractures of the humeral shaft account for 20% of all the humeral fractures [1] and about 3-5 % of the fractures of the human body.

The most common cause for a humeral shaft fracture is an injury, followed by motor vehicle accident. Other causes that account for less than 10% of humeral shaft fractures include sporting activities, industrial accidents, fall from a height, violence, and bone pathology. Pathologic and open fractures of the humeral shaft are uncommon (6% to 8% and 2% to 5% of all diaphyseal humeral fractures, respectively) [1]

This fracture can be treated either conservatively by using functional braces/plaster support or surgically. Non-surgical management has complications like non-union, mal-union, (as the weight of the limb will act as a distracting force) and persistent neurological deficits. Surgical management is considered as the treatment of choice for most open fractures, fractures with vascular injuries, ipsilateral upper extremity segmental fractures, bilateral upper extremity fractures, ipsilateral clavicle fracture, ipsilateral scapular fracture, radial nerve palsy, pathological fractures, Gunshot injuries or patients who have sustained polytrauma. The plate osteosynthesis and an intramedullary nailing are the two most commonly employed fixation methods, both of which carry inherent benefits and complications.

The present study is an attempt to study the advantages & disadvantages of open reduction internal fixation with plate and screws for fracture shaft of Humerus, analyze the results & compare with the relevant standard studies.

## Material & Methods

This study was done as a prospective study among 40 patients admitted for fracture shaft of humerus in the department of Orthopaedic, Rohilkhand Medical College and Hospital, Bareilly between November 2016 to October 2017.

Inclusion criteria were Age- Adults >18 yr, Site- Fracture located at least 5cm distal to the surgical neck and 5 cm proximal to the olecranon fossa; Compound Fracture Type I or II (Gustillo Anderson classification), early conservative treatment failure (non-union and delayed union), bilatera humeral Fracture and ipsilateral forearm fracture, associated with Polytrauma. Pathological fracture, malunited Fracture, infected Fracture and compound Grade III, non union were excluded.

### Each patient will be assessed preoperatively by

1. History- Mode of injury, Interval between injury and admission
2. Local examination of arm including neuro-vascular assessment and U-Slab application
3. General physical examination including co-morbidities
4. The patient's arm radiographs were taken in the Antero-Posterior & Lateral views.
5. Routine investigation (Hb, TLC, DLC, ESR, RBS, Urea, Creatinine, Viral Marker including HIV, HbsAg and HCV, ECG and X-Ray Chest).

In this study, diaphyseal fracture of Humerus were classified according to L. Klenerman's [2] classification. (1966) of London, fractures of the shaft of humerus were classified depending on the level of fracture

1. Fractures of upper third.
2. Fractures at the junction of upper & middle third.
3. Fractures of middle third.
4. Fracture sat the junction of middle & distal third.
5. Fractures of the lower third.

Initially the patient's injured arm is immobilized in a plaster of paris U-slab, drugs are given to alleviate pain. Written & informed consent was obtained from the patient for surgery.

### Operative Technique:

**Anesthesia:** - The patient taken up for surgery under Regional Block.

**Patients Positioning:** The patient is placed in Prone position for Posterior approach & Supine position for Antero-Lateral approach with arm on side board.

**Draping:** The arm with the axilla is Scrubbed with Povidine iodine scrub for 10 minutes, Painted with Povidine iodine solution & spirit, Draped with linen & opsite over the proposed incision site.

**Exposure:** Anterolateral approach for fracture proximal and middle 1/3 shaft humerus and Posterior approach for fracture distal 1/3<sup>rd</sup> shaft humerus.

**Fracture Fixation-** The fracture identified, freshened by curetting, cleaned & approximated. The fracture fragments are Reduced & Plate is placed as assessed pre-operatively, Held with clamps. Then the fracture is fixed with DCP plate and screws with minimum 6 screws. Interfragmentory screws are placed if necessary. The wound is closed in layers, wound is dressed and arm sling pouch applied.

**After treatment:** The wound was inspected on the 2nd

postoperative day. Sutures/staples were removed on 10th postoperative day and check x-ray in antero-posterior and lateral views were obtained. Patients were discharged after suture removal with the arm in an arm pouch and advised to perform shoulder, elbow, wrist and finger movements. They were prohibited from lifting weight or putting additional stresses on the affected limb.

**Follow-up:** All the patients were followed up at monthly intervals for the first 3 months, later at 2 monthly intervals till fracture union and once in 6 months till the completion of study. They were examined in detail clinically and special stress was laid on shoulder and elbow range of movements and subjective complaints. x-rays were obtained in anteroposterior and lateral views and signs of union like disappearance of fracture line and bridging callus were looked for. Clinical healing of the fracture was defined by the absence of functional pain and local tenderness at the previous fracture site.

**Assessment of outcome of the study-** The Results were assessed based on:

1. Pain.
2. Deformity.
3. Range of Movements both of shoulder & elbow.
4. Fracture Union clinically & radiologically.
5. Functional outcome depending on the A.S.E.S. score.
6. Complications like Non-union, Infection & Radial nerve injury.

**Statistical Analysis:** The data were entered in MS office excel sheet and analysis was carried out using the SPSS software 17 and the data were expressed in percentages.

## Results

The present study consists of 40 cases of humeral shaft fractures treated surgically by open reduction and internal fixation using DCP between November 2016 to October 2017. All the patients were available for follow-up.

**Age Incidence:** -The age of the patients in the study ranged from eighteen years to sixty-three years, average being 36.1. (Table-1)

**Table 1:** Age Incidence

Age in Years	Number of patients	Percentage
16 - 25	7	17.5%
26 - 35	15	37.5%
36 - 45	6	15.0%
46 - 55	10	25.0%
56 - 65	2	5.0%

**Sex Distribution:** Majority of the patients, 32 (80%), were males and only 8 (20%) were females.

**Side affected:** The right side was affected more commonly, in 21 patients (52.5%), whereas left side was affected in 19 (47.5%) patients.

**Mode of injury:** 31(77.5%) cases were due to RTA, 4 (10%) cases were due to fall, 3 (7.5%) cases were due to accident at work place and 1(2.5%) case was due to assault.

**Associated injuries:** Out of 40 patients 10 had associated injuries which comprised of 25% of the sample. The details of

the injuries were 3 had Ipsilateral Both Bone Forearm fractures, 1 had Ipsilateral Shaft of Femur & Contralateral Tibia fractures, 1 had Ipsilateral Shaft of Femur fractures& Brachial Plexus Injury and 5 had Radial nerve Injury

**Fracture characteristics:-**

1. Clinical 30 fractures were closed and 10 were open fractures (6 Type I, 4 Type II)
2. Level of fracture- Majority of the fractures were in the middle third (23 in number i.e.57.5%) (Table-2).

**Table 2:** Level of Injury

Level of Injury	Type	Number of Patients	Percentage
Upper 1/3	Type I	1	2.5%
Junction of Upper & Middle 1/3	Type II	3	7.5%
Middle 1/3	Type III	23	57.5%
Junction of Middle & Lower 1/3	Type IV	13	32.5%
Lower 1/3	Type V	0	0.0%
Total		40	100.0%

3. Type of fracture- Majority of fractures were transverse i.e. 18 (45%). There were 13 (32.5%) comminuted fractures, 6 (15%) oblique fracture, 3 (7.5%) spiral fractures and no segmental fractures (Table-3).

**Table 3:** Type of Fracture

Type of Fracture	Number of Patients	Percentage
Oblique	6	15.0%
Transverse	18	45.0%
Spiral	3	7.5%
Segmental	0	0.0%
Comminuted	13	32.5%
Total	40	100.0%

**Table 4:** Time taken for Fracture Union

Fracture Union in weeks	Number of Patients	Percentage
10 – 12 weeks	23	57.5%
13 – 15 weeks	15	37.5%
16 – 18 weeks	1	2.5%
Non-union	1	2.5%
Total	40	100.0%

**Time taken for Fracture Union:** - In the study, the Total time taken for fracture union ranged between 10weeks to 21weeks averaging 11.8 weeks. In Nineteen patients fracture united between 10 to 12 weeks, In Seventeen patients fracture united between 13 to 15 weeks. In one patient fracture united between 16 to 18 weeks & In four patient there were non-union which required revision plating with bone grafting after six months. (Table-4)

**Range of Movements:** -The range of movements were divided into four groups as M I, M II, M III & M IV as mentioned in the key to master chart. Of the forty patients, twenty-three patients had M I range of movements, nine patients had M II range of movements, four patients had M III range of movements & four patients had M IV range of movements at the end of six months.

<b>OUR CRITERIA</b>				
	<b>Excellent</b>	<b>Good</b>	<b>Fair</b>	<b>Poor</b>
Pain (as per V.A.S.)	Nil/Mild (+)	Nil/Mild (+)	Mild/Moderate (+) (++)	Moderate/ Severe (++) (+++)
Deformity(of both rotatory or angulatory)	Nil	Nil	<10°	>10°
<b>R.O.M.</b>				
Shoulder:	M I Full Range	M II	M III	M IV
	Flex-0 to 170/180. Ext- 0 to 40/45. Abd-0 to 170/180. I.R.-0 to 80/90. E.R.-0 to 80/90.	Flex-0 to 140/170 Ext- 0 to 30/40. Abd-0 to 140/170 I.R.-0 to 70/80. E.R.-0 to 70/80	Flex-0 to 120/140 Ext- 0 to 20/30. Abd-0 to 120/140 I.R.-0 to 60/70. E.R.-0 to 50/80	Flex-0 to 70/120 Ext- 0 to 10/20. Abd-0 to 70/120 I.R.-0 to 50/60. E.R.-0 to 30/50
Elbow:	M I Full Range	M II	M III	M IV
	Flex-0/10 to 140/150 Ext-30/40 to 170/180	Flex-10/20 to 130/140 Ext-40/50 to 160/170	Flex-20/30 to 100/130 Ext-50/80 to 150/160	Flex-30/40 to 90/100 Ext-80/90 to 140/150
Fracture Union	10-12 weeks	13-15 weeks	16-18 weeks	>18 weeks
Functional outcome (as per A.S.E.S score)	Grade I (40-52)	Grade II (27-39)	Grade III (14-26)	Grade IV (1-13)
<b>Complications</b>				
	Non-union			
	Infection			
	Radial nerve palsy			

**Table 4:** Our criteria

**Functional Outcome as per A.S.E.S. score:** -The functional outcome was divided into Grade I, Grade II, Grade III & Grade IV as per American Shoulder & Elbow Surgeons Score. Of the forty patients, twenty-four were of Grade I, ten were of Grade II, three were of Grade III & Three were of Grade IV at the end of six months.

**Complications:** -There was only four patient who had Non-union of Diaphyseal fracture of Humerus, for which subsequently revision with plate fixation & bone grafting was done. One patient had surgical site infection and two had Iatrogenic radial nerve palsy.

### Discussion

Diaphyseal fracture of Humerus is a relatively common injury among adults. The management of fracture shaft of Humerus forms a important daily routine of the orthopedic surgeon.

In the present study, forty cases of Diaphyseal fractures of Humerus were surgically managed by plate osteosynthesis. The purpose of the study is to evaluate the outcome of the management of Diaphyseal fractures of Humerus with plate osteosynthesis. The data collected in this study is assessed, analyzed, compared with other series & the results are evaluated.

**Age Distribution-** The average age in our series was 36.1years with the maximum number of patients in the age group of twenty-six to thirty-five years which was similar to the observation of Sam. G. Hunter [3]. 38 yrs, Robert Vander Griend *et al.* [4] -36 Yrs, Dr. Nirav Kumar [5]. 37.93 yrs, Modi N [6]. 36.32 yrs. Mean age was comparable with other studies explaining high incidence in young, active individuals in productive age group who are involved in demanding physical work and vehicular accidents.

**Sex Distribution-**In our study of 40 patients 32 (80%) were males and 8 (20%) were females. In study by Kuppa Srinivas *et al.* [7], incidence of males was 84%, M Vijayashankar *et al.* [8] male was 89% & Dr. Niravkumar Moradiya *et al.* [5] male was 83%. This might be because males are highly exposed to the risk factor, due to highly demanding physical work and vehicular accidents.

**Mode of Injury-** Road traffic accident was the commonest mode of injury in most of the studies. In the present study most common mode of injury was road traffic accidents in 77.5%, fall in 10%, accident at work place in 7.5%, and assault in 2.5%. In study by Kuppa Srinivas *et al.* [7], road traffic accident was the commonest mode of injury (72%), similarly by M Vijayashankar *et al.* [8], RTA was 74%.

**Level of Fracture:** In our study of 40 cases, 57.5% were middle third, 2.5%) were proximal third and 32.5%) were at junction of Middle & Lower 1/3. In study by Kuppa Srinivas *et al.* [7] middle third fractures were the commonest with 80%, & by M Vijayashankar *et al.* [8] with 80%.

**Type of fracture:** Most of the fractures in our series were transverse, 45% patients. This results is in accordance with more recent studies, Kuppa Srinivas *et al.* [7] 52% & M Vijayashankar *et al.* [8] 51%.

**Fracture Union:** 36 (90%) of our 40 fractures united with 4 (10%) fracture going for non-union. Of these 36, there was only 2 (5%) case of delayed union. Probable cause of non-union in one case (2.5%) in the present study was infection

The results in our series are comparable to those obtained by various other authors and even better than Mulier *et al.* [9] and Koch PP *et al.* [10] whom had 75% and 87% respective union rate.

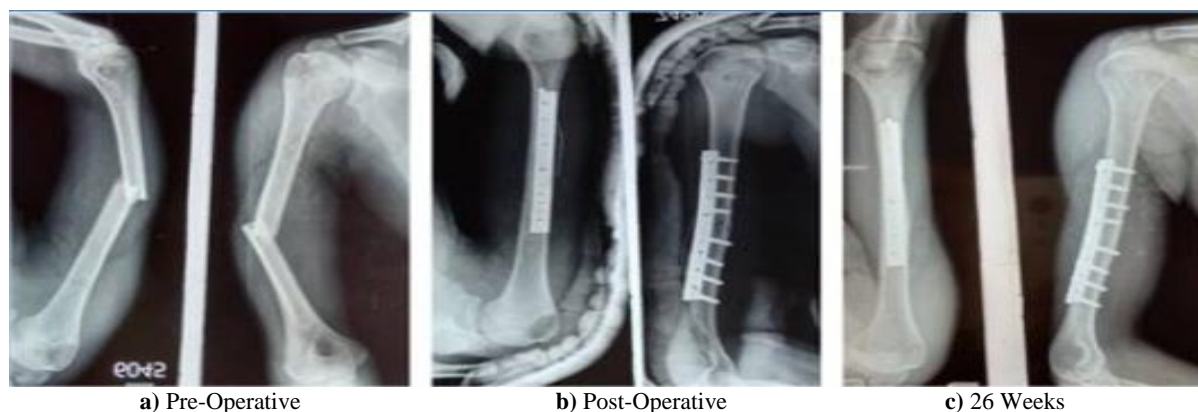
**Range of Mobility of the Elbow and shoulder:** Out of 40 patients in our series, 10% had poor mobility of elbow and shoulder joints which gives 90% good mobility overall. Our results in this aspect i.e. mobility of shoulder and elbow joints are comparable with those of Griend RV, Tomasin J and Ward EF and Heim D *et al.* [11].

**Complication-** Because the radial nerve lies in close proximity to the humeral shaft, it may be injured by any operative approach to the humerus. In our series two patient (5%) had transient iatrogenic nerve palsy. The radial nerve recovered in 3 months. Seddon stated that 70% of radial nerve injuries associated with humeral shaft fractures will recover. One patient has surgical side infection which was treated by wound debridement and I/V antibiotics according to culture and sensitivity.

**Overall Results:** We had 34 (85%) patients with excellent or good results out of 40 patients in our series which is in par with Rodriguez-Mechan EC [12] at the same time better than Mulier *et al.* [9] and Heim D *et al.* [11].

### Conclusion

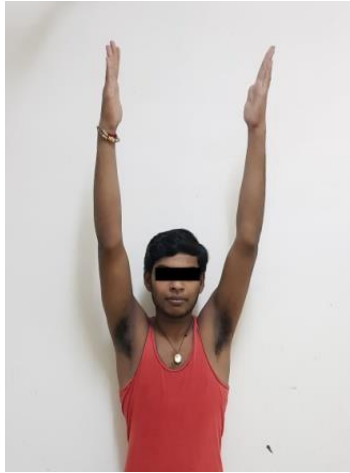In the conclusion of this study, 40 patients of humeral shaft fractures that were treated by plate osteosynthesis, fractures were found in young male cases and Road traffic accidents were seen in majority. The plate osteosynthesis is the very good management method for treatment of fracture shaft of Humerus with very low rate of complications.



**Fig 1:** (A) Pre-Operative (A) Post-Operative (C) 26 Weeks



a) Shoulder Abduction



b) Over Head Shoulder Abduction



c) Elbow Extension with Wrist Dorsiflexion



d) Elbow Flexion

**Fig 2:** Range of motion at shoulder, elbow and wrist

## References

1. Rockwood Green's – Fractures in Adults. eight edition, 2014, 1287-1336.
2. Klenerman L. Fractures of shaft of the Humerus. J.B.J.S. 1966; 48B:105-111.
3. Sam G, Hunter MB. The Closed Treatment of Fractures of The Humeral Shaft C.O.R.R. 1982; 164:192-198.
4. Robert Vander Griend, John Tomasin, Frazier Ward E. & Jackson-Open Reduction & Internal Fixation of Humeral Shaft Fractures J.B.J.S. vol-68A, March 1986, 430- 433.
5. Dr. Niravkumar Moradiya, Dr. Tarun V Desai, *et al.* A study of humerus shaft fractures treated with dynamic compression plating. IJOS. 2017; 3(1): 364-369
6. Modi N, Pundkar GN. Comparative study of functional outcome of Dynamic compression plating with Intramedullary Interlocking nailing in close fracture shaft of humerus in adults. J Res Med Den Sci. 2015; 3(4):298-302.
7. Kuppa Srinivas *et al.* A Study of Surgical Management of Diaphyseal Fractures of Humerus by Dynamic Compression Plate Osteosynthesis. Journal of Evolution of Medical and Dental Sciences. 2015; 4(08):1290-1296,
8. Vijayashankar M, Jayaprakash MS, Balaji Arumugam. A Prospective Analysis of Functional Outcome of Humeral Diaphyseal Fractures Treated with Dynamic Compression Plate, International Journal of Contemporary Medical Research. 2016; 3(9):2725-2728
9. Schatzker J. Screws and plates and their application. In: Muller ME, Allgower M, Schneider R, Willenegger H editors. Manual of Internal Fixation. 3rd ed. Berlin: Springer Verlag; 1991, 179.
10. Koch PP, Gross DF, Gerber C. The results of functional (Sarmiento) bracing of humeral shaft fractures. J Shoulder Elbow Surg. 2002; 11:143-147.
11. Heim D, Herkert F, Hess P, Regazzoni P. Surgical treatment of humeral shaft fractures- the Basel experience. J Trauma. 1993; 35:226-31.
12. Rodriguez- Merchan EC. Compression plating versus hackethal nailing in closed humeral shaft fractures failing nonoperative reduction. J Orthop Trauma. 1995; 9:194.