



ISSN: 2395-1958  
IJOS 2019; 5(2): 1001-1004  
© 2019 IJOS  
www.orthopaper.com  
Received: 09-02-2019  
Accepted: 13-03-2019

**Dr. S Sukumaran**  
Associate Professor, Department  
Of Orthopaedics, Stanley  
Medical College, Chennai, Tamil  
Nadu, India

**Dr. Ashokan C**  
Associate Professor, Department  
of Orthopaedics, Stanley Medical  
College, Chennai, Tamil Nadu,  
India

**Dr. Nagendran K**  
Junior Resident, Department of  
Orthopaedics, Stanley medical  
College, Chennai, Tamil Nadu,  
India

**Dr. Kathirazhagan S**  
Senior Resident, Department of  
Orthopaedics, Tagore Medical  
College, Chennai, Tamil Nadu,  
India

**Correspondence**  
**Dr. Ashokan C**  
Associate Professor, Department  
of Orthopaedics, Stanley Medical  
College, Chennai, Tamil Nadu,  
India

## Is proximal fibular osteotomy a boon or bane for medial compartment osteoarthritis? - Our experience

**Dr. S Sukumaran, Dr. Ashokan C, Dr. Nagendran K and Dr. Kathirazhagan S**

DOI: <https://doi.org/10.22271/ortho.2019.v5.i2o.1467>

### Abstract

**Objective:** To evaluate the functional and radiological outcome in medial compartment osteoarthritic knee treated with proximal fibular osteotomy as a new modality of treatment.

**Materials and Methods:** Fifteen patients (10 men and 5 women, age range between 50-68 years) from May 2016 to May 2018 who had undergone proximal fibular osteotomy for medial compartment osteoarthritis knee were followed prospectively. Pre-operative and post-operative weight bearing scan gram obtained to analyse the alignment of lower limb (Femoro tibial angle) and ratio of joint space (medial/lateral joint space). Functional Outcome was assessed with American Knee Society Score (KSS) and Knee pain was assessed with Visual analogue scale.

**Results:** At final followup the mean Femoro-Tibial angle and joint space ratio were 180.4 and 0.54 respectively. The limb alignment is corrected in few cases and joint space ratio is increased postoperatively. Mean Knee Society Score at final follow up was 75.13 which was higher than the mean preoperative score 52.5. Mean Vas score is reduced significantly up to 4 (preoperative mean Vas score was 8).

**Conclusion:** The present study demonstrates the proximal fibular osteotomy effectively relieves the pain and improves the joint function in the patients with medial compartment osteoarthritis of knee by shifting the mechanical axis. Conversion to total knee replacement or unicompartmental arthroplasty is also less complicated.

**Keywords:** Osteoarthritis, fibular osteotomy

### Introduction

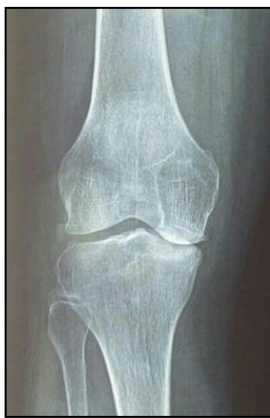Osteoarthritis (OA) of the knee is the progressive degenerative condition which affects the articular cartilage which results in pain, deformity and disability of the affected joint. It is one of the major causes of pain and physical disability in the elderly Indian population (due to preponderance of varus knee) and incidence is 240 per 100,000 per year [3]. It is most commonly seen in males less than 50 years and in females older than 50 years. Non modifiable risk factors associated with osteoarthritis of the knee are increasing age, females, genetics and modifiable risk factors are articular trauma, occupation, obesity and secondary life style [1, 2, 3]. Medial compartment is affected early due to single cortical support and during swing phase its action as pivot.

Various modalities of treatment such as intra articular injections, physiotherapy, visco supplementation, arthroscopic debridement, high tibial osteotomy and unicompartmental knee replacement [1]. All these procedures are associated with their own merits and demerits. High tibial osteotomy and unicompartmental replacement are technically demanding procedures and needs longer learning curve and also it may hinder the future definitive procedure.

Hence it warrants a new modality of treatment which is cost effective, easy to perform with fewer complications. In this scenario proximal fibular osteotomy is a novel method for the management of medial compartment osteoarthritis. Proximal fibular osteotomy is based on the 'theory of differential settlement' [9]. This treatment approach is characterised by minimal trauma, few complications, definite effects and wide clinical applications [14]. The aim of this study is to analyse the functional and radiological outcome of PFO for medial compartment osteoarthritis.

**Materials and Methods**

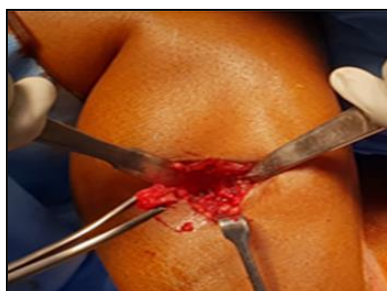
It is a prospective analytic study conducted in Govt. Stanley medical college, Chennai. 15 patients with uni compartment arthritis who presented between May 2016 to May 2018 managed by PFO were included in our study. This study was approved by the ethical committee of our institution. The inclusion criteria were age more than 40 years and isolated medial compartment arthritis while the exclusion criteria were age less than 40 years, valgus knee, tricompartmental arthritis, inflammatory arthritis and medically unfit patient. Preoperatively, all patients were assessed clinically and radiologically. Standard weight bearing X rays of the affected knee were taken in anteroposterior and lateral views and the radiological parameters such as hipkneeangle (HKA) and joint space ratio (medial / lateral space) were calculated and documented in the case sheets. Pre-operative the Visual analogue score (VAS) and the American knee society score was calculated. After obtaining anaesthetic fitness and informed written consent, the patients were taken up for the procedure.




**Fig 1:** Shows the calculation of joint space ratio is the medial joint space divided by lateral joint space.

**Operative procedure**

All 15 patients were operated under regional anesthesia. Patient were placed in supine position with sand bag placed under the ipsilateral pelvis to nullify the tibial torsion. All were operated under tourniquet control. Through posterolateral approach a skin incision of 5 centimetres was made 8-10cm below the head of fibula. The reason behind choosing this level is that an osteotomy at a higher level may injure the common peroneal nerve while if it was done any lower down that the effect of the osteotomy on the medial compartment arthritis would be lost. Subcutaneous and deep fascia was incised along the line of incision. Peroneus and soleus muscle was retracted by using retractors. 1.5- 2cm fibula is excised by using osteotome, Ends are freshened and smoothed. Bone wax used to arrest medullary bleed. Wound wash given. Wound closed in layers.



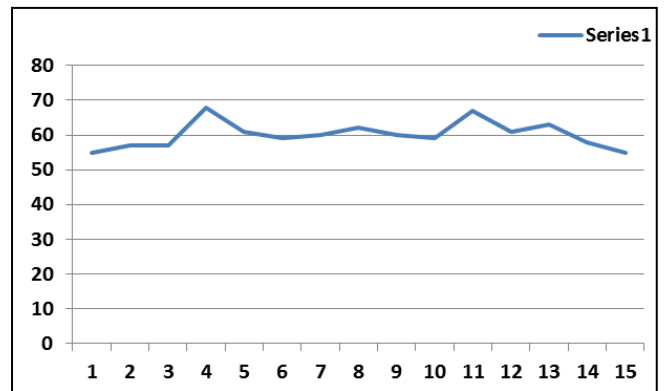
**Fig 2:** Incision and exposure



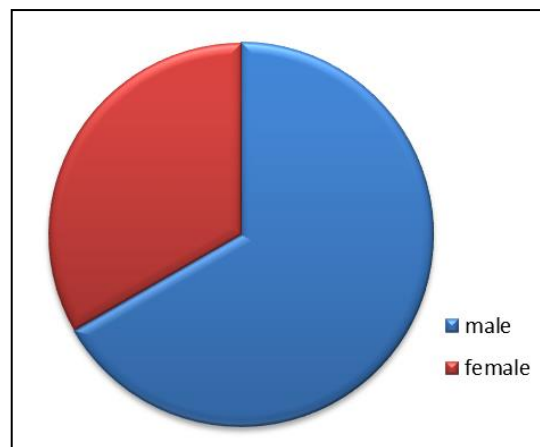
**Fig 3:** 2 cm Fibulectomy

**Results**

15 patients 17 knees with medial compartment arthritis of the knee who presented between May 2016 and May 2018 were managed with PFO and were followed up for a minimum period of 18 months. There was a male preponderance seen in our study with the right sided knee being more commonly affected. Two cases bilateral knee was operated. The age of the patients ranged from 52 to 63 years with the mean age being 56.8 years.



**Fig 4:** Age wise distribution



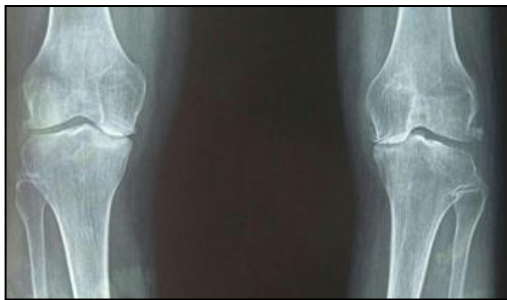**Fig 5:** Sex wise distribution

At final follow up the mean Femoro-Tibial angle and joint space ratio were 180.4 and 0.54 respectively. The limb alignment is corrected in few cases and joint space ratio is increased postoperatively. Mean Knee Society Score at final follow up was 75.13 which is good compared to preoperative clinical assessment. Pre-operative mean vas score was 8.It is significantly reduced into 4 at the final follow up.

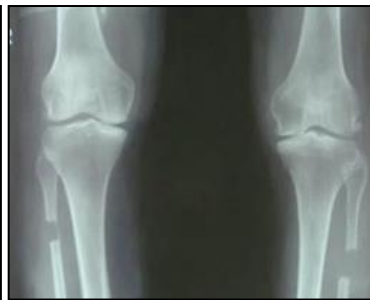**Table 1:** Results

S. No	Parameters	Pre-op	Post -op
1	Joint space ratio	0.40	0.54
2	Hip knee ankle angle	185.8	180.4
3	Vas score	8	4

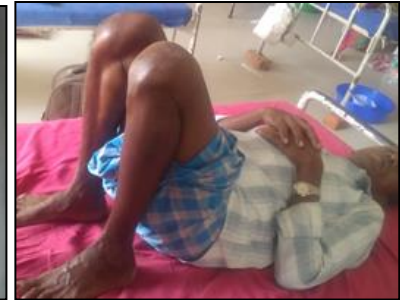Postoperative period was uneventful in all cases except three cases who developed complications. Two patients had extensor hallucis longus weakness and recovered after four weeks. one patient had numbness over the dorsum of foot. There were no common peroneal nerve injury and infection. All patients were satisfied with PFO in terms of pain relief and improved knee function.



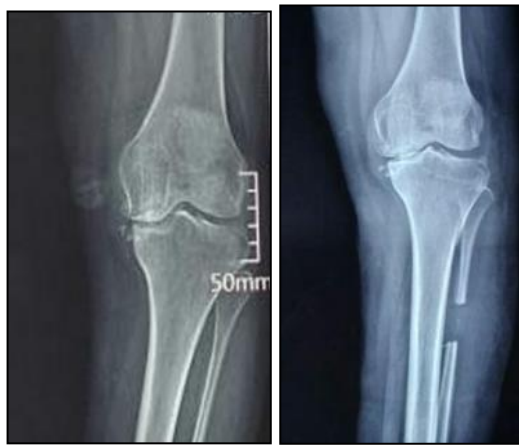Case 1: Pre op xray



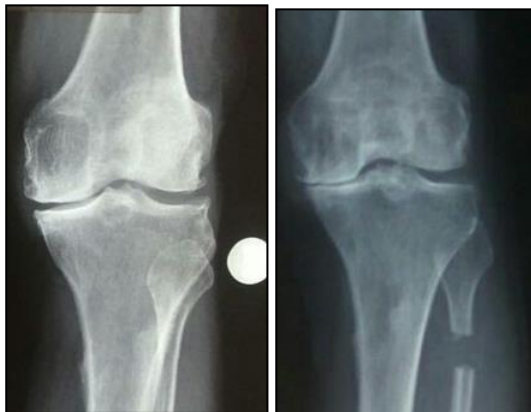Post op xray



Post op knee flexion



Case 2: Preop xray &amp; postop xray



Case 3: Preop xray &amp; postop xray

replacement is available in the management of medial compartment arthritis of the knee which has mixed results according to various studies as found in literature. This procedure could be associated with problems such as poly wear, progression of arthritis or loosening of components [12, 13]. Certain studies have demonstrated a high rate of revision for unicompartmental knee replacement as compared to a Total knee replacement [12, 13].

In this scenario, there is a need for a procedure which is cost-effective, easy to perform, gives good functional results and associated with a shorter recovery period and improves the quality of life for the affected patients. The theory behind the development of medial compartment arthritis suggests that there is an uneven distribution of load across both tibial plateaus with more stress transmitted on the medial side [9, 10]. Hence it becomes weaker with degeneration of the articular cartilage. PFO acts by removing the tricortical support laterally and shifts the stress from the medial to the lateral compartment resulting in relief of pain and provides good functional outcome.

In a study by Yang *et al*, 150 patients with medial compartment arthritis were followed up for a period of more than 2 years. The preoperative KSS score was  $45 \pm 21.3$  while postoperatively it was  $92.3 \pm 31.7$ . The mean VAS score preoperatively was 7 which significantly decreased to 2 in the postoperative period. They stated that PFO dramatically improves the function of the knee and gives good pain relief [15]. In a study by Bo Liu *et al*, they had 84 patients with 111 knees being affected by medial compartment arthritis. The average preoperative VAS score was  $7.08 \pm 1.41$ . The average preoperative KSS and functional scores were  $49.14 \pm 10.95$  and  $44.97 \pm 17.1$  while postoperatively it was  $67.77 \pm 11.08$  and  $64.66 \pm 13.12$  respectively. 51 knees were associated with a satisfactory clinical outcome while 77 knees had a significant improvement [17].

In our study, we had 15 patients who were treated by PFO and were followed up to a period of 18 months. Following the surgery all patients had drastic pain relief with the VAS score dropping significantly from 8 to 4 postoperatively ( $P < 0.005$ ). The average preoperative Oxford score also showed a significant improvement from 52.2 preoperatively to 79 in the postoperative period ( $P < 0.005$ ). We also documented that the opening out of medial joint space occurs in all cases after PFO. The joint space ratio is significantly increased from 0.40 to 0.54. Patients with nearly normal HKA angles showed

## Discussion

The conservative management for unicompartmental osteoarthritis is providing the short-term benefits to the patient [1, 2]. The surgical options for medial compartment osteoarthritis are limited to High tibial osteotomy and Unicompartmental knee replacement. High tibial osteotomy corrects the varus deformity and decompresses the medial compartment of the knee but it is associated with a longer recovery period and a prolonged period of non-weight bearing walking until union of the osteotomy site. There can be issues such as recurrence of deformity and can also lead to revision to a Total knee Arthroplasty. [5, 7, 8]. Unicompartmental knee

better outcomes in joint function, because of the fact that PFO could only correct the varus deformity partially. Studies have shown that patients with grade 4 osteoarthritis had varus deformity in the femoral condyle as well <sup>[10]</sup>. For these patients, PFO may not relieve the pain fully.

In our study demonstrates the proximal fibular osteotomy effectively relieves the pain and improves the joint function in the patients with medial compartment osteoarthritis of knee by shifting the mechanical axis.

It is simple, fast and safe day care surgery with less complications with immediate return to function. May negate the need for replacement. If the procedure does not give good results in any situation then the field for performing a Total knee arthroplasty at a later stage is not altered at all. Limitation of this study is smaller sample size and shorter follow up period. Control group is not allotted. Research studies on this topic are less and mechanism is unclear.

### Conclusion

We thereby conclude that PFO is a novel alternative method in the management of medial compartment arthritis of the knee. It is a simple, cost effective, easy to perform procedure and gives drastic pain relief postoperatively. It is associated with fewer complications and a shorter recovery time as compared to proximal tibial osteotomy and Unicompartmental knee replacement. A longer period of follow up is necessary to conclude whether the beneficial effects of PFO are sustained over a period of time.

### References

1. Ringdahl E, Pandit S. Treatment of knee osteoarthritis. *Am Fam Physician*. 2011; 83:1287-92.
2. Kon E, Filardo G, Drobnic M, Madry H, Jelic M, Dijk N *et al*. Non-surgical management of early knee osteoarthritis. *Knee Surg Sports Traumatol Arthrosc*. 2012; 20:436-9.
3. Michael JW, Schluter-Brust KU, Eysel P. The epidemiology, etiology, diagnosis, and treatment of osteoarthritis of the knee. *Dtsch Arztebl Int*. 2010; 107:152-62.
4. Seed SM, Dunican KC, Lynch AM. Treatment options for osteoarthritis: considerations for older adults. *Hosp Pract (Minneap)*. 2011; 39:62-73.
5. Jackson JP. Osteotomy for osteoarthritis of the knee. *Proceedings of the Sheffield Regional Orthopaedic Club. The Journal of Bone and Joint Surgery*. 1958; 40(4):826.
6. Zhang YZ. Innovations in Orthopedics and Traumatology in China. *Chin Med J (Engl)*. 2015; 128:2841-2842. [PMC free article] [PubMed]
7. Duivenvoorden T, Brouwer RW, Baan A, *et al*. Comparison of closing-wedge and opening-wedge high tibial osteotomy for medial compartment osteoarthritis of the knee: a randomized controlled trial with a six-year follow-up. *J Bone Joint Surg Am*. 2014; 96:1425-1432. [PubMed]
8. Laprade RF, Spiridonov SI, Nystrom LM, *et al*. Prospective outcomes of young and middle-aged adults with medial compartment osteoarthritis treated with a proximal tibial opening wedge osteotomy. *Arthroscopy*. 2012; 28:354-364.
9. Dong T, Chen W, Zhang F, Yin B, Tian Y, Zhang Y, *et al*. Radiographic measures of settlement phenomenon in patients with medial compartment knee osteoarthritis. *Clin Rheumatol*. 2016; 35(6):1573-1578. pmid:26712497
10. Cooke D, Scudamore A, Li J, Wyss U, Bryant T,

Costigan P. Axial lower-limb alignment: comparison of knee geometry in normal volunteers and osteoarthritis patients. *Osteoarthritis Cartilage*. 1997; 5(1):39-47. pmid: 9010877

11. Adams JG, Mcalindon T, Dimasi M, Carey J, Eustace S. Contribution of meniscal extrusion and cartilage loss to joint space narrowing in osteoarthritis. *Clin Radiol*. 1999; 54(8):502-506. pmid:10484216
12. Aleto TJ, Berend ME, Ritter MA, Faris PM, Meneghini RM. Early failure of unicompartmental knee arthroplasty leading to revision. *J Arthroplasty*, 2008, 159-63.
13. Morris MJ, Molli RG, Berend KR, Lombardi AV Jr. Mortality and perioperative complications after unicompartmental knee arthroplasty. *Knee*. 2013; 20:218-220.
14. Proximal fibular osteotomy: a new surgery for pain relief and improvement of joint function in patients with knee osteoarthritis Xiaohu Wang *et al*.
15. Medial Compartment Decompression by Fibular Osteotomy to Treat Medial Compartment Knee Osteoarthritis: A Pilot Study Zong-You Yang *et al*.
16. The effect of partial fibulectomy on contact pressure of the knee: A cadaveric study Hamidreza Yazdi *et al*.
17. Bo Liu, Wei Chen, Qi Zhang, Xiaoli Yan, Fei Zhang, Tianhua Dong *et al*. Proximal fibular osteotomy to treat medial compartment knee osteoarthritis: Preoperational factors for short-term prognosis. Published, 2018, 24. <https://doi.org/10.1371/journal.pone.0197980>