



# International Journal of Orthopaedics Sciences

ISSN: 2395-1958  
IJOS 2019; 5(2): 903-906  
© 2019 IJOS  
www.orthopaper.com  
Received: 21-02-2019  
Accepted: 25-03-2019

**Márcio Oliveira**  
Orthopedics Department of Vila  
Nova de Gaia/Espinho Hospital  
Center, Portugal

**Rita Grazina**  
Orthopedics Department of Vila  
Nova de Gaia/Espinho Hospital  
Center, Portugal

**Moisés Ventura**  
Orthopedics Department of Vila  
Nova de Gaia/Espinho Hospital  
Center, Portugal

**Raúl Cerqueira**  
Orthopedics Department of Vila  
Nova de Gaia/Espinho Hospital  
Center, Portugal

**Campos Lemos**  
Orthopedics Department of Vila  
Nova de Gaia/Espinho Hospital  
Center, Portugal

## Calcaneal fractures treatment with locking nail: is it an option?

**Márcio Oliveira, Rita Grazina, Moisés Ventura, Raúl Cerqueira and Campos Lemos**

DOI: <https://doi.org/10.22271/ortho.2019.v5.i2m.109>

### Abstract

Surgical treatment of calcaneal fractures continues to be a challenge for surgeons owing to the high risk of complications. The aims of this study were to analyze the results of percutaneous locking nail fixation, including radiologic and functional outcomes, complications, time to surgery and to hospital discharge.

This is a retrospective study, that assessed calcaneal fractures treated with a percutaneous locking nail (Calcanail, FH Orthopedics). The fractures were classified according to *Sanders*. Pain, function and range of motion were evaluated at final follow up, according to the visual analogue scale (VAS), the foot and Ankle Outcome Score (FAOS) and the American Orthopaedic Foot and Ankle Society Ankle-Hind foot Score (AOFAS-AHS), respectively.

Between July 2016 and May 2018, 12 patients and 13 fractures were identified.

The mean time to surgical procedure was 10.5 days, with 1 day of hospital stay.

The average AOFAS and FAOS scores were 87.8 and 79.2% respectively, at a mean final follow-up of 16 months, and the mean VAS was 1.83/10. Böhler and Gissane angles improved from 18° and 132° to 28° and 122° respectively. The mean improve of calcaneal height was 0.5 cm. The mean time to return to daily activity level was 3.3 months and to work 4 months.

8% of the patients had complications severe enough to require a new intervention, and we had no skin complications.

Percutaneous calcaneal fracture fixation with locking nail appears to be an effective and reliable procedure. It is a surgical option in selected patients.

**Keywords:** Calcaneal fracture, percutaneous fixation, locking nail

### Introduction

Calcaneal fractures accounts for about 2% of all fractures <sup>[1]</sup>. The patients are mostly young men between 21 and 45 years old, with high-energy axial trauma. These fractures must be recognized as severe lesions, characterized by the high incidence of associated injuries (50%), bilaterally (19.2%) and open fractures (28.9%) <sup>[2]</sup>.

Thus, surgical treatment provides a challenge for surgeons owing to the high risk of wound complications, malunions and posttraumatic osteoarthritis.

The L-shaped extensile lateral approach with open reduction and internal fixation (ORIF) is the most common approach used to access most displaced intra-articular calcaneal fractures. However, this procedure has a significant rate of wound complications, which may reach 30%, with significant number of second intervention, 21% <sup>[3]</sup>. Wound infection and necrosis can affect 16% and 8% respectively <sup>[4]</sup>.

As such, less invasive techniques emerged to the restoration of joint congruity and calcaneal shape in displaced intra-articular calcaneal fractures, namely minimally invasive and percutaneous approach <sup>[5, 6]</sup>.

In the field of percutaneous approach, the locking calcaneal nail was developed to combine the advantages of a less invasive approach and stable percutaneous fixation. The *Calcanail* system is used to perform both intrafocal reduction and internal locked fixation, and is characterized by a vertical position from the posterior calcaneal tuberosity to the subtalar joint which is also supported by two horizontal locked screws <sup>[7, 8]</sup>.

**Correspondence**  
**Márcio Oliveira**  
Orthopedics Department of Vila  
Nova de Gaia/Espinho Hospital  
Center, Portugal

The proposed advantages are: the creation of a working channel that provides a bone autograft, the intrafocal reduction of the displaced articular surface, the insertion of a locking nail that maintains the reduced articular surface at the right height, the possibility to switch from an ORIF to a reconstruction arthrodesis with the same approach and instrumentation<sup>[9]</sup>.

In biomechanical studies, intramedullary nail prove to have high primary stability compared with locking plates, which represent another important advantage<sup>[10, 11, 12]</sup>.

On the other hand, minimally invasive approach appears to be superior in terms of society cost benefit compared to nonoperative management and open approach in Sander II and III fractures<sup>[13]</sup>.

### Objectives

The aims of this study were to analyze the results of percutaneous locking nail fixation (Calcanail, FH Orthopaedics) in calcaneal fractures, including radiologic and functional outcomes, related complications, time to surgery and to hospital discharge. The authors suggest the main advantages and disadvantages of this approach and describe the surgical technique.

### Material and Methods

This is a retrospective study in a level 1 Trauma Center, conducted in a teaching hospital, that assessed calcaneal fractures treated with a percutaneous locking nail (Calcanail®, FH Orthopedics, a device approved by the *Food and Drug Administration* since 2015)<sup>[9, 14]</sup>. This implant is available in three lengths (45, 50, and 55 mm) and 10 mm diameter, with two windows and two holes for the locking screws. The nail has indentations that provide subchondral bone anchorage. The locking screws are cannulated and have large heads for compression.

All patients were admitted in our emergency department between July 2016 and May 2018. Calcaneal fractures were diagnosed and preoperatively study was performed in all patients with lateral and axial x-rays, as well as CT scan. The same x-ray views were performed postoperatively in all patients, as well as CT scan when required.

The measurement of Gissane and Böhler angles were performed in lateral view, as well as the height of the posterior facet. Böhler angle was measured by the intersection of two lines on lateral x-ray: from the highest point of the anterior process to the highest point of the posterior facet and tangential to the superior edge of the tuberosity<sup>[15]</sup>. Gissane's angle was measured from a line tangential to the posterior facet and a line from the sulcus calcaneus to the tip of the anterior process<sup>[3]</sup>. The height of the posterior facet, was measured by a line perpendicular to the calcaneal axis to the highest point of the posterior facet<sup>[16]</sup>. Digital radiographs measurements were obtained, using Sectra IDS7 workstation software, and compared pre and postoperatively.

A demographic population analysis was performed and the fractures were classified according to Sanders<sup>[17]</sup>. The fractures were also characterized by the number of associated lesions and by open or closed fractures. The pain, function and range of motion results were evaluated at final follow up, according to the visual analogue scale (VAS), the Foot and Ankle Outcome Score (FAOS) and the American Orthopaedic Foot and Ankle Society Ankle-Hind foot Score (AOFAS-AHS), respectively. The time to surgery and to hospital discharge was recorded, as well as all complications.

All fractures were immobilized with plaster slab until the

surgery was performed, with no weight bearing and postural drainage of the limb. Patients with open fractures were submitted to an extensive clean and lavage with saline solution at admission, antibiotic treatment and temporary external fixation (when required) until definitive treatment.

All patients were treated by the same surgical technique according to *Goldzak*<sup>[12]</sup>. Surgery was performed only after adequate soft tissues conditions. A lateral decubitus was the patient position of choice, with the injured side upward, so that the procedure could be performed on a sterile wrapped fluoroscopic receiver, to allow for a lateral and axial calcaneal views. The fracture was approached by a 2cm skin straight to calcaneal tuberosity incision. A guide wire was positioned through the calcaneal tuberosity to posterior talar articular surface, in the calcaneal axis targeted at the fourth interdigital space, under fluoroscopic control. A guide device was used for the insertion of two lateral pins for the Caspar distractor, one at the posterior superior part of the calcaneal tuberosity, other at the talar dome. A convergent direction of the distractor pins allows for correction of the varus position of the tuberosity fragment. After subtalar and fracture distraction, a channel was created through the guide pin by a trephine, allowing for autologous bone graft harvest.

The Caspar distractor allows then the correction of varus malposition, gain height and facilitates the reduction of the depressed articular surface. Finally, we performed an internal intrafocal reduction of dislocated depressed calcaneal fragments with the corresponding graft pushers. The aim was to achieve an anatomical subtalar joint surface with restoration of the Gissane angle. Once reduction was achieved, an intramedullary nail was introduced through the same channel and locked with two lateral screws.

### Results

Among 13 patients submitted to surgical procedure with percutaneous locking nail, one required a primary subtalar fusion and was excluded from the study. Thus, our sample included 12 patients and 13 fractures, with a mean age of 48 years old (31-76), 66.7% (8/12) males and 33.3% (4/12) females.

According to the Sanders classification<sup>[17]</sup>, we had 30.8% (4/13) of fractures with 2A type, 15.4% (2/13) with 2B, 7.7% (1/13) with 2C and 46.1% (6/13) with type 3.

The mean time between the fracture and the surgical procedure was 10.5 days (2-20). Two patients were surgically managed in a first approach with external fixation due to open fractures.

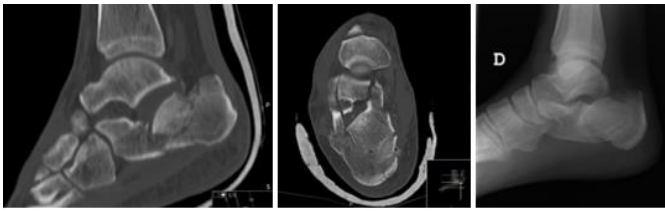
Associated lesions were founded in 33.3% (4/12) of the patients; one pelvic fracture, one sub-trochanteric femur fracture, one contralateral calcaneal fracture, one distal radius fracture, one medial malleolar fracture of the ankle and a Lisfranc fracture of the contralateral foot. All patients were discharged from the hospital the day after surgery.

The patients were followed between July 2016 and March 2019, with mean final follow-up of 16 months (10-28). For the 12 patients, the average AOFAS and FAOS scores were 87.8 (59-100) and 79.2% (51-94) respectively. The mean VAS was 1.83/10 (1/10-3/10).

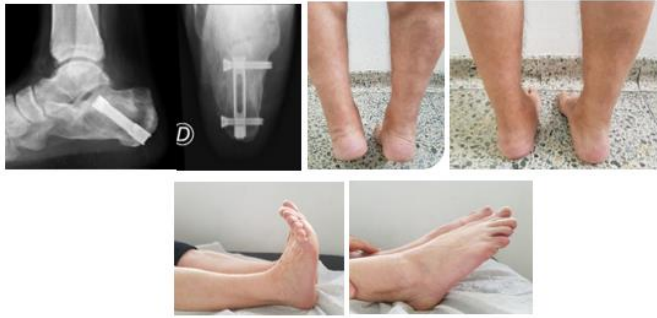All patients had stable ankle joint with all having dorsiflexion and plantar flexion more than 30 degrees. Böhler and Gissane angles improved from an average of 18° and 132° preoperatively to 28.0° and 122° at final follow-up respectively. The height of posterior facet of the calcaneus improved from an average of 4.0cm to 4.5 cm in the same period. The mean time to return to daily activity level was 3.3

months and to work 4 months.

Figure 1 shows a pre-operative study of *Sanders* type 3 right calcaneal fracture, showing a major depressed posterior articular fragment.



**Fig 1:** Preoperative study of *Sanders* type 3 right calcaneal fracture, showing a major depressed posterior articular fragment.



**Fig 2:** Radiologic and functional postoperative results, after 1 year of calcaneal nail fixation.

Figure 2 shows radiological improvement, and figure 3 functional improvement after 1 year of calcaneal nail fixation. Two patients were submitted to an implant removal, one for subtalar complaints, other for insurance company decision. One patient with open fracture had a deep infection treated conservatively, one patient had a transient sural neuropraxia. We had no skin complications, implant failure or conversion to arthrodesis as well as other surgical procedures. Although the global incidence of complications was 23% (3/13), only in 15% (2/13) of the patients the complications were directly related to the surgical procedure, and only 8% (1/13) were severe enough to require a new intervention.

## Discussion

The treatment of intra-articular calcaneal fractures is far from ideal. Nonoperative treatment results are unsatisfactory with high rates of malunion, painful deformity and secondary arthritis.

Operative treatment aims to restore calcaneal shape and subtalar joint. However, open reduction and internal fixation with extensile approaches, namely lateral approach, have high rate of complications: hematoma, skin necrosis, soft tissue infection and material related [3, 4].

Therefore, less invasive approaches and new reduction techniques could be the treatment of choice in the future, reducing the surgical trauma and complication risk.

The biomechanical tests support this concept. Intramedullary calcaneal nail displayed a significantly stiffness and load to failure, even when compared with calcaneal plate [10, 11, 12].

However, there are few data in the literature about this subject. In a series of 10 patients treated with Calcanail (FH Orthopaedics), *Godzak et al.* [18] reported no wound infections and an average AOFAS score of 84.

Good results were also demonstrated by *Hans Zwipp et al.* [19], in 106 cases treated with C-Nail internal fixation adjunct with

arthroscopy, fluoroscopy and sinus tarsi approach. The complication rate was 1.9% of wound edge necrosis and 0.9% soft tissue infection. There was a significant improvement of Böhler angle and posterior facet step-off. The average AOFAS score was 92.6 at 12-month follow-up.

We did not directly evaluate reduction of the posterior facet. Although anatomic articular reduction is a basic principle of articular fractures treatment, it has been suggested that absolute anatomical posterior facet reduction may not be essential for a good outcome, as long as the overall shape and alignment of calcaneus is restored [20, 21, 22]. On the other hand, the *Calcanail* technique can provide good reduction in three quarter of cases [23].

In our results, the mean age of patients was higher than that described in the literature (Average of 48 years old). Otherwise, 66.7% of patients were males, and there are a high number of associated lesions (33.3%), as a result of a high energy mechanism.

We perform a percutaneous locking nail technique in a high range of calcaneal fractures severity, including type III (46.1%) according to *Sanders* classification, which may have a negative effect in the results. Even so, every patient achieved an improvement of Böhler and Gissane angles (Mean of 10° in both measurements), as well as the height of posterior facet of the calcaneus (mean of 0.5cm).

The authors suggest the apparent advantage of reduced surgical time for this procedure, although it was not possible to access these records.

We have excellent results in AOFAS score ( $\geq 90\%$ ) in 62% of the patients, followed by good results (AOFAS score 80-89%) in 23% patients, and less satisfactory results (AOFAS score  $< 80\%$ ) in 15% of the patients. The mean AOFAS score of 87.8 % could suggest that this method of fixation can be at least as good as open reduction (mean AOFAS score of 73.7) [24].

One of the advocated major advantage of this approach was the low incidence of complications. In our results, only 8% (1/13) of the patients had a complication directly related to the surgical procedure and severe enough to require a new intervention.

Our results confirm the low incidence of wound healing problems. In our series, only one patient had a deep infection due to a *Gustilo* type II open fracture, treated with antibiotics, without need of material removal. Therefore, the immediate good outcome allows reduced hospital length of stay (mean time of 1 day). There was no infection or necrosis complications in patients with closed fractures, comparing to 16% and 8% in some reports [4].

As limitations, this is a retrospective study, with a small sample and a short follow-up period. Therefore, it was not possible to obtain statistical analysis and correlate some important variables. Moreover, we didn't perform a regular CT scan during follow-up, so we couldn't evaluate the degree of articular reduction.

## Conclusion

The treatment of calcaneal fractures is far from ideal. According to our results, percutaneous calcaneal fracture fixation with locking nail appears to be an effective and reliable procedure. It is a surgical option in selected patients. Functional and radiographic results were satisfactory with acceptable complication rate and with advantage of lower skin and implant related problems. A long-term follow-up is needed.

## References

1. Veltman ES, Doornberg JN, Stufkens SA, Luitse JS, van denBekerom MP. Long-term outcomes of 1,730 calcaneal fractures: systematic review of the literature. *J Foot Ankle Surg.* 2013; 52(4):486-90.
2. Leite CBG, Macedo RS, Saito GH, Sakaki MH, Kojima KE, Fernandes TD. Epidemiological study on calcaneus fractures in a tertiary hospital. *Rev Bras Ortop.* 2018; 53(4):472-476.
3. Böhler L. Diagnosis, pathology, and treatment of fractures of the os calcis. *J Bone Joint Surg.* 1931; 13:75-89.
4. Koski A, Kuokkanen H, Tukiainen E. Postoperative wound complications after internal fixation of closed calcaneal fractures: a retrospective analysis of 126 consecutive patients with 148 fractures. *Scand J Surg.* 2005; 94:243-5.
5. Kline AJ, Anderson RB, Davis WH, Jones CP, Cohen BE *et al.* Minimally invasive technique versus an extensile lateral approach for intra-articular calcaneal fractures. *Foot Ankle Int.* 2013; 34:773-80.
6. Sampath Kumar V, Marimuthu K, Subramani S, Sharma V, Bera J, Kotwal P. Prospective randomized trial comparing open reduction and internal fixation with minimally invasive reduction and percutaneous fixation in managing displaced intra-articular calcaneal fractures. *Int. Orthop.* 2014; 38(12):2505-2512.
7. Goldzak M, Gradl G, Simon P, Mittlmeier T. A new approach for calcaneal fractures: a preliminary step for calcaneal nailing. *Injury – Int. J care injured.* 2011; 42:55.
8. 8 - Goldzak M, Gradl G, Simon P, Mittlmeier T. Calcanail a new internal device for calcaneal fractures. *Injury Int. J care injured.* 2011; 42:55.
9. Goldzak M, Mittlmeier T, Simon P. Locked nailing for the treatment of displaced articular fractures of the calcaneus: description of a new procedure with calcanail. *Eur J Orthop Surg Traumatol.* 2012; 22:345-349.
10. Goldzak M, Simon P, Mittlmeier T, Chaussemier M, Chiergatti R. Primary stability of an intramedullary calcaneal nail and an angular stable calcaneal plate in a biomechanical testing model of intraarticular calcaneal fracture. *Injury.* 2014; 45:49-53.
11. Reinhardt S, Martin H, Ulmar B, Döbele S, Zwipp H *et al.* Interlocking nailing versus interlocking plating in intraarticular calcaneal fractures: a biomechanical study. *Foot Ankle Int.* 2016; 37:891-897.
12. Dingemans SA, Floris W *et al.* Fixation Methods for Calcaneus Fractures: A Systematic Review of Biomechanical Studies Using Cadaver Specimens. *The Journal of Foot & Ankle Surgery.* 2018; 57:116-122.
13. Clement RC, Lang PJ, Pettett BJ, Overman RA, Ostrum RF, Tennant JN. Sanders II/III Calcaneus Fractures in Laborers: A Cost-Effectiveness Analysis and Call for Effectiveness Research. *J Orthop Trauma.* 2017; 31:299-304.
14. Falis M, Pyszel K. Treatment of displaced intra-articular calcaneal fractures by intramedullary nail. Preliminary report. *Ortop Traumatol Rehabil.* 2016; 18:141-147.
15. Knight JR, Gross EA, Bradley GH, Bay C, LoVecchio F. Bohler's angle and the critical angle of gissane are of limited use in diagnosing calcaneus fractures in the ED. *American Journal of Emergency Medicine.* 2006; 24:423-427.
16. Leung KS, Yuen KM, Chan WS. Operative treatment of displaced intra-articular fractures of the calcaneum. Medium-term results. *J Bone Joint Surg Br.* 1993; 75(2):196–201.
17. Sanders R, Fortin P, DiPasquale T, Walling A. Operative treatment in 120 displaced intraarticular calcaneal fractures. Results using a prognostic computed tomography scan classification. *Clin Orthop Relat Res.* 1993; 290:87-95.
18. Goldzak M, Colombier JA, Simon P. Ostéosynthèse miniinvasive des fractures thalamiques du calcanéum par une voie d'abord postérieure et réduction intrafocale. Brochure AFCP no 6, Journées de spécialités SOFCOT, pp Editions Sauramps, Montpellier. 2010; 344:253-260.
19. Zwipp H, Pasa L, Zilka L, Amlang M, Rammelt S, Pompach M. Introduction of a new locking nail for treatment of intraarticular calcaneal fractures. *J Orthop Trauma.* 2016; 30:88-92.
20. DeWall M, Henderson CE, McKinley TO, Phelps T, Dolan L, Marsh JL. Percutaneous Reduction and Fixation of Displaced Intra-Articular Calcaneus Fractures. *J Orthop Trauma.* 2010; 24:466-476.
21. Stulik J, Stehlik J, Rysavy M, Wozniak A. Minimally-invasive treatment of intraarticular fractures of the calcaneum. *J Bone Joint Surg [Br].* 2006; 88(12):1634-41.
22. Zhang J, Xiao B, Wu Z. Surgical treatment of calcaneal fractures with bioabsorbable screws. *Int. Orthop.* 2011; 35:529-33.
23. Simon P, Goldzak M, Eschler A *et al.* Reduction and internal fixation of displaced intra-articular calcaneal fractures with a locking nail: A prospective study of sixty nine cases. *International Orthopaedics (SICOT).* 2015; 39:2061.
24. Veltman ES, Doornberg JN, Stufkens SA *et al.* Long-term Outcomes of 1,730 Calcaneal Fractures: Systematic Review of the Literature. *The Journal of Foot & Ankle Surgery.* 2013; 52(4):486-490.