



International Journal of Orthopaedics Sciences

ISSN: 2395-1958
IJOS 2019; 5(2): 907-910
© 2019 IJOS
www.orthopaper.com
Received: 24-02-2019
Accepted: 28-03-2019

Anil Gupta MS
Prof & HOD, Government
Medical College, Jammu, Jammu
and Kashmir, India

Shafiq Hackla MS
Senior resident, Government
Medical College, Jammu, Jammu
and Kashmir, India

John Mohammad
Junior resident, Government
Medical College, Jammu, Jammu
and Kashmir, India

Naresh Rana
Junior resident, Government
Medical College, Jammu, Jammu
and Kashmir, India

Kamalji Pandit
Junior resident, Government
Medical College, Jammu, Jammu
and Kashmir, India

Shujat Ali
Junior resident, Government
Medical College, Jammu, Jammu
and Kashmir, India

Correspondence
Anil Gupta MS
Prof & HOD, Government
Medical College, Jammu, Jammu
and Kashmir, India

Management of distal femur fractures with bicolumnar fixation with condylar buttress plate and TENS nail

Anil Gupta MS, Shafiq Hackla MS, John Mohammad, Naresh Rana, Kamalji Pandit and Shujat Ali

DOI: <https://doi.org/10.22271/ortho.2019.v5.i2m.110>

Abstract

Introduction: The fracture of distal femur are often unstable and comminuted and as difficult to treat. The incidence of complications in these fracture are relatively high. We have treated the fracture of distal femur with comminuted medial wall with condylar buttress plate and support of medial wall with TENS nail.

Material and Methods: Fifty three patients with intercondylar fracture of distal femur were selected. There were thirty three males and twenty females. The average age of the patients was 36.2 years. All the patients were operated between 3 to 7 days. The final outcome was assessed according to schatzker and Lambert scoring system. The complications were also noted.

Results: The result was excellent in fifteen, good in twenty three, fair in eleven and poor in four patients according to schatzker and Lambert scoring system. The average time to Union was 14.2 weeks. Complications include superficial wound infection in five patient, knee stiffness, and varus angulation less than 5 degree in eight and five patients respectively.

Conclusion: The use of TENS nail for medial femoral defect along with condylar buttress plate may eliminate the need of plate on medial side. The varus angulation that occurs with defect is decreased and additional long incision and operative time is avoided.

Keywords: TENS nail, varus angulation, medial femoral defect

1. Introduction

The fractures of distal femur are usually the result of high energy trauma. They are often very severe and difficult to treat. The incidence of these fractures is 0.4% of all fracture and 3% of femoral fracture. There is bimodal distribution with highest in woman older than 75 years and adolescent boys and men 15 to 24 years old. Because of proximity of these fractures to knee joint, regaining full knee motion and function may be challenging.

The treatment of distal femur fractures have evolved from non-operative to operative to fixation of both lateral and medial columns of femur ^[1]. The goal of these techniques is to restore anatomical reduction of the joint, stable fixation and to prevent varus or valgus angulation. The high incidence of complications with both column fixations with plates discouraged its use ^[2]. The purpose of our study to evaluate the efficacy of both column fixations by using condylar buttress plate on lateral side and then using TENS nail on medial side to obtain support of medial column and prevent varus angulation.

2. Methods and Materials

A prospective study was conducted in GMCH, Jammu from June 2012 to July 2015. Fifty three patients with comminuted intercondylar fracture of femur were operated. There were thirty seven males and sixteen females. The average age of the patients was 36.22 years the oldest being 56 years old and youngest being 23 years. The forty patients were having road traffic accident and twelve patients were having fall from height. One patient was having implant failure after fall. All the patients were operated within a week after they were hemodynamically stable. The detailed preoperative planning and evaluation was done. Fig 1.

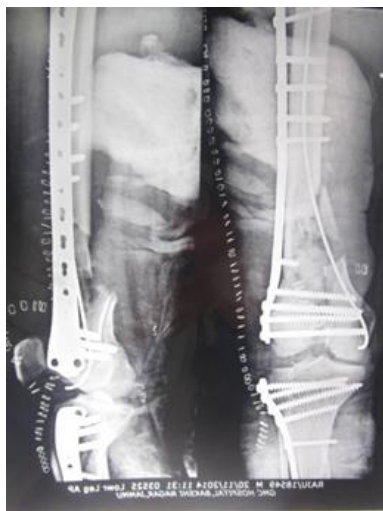


Fig 1: Shows immediate postop radiograph condylar buttress plate on lateral side and TENS nail on medial side 2(A) Approach

The swashbuckler approach was used [3]. The patient was placed supine on radiolucent fracture table. An incision was made in the midline of thigh from above the fracture laterally to across the patella. The vastus lateralis muscle was retracted medially after lateral para-patellar arthrotomy was made. Condylar fragments were reduced, stabilised and then minimally fixed with condylar buttress plate on lateral side (two screws distally and only one screw proximally). The amount of varus angulation was also corrected during the procedure.

By using C- arm guidance, a two cm incision made over medial aspect of distal femur. Entry portal was made with the help of curved awl. An appropriate size TENS nail was then fixed from medial side into the medullary canal of the femur. The final position was then checked under C-arm guidance and remaining screws were put to fix the lateral plate. The wound was then closed in layers and antiseptic dressing was applied Fig 2.

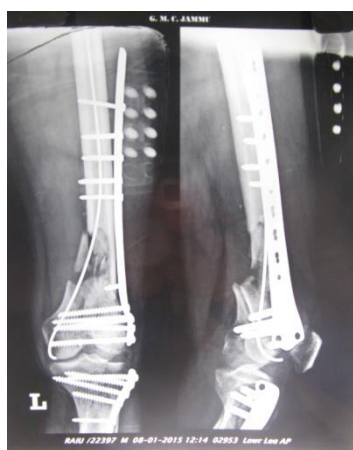

Fig 2: Shows radiographs at 6 weeks follow up with fracture callus and consolidation

2(B) Rehabilitation Protocol

The POP back slab was applied for initial 3 to 4 days. Drains were removed on first dressing. On 4th post-operative day, range of motion and quadriceps strengthening exercises were started. The patient was allowed to walk with a pair of crutches and bear partial weight bearing till they achieved good quadriceps power and radiological examination revealed fracture union fig 3,4.

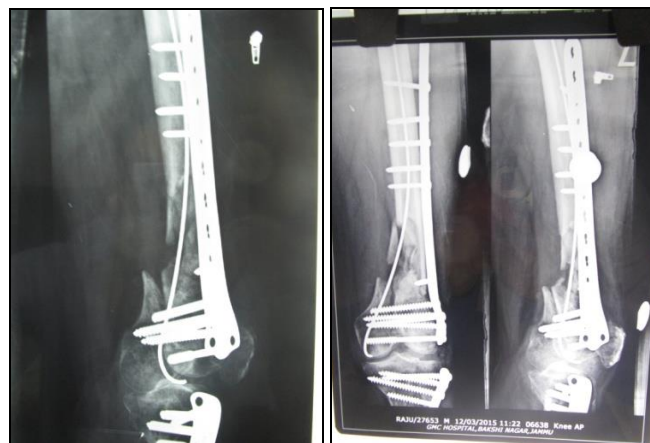


Fig 3, 4: Shows radiograph at 3 months follow up, consolidation of fracture surfaces and slight loss of reduction with posterior angulation

The final outcome was assessed using schatzker and Lambert scoring system which is excellent if full extension, no varus or valgus deformity, no pain and perfect joint congruity is present. Good result includes not more than one of following like loss of length not more than 1.2 cm, less than 10° varus or valgus deformity, flexion loss more than 20° and minimal pain and failure when flexion to 90° or less, varus or valgus more than 15°, joint incongruity and disabling pain [4]. The following were noted at six month follow up. Clinical union, range of motions at knee joint, power, and mobility of quadriceps, walking distance, radiological union, any limb length discrepancy, total time for union and complications fig 5. The average operative time, amount of blood loss and infection rate was also noted.

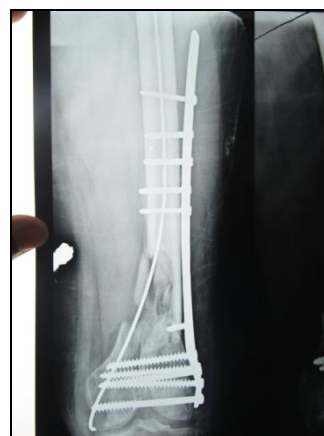


Fig 5: Shows good healing response at 6 month follow up.

3. Result

The average operative time was 92 mins and average union time was 14.2 weeks. The number of patients according to AO/OTA classification was thirty seven in type C and sixteen in type B. Fracture was considered united when patient was full weight bearing, had no or minimal pain and on radiograph at least three cortices were united.(Table.1)

Table 1: Shows average union time

Time taken	No. of cases	Percentage (%)
10 weeks or less	0	0
11-14 weeks	36	68
15-20 weeks	15	28
More than 20 weeks	2	4
Total	53	100

Complications include superficial wound infection in five patients, minimal pain in ten patients, varus angulation less than 5 degree in seven patients. The range of motion greater than 90 degree was present in thirty six patients while seventeen patients were having ROM less than 90 degree. (table.2).

Table 2: Shows the range of movement of knee joint

Range of movement(°)	No. of patients
0-30	3
31-60	4
61-90	10
91-120	15
121-140	21
Total	53

The final outcome was evaluated using schatzker and Lambert scoring system which was excellent in fifteen patients, good in twenty three, fair in eleven and poor in four patients.(table.3).

Table 3: Shows result according to schatzkar and Lambert scoring system

Results	No. of cases	Percentage (%)
Excellent	15	29
Good	23	43
Fair	11	21
Poor	4	7
Total	53	100

4. Discussion

Current fracture patterns veer towards complex comminuted type due to prevalence of high energy trauma. The violent nature of injury in young individuals who sustain high velocity during road traffic accident and osteoporotic bones in elderly patients make single column fixation unsatisfactory option^[5]. The goal of treatment is to achieve bone healing and restore function of the affected limb in shortest possible time without compromising stability^[6].

The distal femoral fractures has been classified by Muller (AO) into extra-articular, partial articular and intra-articular types^[10, 11]. We have based our study on intraarticular type C fractures which are generally associated with severe comminution and bony loss. The mode of trauma in distal femoral fractures is usually severe varus, valgus or rotational force with axial loading sustained in young as result of high energy trauma as in road traffic accident and in elderly as result of minor slip or fall on flexed knee. In intercondylar fractures, there will be rotational malalignment because of separate attachments of gastrocnemius muscle to each condyle.

Complications of distal femoral fractures include malunion, nonunion, varus angulation, limb length discrepancy, infections and secondary osteoarthritis of patellofemoral and tibiofemoral joints. The principle of treatment in these fracture include restoration of bony continuity, maintenance of good reduction, articular congruity, and good range of movements^[7]. These fractures earlier treated nonsurgically were associated with angular deformity, joint incongruity, knee stiffness and delayed patient mobilisation. The different fixation devices used include angle blade plate (schatzker 1979), rush rods (Shelbourne1981), enders nail (Kolmert 1986) and zickel device. However, these devices were technically demanding and didn't achieve rigid fixation of articular surface^[8, 13]. Dual plating used in comminuted

fractures often result in extensive soft tissue stripping on both sides of femur resulting in reduced blood supply, delayed or nonunion and failure of implant. Callus formation was inconsistent and irregular with these plates^[9, 12].

The average union time was 13.8 weeks in Markmiller *et al.* study while it is 14.2 weeks in our study^[15]. No evidence of disability was noted in our study which is comparable to the study of Schultz *et al.*^[16]. The advantages of fixation includes active range of motions can be started earlier, maximum range of motion is preserved, stable internal fixation does not allow malunion to occur, maintenance of articular congruity and incidence of implant failure and hospital stay is reduced^[17].

5. Acknowledgement: None

6. Conflict of interest: None

7. References

1. Foster MC, Komarsamy B, Davison JN. Distal femoral fractures: A review of fixation methods. *Injury*. 2006; 37:97-108.
2. Johnstone A, Carnegie C, Christie, McCollaugh J. The challenges associated with treating distal femoral fractures with distal femoral locking plate in elderly: Different pattern of failure in different locking plates. *J bone J surg (Br)*. 2010; 92(4):550.
3. Frankhauser F, Gruber G, Schippinger G, Christian B, Hofer HP, Grechening W *et al.* Minimally invasive treatment of distal femoral fractures using LISS. A prospective study of 30 patients with follow up upto 20 months. *Acta Orthop Scand*. 2004; 75(1):56-60.
4. Malik I, Khan R, Khurana R, Sharma S. Comparative study of management of distal femur fractures managed by dynamic condylar screw and distal femoral locking plate. *Orthopaedics*. 2015; 6(9):WMC004976.
5. Wahner KL, Hoffmeier KL, Vonoldenberg G. Internal fixation of type C distal femoral fractures in osteoporotic bones. *JBJS (Am)*. 2011;93:40-54
6. Ezekiel TSL, Balogh ZJ. Indications and limitations of locking plate. *Injury*. 2009; 40(7):683-693.
7. Syed AA. Distal femoral fractures: long term outcome following stabilization with LISS. *Injury*. 2004; 35(6):599-607.
8. Wahnert D, Hoffmeyer KL, Frober R, Hoffman GO, Muckley T. Distal femur fractures of the elderly-different treatment options in a biomechanical comparison. *Injury* 2011; 42:655-59.
9. Lujan M, Trevor J, Henderson W. Locked plate for distal femur fractures leads to inconsistent and irregular callus formation. *J Orthop Trauma*, 2010; 24(3):156-162.
10. Jahangir AA, Cross WW, Schmidt AH. Current management of distal femoral fractures. *Current orthopaedic practice*. 2010; 21:193-97.
11. Gwathmey FW Jr, Jones-Quaidoo SM, Kahler D, Hurwitz S, Cui Q. Distal femoral fractures: current concepts. *J Am Acad Orthop Surg*. 2010; 18:597-607.
12. Henderson CE, Kuhl LL, Fitzpatrick DC, Marsh JL. Locking plates for distal femur fractures: Is there a problem with fracture healing? *J Orthop Trauma*. 2011; 25:S8-S14.
13. Beingessner D, Moon E, Barei D, Morshed S. Biomechanical analysis of the less invasive stabilization system for mechanically unstable fractures of the distal femur: comparison of titanium versus stainless steel and bicortical versus unicortical fixation. *J Trauma*. 2011;

71(3):620-4.

14. Hoffman MF, Jones CB, Sietsema DL, Koeing SJ. Clinical outcome of locked plating of distal femoral fractures in a retrospective cohort. *Journal of orthopaedic surgery and research*. 2013; 8:43.
15. Markmiller M, konard G, Sudkamp N. Femur- LISS and distal femoral nail for fixation of distal femoral fractures. *Clin Orthop*. 2004; 426:252-7.
16. Schutz M, Muller M, Regazzoni P. Use of less invasive stabilization system in patients with distal femoral fractures: A prospective multicentric study. *Acta Orthop Trauma*. 2005; 125(2):102-8.
17. Smith TO. The clinical and radiological outcomes of the LISS plate for distal femoral fractures: A systemic review. *Injury Int. Care Injured*, 2009.