



International Journal of Orthopaedics Sciences

ISSN: 2395-1958
IJOS 2019; 5(2): 661-669
© 2019 IJOS
www.orthopaper.com
Received: 19-02-2019
Accepted: 22-03-2019

Dr. Balathithyan R
Dept. of Orthopaedics,
Sree Balaji Medical College and
Hospital, BIHER
No.7, CLC Works Road,
Chromepet, Chennai,
Tamil Nadu, India

Dr. Venkatachalam K
Dept. of Orthopaedics,
Sree Balaji Medical College and
Hospital, BIHER
No.7, CLC Works Road,
Chromepet, Chennai,
Tamil Nadu, India

Correspondence
Dr. Venkatachalam K
Dept. of Orthopaedics,
Sree Balaji Medical College and
Hospital, BIHER
No.7, CLC Works Road,
Chromepet, Chennai,
Tamil Nadu, India

Analysis of outcome of proximal femoral nailing in unstable trochanteric fractures: A prospective study

Dr. Balathithyan R, Dr. Venkatachalam K

DOI: <https://doi.org/10.22271/ortho.2019.v5.i2i.69>

Abstract

Inter-trochanteric fractures are the common fractures of hip which occurs in young adults as a result of high velocity injury and in osteoporotic elderly due to low velocity injury. Inter-trochanteric fractures are treated by various surgical modalities. Proximal femoral nailing is now been used widely for the treatment of unstable inter-trochanteric fractures. The clinical and radiological outcomes are good with low rates of complications. We prospectively studied 36 unstable inter-trochanteric fractures treated with proximal femoral nailing. The overall functional result was assessed by the Harris Hip Score which was Excellent in 13.34%, Good in 41.67%, Fair in 19.44% and Poor only in 5.55%

Keywords: Unstable inter-trochanteric fractures, proximal femoral nailing, Harris Hip Score

1. Introduction

Inter-trochanteric fractures are one of the most common fractures of the hip occurring both in the young adults, as a result of high energy trauma and in the elderly, as a result of low energy trauma due to osteoporosis [1]. These fractures are 3 to 4 times more common in the elderly women whose bones are osteoporotic and in whom trivial trauma is by far the most common mode of injury [2, 3]. One-half of these fractures that occur in the aged around the hip joint are of the trochanteric type and one-half of these are of the unstable variant.

In treating trochanteric fractures, it is important to distinguish between the unstable and stable variants of these fractures. Thus, by definition a truly stable inter-trochanteric fracture, is a one that when reduced has a cortical contact without gap posteriorly and medially. This contact is vital in preventing fracture displacement into Varus or Retro-version. Thus, it is important to understand that unstable fractures cannot be treated on the same lines as stable ones, because when there is inadequate fracture opposition, the fixation will collapse affecting the abductor lever arm and eventually leads to abductor weakness.

The goal of the treatment in inter-trochanteric fractures is the restoration of the patient to his or her pre-injury functional and ambulatory status at the earliest.

Dynamic hip screw is an eccentric load sharing device and a time-tested surgical procedure to manage these fractures but is associated with open reduction, loss of fracture hematoma, periosteal stripping and extensive soft tissue dissection [4].

The factors most significant for instability and fixation failure are: (i) loss of postero-medial support, (ii) severe comminution, (iii) sub-trochanteric extension of the fracture, (iv) reverse oblique fracture, (v) shattered lateral wall, (vi) extension into femoral neck area and (vii) poor bone quality [5-7].

Osteoporosis is particularly important in the fixation of proximal femoral fractures. This can be measured by Singh's index [Fig 1] and bone densitometry (DEXA).

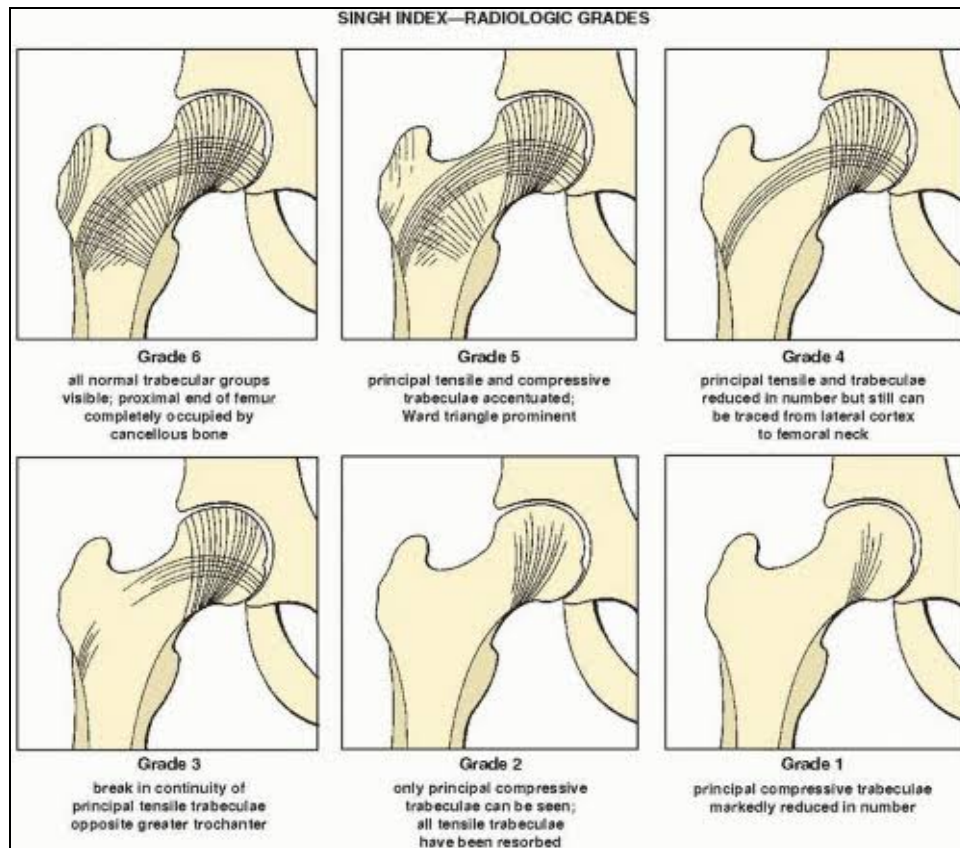


Fig 1: Gradation using Singh’s index. Normal being grade 6.

Closed intramedullary proximal femoral nail (PFN) overcomes the short-comings associated with DHS. Its biomechanical properties like being an axial load bearing device, with a short lever arm [Fig 2], greater implant length, smaller and flexible distal ends and an additional de-rotational screw in femoral neck offers significant advantages over the DHS [8]. It also has the benefits of being a shorter procedure, lesser blood loss, an undisturbed fracture hematoma and early patient mobilization.

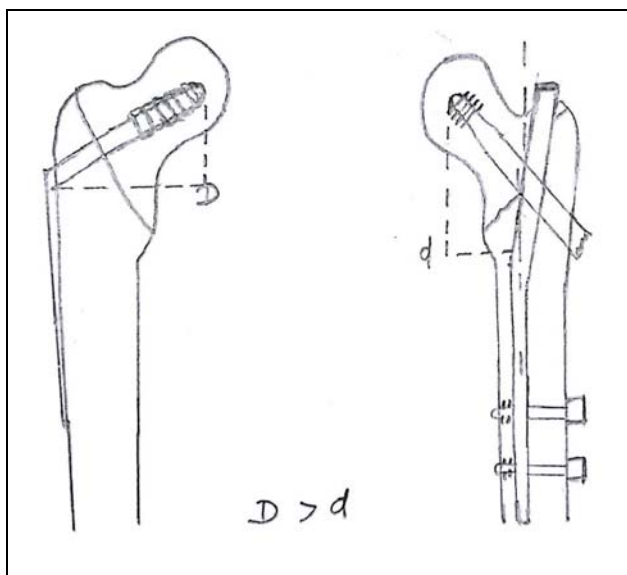


Fig 2: Showing decreased lever arm of intramedullary nail Vis a Vis the DHS. Implant of choice in lateral wall or posteromedial wall comprised trochanteric fractures.

The objective of any surgical intervention of a trochanteric femoral fracture should be to achieve a stable osteosynthesis providing for early full weight-bearing. It is important to understand that, the proximal femoral nailing enshrines the “AO principles” in letter and spirit.

Inter-trochanteric fractures, with evermore distal fracture course and inter-trochanteric comminution zone, rotational instability and pivot transfer of the fracture area to lateral and caudal areas are accompanied by an increase of the dislocating forces. These kinds of fractures (A2 and A3 according to the AO/ASIF classification) are the ones that best profit from an intra-medullary and rotationally stable osteosynthesis.

2. AIM & Objectives

This prospective study was done to evaluate and analyze the clinical, radiological and functional outcome of proximal femoral nailing done for unstable trochanteric fractures (AO-OTA: A2 and A3 variants)

3. Materials and Methods

The present study has been a prospective study, involving patients who had sustained unstable inter-trochanteric fractures. The study began in March 2017 and went on till February 2018 (a total recruitment period of 12 months). The study concluded in October 2018, so that there was a minimum follow-up of 8 months (mean 14.2; range 8 to 20 months).

Inclusion Criteria

- Both male and female patients, in the age group of 56 to 75 years were included in the study.
- Only unstable trochanteric fractures were included (AO-

OTA 2.2, 2.3, 3.1, 3.2 and 3.3).

- Only fractures seen within 10 days of injury were included.

Exclusion Criteria

- Patients with displaced trochanteric fracture not conforming to the above parameters were excluded.
- Open and pathological fractures were excluded.
- Inability to walk independently, prior to fracture due to pre-existing stroke or CVA were excluded.

PRE – Operative Protocol

Awaiting surgery, all patients were put on skin traction. All the routine investigations were done. Pre-operative anesthetic and physician fitness obtained and pre-operative parenteral antibiotics were administered at the time of induction of anesthesia

Surgical Technique

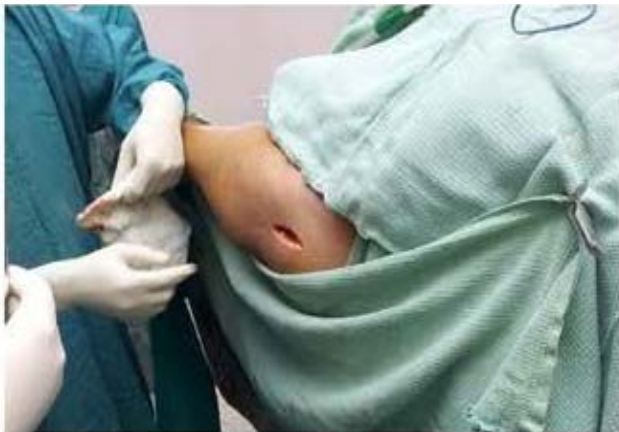

Fig 3a: Incision

Positioning

The patient is positioned supine on the traction table. Reduction was achieved by traction (dis-engaging the fracture fragments) and internally rotating the limb while maintaining traction and confirming with the image-intensifier view.

Approach

A 3 cm incision is made proximal to the tip of greater trochanter. Skin with subcutaneous tissue and deep fascia are incised. Gluteus maximus was split by blunt dissection. The tip of trochanter is then felt with finger

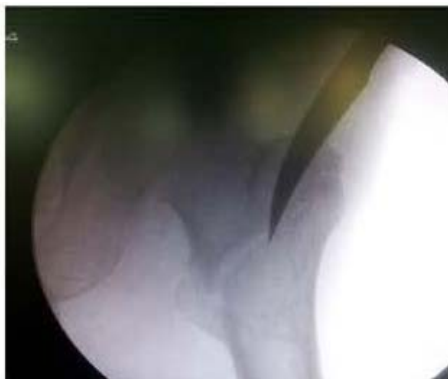

Fig 3b: Entry point with bone awl – AP C-arm view.

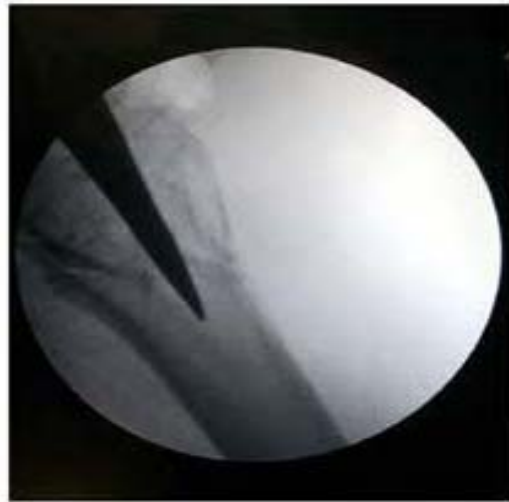

Fig 3c: Entry point with bone Lateral – C-arm view.

Entry Point

Reduction of the fracture was essential before making the entry point. After confirming the anatomical reduction, entry point is made with a bone awl over the tip of greater trochanter. After confirming the position in AP and lateral views, the awl was driven just proximal to the level of lesser trochanter.

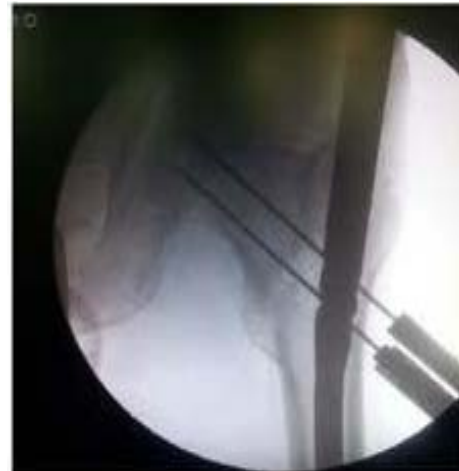

Fig 3d: Guide pin- AP- C-arm view



Fig 3e: Guide pin – lateral – C-arm view

Guide Wire Insertion and Reaming

A 3.2mm guide wire was inserted and driven into the distal fragment. Proximal reaming was done with a 15 mm cannulated reamer.

Nail Insertion

The nail that was in close match to the neck shaft angle of the un-affected hip is assembled in the zig. The PFN is slowly inserted upto the appropriate depth in order to allow placement of two screws within the femoral neck.

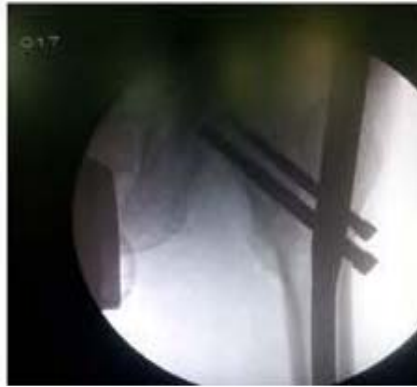

Fig 3f: Proximal targeting.

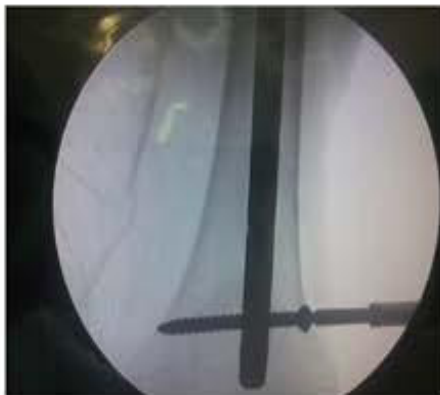

Fig 3g: Distal targeting.

Proximal Targeting

Under C- arm vision, the guide pins for the lag screw and de-rotation screw were driven in through the guide pin sleeves for upto 5 mm from the articular surface of the femoral head. The lag screw and de-rotation screw of appropriate length were then inserted. The de-rotation screw were chosen to be 10 to 15mm smaller than the lag screw in order to avoid the ‘Z’ effect. It was ideal to insert the lag screw along the inferior aspect of the neck, particularly if there had been a medial comminution.

Distal Targeting

Distal targeting was done with distal targeting guide and drill sleeves using 4.0mm drill bit. In case of using a long nail, the distal locking was done through a free hand technique, under C-arm guidance.

Post-Operative Protocol

- Parenteral third generation cephalosporin and aminoglycosides were given for 72 hours. Oral antibiotics till POD 5.

- Non-weight bearing walking was started from POD 3.
- Suture removal was done on POD 12.
- Rehabilitation: Partial weight bearing (toe-touch) was started POD 14 to 28. Full weight bearing was allowed after radiological and clinical signs of union (12-18 weeks).

Follow-UP

- Patients were evaluated clinically and radiologically for signs of radiological and clinical union appear.
- Clinical union was assessed as being absence of pain and tenderness upon full weight-bearing.

Clinical Assessment Included The Following Parameters:

1. Gait,
2. Pain,
3. Deformity,
4. Shortening,
5. Range of movements,
6. Ability to sit cross-legged,
7. Ability to squat,
8. Be able to return to pre-injury occupational status.

Radiological Assessment Included:

1. Signs of union,
2. Varus collapse,
3. Amount of lateral slide,
4. Screw cut-out,
5. ‘Z’ effect,
6. Implant failure and loss of fixation

Functional Evaluation:

The patients were evaluated with Modified Harris Hip Score at the end of 8 months. Patients were then categorized according to the scores they attained as follows:

4. Observaton And Results

Table 1: Age Distribution

AGE GROUP (In Years)	No. of Patients ‘n’	%age
56 – 60	7	19.4%
61 – 65	6	16.6%
66 – 70	9	25%
71 - 75	14	39%
Total	36	100

Table 2: Sex Distribution

AGE GROUP	No. of Patients ‘n’/sex	%age
56-60	2M/5F	5.55%M / 13.88%F
61-65	3M/4F	8.33%M / 11.11%F
66-70	1M/7F	2.79%M / 19.46%F
71-75	3M/11F	8.33%M / 30.55%F
Total	9M/27F	25%M / 75%F

Table 3: Mode Of Injury:

Mode Of Injury	No. of Patients ‘n’	M+F sample total ‘n’	%age
Accidental fall from standing height	6M/23F	29	80.5
Road traffic accident	3M/4F	7	19.5
Total	9M/27F	36	100

Table 4: Fracture Pattern Distribution

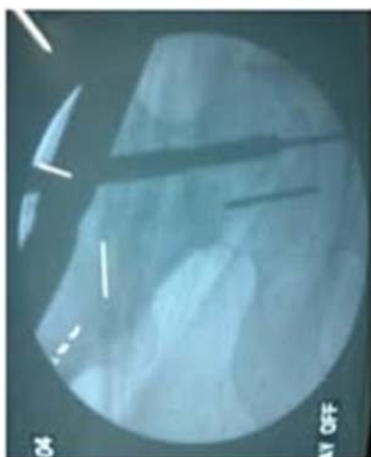Ao Classification	No. of Patients ‘n’/sex	Sample total	%age
Type A2.2	0M/1F	1	2.8%
Type A2.3	3M/15F	18	50%
Type A3.1	4M/7F	11	30.5%
Type A3.2	1M/1F	2	5.6%
Type A3.3	1M/3F	4	11.1%
Total	9M/27F	36	100

Table 5: Post-Operative Complications

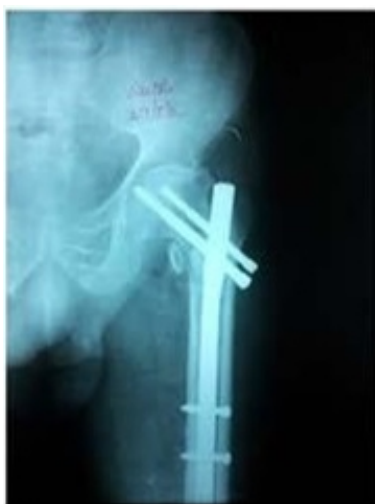S. No.	Nature of complication.	No of Patients 'n'	%age
1.	Shortening	1	2.7
2.	Superficial infection	1	2.7
3.	Deep infection	1	2.7
4.	Varus collapse	1	2.7
5.	Lateral slide of proximal screws	1	2.7
6.	Non-union	0	0.00
7.	'Z' effect	1	2.7
8.	Implant failure	1	2.7
9.	Mortality	0	0.00
	Total	7	19.44

Table 6: Harris Hip Score⁴⁰:

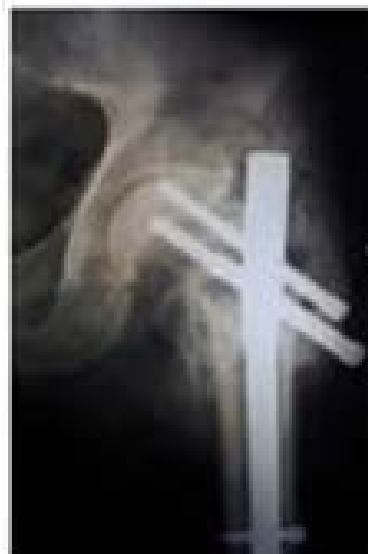Functional Outcome	At the end of 8 months	
	No. of Patients 'n'	%age
Excellent	12	33.34
Good	15	41.68
Fair	7	19.44
Poor	2	5.55
Total	36	100



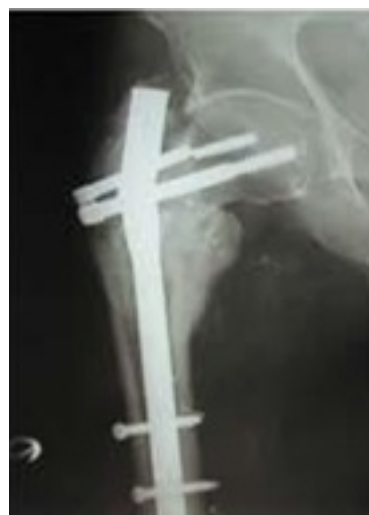4a. Intra-operative drill bit breakage.



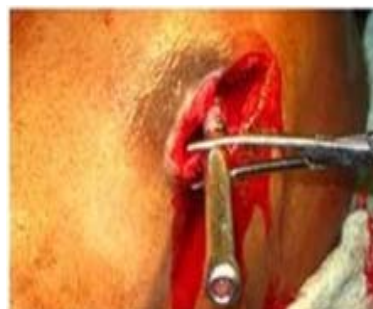4b. Reverse 'z' effect.



4c. Infection with 'Z' effect.



4d. Implant failure with malunion.



4e. Lateral glide of the lag screw.

Fig 4: Intra-operative complications

As per our inclusion criteria, 36 patients were recruited for surgical fixation of unstable trochanteric fractures. Of these 36 patients, 39% (n=14) were in the age group 71-75 years, 25% (n=9) were in the age group of 66-70 years, 19.4% (n=7) were in the age group 56-60 years and the least 16.6% (n=6) were in the age group 61-65 years. In all 75% (n=27) were females and 25% (n=9) were males. Thus there was a female preponderance in our study, making the M:F ratio as 1:3

Approximately 80.5% (n=29) patient had suffered the injury by an accidental fall from standing height and 19.5% (n=7) were victims of RTA. The average time interval between sustaining the injury and being taken up for surgery was 2.03 days (range 1 to 5 days). Among all the fracture patterns treated, AO-OTA trochanteric fracture type A 2.3 was most common at 50% (n=18) and a close second was type A 3.1 which was seen in 30.5% (n=11) patients. With regards to the type of implant used, PFN of 135 degree was used in 47.2% (n=17) patients, 33.3% (n=12) had a long PFN of 135 degrees and 19.5% (n=7) had a short PFN implant of 130 degrees. The average intra-operative time was 63.16 minutes (range: 50 to 77 minutes)

Intra-operatively, we encountered difficulty to engage the de-rotation screw in 2 cases, in 1 case we had fracture displacement upon nail insertion, in 1 case we failed to get anatomical reduction, in 1 case we had breakage of the guide wire and in one case we had a Varus angulation. Post-operatively we had 1 case each of shortening, superficial infection, deep-infection, Varus collapse, Z effect, lateral side of proximal screw and implant failure. In all the rate of intra-operative complication was 16.66% (n=6) and that of post-operative complications was 19.44% (n=7).

The overall functional result as assessed by the HARRIS HIP SCORE was Excellent in 13.34% (n=12), Good in 41.68% (n=15), Fair in 19.44% (n=7) and Poor in 5.55% (n=2)

5. Discussion

The successful treatment of inter-trochanteric fractures depends on many factors⁹; the age of the patient, the patient's general health, the time elapsed from trauma to treatment, concurrent medical treatment and the stability of fixation^[10]. The appropriate method and the ideal implant used for these fractures are still debated with proponents of the various approaches and each claiming their advantages over others. Many internal fixation devices have been recommended for the treatment of these fractures, including extra-medullary and intra-medullary implants.

The dynamic hip screw has remained the implant of choice for over four decades because of its favorable results and a relatively low rate of non-union and failure. It provides for controlled compression at the fracture site. The use of DHS had been supported by their bio-mechanical properties which had been presumed to improve the healing of fractures¹¹. However, the DHS requires a relatively larger exposure, more tissue handling and near anatomical reduction, all of which increases the morbidity, the probability of an infection and a significant blood loss. The possibility of varus collapse and the inability of the implant to survive until fracture union were its main short-comings. The side-plate and screws weaken the bone mechanically. The common causes of this fixation failure were unstable trochanteric fractures, osteoporosis, a lack of anatomical reduction, failure of the fixation device and incorrect placement of the lag screw in the femoral head^[12, 13].

Control of axial telescoping and rotational stability are essential in unstable proximal femoral fractures. An intra-medullary implant inserted in a minimally invasive manner is always better tolerated in the elderly patients^[14]. The cephalo-medullary nails with a trochanteric entry point have recently gained in popularity^[15]. They have been shown to be bio-mechanically much stronger than extra-medullary implants^[16]. The Gamma nail were associated with specific complications, among which was a constant anterior thigh pain and the fear of fracture of the femoral shaft^[17].

The PFN system, developed by AO/ASIF, has some major bio-mechanical innovations to overcome the previously mentioned limitations of the Gamma nail^[18]

Addition of the 6.5 mm anti-rotation hip screw has helped to reduce the incidence of implant cut-out and the rotation of the cervico- cephalic fragment. The PFN nail has been shown to prevent the fractures of the femoral shaft by having a smaller distal shaft diameter which reduces stress concentration at the tip^[19]. As a result, the fracture heals even without the primary restoration of the medial support. The implant temporarily compensates for the function of the medial column^[20].

In A3 fractures impaction does not occur, and medial displacement of the distal fragment of the fracture is bound to occur due to the instability factor. Due to its position close to the weight-bearing axis the stresses that are generated on the intra-medullary implants are negligible. The PFN implant also acts as a buttress in preventing the medialization of the shaft²¹. Bio-mechanically, compared to a laterally fixed side plate, the Intra-medullary nail decreases the bending force on the hip joint by 25 to 30%^[22]. This has the advantage in the elderly age group in-order to make them weight bear earlier. The entry portal of the PFN through the trochanter limits the surgical insult to the tendinous hip abductor musculature only, unlike those nails which require entry through the pyriformis fossa. Compared to Gamma nail, the additional anti- rotation screw placed in the femoral neck avoids rotation of the cervico-cephalic fragments during weight bearing^[15, 23, 24].

In our study of 36 patients with unstable intertrochanteric fracture, the average age incidence was 67.17 years. This is in tandem with the age group as reported in the various literatures. Our study results are comparable with those of Boyd and Griffin, and that of Richard Kyle;^[25] and of that reported by G.S. Kulkarni *et al*;^[9]. Majority of cases occurred in older individuals as the average life expectancy of an Indian is 10 years less than western standards and malnutrition and osteoporosis go hand in hand.

Table 7: Average age of the sample studied

Authors	Average age
K Karl Lunsjo <i>et al</i> ; ^[36]	81.0
B Boyd and Griffin ^[39]	69.7
R R. C. Gupta ^[37]	51.2
R Richard Kyle ^[25]	72
Mohanty S. P. ^[38]	61.7
G.S. Kulkarni ^[9]	62
Our study	67.17

In the present study, the male to female ratio was 1 : 3, hence indicating a female preponderance in our study. This is in tandem with those reported by Pajarinen J *et al*;^[1] and Dousa P *et al*.^[18] The mechanism of injury was accidental fall in 80.5% patients and 19.5% was due to road traffic accident. None of the patient had any associated injuries. The mean duration between the injury and surgical procedure was 2.03 days (range – 1 to 5 days). The average operating time was estimated as 63 minutes (range 50 to 77 minutes), which is in close concordance with the study by Dousa P. *et al*.^[18]; (61 minutes) and Pavelka T *et al*.^[20]; (66 minutes). The average X-ray exposure including the time necessary for reduction of fracture was 3.4 minutes (range 1 to 8 minutes).

Table 8: PFN operating time in various studies compared

Average Operating Time (in minutes)	Dousa <i>et al</i> ¹⁸	Pavelka. T <i>et al.</i> ²⁰	Pajarinen. J <i>et al.</i> ¹¹	Our series
	6 61 min	5 66 min	5 55 min	5 63 min

Intra-operatively, in one patient we had difficulty in achieving anatomical reduction by closed means, so we achieved the reduction by open reduction.

We used short PFN 135° /130° in 24 cases and the long 135° in 12 cases. We used longer nail for unstable reverse oblique variant and for fractures with sub-trochanteric extension in order to minimize peri-prosthetic fracture arising from stress raiser effect, from the tip of the nail [25]. A mismatch between the nail curvature and femoral bow might result in the impingement of the tip of the nail over the anterior cortex. We had no cases of femoral shaft fractures. Egol KA *et al*; [25, 27] reported that the average femoral anterior radius of curvature was 120cm (+/-36cm). Radii of curvature of the intramedullary nails ranged from 186 to 300 cm.

We had a guide pin breakage in one case, while drilling for lag screw and the guide pin could not be retrieved. Since the broken guide pin was within the femoral head, it did not interfere with the hip movements. We had encountered difficulty while drilling for the lag screw, the drill was scraping against the hole edge in the nail. This was solved by transient release of traction. The sleeve was placed in such a way that it would hitch the outer cortex before inserting the guide pin. Otherwise, there is a chance of toggling and bending of the guide pin at the sleeve bone interface.

We encountered difficulty in passing the de-rotation screw in 2 cases. In these two cases, the guide pin was going along the superior aspect of the neck. It was dealt with by replacing a 130° PFN nail instead of 135° PFN. We had encountered distraction at the fracture site in 2 cases, in these cases the fracture was reduced and temporarily stabilized with a 2 mm 'K' wire passed along the anterior cortex; so as not to interfere with the passage of the nail.

In 1 case, we had encountered Varus angulation. Retrospectively, we felt that this could have been prevented by increasing the traction while advancing the nail and removing the guide pin from the femoral head and abducting the lower limb. In our study, 6 of our patients had an abductor lurch which gradually decreased with time. Even though the entry point for PFN is only 15 mm, it still does have a chance of causing some abductor compromise. The Varus collapse and shortening also contributes to the abductor lurch.

In a study by Hardy *et al.* [28], he noted that increased stress at the tip of the nail may lead to cortical hypertrophy with a high incidence of anterior thigh pain and fracture around the distal locking screws. He stated that use of two static locking screws is correlated with a high rate of cortical hypertrophy, and suggested the use of a dynamic locked nail to significantly reduce this complication.

We had shortening of in one case of about 2.4 cm. In PFN, the amount of shortening is comparatively less, as there is controlled fracture impaction [21, 29, 30] (fracture can settle only until the proximal fragment abuts against the nail). The shortening was managed with a heel and sole raise in this case.

All of our patients could partially weight bear by the end of 2 weeks. None of the patients used any walking aid beyond 4 weeks. Pajarinen *et al.* [21], reiterated the ability to early weight bear with PFN.

In our series, one patients had a Varus collapse with an average of 10°. This was attributed probably to the excessive

sliding and collapse, secondary to fracture comminution and premature weight bearing. There was lateral slide of lag screw in 1 case. Lateral slide occurs more often in PFN than Gamma nail. Screw cut-out as seen in gamma nail is rare in PFN. Herrera *et al.*, [29] in a comparative study of 250 per-trochanteric fractures treated with the simple GN or the PFN system (125 fractures in each group) reported a statistically significant difference in the incidence of neck screw cut-out (4%) and fracture below the nail (3.2%) in the GN group, whereas in the PFN group there was a higher incidence of secondary Varus (7.2%) and collapse at the fracture site due to screw migration (8%).

There was one case with failure of de-rotation screw at the junction of threaded portion and the screw shaft. The patient had associated nail breakage with fracture in varus malunion from premature weight bearing. Even-though the patient had implant failure with malunion, the patient however had a good functional outcome. Domingo *et al*; prospectively evaluated 295 patients in whom the majority (59%) had a 31 A 2 intertrochanteric fracture and reported technical complications in 12% of the patients during the operation, 27% in the immediate postoperative period and late complications in 4%. Banan *et al*; [31] reported a higher technical failure rate (8.7%) due to cut-out, 1 case of implant failure and 2 cases of fracture below the tip of the nail after a second fall, out of 60 patients with exclusively unstable trochanteric fractures.

One case had deep infection with secondary 'Z' effect [23, 32]. Initially we had done a wound debridement and put the patient on parenteral antibiotics according to the culture sensitivity. The infection eventually settled and the inward migrated de-rotation screw was later removed. The lag screw was tightened. Patient was put on non-weight bearing. Werner *et al.*, [22] was the first that introduced the term Z-effect, detected in 5 (7.1%) of 70 cases. The incidence of cut-out of the neck screw in this study was 8.6%. The reverse Z-effect described by Boldin *et al*; occurred with movement of the hip pin towards the lateral side. The mechanism is similar, but here the hip pin is sliding back, whereas the neck screw remains impacted to the hole of the nail. The de-rotation screw must be 10 – 15 mm less than the lag screw. The tip of both screws and the proximal end of the nail must be in the same line. The lag screw should have purchase along the inferior cortex of the neck to minimize 'Z' effect.

The average time for fracture union in our study was 16.4 weeks (range: 12–28 weeks). In a meta-analysis, Kaplan *et al*; [33] presented a mean time taken to achieve consolidation of four months, independent of the device used. On the other hand, Bridle *et al*; [34] reported that consolidation occurred after an average of six months. According to Crawford *et al*; [35] the consolidation rate found among patients treated with a cephalo-medullary nail was 89%. In the present study, consolidation was observed in all the patients after 5 months. Patients were followed up for an average period of 12.58 months and the results were analyzed by using the Harris hip scoring system at the end of 8 months post-surgery. Among these patients, union occurred in all patients with no case of non-union. Malunion occurred in one case with implant failure. The mean Harris hip score was 88 at 8 months

The score was excellent in 12 patients, good in 15 patients, fair in 7 patients and poor in 2 patients. The results are

comparable to other international studies done in the same method.

Schipper *et al*; [30] found a mean score of 66.80 (standard deviation = 17.94) with a proximal femoral nail of PFN type after one year. According to Pajarinen *et al*; [11] patients who underwent osteosynthesis with a cephalo-medullary nail, in unstable trochanteric fractures, presented a significantly faster return to their previous level of walking. Herrera *et al*; [29] reported on a study involving 250 patients treated with the PFN and Gamma nail cephalo-medullary nails, in which around 50% of the patients had recovered their previous walking capacity, one year after the surgery. In the present study, we assessed the recovery of walking ability over the course of time. The greatest evolution in the quality of walking occurred over the first three months after the operation, such that all of our patients were walking without the help of any walking aid by 4 weeks post surgery.

In short, the PFN has distinct advantages over DHS and it has proved indeed to be a better implant with adequate surgical technique. The requirement and follow-up based changes in design of PFN from the pioneer Gamma nail will certainly decrease the complication rates and increase all the postulated advantages of Intra-medullary devices used in the treatment of trochanteric fractures.

6. Conclusion

With the demographics of the world population changing, more and more elderly persons are sustaining osteoporotic fractures. Among them, displaced and unstable trochanteric fractures are in significant numbers. The development of implant designs to address these unstable fractures of the proximal femur, have got refined. This has significantly improved the surgical outcomes in managing these problematic fractures. The proximal femoral nail, which was the implant used in this study, has established its distinct superiority in the instances of surgically managing displaced and unstable trochanteric fractures. Its unique advantages are that it is amenable to closed reduction which preserves the fracture hematoma. There is less surgical insult. It enables early rehabilitation and early return to pre-injury activity status. We hereby conclude that, osteosynthesis using a PFN, used in unstable trochanteric fractures, results in a low rate of clinical complications, gives excellent stabilization, fewer mechanical complications and satisfactory functional results. It is thus an ideal implant for surgically managing unstable inter-trochanteric fractures.

7. References

1. Kaufer H. Mechanics of the Treatment of Hip Injuries. *Clin Orthop*. 1980; 146:53-61.
2. Chang WS, Zuckerman JD, Kummer FJ, Frankel VH. Biomechanical evaluation of anatomic reduction v/s medial displacement osteotomy in unstable intertrochanteric fractures. *Clin Orthop*. 1987; 225:141-6.
3. Zhao C, Liu DY, Guo JJ, Li LP, Zheng YF, Yang HB, *et al*. Comparison of proximal femoral nail and dynamic hip screw for treating intertrochanteric fractures. *Zhongguo Gu Shang*. 2009; 22(7):535-7.
4. Yadav S, Srivastava DC, Shukla M. Comparative evaluation of dynamic hip screw and proximal femoral nail for fracture of intertrochanteric femur. *Int J Res Orthop*. 2016; 2:286-90.
5. Kuntscher G. A new method of treatment of pertrochanteric fractures. *Proc R Soc Med*. 1970; 63:1120.
6. Grosse A, Kempf I, Lafforgue D. *Fen Chir Orthop* 1978; 64:33,
7. Russel TA. Fractures of hip and pelvis: In Crenshaw AH (Ed): *Campbell's Operative Orthopaedics* (8th ed). St Louis: CV Mosby. 1992, 895.
8. Navin Dr. Karn, Navin, Karn NK, Jain Ashish, Nepal P, Pal Singh, *et al*. A Prospective Randomized Control Trial Comparing Proximal Femoral Nail and Sliding Hip Screw in The Management of Trochanteric Fracture of The Femur. *Health Renaissance*, 2011. 9. 10.3126/hren.v9i1.4354.
9. Kulkarni GS. Treatment of Trochanteric Fractures of the Hip by Modified Richard's Compressing and Collapsing Screw"; *Indian Journal of Orthopaedics*, 1984; 18(1):30-34.
10. Dean GL, David S, Jason HN. Osteoporotic pertrochanteric fractures; management and concurrent controversies. *J Bone JtSurg (Am)* 2004; 72-B:737-752
11. Pajarinen J, Lindahl J, Michelsson O, Savolainen V, Hirvensalo E. Pertrochanteric femoral fractures treated with a dynamic hip screw or a proximal femoral nail. *J Bone Jt Surg (Br)* 1992; 74-B:352-357
12. Curtis MJ, Jinnh RH, Wilson V, Cunningham BW. Proximal femoral fractures; a biomechanical study to compare extramedullary and intramedullary fixation. *Injury*. 1994; 25:99-104.
13. Kim WY, Han CH, Park JI, Kim FJY. Failure of intertrochanteric fracture fixation with a dynamic hip screw in relation to preoperative fracture stability and osteoporosis. *Int. Orthop*. 2001 25:360-362.
14. Valverde JA, Alonso MG, Porro JG *et al*. Use of Gamma nail in treatment of fractures of the proximal femur. *Clin Orthop*. 1998; 350:56-61
15. Windoff J, Hollander DA, Hakimi M, Linhart W. Pitfalls and complications in the use of proximal femoral nail. *Langenbecks Arch Surg*. 2005; 390(1):59-65, Feb Epub 2004 Apr 15
16. Schipper IB, Bresina S, Wahl D, Linke B, Van Vugt AB., Schneider Biomechanical evaluation of the proximal femoral nail. *Clin Orthop Relat Res*. 2002; 405:277-86.
17. Rosenblum SF, Zuckerman JD, Kummer FJ, Tam BS. A biomechanical evaluation of Gamma Nail. *J Bone Jt Surg*. 1992; 74:352-357
18. Dousa P *et al*. Osteosynthesis of trochanteric fractures using PFN. *Acta Chir Orthop Traumatol Cech*. 2002; 69(1):22-30.
19. Radford PJ, Needoff M, Webb JK. A prospective randomized comparison of the dynamic hip screw and the gamma locking nail. *J Bone Jt Surg (Br)* 1993; 75-B:789-793
20. Pavelka T, Matejka J, Cervenkova H. Complications of internal fixation by a short proximal femoral nail. *Acta Chir Orthop Traumatol Cech*. 2005; 72:344-354
21. Pajarinen J, Lindahl J, Savolainen V, Michelsson O, Hirvensalo E. Femoral shaft medialisation and neck-shaft angle in unstable pertrochanteric femoral fractures. *Int Orthop*. 2004; 28:347-53.
22. Babst, Renner, Nikolaus, Bidermann. Clinical results using the trochanteric stabilization plates along with DHS for internal fixation of unstable intertrochanteric fractures; *Journal of orthopaedic trauma*, Aug 1998; 12(6):392-399
23. Werner-Tutschku W, Lajtai G, Schmiedhuber G, Lang T, Pirkel C, Orthner E. Intra-and perioperative complications in the stabilization of per-and subtrochanteric femoral

- fractures by means of PFN. *Unfallchirurg.* 2002; 105(10):881-5.
24. Review paper by Kenneth J. Koval on IMN of proximal femur (A supplement to American jr of Orthopaedics April 2007)
 25. Kyle Richard F. Fractures and Dislocations; edited by Gustilo Ramon B., Kyle Richard F. and Templeman David; Mosby, 1993; 2(23):783-854.
 26. Pajarinen J, Lindahl J, Michelsson O, Savolainen V, Hirvensalo E. Pertrochanteric femoral fractures treated with a dynamic hip screw or a proximal femoral nail. A randomised study comparing post-operative rehabilitation. *J bone Joint Surg Br.* 2005; 87(1):76-81.
 27. Egol KA, Chang EY, Cvitkovic j, Kummer FJ, Koval KJ. Mismatch of current IMN with the anterior bow of femur. *J Orthoptrauma.* 2004; 18(7):410-415.
 28. Hardy DC, Drossos K. slotted IM hip screws reduce proximal mechanical unloading. *Clin orthop Relat Res.* 2003; 406:176-184.
 29. Herrera A, Domingo LJ, Calvo A *et al*; A competitive study of trochanteric fracture treatment with the gamma nail or the proximal femoral nail *Int orthop,* 2002; 26:365.
 30. Schipper IB, Steyerberg EW, Castelein RM, van der Heijden FH, den Hoed PT, Kerver AJ *et al.* Treatment of unstable trochanteric fractures. Randomised comparison of gamma nail and the proximal femoral nail. *J Bone Joint Surg Br.* 2004; 86(1):86-94.
 31. Banan H, Al-Sabti A, Jimulia T, Hart AJ. The treatment of unstable, extracapsular hip fractures with the AO/ASIF proximal femoral nail (PFN)--our first 60 cases. *Injury.* 2002; 33(5):401-407.
 32. The "Z-Effect" Phenomenon Defined: A Laboratory Study Eric J. Strauss,1 frederick J. Kummer,1 Kenneth J. Koval,2 Kenneth A. Egol (journal of orthopaedic research. 2007 doi 10.1002/jor)
 33. Kaplan K, Miyamoto R, Levine BR, Egol KA, Zuckerman JD. Surgical management of hip fractures: an evidence-based review of the literature. II. Intertrochanteric fractures. *J Am Acad Orthop Surg.* 2008; 16(11):665-73.
 34. Bridle SH, Patel AD, Bircher M, Calvert PT. Fixation of intertrochanteric fractures of the femur. A randomized prospective comparison of the gamma nail and the dynamic hip screw. *J Bone Joint Surg Br.* 1991; 73(2):330-4.
 35. Charles H. Crawford; Arthur L. Malkani; Scot Cordray; Craig S. Roberts; William Sligar. The Trochanteric Nail versus the Sliding Hip Screw for Intertrochanteric Hip Fractures: A Review of 93 Cases. *The Journal of Trauma: Injury, Infection, and Critical Care.* 2006; 60(2):325-329.
 36. Karl Lunsjo, Leif Ceder, Karl-Goran, Thorngren, Bjorn, Skytting, Jan Tidermark, *et al.* Richard Knebel Anders Houggaard anf Leif Stiggson "Extramedullary fixation of 569 Unstable Intertrochanteric Fractures, A Randomised Multicenter Trial of the Medoff Sliding plate Versus Three Other screw plate systems"; *Acta Orthop Scanda,* 2001; 72(2):133-140.
 37. Gupta RC. Conservative treatment of intertrochanteric fracture of femur. *Indian Journal of Orthopaedics.* 1974; 36(6):229
 38. Mohanty SP, Chacko V. A comparative analysis of operative and non-operative management of trochanteric fractures. A study of 135 consecutive cases. *Indian Ortho* 1984; 18(1):19-24
 39. Boyd HB, Griffin. & quot; Classification and treatment of trochanteric fractures & quot; *Arch surgery.* 1949; 58:853-86.
 40. Harris WH. Traumatic arthritis of the hip after dislocation and acetabular fractures: treatment by mold arthroplasty. An end-result study using a new method of result evaluation. *J Bone Joint Surg Am.* 1969; 51(4):737-55