



International Journal of Orthopaedics Sciences

ISSN: 2395-1958
IJOS 2019; 5(2): 344-346
© 2019 IJOS
www.orthopaper.com
Received: 11-02-2019
Accepted: 15-03-2019

Mohammed Jalal Mohiuddin
Assistant Professor, Deccan
College of Medical Sciences,
Hyderabad, Telangana, India

Hassan Rafeeq
Post Graduate, Deccan College of
Medical Sciences, Hyderabad,
Telangana, India

K Mrudula
Assistant Professor, Deccan
College of Medical Sciences,
Hyderabad, India

Mohammed Aslam Mohsin
Post Graduate, Deccan College of
Medical Sciences, Hyderabad,
Telangana, India

C Shamsunder
Professor and Head, Department
of Orthopedics Deccan College of
Medical Sciences, Hyderabad,
Telangana, India

Correspondence
Mohammed Jalal Mohiuddin
Assistant Professor, Deccan
College of Medical Sciences,
Hyderabad, Telangana, India

Genu valgum correction by distal femoral lateral open wedge corrective osteotomy

**Mohammed Jalal Mohiuddin, Hassan Rafeeq, K Mrudula, Mohammed
Aslam Mohsin and C Shamsunder**

DOI: <https://doi.org/10.22271/ortho.2019.v5.i2g.45>

Abstract

There are various conditions which effects normal growth of the physis. As femoral and tibial physis have maximum growth potential, any such diseases affects them most. Genu valgum is one such condition in which distal femur is commonly effected. The various etiologies are idiopathic, rickets, trauma, infections etc. The genu valgum is not only the cosmetic deformity but also alters biomechanics of knee and predispose knee to early lateral compartment osteoarthritis.

After popularization of Steven's 8 plate assisted growth modulation, the need of corrective osteotomy has declined considerably. For the mature skeleton corrective osteotomy is the only answer for correction. The level of osteotomy which is either metaphyseal or metadiaphyseal and the use of bone graft is merely the surgeon's choice. The effect of acute correction over the lateral neurovascular bundle is not being studied clearly.

Present study is the correction of genu valgum involving femoral component by distal femoral lateral based open wedge osteotomy without bone graft. The subclinical effect of osteotomy over the Common Peroneal nerve measured. The correction achieved, time required for the union of bone etc also documented.

Keywords: genu valgum, distal femur, osteotomy, metaphyseal, Steven's 8 plates

Introduction

Angular knee alignment changes according to the age of the child. It is genu varum with internal tibial torsion at birth and maximum varus at the age around 12 months. With progress in growth it straightens to zero by 18 to 24 months. Further drifts into valgus with maximum valgus angulation of about 12 degrees around 5 years. This genu valgum spontaneously correct by age of 7 years to that of normal adult values of around 8 degrees^[1,2].

The Knee valgus more than these values considered as pathological and need intervention. The etiology of genu valgum includes idiopathic, metabolic bone diseases such as rickets, skeletal dysplasia, physeal injury, and post-traumatic valgus^[3,4].

Genu valgum not only presents as cosmetic deformity but also affects the gait by rubbing the knees while running. It effects Q angle and predispose patella for dislocation. The weight bearing shifts to the medial aspect of foot giving the flat foot appearance and needs frequent foot wear change. The long standing alteration in mechanical axis predispose knee to develop lateral compartment osteo arthritis^[5].

Genu valgum deformity in adolescence appears commonly due to nutritional rickets. This appears when the epiphysis is near fusion and the correction possibility by growth modulation is less. These cases have mostly involvement of femoral component^[6]. The left over treatment option in this situation is Osteotomy and correction.

The common procedures described in the literature for this age group are Supracondylar opening or closing wedge osteotomy, metaphyseal diaphyseal level osteotomy, dome osteotomy or distraction osteosynthesis using monolateral and ring external fixator^[7]. Osteotomy by external fixation is cumbersome for patient with frame outside and there is risk of pin tract infection, loosening and stiffness of joint. Closed wedge osteotomy shortens the limb further and metaphyseal diaphyseal osteotomy is not at level of CORA and has risk of non union^[8].

Described technique here is distal femoral lateral based open wedge osteotomy for correction of genu valgum deformity of femoral origin. It has advantage over others as it's at the level of the CORA and there is no loss of the length of the limb. By keeping the medial cortex hinge intact there is no need of bone graft application [9].

Methodology

After IRB (institutional review board) clearance, study was done over 4 patients with genu valgum.

Inclusion criteria

- patients willing to participate in the study
- Male/female
- Fused physis
- No Intraarticular pathology

Exclusion criteria

- **Patients with open physis.**

All the patients were evaluated pre operatively to rule out metabolic abnormalities by performing serum calcium, Serum phosphates, serum Creatinine, Serum vitamin D, Serum alkaline phosphatase. If any metabolic abnormality found, patient treated for same and waited till turns normal.

Clinically deformity localized by flexing knee and assisting the correction. Intermalleolar distance measured pre and post operatively along with clinical thigh leg angle.

Full length X rays (stitch views) obtained for quantitative

measurement. Mechanical lateral distal femoral axis, medial proximal tibial angle, Tibio femoral angle and mechanical axis measured.

All patients were followed every month till union. Nerve conduction studies were performed to monitor for CPN palsy.

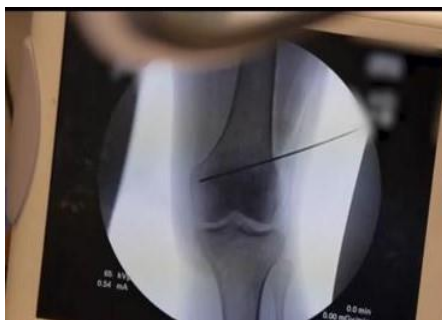Operative procedure

All patients operated under spinal anaesthesia and tourniquet control. Surgical exposure of femur done by using lateral approach. The level of osteotomy marked with guide pin under image intensifier. Osteotomy level at medial side is kept above level of collateral attachment. Lateral, anterior and posterior cortex osteotomy done keeping medial cortex intact. Gradual opening of the osteotomy, hinging over medial cortex performed.

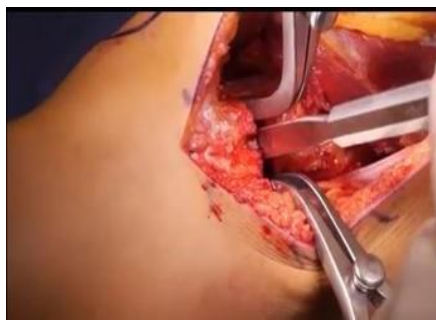Alignment checked on operation table with cautery cord test, cautery wire kept along the centre of mechanical axis at hip and ankle joint and checked at knee. Wedge opened till the knee mechanical axis fall at centre of knee joint. Provisional osteotomy site fixation done by the k-wires. Final osteotomy fixation done using distal femoral locking plate. Layer wise closure over the suction drain after checking haemostasis done, skin closed with 3-0 monocryl subcuticular sutures.

Post-operative follow-up

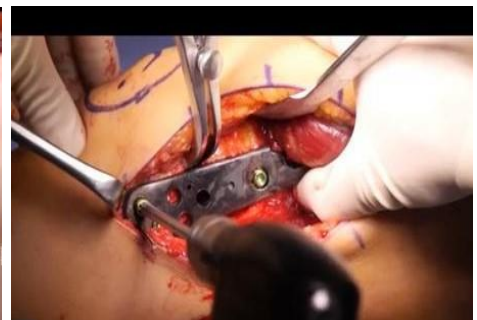Non weight bearing mobilisation of knee joint started after 2nd post op day, serial x rays taken monthly till union achieved.



Localizing site of osteotomy



Opening at osteotomy



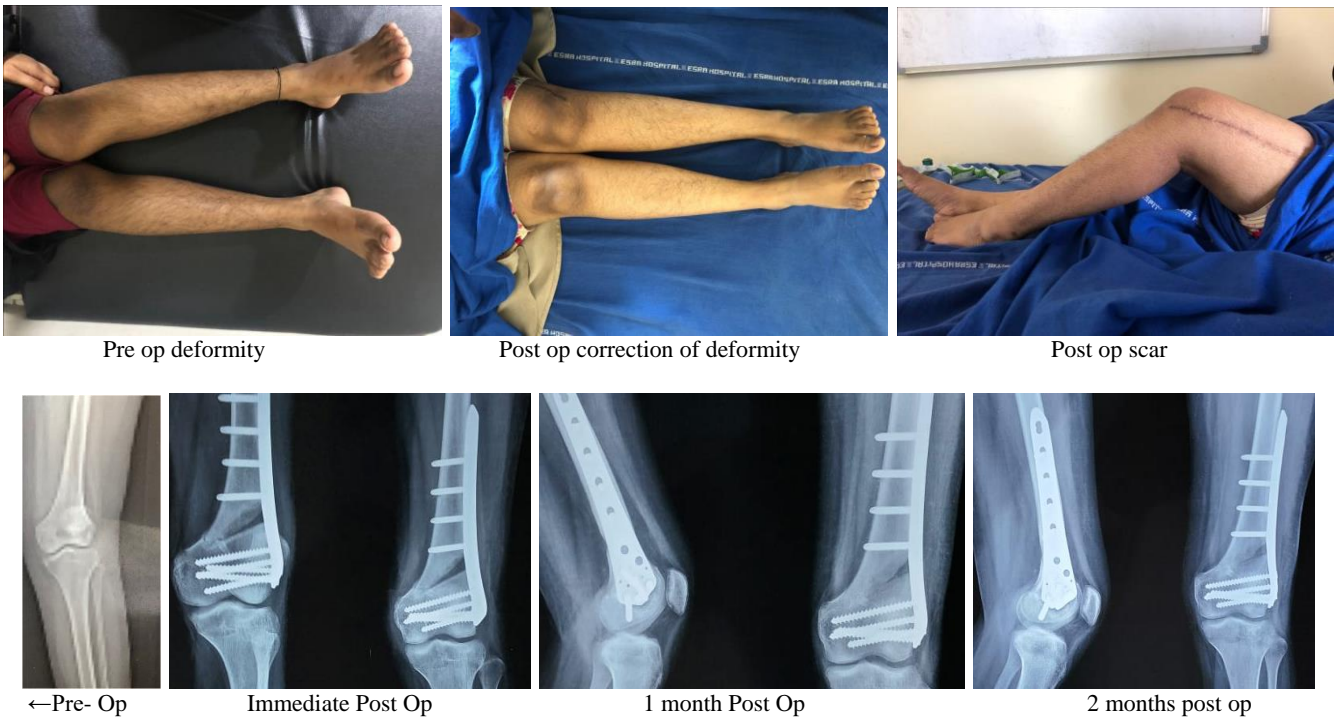
Fixation with distal femur locking plate

Results

Four patients included in study, all females, and mean age: 17.5 years (16yr to 19yr). All patients belong to lower middle class. All had severe vitamin D deficiency at presentation (<15ng/ml). All had high alkaline phosphatase at presentation (>1500 IU/Lit). Right side in one patient, left side in one and bilateral in two patients (operated only one side till now). All had femoral component effected clinically and radiologically. Clinical Tibio femoral angle was between 18 degrees to 20 degrees (mean 18.5 degrees), intermalleolar distance was between 18cms to 22 cms before surgery and decrease to 8 to 14 cms post operatively.

Two patients operated prior for guided growth by medial epiphysiodesis, there was 10 degree correction before physis got fused. mL DFA value in patients was ranging from 65 degree to 70 degree (mean: 67.25 degree) Mechanical axis was displaced laterally in all four patients. Radiological tibiofemoral angle was between 18 degrees to 20 degrees (mean: 18.5 degrees).

Post op NCS done in all patients showed no effect over CPN. There was no complications like nonunion, loss of correction, infection, CPN palsy or loss of knee range of movements, wound healing.



Discussion

Vitamin D deficiency is one of the commonest causes for knee angular deformity. Application of Steven’s 8 plates sometimes fails to correct the complete deformity but partial correction will help to prevent CPN stretch injury during acute correction by osteotomy. Distal femoral Metaphyseal osteotomy corrects deformity at level of CORA with no need of any translation at osteotomy site.

With intact medial cortical hinge and stable fixation, bone graft can be avoided without any risk of failure. There is no loss of the overall length of the limb in this procedure.

Conclusion

Distal femoral metaphyseal lateral based open wedge osteotomy and fixation with distal femur locking plate is the ideal treatment for genu valgum deformity involving femoral component.

References

1. Arazi M, Oğün TC, Memik R. Normal development of the tibiofemoral angle in children: a clinical study of 590 normal subjects from 3 to 17 years of age. *J Pediatr Orthop.* 2001; 21:264-7.
2. Yoo JH, Choi IH, Cho TJ *et al.* Development of tibiofemoral angle in korean children. *J Korean Med Sci.* 2008; 23:714-7.
3. Herring JA, Kling TF. Genu valgus. *J Pediatr Orthop* 1985; 5:236.
4. Bajpai A, Bardia A, Mantan M *et al.* Non-azotemic refractory rickets in Indian children. *Indian Pediatr.* 2005; 42:23-30.
5. Ramin Espandar, Seyed Mohammad-Javad Mortazavi, Taghi Baghdadi. Angular Deformities of the Lower Limb in Children. *Asian Journal of Sports Medicine.* March 2010; 1(1):46-53.
6. Gupta V, Kamra G, Singh D, Pandey K, Arora S. Wedgeless ‘V’ shaped distal femoral osteotomy with internal fixation for genu valgum in adolescents and young adults. *Acta Orthop Belg.* 2014; 80:234-40.
7. Agarwal A, Shaharyar A. Supracondylar “V” osteotomy for postrachitic genu valgum in children: A case series. *J*

- Orthop Traumatol Rehabil. 2017; 9(1):12-6
8. Brinkman JM, Freiling D, Lobenhoffer P, Staubli AE, van Heerwaarden RJ. Supracondylar femur osteotomies around the knee: Patient selection, planning, operative techniques, stability of fixation, and bone healing. *Orthopade* 2014; 43:S1-S10.
9. O'Malley MP, Pareek A, Reardon PJ, Stuart MJ, Krych AJ. Distal Femoral Osteotomy: Lateral Opening Wedge Technique. *Arthrosc Tech.* 2016; 5(4):725-730.