

ISSN: 2395-1958
IJOS 2019; 5(2): 292-294

www.orthopaper.com
Received: 24-02-2018
Accepted: 25-03-2018

Dr. Umesh Yadav
Assistant Professor, Department of Orthopaedics, PGIMS, Rohtak, Haryana, India

Dr. Ashish Devgan
Senior Professor, Department of Orthopaedics, PGIMS, Rohtak, Haryana, India

Dr. Pankaj Sharma
Assistant Professor, Department of Orthopaedics, PGIMS, Rohtak, Haryana, India

Dr. Vasudha
Assistant Professor, Department of Biochemistry, PGIMS, Rohtak, Haryana, India

Dr. Parvesh Kumar
Junior Resident, Department of Orthopaedics, PGIMS, Rohtak, Haryana, India

Dr. Ankur Sahu
Junior Resident, Department of Orthopaedics, PGIMS, Rohtak, Haryana, India

Dr. Rajpal Beniwal
Junior Resident, Department of Orthopaedics, PGIMS, Rohtak, Haryana, India

Dr. Vikas Ahlawat
Senior Resident, Department of Orthopaedics, PGIMS, Rohtak, Haryana, India

Dr. Sujit Kumar Singh
Junior Resident, Department of Orthopaedics, PGIMS, Rohtak, Haryana, India

Correspondence
Dr. Umesh Yadav
Assistant Professor, Department of Orthopaedics, PGIMS, Rohtak, Haryana, India

An unusual case report of broken needle in 6 Month old child migrating to lumbo-sacral spine with review of literature

Dr. Umesh Yadav, Dr. Ashish Devgan, Dr. Pankaj Sharma, Dr. Vasudha, Dr. Parvesh Kumar, Dr. Ankur Sahu, Dr. Rajpal Beniwal, Dr. Vikas Ahlawat and Dr. Sujit Kumar Singh

DOI: https://doi.org/10.22271/ortho.2019.v5.i2f.39

Abstract
Injuries associated with foreign bodies are quite common in children. A detailed history and careful examination and simple investigation techniques can facilitate easy removal of foreign bodies. We hereby present a rare case report of removal of foreign body, a broken needle, after intramuscular injection by a quack and migration of foreign body from gluteal region to lumbar spine. Needle was successfully removed by surgery under fluoroscopy. The purpose of present case is to draw attention towards high prevalence of treatment by quacks.

Keywords: Foreign body, Broken needle, Quacks

Introduction
Children are very prone to injuries by foreign bodies at home, school or playground. Range of injuries can vary from minor to life threatening. Diagnosis can be made by taking a detailed history, careful examination and simple radiological investigations. If the child is small, history is to be taken from parents or relatives. Sometimes there may be, difference between clinical findings and investigations [1, 2] Although most of the injuries are accidental but needle injuries have been found to be associated with child abuse [3, 4] Although less prevalent in western countries but in a developing country like India, treatment by Quacks is quite common specially in rural areas. Complications varies from local infection, endocarditis, sepsis, human immunodeficiency virus transmission, hepatitis C transmission and can even lead to death [5].

Case Report
A 6 month old child was brought by her parents to Accident and Emergency department of PGIMS, Rohtak after alleged history of some intramuscular injection in right gluteal region. As per parents, child was suffering from fever and diarrhoea. So parents took the child to quack in village who administered some intramuscular injection in right gluteal region. While doing so, due to movements of the child needle broke into the gluteal region. Parents took the child to nearby private hospital where an attempt to retrieve the needle was done but all went in vain. Child was referred to PGIMS Rohtak for further management.
On clinical examination, a stitched surgical scar mark was seen in right gluteal region. No apparent foreign body was clinically palpable. Hence, the child was sent for X-rays and to our surprise, needle has migrated to left side up to level of iliac blade on anteroposterior view (Figure 1).

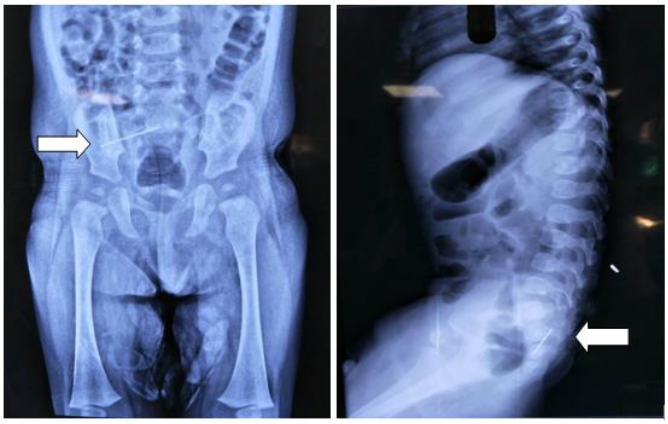

Fig 1, 2: Radiographs of child showing foreign body (arrow)

In lateral view (figure 2), the foreign body can be seen at level of lumbosacral spine. After routine pre anaesthetic checkup child was shifted to operation theatre. Parts were cleaned and draped. Fluoroscopy was used to locate the foreign body before giving any incision (Figure 3).

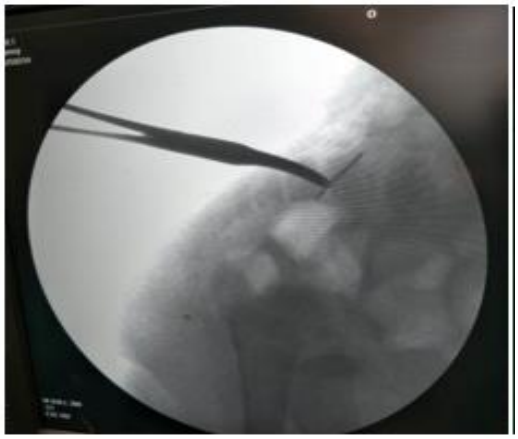

Fig 3: Showing use of fluoroscopy to locate needle in operating room. Arrow shows the incision of failed attempt of needle removal at private hospital.

Fig 4: A separate incision was given over left side above level of iliac crest

A separate incision was given over left side above level of iliac crest (Figure 4). Upon initial gross investigation, the needle was not visible in the soft tissues. Intraoperative fluoroscopy was used and confirmed the proximal migration of the needle during the procedure. Further deep dissection was performed using fingers and finally needle was recovered in muscle plane. It was found to bigger than 23 G needle surprisingly too big for a 6 month old child (Figure 5). Wound was closed in layers. Post operatively child was asymptomatic without any deficit.

Fig 5: Showing skin incision given

Fig 6: Showing removed needle piece

Discussion

Injuries due to foreign body penetration can occur as a result of either simple household accidents or child abuse. When it comes to needle injuries in children, mostly injuries are due to sewing needles. Such type of "iatrogenic" needle injuries are rarely reported in literature. According to previous reports of needle penetration, complications vary from simple to severe. A 6 year old child developed acute appendicitis following accidental ingestion of a sewing needle. Broken needles within the gastrointestinal system are difficult to diagnose because they may migrate. In one case, sewing needle penetration that occurred during childhood led to the formation of a fistula between the jejunum and aorta in a young adult man. This type of migration may complicate the identification of the foreign body during surgery [6-8]

Lukefahr *et al*. reported a case involving abuse of a 13-month-old toddler with penetration of one sewing needle in the perineum and two in the gluteal soft tissues. Rahimizadeh *et al.* and Abbassioun *et al*. reported cases of intracranial sewing needle penetration in adult patients. Patients diagnosed during adulthood may have been subjected to child abuse involving penetration of needles through the open fontanelle as infants. Sturiale *et al.* reported the parents as the responsible party in their review article. Major risk factors for abuse include a young age of the mother, low educational level, young age during pregnancy and delayed prenatal care [9-12].

Among needles, disposable needle syringes are most common type of needle used for injection of intravenous drugs, and may be re-used up to 20 times. The problem of frequent breakage of these small caliber needles is well recognized, especially with repeated manipulation [13, 14].

Diagnosis of a foreign body requires a good observation skill and proper examination. If there is old injury, entry wound may heal within short time. Even if the injury is fresh, due to migration of foreign body it may be difficult to localize. Hence proper radiographs with all possible views or ultrasonography should be done in such cases for a proper preoperative planning. In operating room also, fluoroscopy should be used judiciously to exactly locate foreign body.

Summary

We described a 6 month old child who was given an intramuscular injection by a quack resulting in breakage of needle and further migration of needle upto level of lumbo-sacral spine. A proper history and examination to rule out child abuse should be done and proper use of simple investigations like radiographs and ultrasound can lead to easy and early removal of the same and can avoid catastrophic complications.

References

1. Nadkarni UM, Munshi A, Damle SG *et al*. Retrieval of a foreign object from the palatal root canal of a permanent maxillary first molar: a case report. Quintessence Int. 2002; 33:609-12.
2. Yeung Y, Wong JK, Yip DK *et al*. A broken sewing needle in the knee of a 4-year-old child: is it really inside the knee? Arthroscopy. 2003; 19:E18-20.
3. Sbokos CG, Azariades M, Chlapoutakis E *et al*. The removal of sewing needles from two children's hearts. Thorac Cardiovasc Surg. 1984; 32:373-5.
4. Hambrick E, Rao TR, Lim LT. Jejunoaortic fistula from ingested seamstress needle. Arch Surg 1979; 114:732-3.
5. Kulaylat MN, Barakat N, Stephan RN, Gutierrez I. Embolization of illicit needle fragments. J Emerg Med. 1993; 11:403-408
6. Chintamani, Singhal V, Lubhana P *et al*. Liver abscess secondary to a broken needle migration: A case report. BMC Surg 2003; 3:8.
7. Arbel R, Kaplin O, Goodwin DR. The disappearing needle. J Hand Surg [Br]. 1987; 12:127-8.
8. Sinha DD, Sharma C, Gupta V *et al*. Sewing needle appendicitis in a child. Indian J Gastroenterol 2004; 23:219-20.
9. Lukefahr JL, Angel CA, Hendrick EP *et al*. Child abuse by percutaneous insertion of sewing needles. Clin Pediatr (Phila). 2001; 40:461-3.
10. Rahimizadeh A, Sabouri-Daylami M, Tabatabi M *et al*. Intracranial sewing needles. Neurosurgery. 1987; 20:666.
11. Abbassioun K, Ameli NO, Morshed AA. Intracranial sewing needles. Review of 13 cases. J Neurol Neurosurg Psychiatry. 1979; 42:1046-9.
12. Sturiale CL, Massimi L, Mangiola A *et al*. Sewing needles in the brain: infanticide attempts or accidental insertion? Neurosurgery. 2010; 67:E1170-9.
13. Norfolk GA, Gray SF. Intravenous drug users and broken needles- a hidden risk? Addiction. 2003; 98:1163-1166.
14. Murphy S. Intravenous drug use and AIDS: notes on the social economy of needle sharing. Contemp Drug Probl. 1987; 14:373-395.