



International Journal of Orthopaedics Sciences

ISSN: 2395-1958
IJOS 2019; 5(2): 279-287
© 2019 IJOS
www.orthopaper.com
Received: 16-02-2019
Accepted: 20-03-2019

Dr. K Sagar
Assitant Professor, NRIIMS,
Visakhapatnam, Andhra
Pradesh, India

Dr. K Hari Chandan
Sr. Resident, Dept of
Orthopaedics, Alluri Sitarama
Raju Academy Of Medical
Sciences, Malkapuram, Eluru,
Andhra Pradesh, India

Dr. I Chenchai
Professor, Dept of Orthopaedics,
Alluri Sitarama Raju Academy
of Medical Sciences,
Malkapuram, Eluru, Andhra
Pradesh, India

Surgical stabilization of clavicle fractures in adults: A clinical study

Dr. K Sagar, Dr. K Hari Chandan and Dr. I Chenchai

DOI: <https://doi.org/10.22271/ortho.2019.v5.i2f.37>

Abstract

Background: The purpose of this prospective study was to evaluate the functional results of Surgical stabilization of clavicle fractures in adults decided on specific selection criteria.

Materials and Methods: Twenty patients with clavicle fractures were recruited in the study between Nov 2013 and Dec 2015 at our, Alluri Sitarama Raju Academy of Medical Sciences, Malkapuram, Eluru, Andhra Pradesh, India.

Keywords: clavicle, plate, locking compression plate

Introduction

Clavicular fracture is one of the most common bony injuries. They account for 2.6% to 4% of adult fractures and 35% of injuries to the shoulder girdle. The clavicle is an S-shaped bone that acts as a strut between the sternum and the glenohumeral joint. It also has a suspensory function to the shoulder girdle. The shoulder hangs from the clavicle by the coracoclavicular ligament [1]. Mid shaft of clavicle fracture accounts for 70% to 80% of all clavicular fractures; lateral fractures contribute 15% to 30%, and medial fractures, at 3%, are relatively rare. The rate of mid clavicular fractures is more than twice as high in men as in women. The peak incidence occurs in the third decade of life [2]. Clavicular fractures have traditionally been treated non-operatively. Surgical treatment of acute mid shaft fractures was not favoured due to relatively frequent and serious complications. However, the prevalence of non-union or mal-union in dislocated mid shaft clavicular fractures after conservative treatment is higher than previously presumed and fixation methods have evolved. The incidence of nonunion of clavicular fractures is usually quoted as being from 0.1 to 0.8%, and the mainstay of treatment has long been nonoperative. More recent data, based on detailed classification of fractures, suggest that the incidence of nonunion in displaced comminuted clavicular fractures in adults is between 10 and 15% [3] Persistent wide separation of fragments with interposition of soft tissue may lead to failure of closed reduction and all fractures with initial shortening of more than 2cm resulted in nonunion [4].

Several studies have examined the safety and efficacy of primary open reduction and internal fixation for completely displaced midshaft clavicular fractures and have noted high union rate with a low complication rate [5] In a large number of complex clavicle fractures a satisfactory outcome is possible with a low complication rate using a locked compression plate [6]. Primary internal fixation of displaced comminuted mid-shaft clavicular fractures leads to predictable and early return to function [7].

The present consensus that great majority of clavicular fractures heal with non operative treatment is no longer valid. The amount of pain and disability during the first three weeks of conservative treatment has been underrated and the common view that nonunion does not occur is wrong.

There are various surgical methods for treating clavicle midshaft fractures, such as intramedullary fixation using K-wires, Knowles pin, rock wood pin and titanium elastic nails and plate fixation. In particular, plate fixation can help obtain firm anatomical reduction in severe displaced or comminuted fracture. We have taken up this study to gain a deeper understanding of results and problems associated and to evaluate the functional outcome after fixation of displaced clavicular fractures by surgical management.

Correspondence

Dr. K Hari Chandan
Sr. Resident, Dept of
Orthopaedics, Alluri Sitarama
Raju academy of medical
sciences, Malkapuram, Eluru,
Andhra Pradesh, India

Aims and Objectives

1. To study the surgical outcome in clavicular fractures in terms of duration of union both clinically and radiologically – a study of 20 cases.
2. To study the merits and demerits encountered in the surgical management of clavicle fractures and finally draw conclusions of overall study.
3. Improve and restore the function of the shoulder for activities of daily living, vocational and sports activities.
4. The expected duration of rehabilitation is for 10 to 12 weeks.
5. Day one to one week: Limb is immobilized in a sling with shoulder held in adduction and internal rotation. Elbow is maintained at 90° of flexion with no range of motion at shoulder.
6. At two weeks: After suture removal gentle pendulum exercises to the shoulder in the sling as pain permits is allowed.
7. At four to six weeks: At the end of 6 weeks gentle active range of motion of the shoulder is allowed. Abduction is limited to 80°.

Methods and Methodology

The present study was carried out from November 2015 to August 2017 at Orthopaedics Department in Alluri Sitaramaraju Academy of Medical Sciences, Eluru. During this period 20 patients of clavicular fractures were treated surgically. In our hospital we have done open reduction internal fixation by plating in all 20 cases of which precontoured Locking Compression Plates are used in 14 cases and Reconstruction plates in 6 cases.

Inclusion criteria

1. Adult male and female patients above 18 years to 60 years,
2. Displaced and comminution of clavicular fractures

Exclusion criteria

1. Age < 18 years
2. Open fractures
3. Pathological fractures
4. Undisplaced fractures
5. Associated head injury
6. Associated with neuro vascular injury
7. Established non-union from previous fracture

Demographic information such as name, age, sex, occupation and address were noted. Then a detailed clinical history such as mode of injury like fall on the shoulder, Road traffic accident, direct injury to shoulder and fall on outstretched hand was noted. Enquiry was made to note site of pain and swelling over the affected clavicle. Past medical illness and family history were also recorded.

Follow up: Regular follow up for every 4 weeks up to 3 months was done.

Local examination of the affected clavicle for tenderness, instability deformity and shoulder movements were assessed. X-rays were taken at each follow up visits to know about progressive fracture union and implant position.

Rehabilitation of the affected extremity were done according to the stage of fracture union and time duration from day of surgery. Patients were followed up till radiological union. The functional outcome were assessed by Constant and Murley score [11, 12].

Constant and murley scoring

The patients are graded as follows

A normal shoulder in a 25 year old man resists 25 pounds without difficulty. The score given for normal power is 25 points, with proportionately less for less power.

Patients were graded as below with a maximum of 100 points.

Constant and murley scoring

| Total score | Result |
|-------------|-----------|
| 90-100 | Excellent |
| 80-89 | Good |
| 70-79 | Fair |
| 0-70 | Poor |

Results and Observation

The present study consists of 20 patients of fresh fracture of the clavicle which were treated surgically with open reduction internal fixation with plate (includes both reconstruction plate and precontoured locking compression plate) & screws for clavicle fracture between November 2015 to August 2017. All the patients were treated at ASRAM General Hospital. All the patients were available for follow-up and they were followed every 4 weeks. Results were analyzed both clinically and radiologically.

Table 1: Mode of Injury

| Mode of Injury | No. of clavicle fractures | % |
|-----------------------------------|---------------------------|-----|
| Fall on shoulder from two wheeler | 7 | 35 |
| Road traffic accident | 6 | 30 |
| Simple fall on shoulder | 3 | 15 |
| Fall on out stretched hand | 4 | 20 |
| Total | 20 | 100 |

Direct injury occurred in 16 patients (80%) among them 7 patients (35%) were due to fall on shoulder from two wheeler, 6 patients (30%) were due to road traffic accident, 3 patients (15%) were due to fall on the shoulder after slipping. Indirect injury occurred in 4 patients (20%) due to fall on outstretched hand.

Table 2: Age Gender

| Age in | No. of clavicle fractures | Percentage |
|--------|---------------------------|------------|
| 19-29 | 7 | 35 |
| 30-39 | 5 | 25 |
| 40-49 | 4 | 20 |
| 50-59 | 4 | 20 |
| Total | 20 | 100 |

Majority of the patient with clavicle fracture i.e. 7 patients (35%) were in the age group of 19-29 years. The youngest patient was 20 years and oldest patient was 56 years. The average patient age was 33 years.

Table 3: Gender Incidence

| Sex | No. of clavicle # | % |
|--------|-------------------|-----|
| Male | 16 | 80 |
| Female | 4 | 20 |
| Total | 20 | 100 |

In our study out of 20 patients 16 were male and 4 were female patients

Site of Fracture:

Table 4: Site of fracture

| Site of fracture of clavicle | Number | Percentage (%) |
|------------------------------|--------|----------------|
| middle third fractures | 17 | 85 |
| Lateral third fractures | 3 | 15 |

Table 5: Side Effected

| Side | No. of clavicle # | % |
|-------|-------------------|-----|
| Right | 8 | 40 |
| Left | 12 | 60 |
| Total | 20 | 100 |

In this study, there were 12 patients (60%) of Left sided fracture and 8 patients (40%) of Right sided fracture

Classification

Plain radiograph of clavicle with shoulder is taken in anteroposterior view to assess the site of fracture and the type of fracture (like Displacement, Angulation, Comminution). In this study Robinson classification was followed.

Table 6: Classification

| Type | No. of cases | |
|----------------------|--------------|----------|
| Type -2 Middle third | B1 | 15 (75%) |
| | B2 | 2 (10%) |
| Type-3 lateral third | B1 | 3(15%) |

Out of 20 clavicle fractures Type-2 middle third fracture type-2 B1 (displaced with simple or single butterfly fragment) occurred in 15 patients (75%) and type-2 B2 (displaced with comminuted or segmental) fracture occurred in 2 patients (10%).

In type 3 lateral clavicle fractures B1 (displaced fracture and extraarticular) seen in 3 patients (15%).

Time Interval for Surgery: All the patients were operated as early as possible once the general condition of the patients was stable.

Table 7: Time interval for surgery

| Time of surgery | No. of clavicle # | % |
|-----------------|-------------------|----|
| < 7 days | 18 | 90 |
| 7-14 days | 2 | 10 |

In this study, 18 patients (90%) were operated in the first week and 2 patients (10%) were operated in the second week due to associated fracture and late patient visit after trauma. All the patients were operated under general anaesthesia.

Type of surgery

All patients in our study are operated using open reduction internal fixation by plating of which 14 (70%) fractures are treated with precontoured locking compression plate and 6 (30%) fractures using reconstruction plates.

In all the 3 lateral third clavicle fractures we have used precontoured lcps as the distal cortex purchase was satisfactory. In the 17 middle third clavicle fractures we have used reconstruction plating in 6 cases and LCPs in 11 cases. Decision on plate selection was random and was not affected by any indications.

The aim was to place atleast 3 screws in the medial and lateral fragments through bone cortices

Table 8: Type of Surgery

| Type of Plate | No. of patients | Percentage |
|---------------------------|-----------------|------------|
| Locking compression plate | 14 | 70% |
| Reconstruction plate | 6 | 30% |
| Total | 20 | 100% |

Duration of union

The fracture was considered to be united when clinically there was no tenderness, radiologically the fracture line was not visible and full unprotected function of the limb was possible.

Table 9: Duration of union

| Time of union | No. of clavicle fracture | % |
|---------------|--------------------------|----|
| 8-12 week | 19 | 95 |
| >12 weeks | 1 | 5 |

In middle third clavicle fracture 19 patients (95%) united at the end of 12 weeks. In 1 patient (5%) delayed union occurred. In this patient it was due to large butterfly fragment at fracture site which united at 16 weeks each.

We advise the patient for removal of the plate at the end of 1 year. No patient has turned up for implant removal. So Implant removal was not done in any patient till the end of this study.

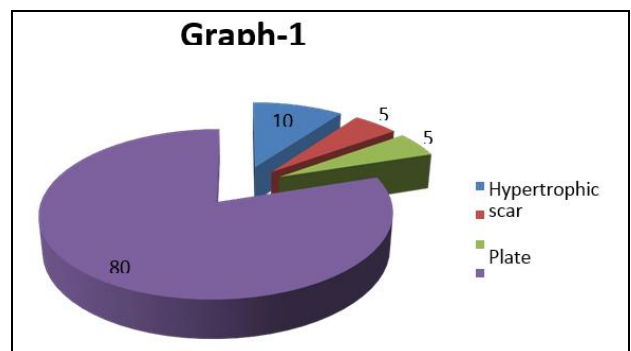
Complications

Major complication: A complication requiring inpatient treatment and resulting in an additional morbidity of 2 months or more was regarded as a major complication.

Table 10: Complications

| | Types | No. of cases | % |
|-------|------------------------|--------------|----|
| Minor | Hypertrophic skin scar | 2 | 10 |
| | Plate prominence | 1 | 5 |
| | Delayed union | 1 | 5 |
| | Plate loosening | 0 | 0 |
| Major | Plate breakage | 0 | 0 |

In this study 2 patients (10%) had hypertrophic skin scar and in 1 patient (10%) had plate prominence and in another 1 patient (5%) delayed union occurred.

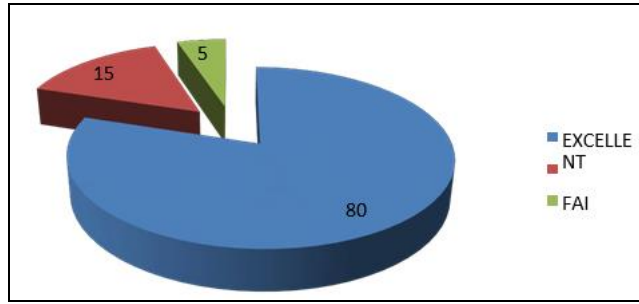


Functional outcome: The functional outcome is assessed by constant and murley score.

Table 11: Functional Outcome

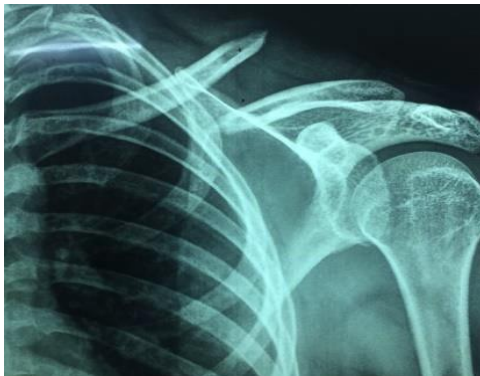| Functional outcome | No. of clavicle fractures | % |
|--------------------|---------------------------|-----|
| Excellent | 16 | 80 |
| Good | 3 | 15 |
| Fair | 1 | 5 |
| Poor | 0 | 0 |
| Total | 20 | 100 |

In this study 16 patients (80%) had excellent functional outcome, (5%).
good functional outcome in 3 patients (15%) and fair in 1 patient

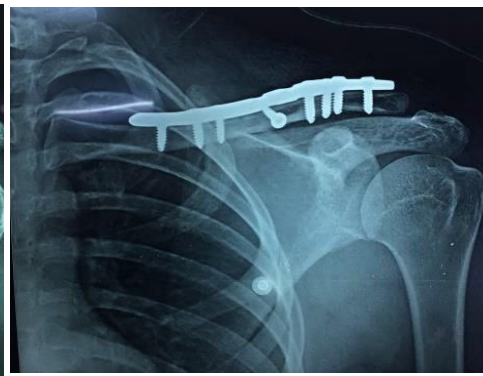


Graph - Functional

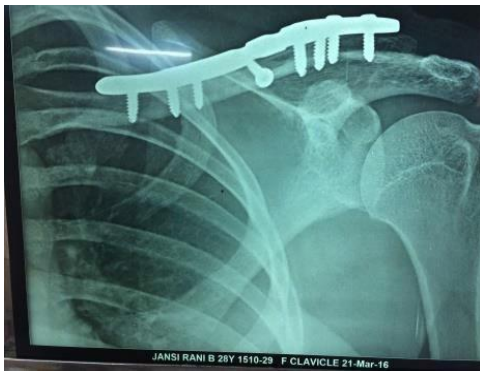Case 1.



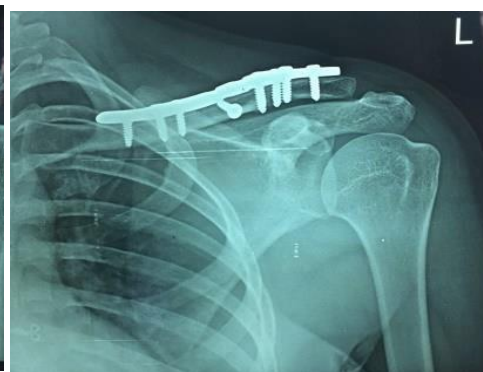Pre operative x-ray



Immediate post operative

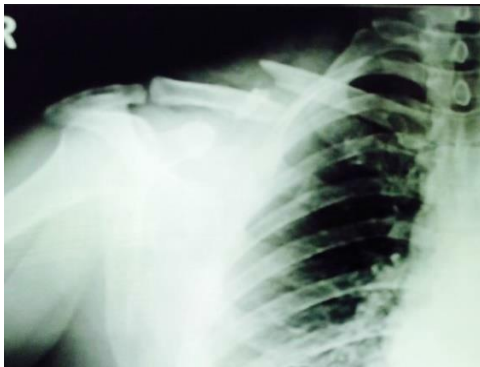

4 weeks post operative

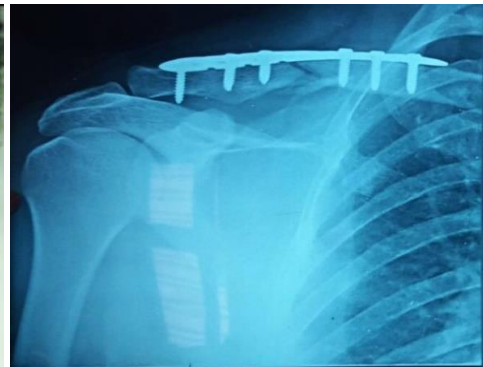

12 weeks post operative x-ray

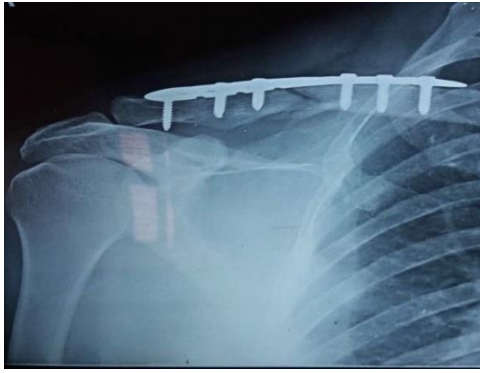
Case 2.



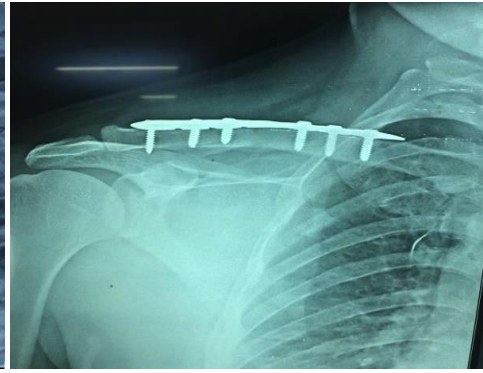
Pre operative x-ray



immediate post operative

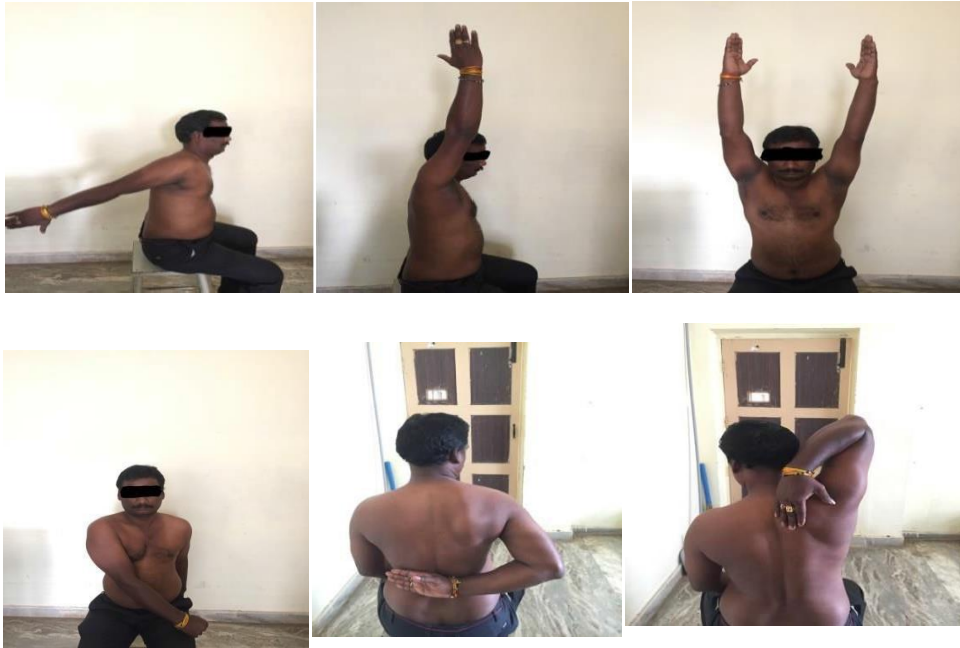

4 weeks post-operative x-ray



12 weeks post-operative x-ray

Movements: flexion, extension, adduction, abduction, internal rotation, external rotation



Complication

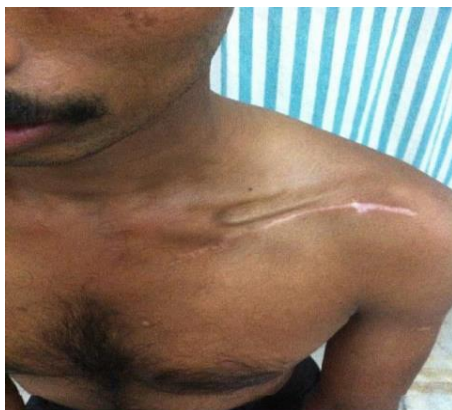

Plate Prominence

Discussion

The clavicle acts as a strut, which transfers power from the trunk to the arm. Most clavicle fractures are treated conservatively. In 1960, Neer¹⁸ reported that nonunion occurred only in 3 of the 2,235 patients in whom clavicle midshaft fractures had been treated non-surgically. In 1968, Rowe⁹ reported that non operative treatments resulted in nonunion in only 4 out of 566 clavicle midshaft fracture cases, and the surgically treated patients presented with more postoperative complications and nonunion. Accordingly, non

operative treatments have been preferred by many surgeons. However, according to Zlowodzki *et al.*^[9] nonunion occurred after non operative treatments in 6% of 1,145 clavicle fracture cases and the percentage increased to 15-20% particularly in the 159 fracture cases with severe displacement. While only 2% nonunion was noted in the surgically treated cases. In addition, the extent of fragment displacement is closely associated with fracture union^[17, 21] and anatomical restoration of the displacement is considered essential for rapid recovery. Hence, there has been increasing interest in surgical treatments with open reduction and internal fixation. In particular, operative treatments are performed more often for the treatment of clavicle fractures due to the increasing instances of severely displaced and comminuted fractures caused by high energy injuries in motor vehicle accidents, industrial accidents and sport injuries.^[22, 23] Shen *et al.*^[24] obtained satisfactory outcomes in 94% of the 232 cases by open reduction and plate fixation in 2007, the Canadian Orthopaedic Trauma Society reported that internal fixation with plates resulted in more rapid union, excellent clinical outcomes, and lower complication rates in 132 patients with displaced clavicle fractures than non-operative treatments^[7] The operative methods for the treatment of clavicle fractures involve intramedullary K-wire fixation or Steinmann pin fixation and plate fixation. The procedures using the former two materials result in low resistance to torque, carry risks of pin loosening and infection, and require a long-term fixation

period. [25, 26] In addition, Elastic stable intramedullary nailing leads to good cosmetic and functional results. Patients profit from marked postoperative pain reduction and a rapid recovery of range of motion in the shoulder joint [27-29]. However, multifragmentary fractures or oblique fractures can lead to a telescoping of the fracture site. This leads to a postoperative length reduction. To prevent this complication, elastic stable intramedullary nailing is only recommended for simple or displaced wedge fractures [46].

Open reduction and internal fixation with plates, such as Sherman plates, dynamic compression plates, and semitubular plates, can be effective in obtaining anatomical reduction, applying direct compression to the fracture site, and producing resistance to torque. However, it is disadvantageous in achieving firm fixation because it is difficult to hold the plates to the clavicle in severely comminuted fracture cases [31].

In contrast, reconstruction plates can be manipulated to fit the contour of the clavicle and fracture pattern to obtain firm fixation, are lighter and thinner than dynamic compression plates and are durable to multidirectional mechanical stress imposed on the fracture site [24, 32]. On the other hand, penetration of the opposite cortical bone for screw fixation may cause damage to the subclavian artery and firm fixation can be difficult to maintain in osteoporotic patients over 50 years of age [33, 27].

In this study the use of reconstruction plate did not result in any complications such as subclavian artery injury or brachial plexus injury and no cases of any screw loosening. The advantages of reconstruction LCPs include strong fixation due to locking between the screw and plate, and blood supply preservation due to minimal contact between plate and cortical bone [28, 29]. With conventional screws and plates, fracture site stability is provided by friction between the plate and bone cortex. Accordingly, screws need to be fixed onto both cortexes. In contrast, when an LCP is used, an external force is transmitted from the cortical bone through the conically threaded plate hole to the plate because the screw head is locked firmly in the threaded plate hole. Therefore, the plate does not need to be compressed onto the cortical bone for stability, which results in good preservation of the blood supply, and the plate thread is also helpful in preventing screw loosening or instability [30, 34]. When LCPs are used to treat clavicle fractures, the risks of injury to the subclavicular artery or brachial plexus can be reduced because fixation can be achieved without the tip of the screw reaching the opposite bone cortex and periosteal stripping can be minimized to promote rapid union [30]. It is believed that the surgery time can be reduced using LCPs because accurate plate contouring is not necessary and periosteal stripping could be minimized using self-tapping screws. However, there were no significant differences between the reconstruction plate group and reconstruction LCP group in terms of the union period, surgical time, and Quick DASH score. Even though the sample of our study is small we did not observe any differences between reconstruction plate cases and LCP plate cases.

Nevertheless, a reconstruction LCP can be an effective replacement for are construction plate considering that complications, such as screw loosening and plate failure, were not observed in the reconstruction LCP group. Contour of the plates was performed with locking sleeves inserted into screw holes considering the problem of LCP that screw fixation can be weakened if breakage of the screw holes occurs in the plate thread during plate contouring.

For lateral third fractures we have got a sample of only 3 cases in our entire study period and we have used locking compression plates for all 3 cases as the distal purchase was adequate. Tan *et al.* [36] revealed that locking plate fixation exhibited excellent results in daily activities, no shoulder pain, ROM in distal clavicle fractures type II near where asklein *et al.* [37] reported complication rate of 22.7% in patients treated with hook plate for unstable lateral 1/3 rd fractures. Tan *et al.* [36] also described that 74% of patients with hook plate developed shoulder pain.

Unfortunately, surgical treatments for clavicle fractures leave distinct scars on the shoulder. Ali Khan and Lucas 35 suggested in 1978 that patients with clavicle midshaft fractures could suffer from hypertrophic scarring after surgical treatments with plates. Surgical scars are currently considered major complications due to the increasing demand for aesthetics. Six of our patients had hypertrophic scarring after surgery and complained of discomfort in carrying out their daily activities. However, none of them had associated pain or requested cosmetic surgery. However, the patients should be informed of the possible appearance of surgical scars preoperatively and surgical techniques should be improved to address the problem.

In a study conducted to clavicle fractures analyze the results of conservative treatment by Hill *et al* 14 in 1997, Nordqvist *et al* 15 in 1998 and Robinson *et al* 9 in 2004 found poor results following conservative treatment of displaced middle third clavicle fracture. There are specific indications like displacement, with or without comminuted middle third clavicle fracture (Robinson Type-2B1, 2B2).

The present study of patients with clavicle fractures is compared with Bostman *et al* 10 study which treated middle third clavicle fractures, in this totally 103 patients were treated by early open reduction and internal fixation with plate and screws. It was also compared with Cho8 *et al* study where 41 patients with a clavicle midshaft fracture were treated by internal fixation with a reconstruction plate (19 patients) or reconstruction LCP (22 patients).It was also compared with H.Jiang *et al* study 17 where 64 cases of open reduction and internal fixation were performed for clavicle mid shaft fractures. MIPPO and conventional open reduction surgery procedures with locking compression plate were used in 32 and 32 cases respectively.

Mechanism of injury

In this study the/ patients with middle third clavicle fracture the mechanism of injury was due to fall on the shoulder from two wheeler in 7 patients (35%), Road traffic accident in 6 patients (30%), simple fall on the shoulder in 3 patients (15%), Fall on outstretched hand in 4 patients (20%).

In Bostman *et al* 10 study the mechanism of injury was due to fall from the two wheeler in 38 Patients (36.8%), slipping and fall in 24 Patients (23.30%), motor vehicle accident in 19 patients (18.45%) and sports in injury 22 patients (21.36%).

In Cho *et al* 8 study, in reconstructions plate group there were 13 patients who sustained Road traffic accident, 3 patients with slip down, 1 patient with sports injury, 1 patient with fall down and 1 patient with miscellaneous mode of injury. In locking compression plate group there 7 patients with road traffic accident, 3 patients with slip down, 1 patient with fall down and 1 patient with miscellaneous mode.

In H. jiang *et al.* [17] study cause of injury in mipppo group was 23 cases who sustained Road Traffic Accident, 4 patients with fall down, and sports injury in 5 patients and in conventional open reduction group 25 cases sustained RTA, 6 patients with

fall down, 1 patient with sports injury. This shows direct injury to the shoulder is the common cause of this fracture.

Age incidence

Clavicle fracture commonly occurred between the age group of 19 to 29 years in 7 patients (40%). The youngest patient age was 20 years and oldest patient age was 56 years. The average patients' age was 33 years. In Bostman *et al.* [24] study patients average age was 33.4 years and the youngest patient age was 19 years and oldest patient age was 62 years. In Cho *et al* 15 study, in reconstruction plate group the mean age was 45 (range 22- 70) and that of the locking compression plate was 46 (range 19- 69). In H. jiang *et al* 17 study in MIPPO group the mean age was 40 (range 20-70) and in conventional open reduction group was 45 (range 18-60) From this we can infer that clavicle fractures occur in young and active patients.

Sex incidence

The patients in this study were 16 males and 4 females. In Bostman *et al* 10 series also commonly males are affected 76 Patients (73.79%) compared to females 27 Patients (26.21%). In Cho *et al.* [8] study, the reconstruction plate groups that 12 male and 7 female Patients and in the locking compression plate group it was 17 male and 5 Patients. In H. jiang *et al.* [17] study the MIPPO group that 20 male and 12 female patients and in the conventional open reduction group it was 20 male and 12 female patients. Male predominance can be drawn from this inference.

Associated injuries

In this study 2 patients had associated injury in the form of tibial plateau fracture and floating elbow. This was caused by Road traffic accident. In Bostman *et al.* [24] series there was no associated injuries. In Cho *et al.* [8] study, an associated injury was found in 16 Cases: hemothorax and rotator cuff tear in 1 Case.

Type of fracture

In this study all Patients with clavicle fractures were of closed type. This is comparable to Bostman *et al* [10] and Cho *et al* [8] study which also showed all their patients were closed fractures.

Fracture classification

In this present study, Robinson Type-2 B1 (Displaced with simple or butterfly fragment) were more common and there were 15 Patients (75%). Type-2 B2 (Displaced with comminution) occurred in only 2 Patients (10%) and lateral third type-3 B1 in 3(15%) patients. In a study by Nordqvist *et al.* 38 fractures of midshaft clavicle are 76% and fracture of lateral third clavicle are 21%. In Bostman *et al* 10 study also Robinson type-2B1 was common in 81 patients (78.64%). Robinson type-2 B2 occurred only in 22 patients (21.36%). In Cho *et al* 8 study, in reconstruction plate group there were 7 Patients with B1 type and 12 Patients with B2 type and that of the locking compression group had 9 B1 type and 13 B2 type. In H. jiang *et al.* [17] study, in MIPPO group there were 18 patients with B1 type and 14 patients with B2 type and that of conventional open reduction group had 15 B1 type and 17 B2 type. In a recent multicentral studies by caroline *et al.* [39] they classified 2422 clavicle fractures by Robinsons classification out of which 358 (14.8%) are of 3B1 which is similar in our study.

Time interval for surgery

Most of the patient in our study were operated in the first week i.e. 18 patients (90%). 2 patients (10%) were operated in the second week due to Associated injuries. In Bostman *et al* 24 study all the patients were operated within 3 days of injury. In Cho *et al* [8] study, the reconstruction plate group was operated by 4 days and that of locking compression plate was 9 days. In H. jiang *et al.* [17] study, the MIPPO group was operated by 7 days (1-15 days) and also 7 days conventional open reduction group.

Type of surgery

In this study 14 cases were treated by using locking compression plates and in 6 cases reconstruction plates were used. In Cho *et al.* [8] out of 41 cases reconstruction plate was used in 19 cases and LCPs were used in 22 cases. In this study atleast 3 cortices were fixed on either side of fracture were used.

In Bostman *et al* 10 study plate length was above 6 holes to place at least three screws in each fragment. Plate length also depends upon the amount of comminution.

Duration of union

In this study majority of the middle third clavicle fracture cases united between 8 to 12 weeks i.e. 19 Patients (95%). In 1 Patient (5%) delayed union occurred as there was a displaced butterfly fragment which united with the main fragment at the end of 16 weeks. Lazarus MD 13 stated radiological union occurred approximately between 6 to 12 weeks. In Cho 15 *et al* study, bony union for reconstruction plate was 14.6 weeks and that of locking compression plate was 13.2 weeks. In H. jiang *et al* [17] study, mean time to union in conventional open reduction group was 13 weeks compared to 12 weeks in MIPPO group.

Complications

There were no major complications in this study. Bostman *et al.* 10, Cho *et al* 8 and H. jiang *et al.* [17] study didn't have any major Complications.

B Minor complication: Delayed union: Delayed union

Occurred in 1 Patient (5%) due to a large butterfly fragment in the inferior aspect of clavicle which went on to unite with the main fragments at the end of 16 weeks. In Bostman *et al* 24 study delayed union occurred in 3 Patients (2.91%).

Skin complications

There were hypertrophic skin scar in 2 Patients (10%). Plate prominence through the skin was reported in 1 Patient (5%). In H. jiang *et al* 17 study, in conventional open reduction dysesthesia in area of skin incision and directly below occurred in 10 cases, hypertrophic skin scar occurred in 5 cases, painful shoulder in 2 cases, limitation of shoulder movement in 1 case. In MIPPO group dysesthesia in 2 cases, no hypertrophic scarring, 2 cases painful shoulder, and no limitation of shoulder movement. The total complications in this study were 10% excluding skin related minor complications. The total complication rate of Bostman *et al.* [10] study was 23%.

Functional outcome

The functional outcome according to Constant and Murley 27 in this study of total 20 Patients of fresh middle third clavicle fracture fixed with locking compression plate and screws showed excellent results in 16 Patients (80%) and good

functional outcome in patients 3 Patients (15%). Fair functional outcome in 1 Patient (5%) where plate prominence occurred and the patient had some pain over the shoulder. The advantage of rigid internal fixation and early mobilization of fresh displaced clavicle fracture is that it (displaced comminuted middle third) gives immediate pain relief and prevents the development of shoulder stiffness and non-union.

Conclusion

Clavicle fractures are usually treated conservatively but there are specific indications for which operative treatment is needed like comminuted, displaced middle third clavicle fractures and displaced lateral third clavicle fractures. Primary open reduction and internal fixation with plate and screws of fresh middle third clavicle fractures provides a more rigid fixation and does not require immobilization for longer periods. In this study reconstruction plates and locking compression plates were used for middle third fractures. Both of them gave similar results with satisfactory outcome and early range of movements. Locking compression plates provides strong fixation due to locking between the screw and plate, and blood supply preservation due to minimal contact between plate and cortical bone and precontoured to the shape of the clavicle, side specific and provide stable fixation.

Reconstruction plates can be manipulated to fit the contour of the clavicle and fracture pattern to obtain firm fixation, are lighter and thinner. It is necessary to put the plate superiorly and at least three screws to be applied medially and three screws laterally.

In case of lateral third clavicle fractures open reduction internal fixation with precontoured locking plate or hook plate can be used. In our study a small number of lateral third clavicle fractures are treated with precontoured locking compression plates gave excellent results with early range of movements. In conclusion, bony union was good and clinical outcomes were satisfactory using both reconstruction plates and locking compression plates in middle third clavicle fractures and Locking compression plates in lateral third clavicle fractures. In all 20 cases fractures united and there were no cases of non union. No implant removal was done till the end of this study. We were able to achieve excellent results in 16 patients.

Summary

Twenty patients with clavicular fractures were treated surgically with primary open reduction and internal fixation with plate and screws between November-2015 to August-2017 at ASRAM General Hospital. Patients above 18 years were included in this study and the patients' age ranged from 19 to 57 years. Clavicle fracture is common between 19 to 29 years. Fall from two wheelers was the cause for this fracture in most of the patients and 16 male and 4 female patients. 60% of the fractures were of the left side. 10% of the patients had associated injury like tibial plateau fracture and floating elbow which were treated surgically.

Out of 20 cases of clavicle fractures 17 cases are middle third and 3 cases are lateral third clavicle fractures. We didn't get any cases with medial 1/3 rd fractures. Middle third clavicle fracture were Robinson type-2B1 in 15 Patients, type-2 B2 in 2 patients and in lateral third fractures type-3 B1 in 3 patients. In 18 cases surgery was done within 1st week.

All our patients were operated under general anesthesia with locking compression plate and screws in 14 pts (11 middle third and 3 lateral third) and reconstruction plates in 6 pts (all are middle third).

All our patients are immobilized in an arm pouch for 4 weeks. Average duration of stay in the hospital was 10.7 days. All the patients were mobilized at the end of 2nd week with the sling. The functional outcome assessment according to Constant and Murley score showed excellent functional outcome in 16 patients (80%) and good functional outcome in 3 patients (15%) and 1 fair functional outcome in 1 patient (5%).

References

1. Robert Buchholz, James D Heckman, Charles Court-Brown, Rockwood Green's fractures in adults 6th edition. 2006; 1:1213-1216.
2. Schiffer G, Faymonville C, Skouras E, Andermahr J, Jubel A. Midclavicular fracture: Not just a trivial injury – current treatment options. *Dtsch Arztebl Int.* 2010; 107(41):711-7.
3. Wun-Jer Shen, Tsung-Jen Liu, Young-Shung Shen. Po-Cheng Orthopaedic Institute, 100 Po-Ai 2nd Road, Kaohsiung, 813, Taiwan. Plate Fixation of Fresh Displaced Midshaft Clavicle Fractures, *J Bone Joint Surg [Br]*. 2008; 90-B:1495-B
4. Terry Canale S. James H Beaty. *Campbell's Operative Orthopedics* 11th Edition, 3, 3371-3376.
5. Stegeman *et al.* Displaced Midshaft Fractures of the Clavicle: Non-Operative Treatment Versus Plate Fixation (Sleutel-TRIAL). A Multicentre Randomised Controlled Trial. *BMC Musculoskeletal Disorders.* 2011; 12:196.
6. Modi N, Patel AD, Hallam Norfolk P. Norwich University Hospital NHS Foundation Trust, Norwich, UK. Outcome Of 62 Clavicle Fracture Fixations With Locked Compression Plate: Is This The Right Way To Go? *Doi: 10.1016 / j.injury.2011.06.266.*
7. WgCdr V Kulshrestha. Primary Plating of Displaced Mid-Shaft Clavicular Fractures. *MJAFI* 2008; 64:208-211.
8. Chul-Hyun Cho, Kwang-Soon Song, Byung-Woo Min, Ki-Cheor Bae, Kyung-Jae Lee. Reconstruction Plate versus Reconstruction Locking Compression Plate for Clavicle Fractures. *Clinics in Orthopedic Surgery.* 2010; 2:154-159.
9. Robert Buchholz, James D Heckman. Charles Court-Brown, Rockwood Green's Fractures in Adults 6th Edition. 2006; 1:1213- 1216.
10. Stegeman *et al.* Displaced Midshaft Fractures of the Clavicle: Non-Operative Treatment Versus Plate Fixation (Sleutel-TRIAL). A Multicentre Randomised Controlled Trial. *BMC Musculoskeletal Disorders* 2011, 12:196.
11. Zenni EJ Jr, Krieg JK, Rosen MJ. Open reduction and internal fixation of clavicular fractures. *J Bone Joint Surg Am.* 1981; 63:147-51.
12. Jupiter JB, Leffert RD. Non-union of the clavicle. Associated complications and surgical management. *J Bone Joint Surg Am.* 1987; 69:753-60.
13. Iannotti MR, Crosby LA, Stafford P, Grayson G, Goulet R. Effects of plate location and selection on the stability of midshaft clavicle osteotomies: a biomechanical study. *J Shoulder Elbow Surg.* 2002; 11:457-62.
14. McKee, Wild LM, Schemitsch EH. Midshaft malunion of the clavicle. *J Bone Joint Surg Am.* 2003; 85:790-7.
15. McKee, Pedersen EM, Jones C, Stephen DJ, Kreder HJ, Schemitsch EH, *et al.* Deficits following non operative treatment of displaced midshaft clavicular fractures. *J Bone Joint Surg Am.* 2006; 88:35-40.
16. Canadian Orthopedic Trauma Society. Nonoperative treatment compared with plate fixation of displaced

- midshaft clavicular fractures. A multicenter randomized clinical trial. *J Bone Joint Surg Am.* 2007; 89(1):1-10.
17. Huang JI, Toogood P, Chen MR, Wilber JH, Cooperman DR. Clavicular anatomy and the applicability of precontoured plates. *J Bone Joint Surg Am.* 2007; 89:2260-5.
 18. Chul-Hyun Cho, Kwang-Soon Song, Byung-Woo Min, Ki-Cheor Bae, Kyung-Jae Lee. Reconstruction Plate versus Reconstruction Locking Compression Plate for Clavicle Fractures. *Clinics in Orthopedic Surgery.* 2010; 2:154-159.
 19. Darren S Drosdoweck. Frscs, Biomechanical Analysis of Fixation of Middle Third Fractures Of Clavicle, *Journal of Ortopaedic Trauma,* 2011.
 20. Craig EV, Basamania CJ, Rockwood CA. Fractures of the clavicle. Chapter-11, In : Rockwood CA, Matsen FA, Wirth MA, Lippitt SB, editors, *The shoulder.* 3rd edition Philadelphia: Saunders, 2004, 455-519.
 21. Lazarus. Fractures of the Clavicle. Chapter-26, In: Bucholz RW and Heckman JD, editors, *Rockwood and Green's fractures in adults,* 5th edition, Philadelphia: Lippincott Williams and Wilkins, 2001, 1041-1078.
 22. Wilk KE. The shoulder. Chapter-15, In Malone TR, McPoil TG, Nitz AJ, editors, *Orthopaedics and sports physical therapy,* 3rd edition, St. Louis: Mosby 1997; 401-409.
 23. Ruedi T, Duwelins PJ. Fractures and dislocations of the shoulder girdle and humerus. Chapter-15, In: Chapman MW, editor, *Chapaman' sorthopaedic Surgery,* Philadelphia, Lippincott Williams and Wilkins, 3rd edition 2001, 444-450.
 24. Robinson's CM. Fractures of the clavicle in the adult. Epidemiology and classification. *J Bone Joint Surgery (Br),* 1998; 80:476-484.
 25. Creashaw AH. Fractures of shoulder arm and forearm. Chapter- 54, In: Canale ST, editor. *Campbell's operative orthopaedics,* 10th edition, St. Louis, Mosby. 2003; 2985-3071.
 26. Geel CW. Scapula and clavicle. Chapter-4 In Colton CL, Dell'oca AF, Holz U, Kellam JF, Ochsner PE, editors. *AO Principles of fracture management,* New York: Thieme, 2000, 262-264.
 27. Bostman O, Manninen M, Pihlajamaki H. Complications of plate fixation in fresh displaced mid clavicular fractures. *J Trauma,* 1997; 43:778-783.
 28. Jupiter JB, Ring D. Fractures of the clavicle. Chapter- 26, In: Iannotti JP and Williams GR. editors. *Disorders of the Shoulder diagnosis and Management,* Philadelphia: Lippincott Williams and Wilkins 1999, 709-786.
 29. Gaudinez RF, Hoppenfeld S. Clavicle fractures. Chapter-10 In: Hoppenfeld S, Murthy VL, editors. *Treatment and Rehabilitation of fractures,* Philadelphia: Lippincott Williams and Wilkins, 2000; 73-84.
 30. Constant CR, Murley AHG. A clinical method of functional assessment of the shoulder. *Clinical orthopaedics and related research.* 1987; 214:160-164
 31. Labler L, Platz A, Weishaupt D, Trentz O. Clinical and functional results after floating shoulder injuries *J Trauma.* 2004; 57:595-602.
 32. Shen WJ, Liu TJ, Shen YS. Plate fixation of fresh displaced mid shaft clavicle fractures. *Injury.* 2000; 31(3):175-179.
 33. Hill JM, Mc Guire MH, Crosby LA. Closed treatment of displaced middle third fractures of the clavicle gives poor results. *J Bone Joint Surgery (Br),* 1997; 79:537-540.
 34. Nordqvist A, Petersson CJ, Redlund-Johnell. Mid clavicular fractures in adults: end result study after conservative treatment. *J Orthop Trauma.* 1998; 12:572-576.
 35. Robinson CM, Court Brown CM, McQueen MM, Walkefield AE. Estimating the risk of non union following non operative treatment of a clavicular fracture. *J Bone Joint Surgery (Am),* 2004; 86:1359-1365.
 36. Jiang H, Qu W. Comparison between MIPPO and Coventional open reduction, *Orthopedics and Traumatology: Surgery and Research.* 2012; 98(6):666-671.
 37. Neer CS. 2nd Nonunion of the clavicle. *J Am Med Assoc.* 1960; 172(10):1006-1011.
 38. Zlowodzki M, Zelle BA, Cole PA, Jeray K, McKee MD. Treatment of acute midshaft clavicle fractures: systematic review of 2144 fractures: on behalf of the Evidence-Based Orthopaedic Trauma Working Group. *J Orthop Trauma.* 2005; 19(7):504-507.