



International Journal of Orthopaedics Sciences

ISSN: 2395-1958
IJOS 2019; 5(1): 275-278
© 2019 IJOS
www.orthopaper.com
Received: 12-11-2018
Accepted: 16-12-2018

Dr. Rohan P Doshi
Senior Resident, Department of
Orthopaedics, C.U Shah Medical
College, Surendranagar, Gujarat,
India

Dr. Rajesh L Chachcha
Professor and Head of
Department Of Orthopaedics,
C.U Shah Medical College,
Surendranagar, Gujarat, India

Dr. Bhaumik Jesadiya
Senior Resident, Department Of
Orthopaedics, C.U Shah Medical
College, Surendranagar, Gujarat,
India

Dr. Rajdeepsinh H Chauhan
Consultant, Orthopaedic
Surgeon, Aayush Multispeciality
Hospital, Morbi, Gujarat, India

Dr. Kabir Desai
Senior Resident, Department Of
Orthopaedics, C.U Shah Medical
College, Surendranagar, Gujarat,
India

Dr. Baiju M Patel
Second Year Resident,
Department Of Orthopaedics,
C.U Shah Medical College,
Surendranagar, Gujarat, India

Correspondence

Dr. Rajesh L Chachcha
Professor and Head of
Department Of Orthopaedics,
C.U Shah Medical College,
Surendranagar, Gujarat, India

A study to compare the functional outcomes in diaphyseal fractures of humerus treated with intramedullary nailing vs plating in adults

Dr. Rohan P Doshi, Dr. Rajesh L Chachcha, Dr. Bhaumik Jesadiya, Dr. Rajdeepsinh H Chauhan, Dr. Kabir Desai and Dr. Baiju M Patel

DOI: <https://doi.org/10.22271/ortho.2019.v5.i1e.48>

Abstract

Introduction: Fracture of shaft of humerus is a common fracture of the upper limb which consists of 1-3% of all fractures. The most common method of fixation is open reduction internal fixation with plate and screw, and closed reduction with intramedullary nail fixation. The purpose of this study was to evaluate the clinical outcome of plate fixation versus intramedullary nail fixation. The study of fractures of shaft of humerus is important due to chances of these fractures to go in mal-union and non-union and the functional disability to the patient after these fractures being a hindrance in earning their daily living.

Material and Method: We randomly followed 50 cases of humeral shaft fracture of which 24 treated by closed reduction and intramedullary nailing and 26 treated with open reduction and plating. Union, functional outcome and complication were compared between both the groups. Evaluation of follow-up as per ASES (American shoulder and elbow surgeons) score was done on last follow-up.

Result: The average age of patient was 37.8 years; most common site was middle 1/3rd shaft of humerus. The average duration to achieve union with closed reduction and intramedullary nailing is 10.91 weeks and average duration of union with open reduction and plating was 12 weeks. Functional outcome was assessed by using ASES score value. The average ASES score for plating was 80.36 and that of nailing was 76.23. Complications like Non-union (12.5%), iatrogenic nerve injury (11.5) and infection (7.7%) were encountered in plate group where in IM nail group Non-union (12.5%), shoulder stiffness (16.6%) and impingement.

Conclusion: Functional outcome of Plating group is better than IM nail. Early mobilisation with IM nailing is advantage compare to plating. IM nail when used, one has to take precautions, like proper countersinking of the nail at entry point to prevent shoulder movement restriction, irrigation of entry point site to remove all reamed bone debris. Careful dissection of rotator cuff to prevent its damage.

Keywords: Diaphyseal fracture of humerus, compression plate, intramedullary nail, AO classification, union time, complications, functional outcome, ASES score

Introduction

Fracture of shaft of humerus is a common fracture of the upper limb which consists of 1-3% of all fractures^[1]. The study of fractures of shaft of humerus is important due to chances of these fractures to go in mal-union and non-union and the functional disability to the patient after these fractures being a hindrance in earning their daily living. Fractures of shaft humerus can be managed conservatively^[2-3] by hanging cast, U- plaster of Paris cast, high above elbow cast, U + high above elbow slab. But the problems with conservative methods are inability or loss of reduction, immobilization for long time, mal-union or non-union. Operative management is indicated for failure to obtain or maintain acceptable alignment. Operative management has many advantages which include anatomical reduction, stable fixation and early mobilisation leading to decreased morbidity. Once operative management with internal fixation is considered option of plate and screw fixation and intra-medullary nailing exist. Conventionally plate fixation required extensive open surgery with drainage of hematomas and stripping of soft tissue from bone. It also provides less secure fixation in osteoporotic bone and is associated with risk of infection and potential iatrogenic radial nerve injury^[4].

Closed intramedullary nailing can be done either by ante-grade or retrograde method. Various unlocked nails like Rush pins, Enders nail, Kuntscher nails have given a poor rate of union and lack rotational control. But with the availability of locked nails it is not so. Locked nails can be inserted using closed techniques, avoiding extensive soft tissue dissection required for plating. Disadvantage of intramedullary nail is restriction of shoulder range of motion^[5-6] and anaesthesia in regimental badge area, due to damage to upper cutaneous nerve of arm while inserting proximal locking screws.

Material and method

Prospective study of 50 cases of diaphyseal humeral fracture treated by closed reduction and intramedullary nailing or open reduction and plating took place at department of orthopaedics at C.U. Shah Medical College and Hospital, Surendranagar between 2013 and 2017. Patients with pathological fractures, distal neurovascular deficit, old fracture of shaft of humerus and Segmental humerus fractures were excluded from the study. All the cases were followed up for six month post operatively. All patients with acute, displaced fracture of shaft humerus and skeletally mature were included in study.

Surgical technique

Posterior approach was taken for plate fixation. Dissection involved separating lateral and long heads of triceps brachii supplied by radial nerve with identifying and protecting radial nerve and splitting of medial head of triceps brachii. Decision regarding length of plate and need for inter-fragmentary screw was taken based on fracture pattern.

Ante-grade insertion of intramedullary nailing was done. Dissection involved splitting deltoid and supraspinatus. Entry was made using the entry awl. Guide wire was inserted and canal was reamed with successive reamers. Proximal screws were inserted with the help of zig. And distal screw was inserted by freehand under image intensifier guidance.

All 50 patients showed acceptable alignment, in postoperative x-rays. Patients were given cuff and collar support, shoulder and elbow movements started as tolerated, flexion and extension exercise of shoulder and pendulum exercise allowed immediately post-operatively in plate group but rotation of arm allowed only after the appearance of visible callus formation, usually after 6 weeks. Passive flexion and abduction exercise of shoulder, flexion and extension exercise of elbow started on second postoperative day, rotational exercise started after soft callus formation in nail group. X-rays were taken at one month postoperatively and at one month intervals thereafter for at least six months. At final follow-up functional assessment was done between the plate and nail group based on ASES score.

Result

As shown in Table-1 We had 24 patients in nail group and 26 patients in plate group. The mean age of patients of nail group was 42.33 years and that of plate group was 33.62 years of this there were 18 male and 6 female patients in nailing group and 20 male and 6 female patients in plate group. Of these 13 patients were of left side and 11 of right side in nail group and 19 patients of left side and 7 patients of right side in plate group. The fractures were classified based on AO classification of which in nail group there were 19 patients

with type A, 4 patients with type B and 1 patient with type C fractures (Table-2). In plate group there were 20 patients with type A fracture, 5 patients with type B fracture and 1 patient with type C fracture (Table-2). Most of patients of nailing (91.67%) united within <16 weeks. 66.67% of patients united within <10 weeks. The average time of union was 10.91 weeks with nailing. The three patients which united after 16 weeks were actually failed nailing cases and revised with open reduction and plating. Most of patients in plating (88.46%) group united in <20 weeks, and 50% in <10 weeks. 3 patients in plate group went into non-union due to implant failure and were later revised with bone grafting and plating and united later at 20-30 weeks. Average union time for plating is 12 weeks.

In intramedullary nail 58.33% of patient had excellent upper limb functional status at end of treatment with ASES 46-52. 29.17% of patients had ASES score of 42-46 which is also good upper limb functional status. Only 12.5% had ASES 36-41 which implies to fair functional upper limb (Table-3). For plating 84.62% of patients had ASES score 46-52 which implies excellent upper limb function. 7.69% of patients had ASES score of 42-46 which is also good upper limb function. Only 7.69% had ASES score 36-41 which implies to fair functional upper limb (Table-3). The p value is statistically significant thus plate has better ASES score than nail.

Most common complications with intramedullary nail are shoulder stiffness in 4 (16.66%) cases. In 3(12.5%) cases non-union was observed. Superficial infection was seen in 1(4.16%) case which was treated with regular dressing and antibiotics. 1(4.16%) case had anaesthesia in regimental badge area due to trauma to upper lateral cutaneous nerve of arm (Table-4). The most significant complication of plating was iatrogenic radial nerve injury in 3(11.5%) cases. 2nd most common complication was non-union in 2(7.7%) cases and superficial infection in 2(7.7%) cases (Table-4).

Table 1: 24 patients in nail group and 26 patients in plate group.

	Nail	Plate
No. of patients	24(48%)	26(52%)
Age (mean)	42.33 years	33.62 years
Sex		
-Male	18(75%)	20(76.92%)
-female	6(25%)	6(23.08%)
Side of affected limb		
-Left	13(54.16%)	19(73.07%)
-Right	11(45.84%)	7(26.93%)
Union time (mean)	10.91 weeks	12 weeks
ASES score (mean)	76.23	80.36

Table 2: AO classification of Fracture shaft of humerus

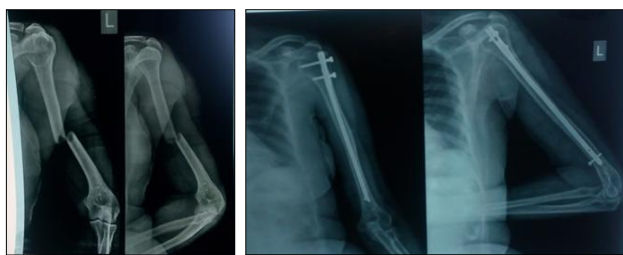AO Type	Nail	Plate
Type A (simple non-comminuted)	19	20
A1 (spiral fracture)	6	1
A2 (oblique fracture)	7	8
A3(transverse fracture)	6	11
Type B (fracture with butterfly fragment)	4	5
B1 (spiral fracture)	0	2
B2 (bending wedge)	4	3
B3 (wedge with more than one fragment)	0	0
Type C (comminuted fractures)	1	1
C1 (double spiral fracture)	1	0
C2 (segmental fracture)	0	0
C3 (complex fracture)	0	1

Table 3: Comparison of functional assessment in both the groups.

Ases Score	II Nail	Plate
46-52	14(58.33%)	22(84.62%)
42-46	7(29.17%)	2(7.69%)
36-41	3(12.5%)	2(7.69%)
31-35	-	-
<30	-	-
	24	26

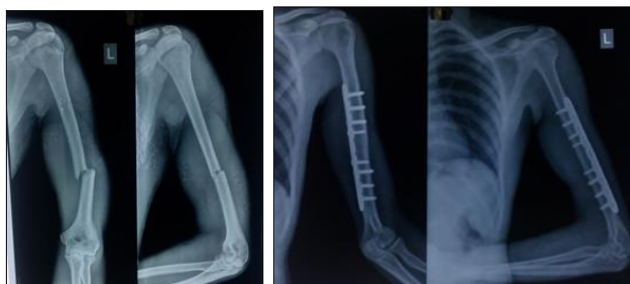
Table 4: Complication with nailing and plating

Complication	Nail	Plate
Infection		
-Superficial	1(4.6%)	2(7.7%)
-Deep	0(0%)	0(0%)
Delayed Union	0(0%)	1(3.84%)
Non Union	3(12.5%)	2(7.7%)
Iatrogenic Radial Nerve Injury	0(0%)	3(11.5%)
Shoulder Stiffness	4(16.66%)	0(0%)
Anaesthesia In Regimental Badge Area	1(4.16%)	0(0%)



Pre-operative

Post-operative at final follow-up

Fig 1: IM Nail

Pre-operative

Post-operative (final follow-up)

Fig 2: Compression plate

Discussion

Conservative management showed union rate in more than 90% of cases [2-3]. Results of treatment with plate and screw fixation were good [4, 7, 8]. If the fracture goes into non-union, the surgery revised with plating or nailing with autogenous bone-graft gives result which is acceptable [8-9-10]. Studies show restricted shoulder movement in ante-grade nailing either due to impingement of nail tip or rotator cuff damage [11-12-13]. Reaming of medullary canal facilitates healing but in spite of that non-union can occur in nailing [14-15-16]. Exchange nail or revision surgery with plate can be taken into account as a treatment for delayed or non-union [9, 10, 17].

Most of patients of shaft humerus fracture treated with intramedullary nailing (91.67%) united within <16 weeks. 66.67% of patients united within <10 weeks. The average time of union was 10.91 weeks as compared with Crolla *et al* which was 9 weeks [18]. Most of patients of shaft humerus fracture treated with plating (88.46%) united in less than 20 weeks and 50% united in less than 10 weeks. The average union time was 12 weeks as compared with study by Foster *et*

al which was 14 week [19]. We observed non-union in 3 cases of nail group, we labelled it non-union after 6 months of initial fixation and these cases were re-operated with removal of implant and plating with autogeneous bone-grafting this can be compared with study by Chao *et al.* [20] who also had non-union in 3 cases out of total 24 patients treated with nailing. The reason for non-union in our study was believed to be distraction at fracture site at time of primary fixation in 2 cases and in 1 case it is believed to be soft-tissue interposition as it can be found in close reduction technique. We observed 2 cases of non-union in plate group, which was re-operated with removal of implant and re-plating with bone-grafting this can be compared with study by Chao *et al.* [20] who had 3 patients out of total 36 patients in plating. We observed solid union after 20-30 weeks of reoperation who were treated with autogenous bone grafting. Another significant complication was iatrogenic radial nerve injury which occurred in 3 cases of plate group which as compared to study by Denies *et al.* [21] who had 4 out of 42 cases treated with plate, in our case the palsy was fully recovered after 3 months of surgery. It was observed that there was no iatrogenic radial nerve injury in nail group. We observed 16.66% cases of shoulder stiffness in nailing group which is lower than Denies [21] who observed same in 21.4% cases. It is believed that this was due to impingement of nail for which physiotherapy was done, no such cases was seen in plate group. We observed superficial infection in 1 case of nail group and 2 cases in plate group both of which were treated with regular dressing. Patients treated with intramedullary nail had excellent upper-limb functional status at the end of treatment in 58.33% cases with ASES 46-52. 29.17% of patients had ASES score of 42-46 which is also a good functional upper limb status. Only 12.5% had ASES 36-41 which implies to fair functional upper limbs. For plating 84.62. % of patients had ASES score 46-52 which implies excellent upper limb function. 7.69% had ASES score 42-46 which is also a good functional upper limb. Only 7.69% had ASES score of 36-41 which implies to fair functional upper limb. There is significant difference of functional outcome between nailing and plating groups in which plate has better functional outcome than nail probably because of impingement of nail and rotator cuff injury during its insertion. Anatomical reduction, Stable fixation, adequate blood supply and soft tissue preservation are important factors for union. Plate fixation of fracture shaft of humerus required extensive soft tissue dissection as well as dissection of radial nerve which carries risk of infection, soft tissue stripping and radial nerve paresis or palsy. intramedullary nail require minimal incision which carries minimal risk of infection, it provide stable fixation for simple as well as comminuted fractures. Entry site of intramedullary nail has to be accurate so that post-operative impingement of nail should not occur. Early mobilisation hastens union by allowing hydrodynamic forces of muscle to enhance blood supply and encourage organisation of healing granuloema by allowing stress forces to function. Though patients with plating have better shoulder function than antegrade nailing, it is to some extent due to uncooperative patients, pain or impingement of rotator cuff by nail. But this restriction can be corrected by removal of nail after consolidation followed by mobilization and physiotherapy.

Declaration

1. I confirm that I have read, understand and agreed to the submission guidelines, policies and submission declaration of the journal.

2. I confirm that all authors of the manuscript have no conflict of interests to declare.
3. I confirm that the manuscript is the authors' original work and the manuscript has not received prior publication and is not under consideration for publication elsewhere.
4. On behalf of all Co-Authors, I shall bear full responsibility for the submission.
5. I confirm that all authors listed on the title page have contributed significantly to the work, have read the manuscript, attest to the validity and legitimacy of the data and its interpretation, and agree to its submission.
6. I confirm that the paper now submitted is not copied or plagiarized version of some other published work.
7. I declare that I shall not submit the paper for publication in any other Journal or Magazine till the decision is made by journal editors.
8. If the paper is finally accepted by the journal for publication, I confirm that I will either publish the paper immediately or withdraw it according to withdrawal policies.
9. I understand that submission of false or incorrect information/undertaking would invite appropriate penal actions as per norms/rules of the journal.
10. I confirm that patients participated in this study were gave their written and informed consent to participate and their data has been kept confidential.

Abbreviations: ASES – American Shoulder and Elbow Surgeons, AO - Arbeitsgemeinschaft für Osteosynthesefragen, IM nail: Intramedullary Nail

References

1. Ekholm R, Adami J, Tidermark J. Fractures of the shaft of the humerus. An epidemiological study of 401 fractures. *J Bone Joint Surg.* 2006; 88-B:1469-1473.
2. Sarmiento A, Zagorski JB, Zych GA, Latta LL, Capps CA. Functional bracing for the treatment of fractures of the humeral diaphysis. *J Bone Joint Surg.* 2000; 82-A:478-486.
3. Wallny T, Sagebiel C, Westerman K, Wagner UA, Reimer M. Comparative results of bracing and interlocking nailing in the treatment of humeral shaft fractures. *Int Orthop.* 1997; 21:374-379.
4. Lin J. Treatment of humeral shaft fractures with humeral locked nail and comparison with plate fixation. *J Trauma.* 1998; 44:859-864.
5. Lin J, Shen PW, Hou SM. Complications of locked nailing in humeral shaft fractures. *J Trauma.* 2003; 54:943-949.
6. Simon P, Jobard D, Bistour L, Babin SR. Complications of Marchetti locked nailing for humeral shaft fractures. *IntOrthop.* 1999; 23:320-324.
7. Chapman JR, Henley MB, Agel J, Benca PJ. Randomized prospective study of humeral shaft fracture fixation: intramedullary nails versus plates. *J Orthop Trauma.* 2000; 14:162-166.
8. McCormack RG, Brien D, Buckley RE, Mckee MD, Powell J, Schemitsch EH. Fixation of fractures of the shaft of the humerus by dynamic compression plate or intramedullary nail: a prospective, randomized trial. *J Bone Joint Surg Br.* 2000; 82:336-339.
9. Kumar A, Sadiq SA. Non-union of the humeral shaft treated by internal fixation. *Int Orthop.* 2002; 26:214-216.
10. Martinez AA, Cuenca J, Herrera A, Treatment of humeral shaft nonunions: nailing versus plating. *Arch Orthop*

Trauma Surg. 2004; 124:92-95.

11. Flinkkila T, Hyvonen P, Lakovaara M, Linden T, Ristiniemi J, Hamalainen M. Intramedullary nailing of humeral shaft fractures. A retrospective study of 126 cases. *Acta Orthop Scand.* 1999; 70:133-136.
12. Hall RF, Pankovich AM. Ender nailing of acute fractures of the humerus. *J Bone Joint Surg Am.* 1987; 69:558-567.
13. Liebergall M, Jaber S, Laster M, Abu-Snieneh K, Mattan Y, Segal D. Ender nailing of acute humeral shaft fractures in multiple injuries. *Injury.* 1997; 28:577-580.
14. Fernandez FF, Matschke S, Hulsenbeck A, Egenolf M, Wentzensen A. Five years clinical experience with the undreamed humeral nail in the treatment of humeral shaft fractures. *Injury.* 2004; 35:264-271.
15. Lin J, Hou SM. Locked nailing of severely comminuted or segmental humeral fractures. *Clin Orthop.* 2003; 406:195-204.
16. Sanzana ES, Dümmer RE, Castro JP, Díaz EA. Intramedullary nailing of humeral shaft fractures. *Int Orthop.* 2002; 26:211-213.
17. Wenzl ME, Porte T, Fuchs S, Faschingbauer M, Jurgens C. Delayed union and non-union of the humeral diaphysis - compression plate or internal plate fixation. *Injury.* 2004; 35:55-60.
18. Crolla LMPH, Vries LS, Cleners SJ. Locked intramedullary nailing of humerus fractures; Injuries; *International Journal of the care of the injured.* 1993; 24(6):403-5.
19. Foster RJ, Dixon GL, Bach AW, Appleyard RW, Green TM. Internal fixation of fractures and non-unions of the humeral shaft. Indications and results in a multi-center study. *J Bone Joint Surg Am.* 1985; 67:857-64.
20. Chao TC, Chou WY, Chung JC, Hsu CJ. Humeral shaft fractures treated by dynamic compression plates, Ender nails and interlocking nails. *SICOT.* 2005; 29:88-91.
21. Denies E, Nijs S, Sermon A, Broos P. Operative treatment of humeral shaft fractures. Comparison of plating and intramedullary nailing *Acta Orthop. Belg.* 2010; 76:735-742.