



ISSN: 2395-1958  
IJOS 2019; 5(1): 194-199  
© 2019 IJOS  
www.orthopaper.com  
Received: 17-11-2018  
Accepted: 20-12-2018

**Dr. Ravi Kiran Kakumanu**  
Assistant Professor NRI  
Institute of Medical Sciences,  
Sangivalasa, Visakhapatnam,  
Andhra Pradesh, India

**Dr. Dinesh Golla**  
Assistant Professor, NRI  
Institute of Medical Sciences,  
Sangivalasa, Visakhapatnam,  
Andhra Pradesh, India

## Analysis of the functional outcome in patients following mini-open Latarjet procedure for the treatment of anterior instability of shoulder

**Dr. Ravi Kiran Kakumanu and Dr. Dinesh Golla**

DOI: <https://doi.org/10.22271/ortho.2019.v5.i1d.37>

### Abstract

More than 200 different operations have been described for the treatment of recurrent anterior dislocation of shoulder. The Latarjet procedure employs re-routing of the osteotomised coracoid process with its attached conjoined tendon through a split in the substance of sub scapularis and fixed to the antero inferior aspect of glenoid rim. The present study is done to analyse the functional outcome of Latarjet procedure by mini-open technique in recurrent anterior shoulder dislocations with or without bony Bankart lesion/ Hillsachs lesion. A total of 25 (23 men and 2 women). patients managed by mini open Latarjet technique with a 4-5 cms long incision(3cm in young females) and splitting the subscapularis tendon were followed up for a minimum of one year. Patients were evaluated using ROWE instability score, Oxford Shoulder Instability index Score at the last follow up. The mean external rotation achieved was 60 degrees (45-70 degrees). Mean abduction was 160 deg (150-180 deg). There was no single episode of recurrence of dislocation or subluxation, all the patients regained preoperative range of motion. Mean ROWE score is 90(excellent) & mean oxford shoulder instability index is 38.1(good). One patient has developed fibrous union (4%). None has developed osteoarthritic changes. The classic Open Latarjet procedure results in a large scar and decreased external rotation. Adequate exposure can be obtained by a mini open incision with splitting of the subscapularis. In our technique we split subscapularis at its distal edge in order to place the bone block in right position only splitting of the subscapularis tendon leads to better outcomes with a smaller scar. Latarjet procedure is an excellent surgical option for recurrent shoulder instability associated with glenoid bone deficiency with or without engaging hill Sachs lesion.

**Keywords:** Recurrent shoulder dislocation, mini-open Latarjet procedure, corocoid process, rowe score

### 1. Introduction

Anterior shoulder instability has been reported to occur at one of the highest rates (0.12 per 1000 exposures) in collegiate athletes <sup>[1]</sup>. It occurs most frequently in the 20 – 40 years of age. It is a difficult clinical problem and is treated by a variety of open and arthroscopic methods with good results Glenoid bone loss is commonly observed in anterior instability and varies greatly in both its extent and significance <sup>[2, 3]</sup>. Nonoperative management of glenohumeral instability has been associated with high rates of recurrence with recurrence rates ranging from 37% to 85%. <sup>[3-7]</sup> Arthroscopic stabilization procedures have been similarly associated with recurrent instability, with recurrence rates ranging from 10.8% to 21.1% <sup>[8-11]</sup>. Bankart repair remains a popular option, but it addresses only soft tissue deficiency using suture anchors. However, the situations involving irreparable ligamentous damage or bony deficiency, this technique may be insufficient to stabilize the shoulder. The Latarjet procedure is a reliable method of treatment for anterior instability, with good results reported in many studies <sup>[12-14]</sup>. It is effective in situations in which soft-tissue reconstruction is not a reasonable option <sup>[15]</sup>. The use of the coracoid process to stabilise the shoulder was first described by Oudard <sup>[16]</sup> in 1923. The Screwing of the coracoid process on to the antero-inferior side of the glenoid at the level of the anterior glenoid rim was described by Latarjet <sup>[17]</sup> in 1954. Helfet <sup>[18]</sup> in 1958 described the Bristow procedure in which the coracoid process was merely sutured to the anterior part of the scapular neck through a transversally sectioned subscapularis muscle.

**Correspondence**  
**Dr. Dinesh Golla**  
Assistant Professor NRI  
Institute of Medical Sciences,  
Sangivalasa, Visakhapatnam,  
Andhra Pradesh, India

Mead and Sweeney [19] in 1964, and May [20] in 1970, described a modification of the Bristow Helfet procedure that consisted of fixing the bone block to the anterior glenoid rim with a screw. In mini-open technique incision is limited to 4-5 cm and when it is possible to 3 cm. In this technique we do not cut the subscapularis tendon but we split the tendon at its distal edge in order to place the bone block in right position. This allows a fast recovery without any post-operative immobilization.

### 1.1 Objectives of the study

- A. To evaluate the clinical outcome associated with this treatment modality in terms of Range of Motion of Shoulder, Apprehension Relief, Pain Relief, Return to normal activities and to assess the reoccurrence of Anterior Instability of Shoulder.
- B. To evaluate Effectiveness & Complication of Latarjet Procedure for treatment of Recurrent Anterior Instability of Shoulder.

## 2. Materials and Methods

The study is a clinical, prospective and observational study conducted at NRI institute of medical sciences, Orthopaedics department between November 2016 to June 2018 with recurrent episodes of anterior shoulder dislocation were evaluated clinically and radiologically (antero-posterior view, trans-axillary lateral view, scapular y view, CT Scan and MRI Scan). A total of 25 patients (23 male and 2 female) with mean age at the time of surgery was 22.2 years (18-30 years), steps in the data collection are,

1. History by Verbal communication with patients and their attendees
2. Clinical examination, both local and systemic.
3. Diagnosis: Clinical and Radiological.
4. Base line investigation.
5. Basic Radiological Examination.(X-Ray, CT,MRI Scans)
6. Surgical Findings.
7. Routine Antibiotics and Analgesics/ Anti-inflammatory drugs.
8. Post-Operative evaluation by clinical and radiological examination.
9. Post operatively wound healing, complications, time for union, weight bearing, range of motion of Shoulder joint, mobilization will be assessed.

### 2.1 The secondary parameters observed will be as follows

1. Duration between last Dislocation Incident and the day of Surgery.
2. Duration from the day of surgery to mobilization.
3. Infection rates.
4. Duration of stay at hospital.
5. Graft Rejection rates
6. Secondary surgeries.

### 2.2 Inclusion criteria

- Recurrent Shoulder Dislocation due to significant bony defect of Glenoid. (Glenoid Index less than or equal to 0.76)
- Recurrent Shoulder Dislocation with Bony Bankart.
- Recurrent Shoulder Dislocation with Anterior Instability with previous surgical Repair.
- Patients with epilepsy with Recurrent Shoulder Dislocation.
- Recurrent Shoulder Dislocation with Humeral Avulsion of Glenohumeral Ligament Lesion.

### 2.3 Exclusion Criteria

- Patients with Recurrent Shoulder Dislocation with Glenoid Index More than 0.76.
- Any Anterior Dislocation Along with any Associated Fracture
- Single Episode of Shoulder Dislocation.
- Posterior Instability of Shoulder.
- Patients of age group < 18 years.
- Patient with Bankart Lesions or SLAP (Superior Labral Anterior Posterior) Lesions.
- Patients managed conservatively for other medical reasons.

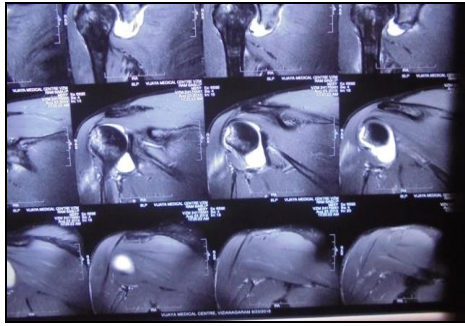
### 2.4 Mini-Open Latarjet Procedure

Patient is placed in beach chair position. A limited deltopectoral approach is used. A 3-5 cms incision was given over the deltopectoral groove extending from the tip of the coracoid process towards the Axilla. The Cephalic vein was identified and retracted laterally and an interval between the deltoid and the pectoralis was made. Corocoid process with its attached conjoint tendon identified the superior surface of the coracoid process was cleared and a blunt retractor was placed at the knee of the coracoid to allow for better visualization. Multiple drill holes were made at the base of the coracoid process in a medial to lateral direction to avoid neurovascular injury. The osteotomized coracoid process was then cleared off the coracohumeral ligament inferiorly to allow for better excursion.

The lower margin of the Subscapularis was identified with the help of neurovascular structures. Subscapularis muscle is split horizontally at the junction of upper two thirds and lower one third near the musculo-tendinous junction and the capsule was incised vertically. Osteotomised corocoid was placed over the glenoid defect and fixed with two 4 mm cannulated cancellous screws and wound closed in layer. Shoulder was immobilised in arm pouch for a period of one week and post-operative physiotherapy started after 1week in the form of all movements except extreme abduction and external rotation. Patients were discharged on day 10 after suture removal. The patients were followed up at 3 weeks, 6 weeks and 12 weeks. Mean follow up period was 1 year (6 months to 2 years). Post-operative shoulder function was evaluated using ROWE and OSII scores. The results were presented as mean and median.

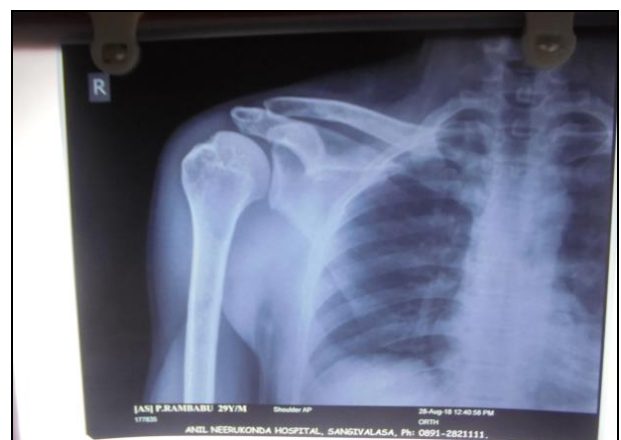

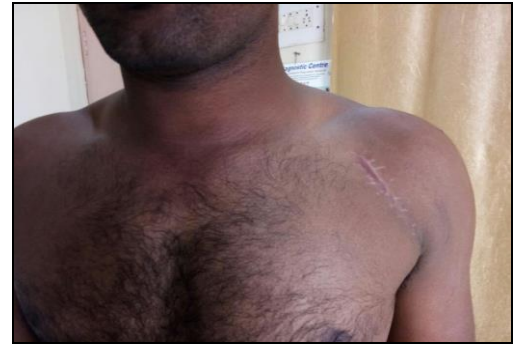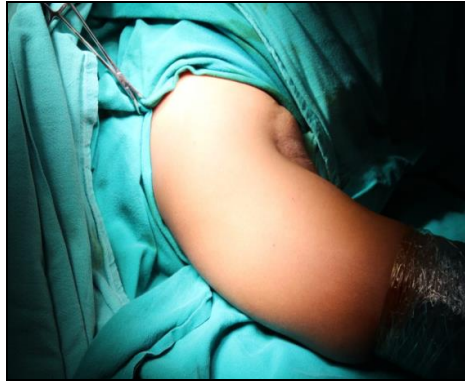Fig 1: Pre-op xray



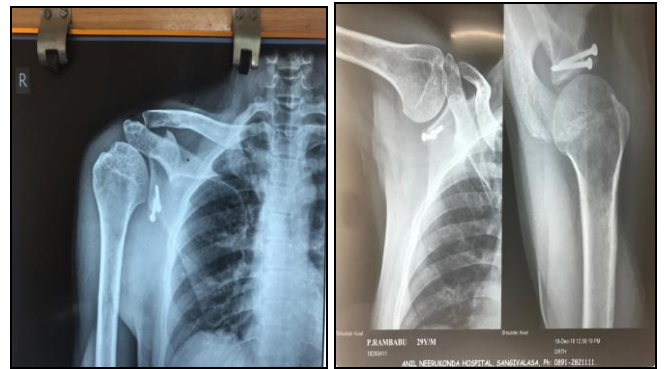
**Fig 2:** MRI showing hill-sach lesion



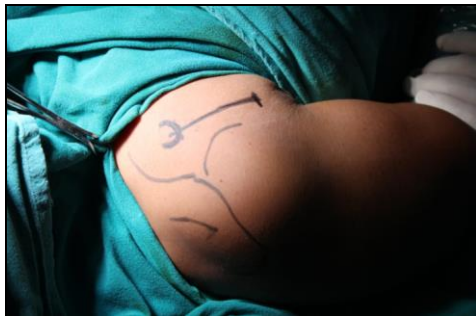**Fig 7:** Post-Operative Scar



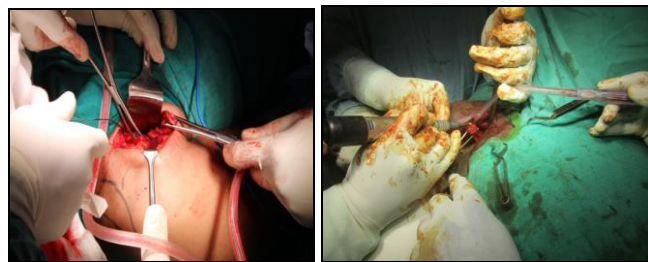
**Fig 3:** Positioning



**Fig 8:** Post Op xrays at final follow Up



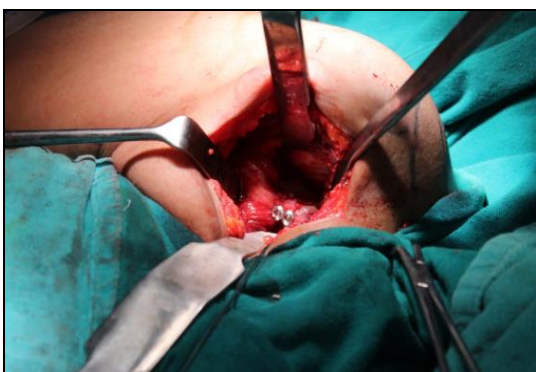**Fig 4:** Bony Land Marks & Incision Size



**Fig 5:** Conjoint tendon identified, corocoid osteotomy & corocoid preparation



**Fig 9:** Full Rom at Final Follow-Up



**Fig 6:** Final coracoid screw fixation

### 3. Results

All patients were followed for a period of average 1 year (6 months to 2 years), during this period no patient had recurrence of shoulder dislocation. Post-operative range of motion of shoulder was almost fully achieved. Mean abduction was 160 deg (150-180 deg), mean external rotation loss was 20 deg (15-25 deg). The mean external rotation



achieved was 60 degrees (45-70 degrees). The mean abduction achieved was 160 degrees (130-174), mean flexion of 80 degrees (60-90) and mean internal rotation of 80 degrees (70-90). All patients had a positive apprehension test pre operatively and all these patients found to have a negative apprehension test post operatively. The functional outcome assessed as per the mean ROWE score was found to be excellent (90-100) in 16 patients (64%) and good (28%) in 7

& fair in (8%) 2 patients. Mean OSII score was 38.1(28-44), mean ROWE score was 90 (70-100). 24 of the 25 patients had excellent to good results and 1 patient had fair result based on ROWE and OSII score. One patient has developed fibrous union (4%).

At the latest follow up all the post-operative radiographs had shown good union of corocoid process and none had osteoarthritic changes.

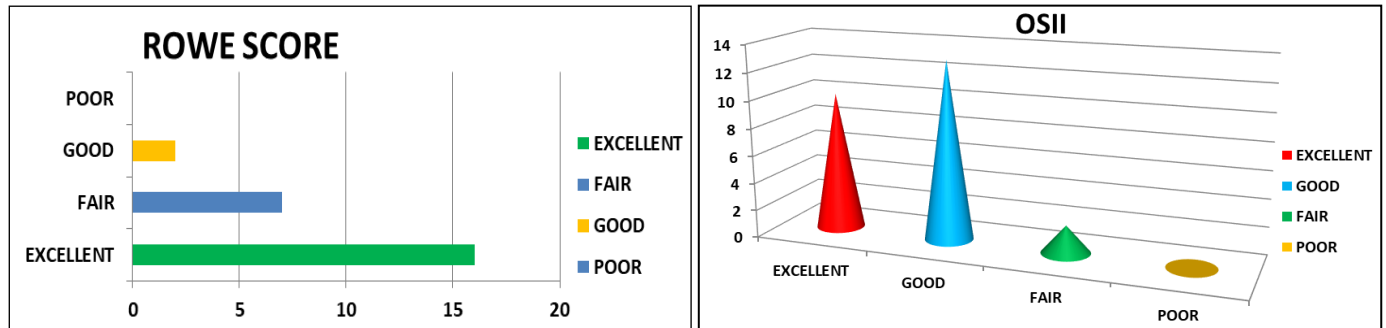


Fig 10: OSII Score

#### 4. Discussion

The open or arthroscopic bankarts repair gives poor results if glenoid bone loss was the major contributing factor for recurrent dislocation of shoulder. The Latarjet procedure is a useful form of treatment for patients with recurrent anterior dislocation of the shoulder<sup>[21, 22]</sup>.

The stability is achieved by the following three effects:

1. The creation of a sling mechanism by the conjoint tendon by compressing the subscapularis tendon and antero-inferior part of capsule, against the humeral head.
2. The restoration of the anterior glenoid rim by the transposed coracoid process.
3. Repair of the capsule, which is performed using the stump of the resected coraco-acromial ligament.

The classical Latarjet procedure uses an incision of 8-10 cms with cutting of the subscapularis tendon off the lesser tuberosity. This resulted in a large scar and decreased external rotation. The mini open Latarjet procedure keeps the incision to a minimum using the skin elasticity for exposure. The fixation can be done adequately even without causing much damage to the subscapularis tendon. This procedure yields Excellent long-term results, with low rates of redislocation.

**4.1 Range of Motion:** Loss external rotation, has long been a criticism of the modified Bristow- Latarjet procedure. Most authors have reported that a mean loss of 9° to 12° of external rotation<sup>[23-24]</sup>, and some have reported external rotation losses of up to 20°<sup>[25-26]</sup>. In the present study there is no significant loss of range of motion especially on external rotation. We achieved a mean of 60 degrees of external rotation in our study which is similar to the results attained by Hovelius *et al*<sup>[27]</sup>. This was probably because we protected the subscapularis tendon during surgery. An immediate postoperative rehabilitation is also a contributing factor for good results.

**4.2 Satisfaction:** According to Rowe or OSII scores the rates of excellent and good results go from 69% to 93%. In the present study the Mean OSII score was 38.1 (28-44), mean ROWE score was 90 (70-100).

**4.3 Recurrent Instability:** In Bristow-Latarjet procedure recurrent instability rate reported as 0% to 5.4%. Hill *et al.*<sup>[28]</sup>

reported a rate of redislocation of 3% and a rate of subluxation of 6%. Allain *et al.*<sup>[29]</sup> reported no recurrent dislocation but subjective subluxation in 1 of 58 shoulders (2%) at a mean follow-up of 14.3 years. Hovelius *et al.*<sup>[30]</sup> reported a recurrence rate of 4% and a subluxation rate of 9%. Matthes *et al* reported no subluxation rate in 29 cases for 38 month follow-up period. In our study, no patients had any incidence of dislocations at final follow up.

**4.4 Gleno-humeral Arthritis:** It is probably as a result of initial traumatic shoulder dislocation. Hovelius *et al* in their series arthropathy after primary anterior shoulder dislocation in 223 cases for 5 years follow up concluded that, the risk increases with the age of the first dislocation, alcohol abuse, high energy sports and the number of recurrence<sup>[31]</sup>. The main factor classically associated with significant degenerative changes after the Latarjet procedure is an over-hanging position of the bone block<sup>[32]</sup>. None of the patient in our study developed osteoarthritic changes

**4.5 Bone Block Position and Screw Fixatio:** Allain *et al.*<sup>[29]</sup> observed 53% too lateral bone blocks and 5% too medial bone blocks. Hovelius *et al.*<sup>[33]</sup> found 36% malpositioned bone blocks above the equator and 6% too medially placed bone blocks. Huguet *et al.*<sup>[34]</sup> found 45% of the grafts overhanging in the joint. All of these studies showed the final result depends on graft position.

That is, a too lateral or overhanging bone block leads to arthritis in more or less long term. A too medial bone block will result in recurrent instability, and a bone block located above the equator also exposes the joint to recurrent dislocation<sup>[33]</sup>. We noticed medialization of grafts in two patients and lateralization in none.

**4.6 Nonunion rates:** Griesser *et al*<sup>[35]</sup> in their systematic review of 1904 shoulders reported a non-union rate of 9.1%. There have also been studies<sup>[36]</sup> that have reported non-union rates as low as 1.7%. We used 4mm lag screws used to fix bone block to yield good results. Small grafts were managed using a screw with a washer over the margin of the coracoids graft along with proximal screw fixation to prevent rotation. None of the patients has developed non-union. One patient has developed fibrous union.

**Table 1:** Studies of patient/number subluxation

Studies	Patient\Number	Subluxation\Rates	Rowe\Excellent	Rowe\Good	Rowe\Fair	Rowe\Poor
Banas <i>et.al</i> <sup>37</sup> 1993	79	4	74	11	9	6
Singer <i>et.al</i> <sup>38</sup> 1995	14	0	36	57	7	1
Pap <i>et.al</i> <sup>39</sup> 1997	31	3	45	39	6	10
Hovellius <i>et al</i> <sup>40</sup> 2004	118	4	71	15	11	4
Matthes <i>et.al</i> <sup>41</sup> 2007	29	0	59	24	10	7
Dossim <i>et.al</i> <sup>42</sup> 2008	84	98	30	43	16	11
Edouard <i>et.al</i> <sup>43</sup> 2010	20	21	95	0	0	5
DiGiacomo <i>et.al</i> <sup>44</sup> 2011	26	17	69	23	8	0
Rao <i>et.al</i> <sup>45</sup> 2014	30	0	60	30	10	0
Our study 2018	25	0	64	28	8	0

## 5. Conclusion

Anterior stabilization of the gleno-humeral joint by means of the Latarjet procedure continues to be a viable treatment option in selected patients with post-traumatic anterior shoulder instability. The results reported in literature show an early rehabilitation, a low rate of recurrence with excellent to good subjective out-comes. With good clinical and radiological evaluation more complex lesions like bony bankarts and bankarts with associated hill-sachs lesion can be identified and successfully treated by latarjet procedure. In mini-open technique we limit the approach to 4 or 5 cm and when it is possible to 3 cm, especially, in thin women. It leads to better outcomes and a more acceptable scar. The use of a cobra retractor intra operatively across the glenoid rim helps for better exposure of the antero inferior glenoid rim and proper placement of the coracoid graft. In our technique we do not cut the subscapularis tendon but we split the tendon at its distal edge in order to place the bone block in right position. This allows a fast recovery without any post-operative immobilization. However, a limited sample size and limited follow up of our patients are the limitations of our study.

## 6. References

- Owens BD, Agel J, Mountcastle SB, Cameron KL, Nelson BJ. Incidence of glenohumeral instability in collegiate athletics. *Am J Sports Med.* 2009; 37(9):1750-1754.
- Edwards TB, Boulahia A, Walch G. Radiographic analysis of bone defects in chronic anterior shoulder instability. *Arthroscopy.* 2003; 19:732-739. Edwards TB, Boulahia A, Walch G. Radiographic analysis of bone defects in chronic anterior shoulder instability. *Arthroscopy.* 2003; 19:732-739.
- Itoi E, Lee SB, Berglund LJ, Berge LL, An KN. The effect of a glenoid defect on antero inferior stability of the shoulder after Bankart repair: a cadaveric study. *J Bone Joint Surg Am.* 2000; 82:35-46.
- Hovellius L, Olofsson A, Sandstrom B *et al.* Nonoperative treatment of primary anterior shoulder dislocation in patients forty years of age and younger. a prospective twenty-five-year follow-up. *J Bone Joint Surg Am.* 2008; 90:945-952
- Arciero RA, Wheeler JH, Ryan JB, McBride JT. Arthroscopic Bankart repair versus nonoperative treatment for acute, initial anterior shoulder dislocations. *Am J Sports Med.* 1994; 22:589-594
- Buss DD, Lynch GP, Meyer CP, Huber SM, Freehill MQ. Nonoperative management for in-season athletes with anterior shoulder instability. *Am J Sports Med.* 2004; 32: 1430-1433
- Roberts SB, Beattie N, McNiven ND, Robinson CM. The natural history of primary anterior dislocation of the glenohumeral joint in adolescence. *J Bone Joint Br.* 2015; 97:520-526
- Balg F, Boileau P. The instability severity index score. A simple pre-operative score to select patients for arthroscopic or open shoulder stabilisation. *J Bone Joint Surg Br.* 2007; 89:1470-1477
- Burkhart SS, De Beer JF. Traumatic glenohumeral bone defects and their relationship to failure of arthroscopic Bankart repairs: Significance of the inverted-pear glenoid and the humeral engaging Hill-Sachs lesion. *Arthroscopy.* 2000; 16:677-694
- Boileau P, Villalba M, Hery JY, Balg F, Ahrens P, Neyton L. Risk factors for recurrence of shoulder instability after arthroscopic Bankart repair. *J Bone Joint Surg Am.* 2006; 88:1755-1763
- An VV, Sivakumar BS, Phan K, Trantalis J. A systematic review and meta-analysis of clinical and patient-reported outcomes following two procedures for recurrent traumatic anterior instability of the shoulder: Latarjet procedure vs. Bankart repair. *J Shoulder Elbow Surg.* 2016; 25:853-863
- Chen AL, Hunt SA, Hawkins RJ, Zuckerman JD. Management of bone loss associated with recurrent anterior glenohumeral instability. *Am J Sports Med.* 2005; 33:912-925
- Yoneda M, Hayashida K, Wakitani S, Nakagawa S, Fukushima S. Bankart procedure augmented by coracoid transfer for contact athletes with traumatic anterior shoulder instability. *Am J Sports Med.* 1999; 27:21-26.
- Nourissat G, Nedellec G, O'Sullivan NA *et al.* Mini-open arthroscopically assisted Bristow-Latarjet procedure for the treatment of patients with anterior shoulder instability: A cadaver study. *Arthroscopy.* 2006; 22:1113-1138.
- Burkhart SS, De Beer JF, Barth JR, Cresswell T, Roberts C, Richards DP. Department of Orthopaedic Surgery, University of Texas Health Science Center at San Antonio, San Antonio, Texas, USA.
- Oudard M. La luxation récidivante de l'épaule, procédé opératoire. *J Chir.* 1923; 23:13-25 (in French).
- Latarjet M. Treatment of recurrent dislocation of the shoulder. *Lyon Chir.* 1954; 49:994-1003.
- Helfet AJ. Coracoid transplantation for recurring dislocation of the shoulder. *J Bone Joint Surg [Br]* 1958; 40:B198-202.
- Mead NC, Sweeney HJ. Bristow procedure. *Spectator letter.* The Spectator Society, 1964.
- May VR. A modified Bristow operation for anterior recurrent dislocation of the shoulder, *Journal of Bone and Joint Surgery A.* 1970; 52(5):1010-1016.
- Patte D, Debeyre J. Luxations recidivantes del'épaule.

- Paris-Technique chirurgicale. Orthopedie. Encycl Med Chir. 1980; 44265:44-52.
22. Itoi E, Lee SB, Berglund LJ *et al.* The effect of a glenoid defect on anteroinferior stability of the shoulder after Bankart repair: a cadaveric study. *J Bone Joint Surg Am.* 2000; 82(1):35-46.
  23. Banas MP, Dalldorf PG, Sebastianelli WJ, DeHaven KE, Warren RF. Long-term followup of the modified Bristow procedure, *American Journal of Sports Medicine.* 1993; 21(5):666-671.
  24. Hovelius LK, Sandstrom BC, Rosmark DL, Saebo M, Sundgren KH, Malmqvist BG. Long-term results with the Bankart and Bristow-Latarjet procedures: recurrent shoulder instability and arthropathy, *Journal of Shoulder and Elbow Surgery.* Vol. 2001; 10(5):445-452.
  25. Allain J, Goutallier D, Glorion C. Long-term results of the Latarjet procedure for the treatment of anterior instability of the shoulder. *Journal of Bone and Joint Surgery A.* 1998; 80(6):841-852.
  26. Singer GC, Kirkland PM, Emery RJH. Coracoid transposition for recurrent anterior instability of the shoulder. A 20-year follow-up study, *Journal of Bone and Joint Surgery B.* 1995; 77(1):73-76.
  27. Hovelius LK, Sandstrom BC, Rosmark DL, Saebo M, Sundgren KH, Malmqvist BG. Long-term results with the Bankart and Bristow-Latarjet procedures: recurrent shoulder instability and arthropathy, *Journal of Shoulder and Elbow Surgery.* 2001; 10(5):445-452.
  28. Hill JA, Lombardo SJ, Kerlan RK. The modified Bristow-Helfet procedure for recurrent anterior shoulder sub-luxations and dislocations, *American Journal of Sports Medicine.* 1981; 9(5):283-287.
  29. Allain J, Goutallier D, Glorion C. Long-term results of the Latarjet procedure for the treatment of anterior instability of the shoulder, *Journal of Bone and Joint Surgery A.* 1998; 80(6):841-852.
  30. Hovelius L, Sandstrom B, Sundgren K, Saebo M. One hundred eighteen Bristow-Latarjet repairs for recurrent anterior dislocation of the shoulder prospectively followed for fifteen years: study I-clinical results, *Journal of Shoulder and Elbow Surgery.* 2004; 13(5):509-516.
  31. Hovelius L, Saeboe M. Neer award 2008: arthropathy after primary anterior shoulder dislocation-223 shoulders prospectively followed up for twenty-five years, *Journal of Shoulder and Elbow Surgery.* 2009; 18(3):339-347.
  32. Cassagnaud X, Maynou C, Mestdagh H. Results of 106 Latarjet-Patte procedures: computed tomography analysis at 7.5 years follow-up, *Journal of Bone and Joint Surgery.* 2002; 84(1):39.
  33. Hovelius L, Korner L, Lundberg B *et al.* The coracoid transfer for recurrent dislocation of the shoulder. Technical aspects of the Bristow-Latarjet procedure, *Journal of Bone and Joint Surgery A.* 1983; 65(7):926-934.
  34. Huguet D, Pietu G, Bresson C, Potaux F, Letenneur J. Anterior instability of the shoulder in athletes: apropos of 51 cases of stabilization using the Latarjet-Patte intervention, *Acta Orthopaedica Belgica.* 1996; 62(4):200206.
  35. Griesser MJ, Harris JD, McCoy BW, Hussain WM, Jones MH, Bishop JY *et al.* Complications and re-operations after Bristow-Latarjet shoulder stabilization: a systematic review. *J Should Elbow Surg Am Should Elbow Surg.* 2013; 22(2):286-92. doi: 10.1016/j.jse.2012.09.009.
  36. Lafosse L, Lejeune E, Bouchard A, Kakuda C, Gobezie R, Kochhar T. The arthroscopic Latarjet procedure for the treatment of anterior shoulder instability, *Arthroscopy.* 2007; 23(11):1242-1242.
  37. Banas MP, Dalldorf PG, Sebastianelli WJ, DeHaven KE, Warren RF. Long-term followup of the modified Bristow procedure, *American Journal of Sports Medicine.* 1993; 21(5):666-671.
  38. Singer GC, Kirkland PM, Emery RJH. Coracoid transposition for recurrent anterior instability of the shoulder. A 20-year follow-up study, *Journal of Bone and Joint Surgery B.* 1995; 77(1):73-76.
  39. Pap G, Machner A, Merk H. Treatment of recurrent traumatic shoulder dislocations with coracoid transfer Latarjet-Bristow operation. *Zentralblatt fur Chirurgie.* 1997; 122(5):321-326.
  40. Hovelius LK, Sandstrom BC, Rosmark DL, Saebo M, Sundgren KH, Malmqvist BG. Long-term results with the Bankart and Bristow-Latarjet procedures: recurrent shoulder instability and arthropathy, *Journal of Shoulder and Elbow Surgery.* 2001; 10(5):445-452.
  41. Matthes G, Horvath V, Seifert J *et al.* Oldie but goldie: Bristow-Latarjet procedure for anterior shoulder instability, *Journal of Orthopaedic Surgery.* 2007; 15(1):4-8.
  42. Dossim A, Abalo A, Dosseh E, Songne B, Ayite A, Gnandi-Pio F. Bristow-Latarjet repairs for anterior instability of the shoulder: clinical and radiographic results at mean 8.2 years follow-up, *Chirurgie de la Main.* 2008; 27(1):26-30.
  43. Edouard P, Beguin L, Fayolle-Minon I, Degache F, Farizon F, Calmels P. Relationship between strength and functional indexes (Rowe and Walch-Duplay scores) after shoulder surgical stabilization by the Latarjet technique, *Annals of Physical and Rehabilitation Medicine.* 2010; 53(8):499-510.
  44. Di Giacomo G, Costantini A, de Gasperis N. Coracoid graft osteolysis after the Latarjet procedure for antero inferior shoulder instability: a computed tomography scan study of twenty-six patients, *Journal of Shoulder and Elbow Surgery.* 2011; 20(6):989-995.
  45. Rao S, Raju SD, Chiranjeevi V. Results of mini open Latarjet procedure for recurrent shoulder dislocation in India: A series of 30 cases, *Journal of Dental and Medical Sciences.* 2014; 13(11):59-62.