

# International Journal of Orthopaedics Sciences

ISSN: 2395-1958  
IJOS 2019; 5(1): 170-174  
© 2019 IJOS  
www.orthopaper.com  
Received: 15-12-2014  
Accepted: 20-01-2015

**Dr. Amit Nandan Mishra**  
Associate Professor,  
Department of Orthopaedics,  
Era's Lucknow Medical College,  
Lucknow, Uttar Pradesh, India

**Dr. Sandhya Mishra**  
Assistant Professor,  
Department of Community  
Medicine, Integral Institute of  
Medical and Research Sciences,  
Integral University, Lucknow,  
Uttar Pradesh, India

**Dr. Shakeel Ahmad Qidwai**  
Professor, Department of  
Orthopaedics, Era's Lucknow  
Medical College, Lucknow,  
Uttar Pradesh, India

**Dr. Varun Kumar Shrimal**  
Senior Resident,  
Department of Orthopaedics,  
Era's Lucknow Medical College,  
Lucknow, Uttar Pradesh, India

## A-prospective study of the outcome of closed intramedullary fixation of humeral shaft fractures treated with multiple K-wires in adults

**Dr. Amit Nandan Mishra, Dr. Sandhya Mishra, Dr. Shakeel Ahmad Qidwai and Dr. Varun Kumar Shrimal**

DOI: <https://doi.org/10.22271/ortho.2019.v5.i1d.32>

### Abstract

**Objective:** To evaluate the feasibility and efficacy of management of fracture of shaft humerus in adults by closed reduction internal fixation with the help of long K-wires followed by immobilization for 3 weeks in splint and then guarded mobilization till fracture united.

**Methods:** This was a prospective longitudinal study. The subjects with fresh diaphyseal humeral shaft fractures without injury to the same limb, transverse/oblique fractures with a large butterfly fragment, comminuted fractures/segmental fragments and long oblique or spiral fracture were included in the study. Patient was taken on the table in lateral position. The general anaesthesia was given. A midline vertical incision of about 3 cms was given on the posterior aspect of distal humerus and the soft tissue dissected. Triceps was split in line with the fibres and the bone was reached.

**Results:** The mean age of the patients was 42.13 ( $\pm 13.02$ ) years. More than half (69.6%) of the subjects were male. The RTA was among 65.2% of the subjects. The oblique with butterfly type of injury was in 30.4% of the subjects and comminuted was in 21.7%. The middle site of fracture was in 52.2% and left site of fracture was in 52.2%. The antegrade nailing was used among 69.6% of the patients. There was significant increase in the extent of union, constant score and Mayo score from 4 week to 8 and 12 week. The shoulder stiffness was among 65.2% at 4 week which became 13% at 8 and 12 week. The elbow stiffness was in 17.4% of the subjects which decreased to 13% and 8.7% at 8 and 12 week respectively.

**Conclusion:** The present study showed that K-wire fixation for humeral shaft fractures has distinct advantages over other conservative and over operative techniques.

**Keywords:** Fracture, humerus, K-wire fixation

### Introduction

Fracture of the humeral shaft are common, account for approximately 3% of all orthopaedic injuries, and result in a significant burden to society form lost productivity and wages as it affects the most productive age groups with majority of patients being affected in age group 21 to 40 years [1-3].

Treatment modalities have greatly evolved since their first description in ancient Egypt (Circa 1600 BC); however, fundamental management principles have remained consistent throughout time. Non operative management continues as the mainstay for treatment of the majority of these injuries, with acceptable healing in more than 90% of patients. The humeral shaft is covered with muscles and is well vascularised. Slight malunion is functionally and cosmetically tolerated [4-5]. Advances in internal fixation modalities have improved surgical outcomes [6-9].

A new technique for treatment of humeral shaft fractures by closed fixation using multiple intramedullary Kirschner wires has been reported with good clinical and functional results [10-11]. This technique has been found simple and effective in providing a stable fixation of transverse and short oblique fractures of the humeral diaphysis. Considering the low-cost, universal availability and dynamic fixation without compromising stability shown in preliminary studies, K-wire fixation seems to be a perfect treatment modality for a resource scarce economy like ours.

The present study was an attempt to evaluate the feasibility and efficacy of management of

### Correspondence

**Dr. Sandhya Mishra**  
Assistant Professor,  
Department of Community  
Medicine, Integral Institute of  
Medical and Research Sciences,  
Integral University, Lucknow,  
Uttar Pradesh, India

Fracture shaft humerus in adults by closed reduction internal fixation with the help of long K-wires followed by immobilization for 3 weeks in splint and then guarded mobilization till fracture united.

## Material and Methods

**Study Design:** This was a prospective longitudinal study.

**Study place:** The study was conducted at the Department of Orthopaedics, Era's Lucknow Medical College and Hospital, Lucknow after the ethical approval by the ethical committee of the institute. The informed consent was taken from each of the study subjects after explaining the purpose of the study.

The subjects with fresh diaphyseal humeral shaft fractures without injury to the same limb, transverse/oblique fractures with a large butterfly fragment, comminuted fractures/segmental fragments and long oblique or spiral fracture were included in the study. The subjects with old fractures either treated by other methods i.e. conservative or other surgical methods or neglected, fractures with closed head injury, segmental loss of bone, vascular injury, neurological injury, failure to reduce the fracture by closed method satisfactorily and pathological fractures were excluded from the study.

## Retrograde Nailing

Patient was taken on the table in lateral position. The general anaesthesia was given. A midline vertical incision of about 3 cms was given on the posterior aspect of distal humerus and the soft tissue dissected. Triceps was split in line with the fibres and the bone was reached. About 2 cms proximal to the olecranon fossa a hole was drilled on the posterior aspect of the bone of about 0.5&0.5 cms diameter. Standard k-wires of 2 mm and 2.5 mm diameter and 30 cms length were bent at an angle of 45 degrees approximately 2 cms from the proximal end and was loaded on a T handle chuck and then inserted from the window into the medullary cavity crossing the fracture site into the proximal fragment under fluroscopic guidance. The tip of the wire was driven up into the humeral head and impacted. Outer end of the wire was cut 1 cm away from the entry point and was bent like a U to avoid proximal migration of the wire. Similarly a total of 2 – 4 K – wires were inserted in the medullary cavity depending upon the surgeon's judgement of the stability of the fixation. Proximal tip of the wires were kept divergent to have a purchase at different points in the head to achieve rotational stability at fracture site. After insertion of the k-wires the fracture was gently impacted to avoid distraction at the fracture site. Excessive force was avoided while pushing the wires into the medullary cavity to prevent iatrogenic fracture of the greater tubercle. The wound was then irrigated with saline and closed in layers. Similarly a total 4-5 wires depending upon the size of the medullary cavity were inserted and stacked. The distal tips of the wires were kept divergent to have a purchase at different points to achieve rotational stability at fracture site. Wound was irrigated with saline and closed in layers and patient was given a functional brace in the postoperative ward. All patients received broad spectrum antibiotics for a period of 2 days minimum and intravenous paracetamol 1 gm thrice daily for three days. Assisted exercises were started on the 4<sup>th</sup> postop day only if the VAS was 6 or less or else paracetamol was continued in the same dose for 2 more days and when the VAS and 6 or less, assisted exercises were started.

## Assessment criteria

Patients were followed up on 4<sup>th</sup>, 8<sup>th</sup> and 12<sup>th</sup> weeks. Clinical assessment in terms of:-Mal alignment:-angular alignment and short earning was done. The functional assessment of shoulder and elbow joint by Constant Score and Mayo Score were evaluated. Radiological assessment in terms of sequential radiographs was done.

## Analysis

The results are presented in mean±SD and percentages. The Paired t-test was used to compare the changes in the study parameters from 4 to 8 and weeks. The p-value<0.05 was considered significant. All the analysis was carried out by using SPSS 16.0 version (Chicago, Inc., USA).

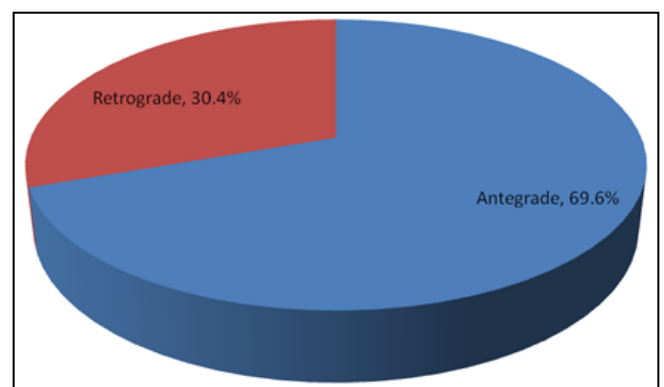
## Results

The mean age of the patients was 42.13 (±13.02) years. More than half (69.6%) of the subjects were male. The RTA was among 65.2% of the subjects. The oblique with butterfly type of injury was in 30.4% of the subjects and comminuted was in 21.7%. The middle site of fracture was in 52.2% and left site of fracture was in 52.2% (Table-1).

**Table 1:** Basic characteristics of the study subjects

	No. (n=23)	%
Age in years	42.13±13.02	
Gender		
Male	16	69.6
Female	7	30.4
Mode of injury		
Household	8	34.8
Road traffic accidents	15	65.2
Type of injury		
Comminuted	5	21.7
Compound	2	8.8
Oblique	5	21.7
Oblique with butterfly	7	30.4
Transverse	4	17.4
Site of fracture		
Distal	4	17.4
Middle	12	52.2
Proximal	7	30.4
Site of fracture		
Right	11	47.8
Left	12	52.2

The antegrade nailing was used among 69.6% of the patients (Fig.1).



**Fig 1:** Type nailing used

There was no change in extent of rotation, angulation and bone shortening from 4 week to 8 and 12 week of follow-up. However, there was significant increase in the extent of union, constant score and Mayo score from 4 week to 8 and 12 week (Table-2).

**Table 2:** Comparison of parameters at follow-ups

	4 week	8 week	12 week
Extent of rotation	9.09±5.31	9.09±5.31	9.09±5.31
Extent of angulation	4.91±2.11	4.91±2.11	4.91±2.11
Extent of bone shortening	1.5±0.70	1.5±0.70	1.5±0.70
Extent of union cortices	2.09±0.79	2.78±1.00 <sup>a</sup>	3.26±1.18 <sup>a</sup>
Extent of constant score	56.00±14.10	66.35±15.53 <sup>a</sup>	84.87±10.14 <sup>a</sup>
Extent of Mayo score	58.47±15.91	76.52±15.70 <sup>a</sup>	93.04±14.83 <sup>a</sup>

<sup>a</sup>p<0.0001 (from 4 week to 8 and 12 week)

Table-3 shows the post-operative complications. The shoulder stiffness was among 65.2% at 4 week which became 13% at 8 and 12 week. The elbow stiffness was in 17.4% of the subjects which decreased to 13% and 8.7% at 8 and 12 week respectively.

**Table 3:** Post-operative complications at follow-ups

Complications	4 week		8 week		12 week	
	No.	%	No.	%	No.	%
Pin tract infection with elbow stiffness	1	4.3	0	0.0	0	0.0
Pin tract infection with shoulder stiffness	1	4.3	0	0.0	0	0.0
Skin necrosis with elbow stiffness	2	8.7	0	0.0	0	0.0
Elbow stiffness	4	17.4	3	13.0	2	8.7
Shoulder stiffness	15	65.2	3	13.0	3	13.0
No complication	0	0.0	17	73.9	18	78.3

## Discussion

Humerus shaft fractures affect the functional ability of an individual while at the same time restrict the social and psychological status. Full restoration of functional ability at the shortest possible time is the priority of management team. Treatment of humerus shaft fractures thus not only requires an early restoration but also requires that it is achieved completely with no restriction so as to enable the patient to take part in his/her routine activities without causing an economic or social burden.

For this purpose, a prospective study was carried out in which a total of 23 patients fulfilling the inclusion criteria and not falling into the domain of exclusion criteria were enrolled. The age of patients ranged from 23 to 67 years with a mean age of 42.13±13.02 years. Majority of patients were in young and productive age group (21-40 years; 52.2%). Humerus fractures have often been reported in age group 21 to 40 years in literature too. The reason for involvement of this age group is that this is the most active age group and owing to higher level of activity has a higher risk of humerus fractures. However, in several studies average age of patients has been reported to be as high as 52 to 72 years [12-13]. However, this might be owing to the fact that they either have an inclusion criteria that includes elderly patients only or the studies are from a region with higher median age [13]. However, despite these sporadic differences, fracture humerus is generally more common in individuals with higher activity level and this is reflected in the age profile of patients in present study.

On gender wise evaluation too, we observed that majority of the patients included in the study were males (69.575) and rest of the patients were females (40.43%). This finding once again endorses our earlier assumption regarding association of incidence of humerus fractures with activity level of a person.

However, contrary to this, the findings in western studies suggest a higher prevalence of humeral shaft fractures among women as compared to men [14]. The reason for this as explained by the cited authors is low bone mineral density in advancing age women. The difference in etiology of humeral shaft fractures in our settings and that of western settings is that while road traffic accidents and violence are major etiologies in Indian context, in western context, the etiology is often different. In Indian studies a male predominance has often been reported with road traffic accident being the major etiology [15, 2]. In present study too, we found that road traffic accident was the most common etiology (65.22%).

With respect to type of fracture most common type of fracture in the present study was oblique with butterfly (30.43%), followed by comminuted (21.74%), oblique (21.74%) and transverse (17.39%). Only 8.70% suffered with compound fracture. The type of fracture depends on the site, nature and intensity of the impact due to which fracture has taken place. Oblique with butterfly and oblique fractures are generally caused by an injury to the bone as the result of a fall accident or other trauma while comminuted fractures are caused mainly by high intensity trauma while transverse fractures are caused by bending forces [16].

In the present study, the most common fracture site was middle (52.17%), followed by proximal (30.43%) and least common site was distal (17.39%). In a study by Obruba *et al* [13]. Too middle third was involved in 64%, proximal third in 30% and distal third in 6% of cases.

In the present study, majority proportion of patients had involvement of left (52.17%) side. In literature no side predilection has been reported [2]. In present study, antegrade type of nailing was used in majority of the patients (68.57%) and in rest of the patients (30.43%) retrograde type of nailing was used. The selection of type of nailing depends on the site of fracture. Antegrade nailing is more suitable for proximally located fractures while retrograde nailing is used for distal fractures [17].

On follow up, in present study, all the patients had pain score between 5 and 10. Majority of the patients rate their pain score as 7 and 8 (82.61%) while 17.39% patients rated their pain score as 6. Severe pain is usually reported in pathologic fractures of the humerus [18-20]. As pathologic fractures were excluded from the present study, hence there was no case with severe pain intensity in present study. Some studies [12, 21]. Have shown that displacement/migration of K-wires results in a painful experience, however, the intensity of pain reported by patients in present study did not indicate any such situation.

The mean extent of rotation also remained unchanged from 4<sup>th</sup> week follow up till 12<sup>th</sup> week follow up (9.09±5.31). Similarly direction of angulation and extent of angulation also remained unchanged throughout the study period, thus indicating that the K-wires were stabilized and did not result in any unwanted rotation. In all the cases, the angulation was less than 20 degrees and rotation was less than 30 degrees thus meeting the criteria of good outcome [22]. This stability was attained by keeping the wire tips divergent to provide rotational stability at the fracture site [23].

In present study, shortening of bone was reported in two patients and it was evident from the 4<sup>th</sup> week follow up itself. However, the extent of shortening was 1 cm and 2 cm respectively which is within the treatment objective of achieving a shortening of 3 cm [22].

However, with respect to extent of union of cortices, a gradual and continuous increase was observed during the entire period

of follow-up. K-wire induces cortical union by continuously activating the adjoining cortical tissue. Use of K-wire has been shown to provide a better cortical union in nonunited humerus shaft fractures treated by external fixator augmented by intramedullary rod [24].

In the present study, a gradual increase in functional scores of shoulder (Constant scores) was observed from 4<sup>th</sup> week itself. Mean functional scores at the end of follow up were 84.87 and median scores were 90, thus indicating that majority of patients achieved good functional restoration. Minimum functional scores at the end of follow up was 66, thus indicating that at least fair restoration of functional ability was observed in all the patients. In a study by Hoffmann *et al* [12]. In a minimum follow up of 12 months 60% patients showed good or excellent results, 30% had a satisfactory and 10% had an unsatisfactory or poor result.

In present study, with respect to elbow performance, though at 4<sup>th</sup> week of follow up mean scores indicative of a poor performance were observed (58.47±15.91) yet by 12<sup>th</sup> week of follow up a very highly significant change in mean scores was observed (93.04±14.83). Thus, overall mean scores indicated an excellent resumption of elbow performance. The median MAYO score at 12<sup>th</sup> week was 100, which indicated that majority of patients had scores above 90 which indicated an excellent performance of elbow [10]. In their assessment also showed achievement of results comparable to our study with 93% patients showing good to excellent movements at shoulder and elbow. In present study too, we observed that except for 2 (8.7%) patients, all the patients achieved MAYO score above 80 which indicated that good elbow functional status was achieved in 91.3% patients. The reason for achievement of good functional status of shoulder and elbow in intramedullary wires in humeral shaft fractures could be attributed to relative freedom of movements at these ends as against conservative management and immobilization techniques. The findings thus relate with the observations of Qidwai [10]. And Khan *et al.* [11] who were of the view that multiple intramedullary Kirschner wires provide good clinical and functional results.

In the present study, during first follow up at 4 weeks all the patients included in the study reported some complications. Shoulder stiffness only was reported by 15 (65.22%) cases and shoulder stiffness with pin tract infection was reported by 1 (4.35%) patient, this was present in cases of antegrade nailing. 4 (17.39%) patients reported elbow stiffness only, 2 (8.70%) reported elbow stiffness with skin necrosis and 1 (4.35%) patient reported elbow stiffness with pin tract infection. The stiffness of shoulder or elbow is result of immobilization and during the initial period of immobilization causes discomfort to the patient until adjustments are made. The infection and tissue necrosis was relieved by antibiotic and medical management and in subsequent follow up none of the patient had these complaints. By 12<sup>th</sup> week, only 2 patients reported of elbow stiffness while 3 (13.04%) reported of shoulder stiffness, and the remaining 18 (78.26%) had no complication at all. Stiffness of the shoulder and elbow joints is a frequently reported disadvantage of non-operative methods.

The present study showed that K-wire fixation for humeral shaft fractures has distinct advantages over other conservative and over operative techniques. The low cost and universal availability of K-wires (as compared to titanium nails and the short hospital stay make this treatment cost effective and particularly suitable for developing and underdeveloped countries. This is a simple technique, and sophisticated

instrumentation is not required.

## References

1. Tsai CH, Fong YC, Chen YH, Hsu CJ, Chang CH, Hsu HC. The epidemiology of traumatic humeral shaft fractures in Taiwan. *Int Orthop.* 2009; 33:463-7.
2. Singiseti K, Ambedkar M. Nailing versus plating in humerus shaft fractures: A prospective comparative study. *Int Orthop.* 2010; 34(4):571-576.
3. Sidhu AS, Mann HS, Sidhu GDS, Banga A, Bassi A, Gupta M. management of fracture shaft of humerus – open versus closed antegrade nailing. *Pb Journal of Orthopaedics.* 2011; 12(1):34-37.
4. Putti AB, Uppin RB, Putti BB. Locked Intramedullary nailing versus dynamic compression plating for humeral shaft fractures. *Journal of Orthopaedic Surgery.* 2009; 17(2):139-41.
5. Walker M, Palumbo B, Badman B, Brooks J, Gelderen JV, Mighell M. Humeral shaft fractures: a review. *J Shoulder Elbow Surg.* 2011; 20(5):833-44.
6. Chapman JR, Henley MB, Agel J, Benca PJ. Randomized prospective study of humeral shaft fracture fixation: intramedullary nails versus plates. *J Orthop Trauma.* 2000; 14:162-6.
7. Martinez AA, Cuenca J, Herrera A. Treatment of humeral shaft nonunions: nailing versus plating. *Arch Orthop Trauma Surg.* 2004; 124:92-5.
8. Bhandari M, Devereaux PJ, McKee MD, Schemitsch EH. Compression plating versus intramedullary nailing of humeral shaft fractures: a metaanalysis. *Acta Orthop.* 2006; 77:279-84.
9. Singiseti K, Ambedkar M. Nailing versus plating in humerus shaft fractures: A prospective comparative study. *Int. Orthop.* 2010; 34(4):571-576.
10. Qidwai SA. Treatment of human shaft fractures by closed fixation using multiple intramedullary Kirschner wires. *J Trauma.* 2000; 49(1):81-5.
11. Khan AQ, Iraqi AA, Sherwani MK, Abbas M, Sharma A. Percutaneous multiple K-wire fixation for humeral shaft fractures. *Saudi Med J.* 2007; 28(1):144-6.
12. Hoffmann R, Khodadadyan C, Raschke M, Melcher I, Maitino PD, Haas NP. Retrograde intramedullary nailing in proximal fracture of the humerus in the elderly patient. Results of minimally invasive management concept. *Zentralbl Chir.* 1998; 123(11):1232-8.
13. Obruba P, Kopp L, Edelmann K. Treatment of humeral shaft fractures using Hackethal's technique of intramedullary bundle nailing. *Acta Chir Orthop Traumatol Cech.* 2012; 79(4):341-6.
14. Kim SH, Szabo RM, Marder RA. Epidemiology of humerus fractures in the United States: nationwide emergency department sample, 2008. *Arthritis Care & Research.* 2012; 64(3):407-414.
15. Putti AB, Uppin RB. Locked intramedullary nailing versus dynamic compression plating for humeral shaft fractures. *J Orthop Surg (Hong Kong).* 2009; 17(2):139-41.
16. Newton CD. Etiology, Classification and Diagnosis of Fractures. In: *Small Animal Orthopedics.* Newton CD, Nunamaker DM, (eds.). Lipincott Philadelphia, 1985.
17. Lin J, Inoue N, Valdevit A *et al.* Biomechanical comparison of antegrade and retrograde nailing of humeral shaft fracture. *Clin Orthop.* 1998; 351:203-213.
18. Flinkkila T, Hyvonen P, Leppilahti J, Hamalainen M. Pathological fractures of the humeral shaft. *Ann Chir*

- Gynaecol. 1998; 87(4):321-4.
19. Anselmetti GC, Manca A, Chiara G, Tutton S, Iussich G, Gino G *et al.* Painful pathologic fracture of the humerus: percutaneous osteoplasty with bone marrow nails under hybrid computer tomography and fluoroscopic guidance. *J Vasc Interv Radiol.* 2011; 22(2):1031-4.
  20. Jindal N, Gupta P, Gupta RK, Kumar A, Jindal A. Pucker sign in proximal humeral fractures: implications on management. *Strategies Trauma Limb Reconstr.* 2013; 8(2):123-126.
  21. Fang RH, Chang TL. Watch out for the K-wire: painful experiences in two cases. *Br J Plast Surg.* 2002; 55(8):698-9.
  22. Sarmiento A, Kinman PB, Galvin EG *et al.* Functional bracing of fractures of the shaft of the humerus. *J Bone Joint Surg (Am).* 1977; 59-A(5):596-601.
  23. Qidwai SA. Treatment of proximal humeral fractures by intramedullary Kirschner wires. *J Trauma.* 2001; 50(6):1090-5.
  24. El-Rosasy MA. Nonunited humerus shaft fractures treated by external fixator augmented by intramedullary rod. *Ind. J Orthop.* 2012; 46(1):58-64.