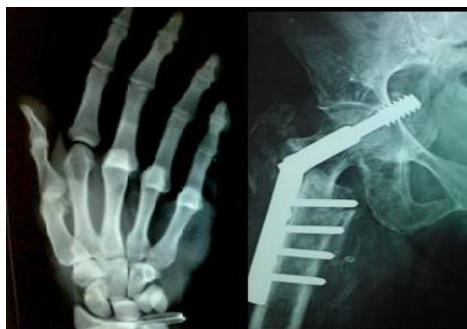



International Journal of Orthopaedics Sciences

ISSN: 2395-1958
IJOS 2019; 5(1): 38-43
© 2019 IJOS
www.orthopaper.com
Received: 19-11-2018
Accepted: 23-12-2018

Dr. Latheesh Leo

Associate Professor, Chief of
Hand & Microvascular surgery
Unit, Dept of Orthopaedic
Surgery, Father Muller Medical
College, Mangalore, Karnataka,
India

Dr. Jayendra Burde

Resident, Dept of Orthopaedic
Surgery, Father Muller Medical
College, Mangalore, Karnataka,
India

Dr. Vivian Roshan D Almeida

Assistant Professor, Father
Muller Medical College Hospital,
Mangalore, Karnataka, India

Comparative analysis of clinical features and radiological outcome of neuropathic ulcers in a diabetic foot

Dr. Latheesh Leo, Dr. Jayendra Burde and Dr. Vivian Roshan D Almeida

DOI: <https://doi.org/10.22271/ortho.2019.v5.i1a.08>

Abstract

Background: Neuropathic osteoarthropathy (NO) commonly referred to as Charcot Foot, in patients with Diabetes mellitus, is a condition in which the bones, joints, and soft tissues of the foot and ankle are affected and involves inflammation in the initial phase. It further leads to reduced quality of life with high mortality rate and quality of life reduction. Several components interact to cause high incidence of fracture non-union, joint dislocation, foot deformity, and skin ulceration, increasing the relative risk of amputation. Annual incidence rates of 8.5/1000 per year have been reported. This rate has been increasing over the years with the availability of imaging modalities and reduced time in patient treatment

Objectives: To compare the clinical and radiological characteristics in diabetic patients with Neuropathic ulcers and to evaluate the severity of joint involvement in the Diabetic Neuropathy affected feet

Methods: In the year 2017 to 2018, a minimum sample size of 47 cases with diabetic neuropathy having osteoarthropathic changes satisfying inclusion and exclusion criteria and who have been admitted inpatient or treated on outpatient basis at our institution were selected. A cross sectional study on the samples was carried out. The aim of this study is to compare the clinical characteristics and radiographic changes in diabetic patients with neuroarthropathy and their outcome analysis.

Results: In the total pool of 47 patients taken together, male predominance was found with maximum patients in the age group of 45-55 years. Diabetic patients with fore - foot ulcers had greater involvement than in mid - foot and Hind - foot ulceration when measuring the above mentioned angles with underlying neurological and vascular sign. Radiographic abnormalities were noted with changes mainly on Saggital and AP plains of the foot with predominance increased medial column height with reduction in calcaneal pitch and reduced Lateral calcaneal- 5th metatarsal angles in majority of the patients.

Conclusion: Findings in the sagittal plane differed than in Antero - posterior significantly when comparing patients on basis of area of involvement. The ultimate aim of the treatment is to prevent ulceration of the foot, and increase awareness among the patients having progressive deformity mainly in the sagittal plane. This will help to address the xray abnormalities and plan for further reconstructive CN surgery re-establishing the normal anatomy.

Keywords: neuroarthropathy (NO), charcot's, osteoarthropathy

Introduction

Neuropathic osteoarthropathy (NO) commonly referred to as Charcot Foot, in patients with Diabetes mellitus, is a condition in which the bones, joints, and soft tissues of the foot and ankle are affected and involves inflammation in the initial phase. It is associated with high mortality rate and quality of life reduction^[1]. Several components like diabetes, sensory-motor neuropathy trauma, metabolic disorders and autonomic neuropathy interact to cause high incidence of fracture non-union, joint dislocation, foot deformity, and skin ulceration, increasing the relative risk of amputation.² Long term elevation of glucose levels can cause changes in feet of patients with Diabetes mellitus. The pathogenesis includes two theories causing ulceration in a diabetic foot and includes the neurotraumatic (German) and neurovascular (French) theories. It is thought that the neuropathy may be due to sorbitol accumulation and the glycosylation process which may disrupt the protein function in the nerves. Pain, proprioception, sensory, motor, and autonomic pathways are mainly involved in diabetic neuropathy. Abnormal pressure loading over the involved foot is mainly due to the

Correspondence

Dr. Latheesh Leo

Associate Professor, Chief of
Hand & Microvascular surgery
Unit, Dept of Orthopaedic
Surgery, Father Muller Medical
College, Mangalore, Karnataka,
India

motor neuropathy causing subsequent muscle imbalance and fixed foot deformity [3]. The reported incidence and prevalence of CNO varies between 0.08% to 8% of diabetic population [4, 5]. Annual incidence rates of 8.5/1000 per year have been reported [4]. This rate has been increasing over the years with the availability of imaging modalities and reduced in patient treatment and increased out-patient treatment coupled with early mobilisation.

The aim of this study is to compare the clinical characteristics and radiographic changes in diabetic patients with neuroarthropathy. The PEDIS classification system is used to quantify the foot involvement and the predicted outcome of the involved diabetic foot.

Materials and Methods

Materials

The study was a hospital based cross-sectional study. Forty – seven patients with long standing Diabetes Mellitus and features of diabetic foot aged 35 years and above were selected. Period of study was one year from May 2017 to December 2018. Patients who were presented to the Department of Orthopaedics on IPD and OPD basis at Father Muller Medical College hospital, Mangalore were drawn into the study. The cases which fulfilled the inclusion criteria mentioned here were taken up for the study.

Inclusion Criteria

1. Patients aged 35 and above
2. More than 8 years of diagnosed Diabetes mellitus
3. Definitive ulceration or deformity of the involved foot
4. Patients with signs of peripheral neuropathy

Exclusion Criteria

1. Patients not willing for follow up or any medical/surgical intervention.
2. Patients with evidence of infections or malignancy
3. Patients with trophic ulcers due to other causes like leprosy, Tabes dorsalis, spinal disorders

Methods

After institutional ethical clearance was obtained, the patients fitting in the inclusion criteria were searched from year May 2017 to December 2018. Forty – seven patients included in the study having either fore – foot, mid-foot and hind-foot ulceration with underlying diabetes and who have not undergone previous major mid - foot, hind - foot, or ankle surgery. The patients were divided into three groups. Michigan Neuropathy Screening Index was used to diagnose peripheral neuropathy on each patient which include use of Semmes-Weinstein monofilament, presence of ulceration, and the presence or absence of deformity (claw toes, CN) [6]. Six sites on plantar aspect of the foot were tested for sensations (1st and 4th toe, 1st, 3rd 5th Metatarsal heads and heel). The vascular status of the limb was clinically recorded on basis of the presence or absence of pulse at two levels. Previous treatment and knowledge of current footwear and footwear education was noted. Ulcers were inspected and palpated and location noted [3]. Sanders/ Frykberg classification system was used to classify anatomically the location of ulcers (Type 1 -

involving the forefoot, Type 2 - tarsometatarsal joints, Type 3 - naviculocuneiform, talonavicular, and calcaneocuboid joints, Type 4 - ankle and/or subtalar joints and Type 5 - the calcaneus). However for the ease of research purpose, The foot was divided into Fore – foot (Type 1 sander's), Mid – foot (Type 2 and 3 sander's) and Hind – foot (Type 4 and 5 sander's). Thus, it included Group – 1/ Fore – foot involvement (n= 15), Group 2 / Mid – foot involvement (n= 26) and Group 3/ Hind – foot involvement (n= 6) with ulceration and osteoarthropathy.

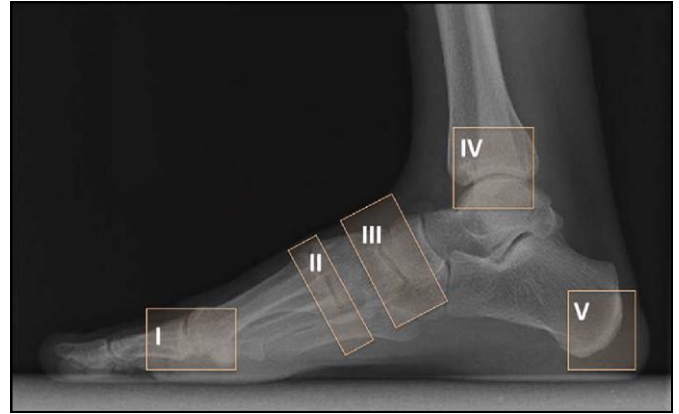


Illustration of Sander's and Frykberg's classification

Anteroposterior (AP) and weight bearing lateral radiographs of each involved diabetic foot were assessed using a ruler and goniometer to measure the AP talar-first metatarsal angle and Hind-foot - Fore-foot angle on AP view and calcaneal pitch, medial column height, cuboid height and lateral talar-first metatarsal angle on Lateral views.

On antero-posterior view

1. AP talar first metatarsal angle - Angle formed between a line bisecting the talar body and neck and a line bisecting the first metatarsal – normally $+4^{\circ}$ (Fig.1 - angle A)
2. The Hindfoot-forefoot angle - Line that bisected the AP talocalcaneal angle and a line through the longitudinal axis of the 2nd metatarsal – normally -7° (Fig.1 – angle B)

On Lateral views

1. Calcaneal pitch angle – Angle formed between a reference line drawn from the calcaneal tuberosity on plantar aspect to the 5th metatarsal head and a line drawn from the most plantar aspect of the calcaneal tuberosity to the anterior process of the calcaneum – normally measuring 10° (Fig.2 – angle A)
2. Lateral calcaneal-fifth metatarsal angle – Angle formed between the Line bisecting the fifth metatarsal and a line drawn the calcaneal tuberosity to the anterior process of the calcaneus on its plantar most aspect - normally measuring 19° (Fig.2 – angle C)
3. Medial column height - Perpendicular distance from the reference line AB to 1st tarsometatarsal joint on its plantar most aspect– normally measuring 8.4 mm (Fig.2 – line B)

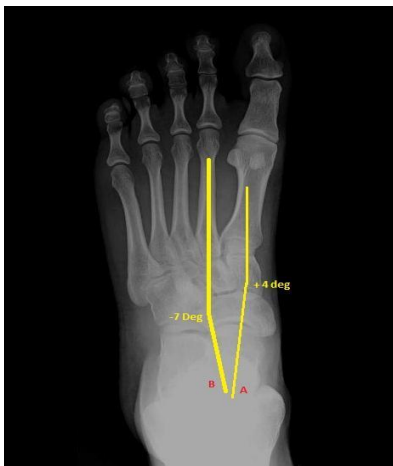

Fig 1: X-ray Foot – AP view (angle A and angle B)

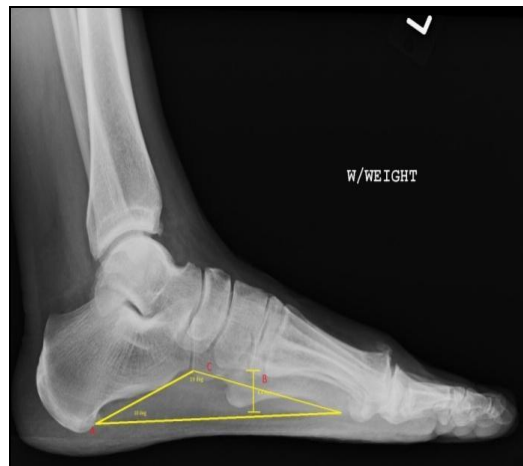


Fig 2: X-ray Foot – Standing lateral view (angles A, B and C)

To summarize, the statistics were described as frequencies (percentages, %) or as mean \pm standard deviation (SD), as applicable. A multivariate analysis of variance (MANOVA) test was used which included with all the 5 angles as the outcome and group used as predictor was fit to the data. The MANOVA analysis was used to obtain the effect of the desired 3 groups (Forefoot ulcers, Midfoot ulcers, and Hindfoot ulcers) on 5 dependent variables (5 angles). The MANOVA *P* value represents the test is significant and that the angle vector means are equal amongst the 3 groups.) MANOVA tests were followed up for each dependent

variable further using the Univariate analyses of variance (ANOVAs).

Results
Age and Sex distribution

Age group of our patients was between 35 to 75 years. Majority of our patients with diabetic foot involvement were found to be the age group of 45-55 years. The study showed involvement of ulcers in diabetic patients with a predominance of males accounting to almost 74% (n = 35) as compared to 26% of females (n = 12).

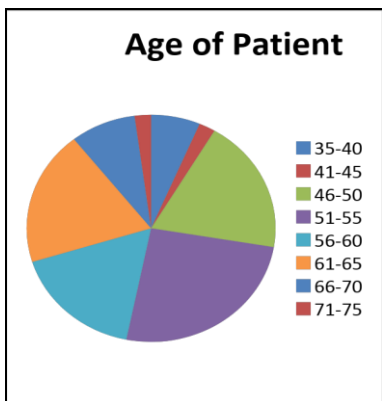


Fig 3: Age-wise distribution

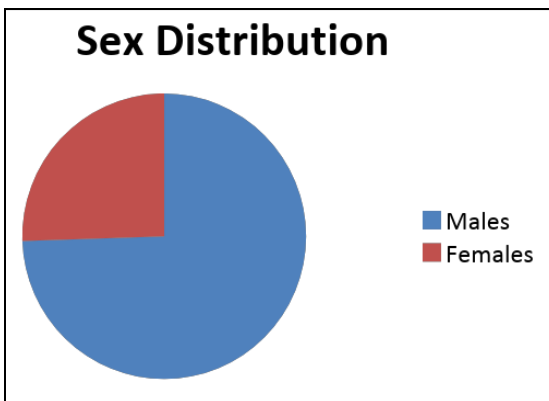


Fig 4: Sex distribution in population

In our study, about thirty eight patients (81%) had type II diabetes mellitus and nine patients had type I diabetes (19%). Among all the patients, about 24 patients (51%) were on treatment with insulin. There was no significant correlation

between the HbA1c values and location/ severity of the ulcer. The approximate duration of diabetes was around 8 – 10 years in about 30% of the subjects (n= 14).

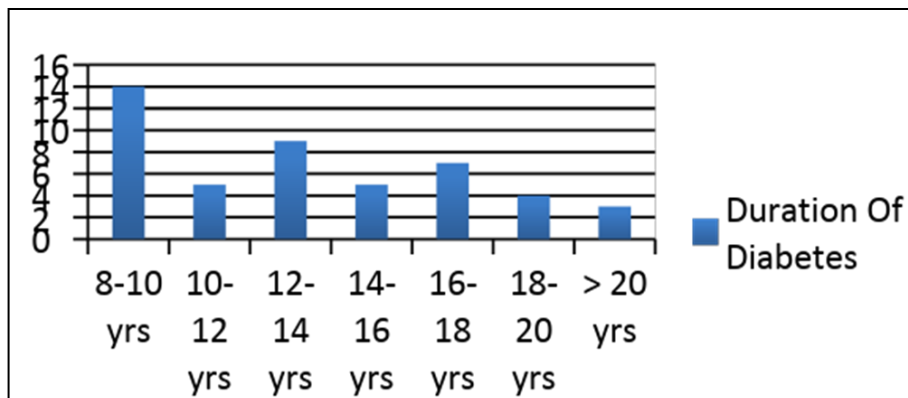


Fig 5: Average duration of Diabetes in population

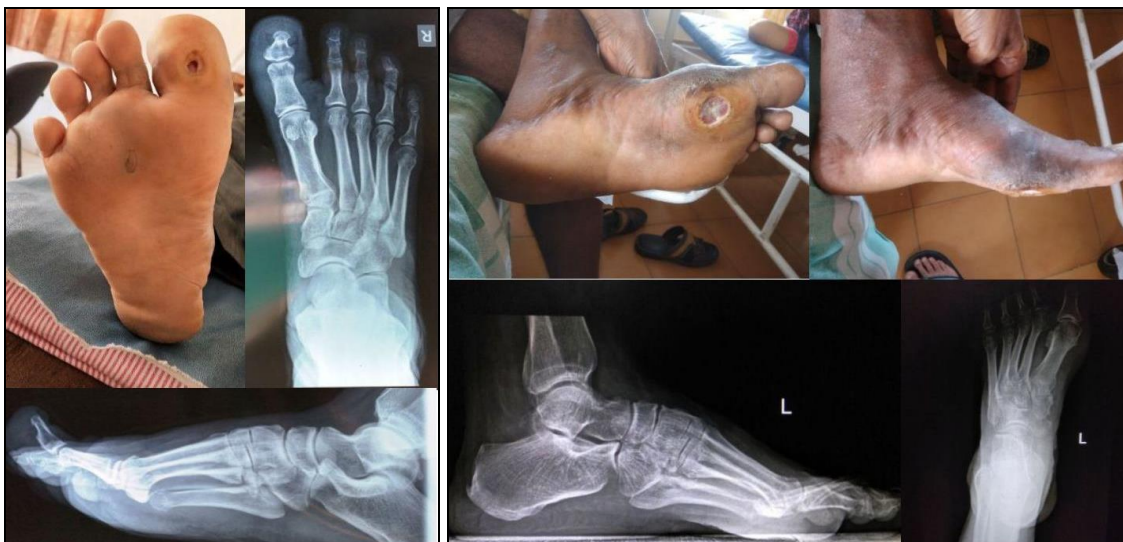Table 1: Radiographic data (subjects)

Angles And ratios →	AP talar – 1 st Metatarsal (degrees)	Hindfoot Forefoot angle (degrees)	Calcaneal Pitch (degrees)	Medial column height (length=mm)	Lateral calcaneal – 5 th Metatarsal angle(degrees)	MANOVA (overall test)	ANOVA (f- ratio)	ANOVA (p value)
Forefoot Ulcers (n = 26)	4.4231	5.9615	9.8846	10.2308	17.1923	P < 0.0001	361.44526	< 0.00001
MEAN ± 2SD	(±2.95)	(±3.92)	(±2.49)	(±2.06)	(±2.53)			
Midfoot Ulcers (n = 15)	3.9333	6.3333	10.4667	11.2	16.6	P < 0.0001	143.37395	< 0.00001
MEAN ± 2SD	(±2.20)	(±2.89)	(±4.13)	(±3.22)	(±3.00)			
Hindfoot Ulcers (n = 6)	4.8333	5.5	10.3333	11.1667	17.1667	P < 0.0001	112.58794	< 0.00001
MEAN ± 2SD	(±2.33)	(±2.09)	(±2.42)	(±2.33)	(±2.66)			

Table 1 the means and standard deviations of the dependent variables (ie, angles) for the 3 groups. The results showed an overall difference amongst the angles from different groups using the MANOVA, and $P < .0001$. The univariate ANOVA results was verified after considering the overall significance from the test. There was statistical significance for AP 1st Metatarsal angle, Hindfoot – forefoot angle, Calcaneal pitch, medial column height and Lateral calcaneal – 5th metatarsal angle using the ANOVA test wherein $P < 0.00001$ for each of three groups → forefoot, midfoot and hindfoot. The f- Ratios were 361.44526, 143.37395, 112.58794 respectively.

ANOVAs showed significant differences over the 3 groups

with respect to area of foot involvement. Diabetic patients having fore - foot ulcers showed greater involvement as compared to in mid – foot and Hind – foot ulceration when measuring the above mentioned angles. In our study, almost all the patients showed signs of peripheral neuropathy. About 88% of patients with forefoot ulcers had nerve involvement (n = 23), while mid-foot ulcers accounted for 93% involvement (n = 14) and hindfoot ulcers about 93% (n = 4). Almost 17% of the patients with fore foot ulceration had Peripheral vascular involvement either feeble or absent pulse as the clinical finding. However, there was no significant difference within the mid – foot or hind – foot involvement.

**Case Study 1****Case Study 2**

Observations and Discussion

The patients with diabetic foot involving neuropathic changes and forefoot deformity are at risk of developing plantar forefoot ulceration. The results show male predominance in the study population with average age being between 45 to 55 years. Our findings are consistent with respect to the study done by A. Veves *et al.* on risk ulceration on foot in Diabetic patients [8] Patients with underlying disease showed mainly Type II Diabetes mellitus with of ongoing insulin treatment. This finding was similar to that of results of study population done by Evanthia Gouveri, Nikolaos Papanas on Charcot's osteoarthropathy [5].

In our study, patients on an average have minimum of 8 years of Diabetes commonly between eight to ten years of disease mainly on Insulin treatment. There was no correlation on the basis of HbA1c values and severity of ulcer. Patients mainly belonged to upper lower socioeconomic strata of the society which was classified in accordance with the Modified Kuppusswamy classification [9]. Most of the patients had poor

hygiene and sanitary condition, lack of proper foot care and inappropriate footwear use.

Dane K. Wukich *et al.* in a study involving evaluation of weight bearing radiographs in patients with and without foot ulcers diagnosed with CN secondary to diabetes mellitus found out that saggital plane deformities were more commonly associated with foot ulceration than transverse plane deformities and that lateral column involvement had worse prognosis. Our findings are consistent with this study with regards to involvement of mainly forefoot and mid-foot areas causing ulceration on the plantar surface. This is mainly associated with mainly increased medial column height (> 8.4 mm), decreased calcaneal pitch (< 10 degrees) and decreased Lateral calcaneal- 5th metatarsal angles (< 19 degrees) in majority of the patients and results are found to be statistically significant with p-value less than 0.00001 as found out by ANOVA test of significance. This study also demonstrated that ulceration shows concurrent involvement of features of peripheral neuropathy in almost all the patients, which

concludes that decreased sensory perception is a major cause for the initiation of the ulceration process. Also associated Peripheral vascular disease, systemic conditions like renal or, cardiac and generalised nutrition status of the patients has significant effects on plantar foot ulcerations.

Limitations

The study is limited by involving a limited number of patients chosen on cross sectional basis. In addition, neuropathy was identified with the use of light touch sensation. Besides, the patients were selected randomly on OPD and IPD basis with no record of follow – up of the subjects and exclusion of patients with diabetes involving other causes of neuropathic ulcers as well. Despite having the limitations, we believe the relevance of the data will help for the early identification of the diabetic osteoarthropathy and appropriate management based on the severity of the Charcot's foot.

Conclusion

Based on our radiographic study, findings in the sagittal plane differed than in Antero - posterior significantly when comparing patients on basis of area of involvement. The ultimate aim of the treatment is to prevent ulceration of the foot, and increase awareness among the patients having progressive deformity mainly in the sagittal plane. This will help to address the Xray abnormalities especially increased medial column height and decreased Lateral calcaneal- 5th metatarsal angles causing forefoot ulcers and plan for further reconstructive CN surgery re-establishing the normal anatomy. Lateral weight bearing angles play an important role to predict risk of further ulceration. Even though it is usually possible to normalize these angles, xrays provide a platform to plan for internal off – loading or alignment improving surgeries resulting in a plantigrade alignment of the foot and initiation of ulcer healing.

Declarations

Funding: None

Conflict of interest: None declared

Ethical approval: Obtained from the institution (protocol no. 322/18, Father Muller Medical College Institutional Ethics Committee.

References

- Wukich DK, Raspovic KM, Hobizal KB, Rosario B. Radiographic analysis of diabetic midfoot Charcot neuroarthropathy with and without midfoot ulceration. *Foot & ankle international*. Nov. 2014; 35(11):1108-15.
- Hastings MK, Johnson JE, Strube MJ, Hildebolt CF, Bohnert KL, Prior FW, Sinacore DR. Progression of foot deformity in Charcot neuropathic osteoarthropathy. *The Journal of bone and joint surgery. American volume*. Jul 3. 2013; 95(13):1206.
- Bevan WP, Tomlinson MP. Radiographic measures as a predictor of ulcer formation in diabetic Charcot midfoot. *Foot & ankle international*. Jun. 2008; 29(6):568-73.
- Frykberg RG, Belczyk R. Epidemiology of the Charcot foot. *Clinics in Podiatric Medicine and Surgery*. Jan 1. 2008; 25(1):17-28.
- Gouveri E, Papanas N. Charcot osteoarthropathy in diabetes: a brief review with an emphasis on clinical practice. *World journal of diabetes*. May 15. 2011; 2(5):59.
- Boulton A, Armstrong D, Albert S, Frykberg R, Hellman R, Kirkman M, Lavery L, LeMaster J, Mills Sr J, Mueller M, Sheehan P. Comprehensive foot examination and risk assessment. *Endocrine Practice*. Jul 1. 2008; 14(5):576-83.
- Ergen FB, Sanverdi SE, Oznur A. Charcot foot in diabetes and an update on imaging. *Diabetic foot & ankle*. Jan 1. 2013; 4(1):21884.
- Veves A, Murray HJ, Young MJ, Boulton AJ. The risk of foot ulceration in diabetic patients with high foot pressure: a prospective study. *Diabetologia*. Jul 1. 1992; 35(7):660-3.
- Mishra D, Singh HP. Kuppuswamy's socioeconomic status scale—a revision. *Indian journal of pediatrics*. Mar 1. 2003; 70(3):273-4.
- Rosenbaum AJ, DiPreto JA. Classifications in brief: Eichenholtz classification of Charcot arthropathy. *Clinical Orthopaedics and Related Research*. 2015; 473(3):1168-1171.
- Cofield RH, Morrison MJ, Beabout JW. Diabetic neuroarthropathy in the foot: patient characteristics and patterns of radiographic change. *Foot & ankle*. Jul. 1983; 4(1):15-22.
- Meltzer AD, Skversky N, Ostrum BJ. Radiographic evaluation of soft-tissue necrosis in diabetics. *Radiology*. Feb. 1968; 90(2):300-5.
- Gondos B. Roentgen observations in diabetic osteopathy. *Radiology*. Jul. 1968; 91(1):6-13.
- Boyko EJ, Ahroni JH, Stensel V, Forsberg RC, Davignon DR, Smith DG. A prospective study of risk factors for diabetic foot ulcer. The Seattle Diabetic Foot Study. *Diabetes care*. Jul 1. 1999; 22(7):1036-42.
- Rajbhandari S, Jenkins RD, Davies C, Tesfaye S. Charcot neuroarthropathy in diabetes mellitus. *Diabetologia*. Aug 1. 2002; 45(8):1085-96.
- Rogers LC, Frykberg RG, Armstrong DG, Boulton AJ, Edmonds M, Van GH *et al*. The Charcot foot in diabetes. *Diabetes care*. Sep 1. 2011; 34(9):2123-9.
- Hastings MK, Sinacore DR, Mercer-Bolton N, McCormick JJ, Hildebolt CF, Prior FW *et al*. Precision of foot alignment measures in Charcot arthropathy. *Foot & ankle international*. Sep. 2011; 32(9):867-72.
- McCrary JL, Morag E, Norkitis AJ, Barr MS, Moser RP, Caputo GM, Cavanagh PR *et al*. Healing of Charcot fractures: skin temperature and radiographic correlates. *The Foot*. Sep 1. 1998; 8(3):158-65.
- Molines L, Darmon P, Raccach D. Charcot's foot: newest findings on its pathophysiology, diagnosis and treatment. *Diabetes & metabolism*. Sep 1. 2010; 36(4):251-5.
- Cavanagh PR, Young MJ, Adams JE, Vickers KL, Boulton AJ. Radiographic abnormalities in the feet of patients with diabetic neuropathy. *Diabetes Care*. Mar 1. 1994; 17(3):201-9.
- Schon LC, Weinfeld SB, Horton GA, Resch S. Radiographic and clinical classification of acquired midtarsus deformities. *Foot & ankle international*. Jun. 1998; 19(6):394-404.
- Brach JS, Talkowski JB, Strotmeyer ES, Newman AB. Diabetes mellitus and gait dysfunction: possible explanatory factors. *Physical therapy*. Nov 1. 2008; 88(11):1365-74.
- Sinacore DR, Gutekunst DJ, Hastings MK, Strube MJ, Bohnert KL, Prior FW, Johnson JE. Neuropathic midfoot deformity: associations with ankle and subtalar joint motion. *Journal of foot and ankle research*. Dec. 2013;

6(1):11.

24. Williams DT, Hilton JR, Harding KG. Diagnosing foot infection in diabetes. *Clinical Infectious Diseases*. Aug 1. 2004; 39(2):83-6.
25. Chuan F, Tang K, Jiang P, Zhou B, He X. Reliability and validity of the perfusion, extent, depth, infection and sensation (PEDIS) classification system and score in patients with diabetic foot ulcer. *PloS one*. Apr 13. 2015; 10(4):e0124739.