



ISSN: 2395-1958
IJOS 2018; 4(4): 866-874
© 2018 IJOS
www.orthopaper.com
Received: 04-08-2018
Accepted: 08-09-2018

Dr. Gururagavendra.P
MBBS, D Ortho, DNB Ortho
Registrar in Orthopaedics,
Devadoss multispecialty
Hospital, Madurai, Tamil Nadu,
India

Dr. Sathish Devadoss
MBBS, MS Ortho, Mch Ortho (UK),
FASIF (AUS)
Consultant and HOD, Institute
of Orthopaedic Research and
Accident Surgery, Devadoss
Multispecialty Hospital,
Madurai, Tamil Nadu, India

Dr. Jayakumar S
MBBS, D Ortho, DNB Ortho,
MNAMS, FISS
Consultant ortho surgeon,
Devadoss multispecialty
Hospital, Madurai, Tamil Nadu,
India

Prof. A.Devadoss
MBBS, Mch Ortho, FRCS(Edin),
FRCS(Glasgow), DSC
Director and Senior Orthopaedic
Surgeon, Devadoss
multispecialty Hospital,
Madurai, Tamil Nadu, India

Correspondence
Dr. Gururagavendra.P
Registrar in Orthopaedics,
Devadoss multispecialty
Hospital, Madurai, Tamil Nadu,
India

Randomised comparative study in management of unstable intertrochanteric fracture with PFN V/S PFN A2 - functional and radiological out-come

Dr. Gururagavendra.P, Dr. Sathish Devadoss, Dr. Jayakumar S and Prof. A.Devadoss

DOI: <https://doi.org/10.22271/ortho.2018.v4.i4l.112>

Abstract

A prospective, randomized, comparative study, this study was conducted in Institute Of Orthopaedic Research and Accident Surgery (IORAS) Devadoss Multispecialty Hospital, Madurai, Tamil Nadu. Study period of Two years from April 2016 – May 2017. Since this fracture is more common in the elderly patients, the aim of treatment is prevention of mal union and early mobilization, taking all the factors into consideration surgery by internal fixation of the fracture is ideal choice. A wide modalities of internal fixation are available for the management of these fractures, most commonly used implant is dynamic hip screw(DHS) with side plate, this is a controlled collapsible fixation device, unstable intertrochanteric fracture are difficult to treat, so intramedullary devices such as proximal femoral nail(PFN) are biomechanically stronger and more rigid compared to extramedullary devices such as DHS, PFN also has showed more number of post-operative complications like implant failure, screw cutout in case of unstable intertrochanteric fractures, to improvise in 2009 AO/ASIF introduced Proximal femoral nail antirotation (PFN A2) which claimed better rotation and angular stability with helical blade and better functional outcome in treating unstable intertrochanteric fractures when compared to PFN. So to evaluate and compare functional and radiological outcome of the patients having unstable intertrochanteric fractures treated by two different methods of fixation with PFN and PFNA2. This study is taken up to find out the efficacy of newer implant PFN A2 over PFN.

Keywords: unstable intertrochanteric fractures, dynamic hip screw (DHS), PFN, antirotation

Introduction

Intertrochanteric fractures are devastating injuries that most commonly affect the elderly and also in young, have a tremendous impact on both the health care system and society in general. Despite marked improvements in implant design, surgical technique and patient care, intertrochanteric fractures continue to consume a substantial proportion of our health care resources.

Trochanteric fractures are common in the elderly people. The frequency of these fractures has increased primarily due to the increasing life span and more sedentary lifestyle brought on by urbanization. Trochanteric fractures occur in the younger population due to high velocity trauma, whereas in the elderly population it is most often due to trivial trauma.

Intertrochanteric fractures are defined as “fractures involving upper end of femur through and in between both trochanters with or without extension into upper femoral shaft.” An increasing incidence of intertrochanteric fractures with advancing age is well known, more in men than women, about 1.5: 1, being outside the joint capsule 1, 2. Intertrochanteric fractures are the most frequently operated fractures and has the highest mortality and morbidity rates.

More than 20000 fractures occur every year, and the incidence is expected to double by year 2020, the trochanteric fractures can be managed by conservative methods and there is usually union of the fracture. If suitable precautions are not taken the fracture undergoes malunion, leading to varus and external rotation deformity at the fracture site and shortening and limitation of hip movements. It is also associated with complications of prolonged immobilization like bedsores, deep vein thrombosis, urinary tract infections and respiratory infections. Since this fracture is more common in the elderly patients, the aim of treatment

should be prevention of malunion, and early mobilization. Taking all the factors into consideration surgery by internal fixation of the fracture is ideal choice [3]. A wide modalities of internal fixation are available for the management of these fractures, most commonly used implant is dynamic hip screw (DHS) with side plate, this is a controlled collapsible fixation device, Unstable intertrochantric fracture are difficult to treat so Intramedullary devices such as Proximal femoral nail (PFN) are biomechanically stronger and more rigid compared to extramedullary devices such as DHS5. PFN also has showed more number of post-operative complications, like implant failures, screw cut out in case of unstable intertrochantric fractures 6 To improvise, in 2009 AO/ASIF introduced Proximal femoral nail antirotation (PFNA 2). PFNA2 claimed better rotation and angular stability with helical blade and better functional outcome in treating unstable intertrochantric fractures when compared to PFN7. In spite of the advances in anesthesia, and surgical techniques, hip fractures remain a significant cause of morbidity and mortality in the elderly population. In view of these considerations, to evaluate and compare the functional and radiological outcome of the patient having unstable intertrochantric fractures treated by two different methods of fixation with PFN and PFNA2, this study is taken up, to find out the efficacy of newer implant PFNA2 over PFN.

Aim: To evaluate and compare the functional and radiological outcome of patients having EVAN'S unstable intertrochantric fractures treated by two different methods of intramedullary fixations PFN and PFNA2.

Objectives

- To assess the stability of fixation and early mobilization of patients.
- To analyze the radiological and functional outcome of treatment of Intertrochanteric fractures using Proximal Femoral Nail,
- To compare the results of PFN with PFNA2 and draw conclusion with help of Standard studies.

Material and Methods

Study Design: A prospective, randomized, comparative study.
Study site: This study was conducted in Institute Of Orthopaedic Research And Accident Surgery (IORAS), Devadoss Multispeciality Hospital – Madurai, Tamil Nadu.
Study Period: Two Years
Study duration: April 2016 – May 2017
Sample Size calculation:

This is a randomized study to compare the efficacy of PFN and PFN A2 in the management of unstable intertrochantric fractures. Blood loss is an outcome variable in this study.

Sampling Procedure : Since only a limited number of cases satisfying the Inclusion and Exclusion criteria are expected in this Institution during the Study period, all consecutive cases satisfying the Inclusion and Exclusion criteria were included in the study without any sampling.

Inclusion Criteria

1. Patients who are skeletally mature (25 to 95 yrs),
2. Patients with unstable intertrochantric fractures,
3. Medically fit patients,
4. Patients with closed fractures,

Exclusion Criteria

1. Patients with pathological fractures,
2. Patients who are medically unfit for surgery,
3. Patients with open injuries,
4. Patients who have unstable intertrochantric fractures with sub trochantric extension.

Pre-Operative Evaluation

Patient with suspected trochanteric fracture satisfying inclusion and exclusion criteria were included in study, necessary clinical and radiological evaluation was done and admitted to the ward after necessary resuscitation, urinary catheterization and splintage of limb using skin traction.

In our study patients with singh's grade 3 and below were considered osteoporotic and evaluated with Dual energy x ray absorptiometry (DXA) and T score was calculated for confirmation at 1st month follow up.

All the patients were evaluated for associated medical problems and necessary treatment were given. Associated injuries were evaluated and treated simultaneously. All the patients underwent Pre anaesthetic check up, once they are fit, they were operated within 24- 48 hrs (as early as possible) with either proximal femoral nail or PFNA2. Patients were allotted in two groups by simple randomization method in operation theatre using shuffled chits. Clearance from institutional ethical and scientific committee has been taken to conduct the study.

Proximal Femoral Nail implant details

The implant consists of a proximal femoral nail, self tapping 6.5mm hip pin, self-tapping 8mm femoral neck screw, 4.9mm distal locking bolts, and an end cap. Proximal femoral nail is made up of either 316L stainless steel or titanium alloy which comes in following sizes.

1. Length: standard PFN –250 mm Long PFN- 340- 420mm.
2. Diameter: 9,10,11,12 mm
3. Neck shaft angle range: 125⁰, 130⁰, 135⁰.

The nail is having 14mm proximal diameter. This increases the stability of the implant. There is 6⁰ mediolateral valgus angle, which prevent varus collapse of the fracture even when there is medial comminution. The distal diameter is tapered to 9 to 12 mm which also has grooves to prevent stress concentration at the end of the nail and avoids fracture of the shaft distal to the nail.

Proximally it has 2 holes the distal one is for the insertion of 8 mm neck screw which acts as a sliding screw, the proximal one is for 6.5 mm hip pin which helps to prevent the rotation. Distally nail has two holes for insertion of 4.9 mm locking bolts, of which one is static and the other one is dynamic which allows dynamization of 5 mm.

In our study we used a standard length PFN of 250 mm with distal diameter of 10, 11, 12mm. the proximal diameter of nail is 14mm. The proximal derotation screw of 6.5mm and distal lag screw of 8mm. Distal locking is done with self tapping 4.9mm cortical bolts one in static mode and the other in dynamic mode allowing 5mm dynamisation. The nail is universal with 6 degrees mediolateral angulation and with a neck shaft angle of 135 degrees. We did not use end cap.

Proximal femoral nail

PFNA2 Details

The implant consists of a proximal femoral nail, Spiral blade of 11mm for femoral neck, 4.9 distal locking bolt, and an end cap. Proximal femoral nail is made up of either 316L stainless

steel or titanium alloy which comes in following sizes.

1. Length: standard PFNA2 –200 mm, Other sizes- 170/ 240mm, long nails 260 to 420mm,
2. Diameter: 9,10,11,12 mm
3. Neck shaft angle range: 125°, 130°.

Reamers for Neck screw and Hip pin Hip pin and Neck screw PFN with aiming device and sleeves Implant set for PFN The nail is having 17mm proximal diameter. This increases the stability of the implant. There is 5° mediolateral valgus angle, allows insertion at the tip of the greater trochanter, It has one hole proximally for insertion of 11mm spiral blade and distally it has one hole for 4.9mm locking bolt, locking can be done with the help of aiming arm in dynamic or static mode. In our study we used standard nail length of 200mm with distal diameter of 10, 11 mm. Patients who are all medically fit and x rays shows unstable intertrochantric fractures are posted for closed reduction and internal fixation with PFN, In operating room patients are randomly allocated into two groups by simple randomization.

1. Group A: PFN group,
2. Group B: PFN A2 group.

Results

A. Profile of Cases Studied

Table A1: Number of cases studied with the two types of implant

Implant used	Cases studied	
	No.	%
PFNA 2	15	48.4
PFN	16	51.6
Total	31	100

In total of 31 cases, PFN was done for 16 patients and PFN A2 was done for 15 patients.

Table A2: Age distribution

Implant used	Age (years)		
	Range	Mean	S.D.
PFNA 2	35 – 80	69.1	12.0
PFN	39 – 87	69.9	14.9
'p'	0.8694 Not significant		

Mean age was 69.1 years in PFN A2 group and 69.9 years in PFN group.

Table A3: Sex distribution

Implant used	Sex			
	Males		Females	
	No.	%	No.	%
PFNA 2	9	60.0	6	40.0
PFN	11	68.8	5	31.3
'p'	0.6167 Not significant			

In our study in total of 31 cases, 20 are males and 11 are females.

Table A4: Side involved

Implant used	Side			
	Left		Right	
	No.	%	No.	%
PFNA 2	9	60.0	6	40.0
PFN	9	56.3	7	43.8
'p'	0.8352 Not significant			

In our study one patient had both bone forearm fracture which was treated by plating, other 3 patients with scaphoid fracture, D12 compression fracture and 2nd metacarpal fracture were treated conservatively.

Table A6: Time interval between injury and surgery

Implant used	Time interval between injury and surgery(days)		
	Range	Mean	S.D.
PFNA 2	1 – 3	1.2	0.56
PFN	1 -4	1.44	0.96
'p'	0.4127 Not significant		

All the cases included in our study group were fresh fractures who underwent surgery at the earliest possible in our set up. The delay was due to associated injuries, medical condition of the patients. All the patients were operated at an average interval of one and half day from the date of trauma.

Table A6: Time interval between injury and surgery

Implant used	Time interval between injury and surgery(days)		
	Range	Mean	S.D.
PFNA 2	1 – 3	1.2	0.56
PFN	1 -4	1.44	0.96
'p'	0.4127 Not significant		

All the cases included in our study group were fresh fractures who underwent surgery at the earliest possible in our set up. The delay was due to associated injuries, medical condition of the patients. All the patients were operated at an average interval of one and half day from the date of trauma.

Table B2: Functional Outcome

Functional Outcome	Implant used			
	PFNA 2		PFN	
	No.	%	No.	%
Excellent	4	26.7	3	18.8
Good	9	60.0	6	37.5
Fair	2	13.3	7	43.7
'p'	0.1419 Not significant			

In our study, According to Harris Hip Scoring System (Modified), we had Good to excellent results in in 86.7%, Fair in 13.3%. we had no case with poor results.

B: Efficacy of the Two Implants

Table B1: Harris Hip Score

Implant used	Harris Hip Score		
	Range	Mean	S.D.
PFNA 2	70 – 74	83.6	6.8
PFN	71 – 94	81.9	7.2
'p'	0.5148 Not significant		

In our study average surgical time in PFN A2 group is about 59 mins and in PFN group it's about 71.9 mins which is statistically significant.

Table B6: Surgical blood loss

Implant used	Surgical blood loss (ml)		
	Range	Mean	S.D.
PFNA 2	90 – 120	98.9	9.2
PFN	110 – 140	123.1	10.1
'p'	< 0.0001 Significant		

In our study mean blood loss in PFN A2 group is 98.9 ml and PFN group is 123.1ml which is statistically significant.

Table B7: Complications

Implant used	Complications			
	Present		Absent	
	No.	%	No.	%
PFNA 2	2	13.3	13	86.7
PFN	3	18.7	13	81.3
'p'	0.9372 Not significant			

In our study FOUR patients had coxa vara, one patient had screw cut out in PFN A2 group, one patient had compression screw head breakage in PFN group.

Table B8: SINGH'S Index and Implants used

Singh's Index	No. of cases		Implants used			
			PFN		PFNA2	
	No.	%	No.	%	No.	%
Grade 2	8	25.8	3	37.5	5	62.5
Grade 3	14	45.2	8	57.1	6	42.9
Grade 4	6	19.3	3	50.0	3	50.0
Grade 5	3	9.7	2	66.7	1	33.3
Total	31	100	16	51.6	12	48.4
'p'	0.8694 Not significant					

In our study about 71% of the patients were diagnosed to have osteoporosis, but osteoporosis in both the groups were comparable

Table B9: Singh's Index and DXA T Score (BMD)

Singh's Index	DXA T Score (BMD)	
	Mean	S.D.
Grade 2	-3.74	0.3
Grade 3	-3.71	0.41
'p'	0.858 Not significant	

Mean BMD in our study is about -3.7 and there was no correlation between Singh's index and BMD.

Table B2: Functional Outcome

Functional Outcome	Implant used			
	PFNA 2		PFN	
	No.	%	No.	%
Excellent	4	26.7	3	18.8
Good	9	60.0	6	37.5
Fair	2	13.3	7	43.7
'p'	0.1419 Not significant			

In our study, According to Harris Hip Scoring System (Modified), we had Good to excellent results in in 86.7%, Fair in 13.3%. we had no case with poor results.

Table B3: Time for Radiological Union

Implant used	Time for Radiological Union (weeks)		
	Range	Mean	S.D.
PFNA 2	13 – 22	15.3	2.3
PFN	13 – 24	15.8	2.4
'p'	0.5783 Not significant		

In our study on an average of 15 wks all fractures united, two of the cases had delayed union at 22 weeks.

Table B4: Tip / Apex distance

Implant used	Tip / Apex distance (mm)		
	Range	Mean	S.D.
PFNA 2	16.5 – 26	22.24	2.33
PFN	20.0 – 26	23.78	1.62
'p'	0.0399 Significant		

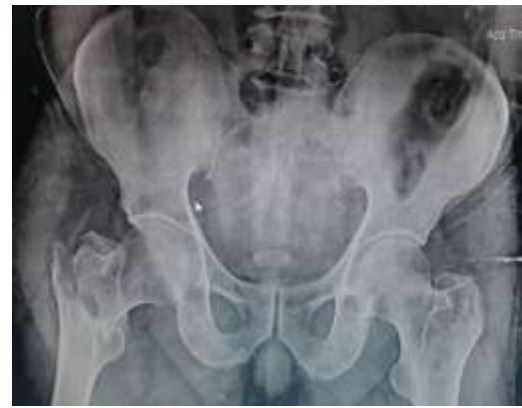Average tip apex distance in PFN A2 is 22. 24mm and in pfn group it is 23.78mm which is significant.

Table B5: Surgical time

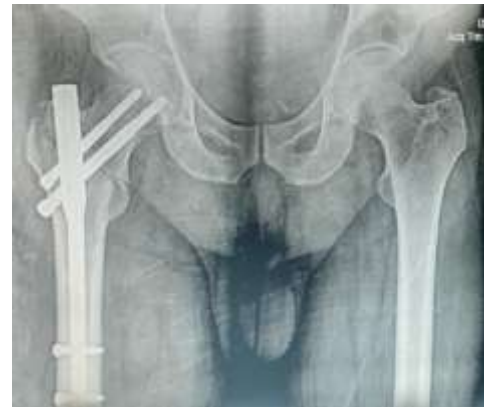Implant used	Surgical time (minutes)		
	Range	Mean	S.D.
PFNA 2	50 – 65	59.0	5.1
PFN	65 – 85	71.9	5.4
'p'	< 0.0001 Significant		

Clinical Cases

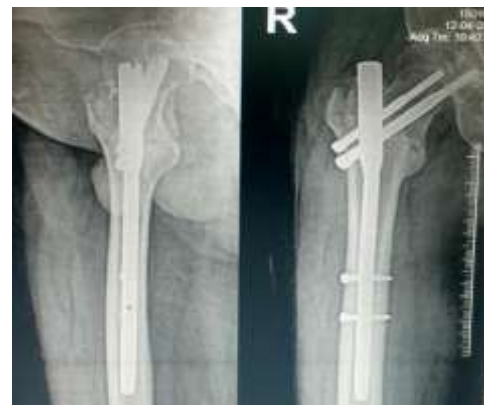Case 1: (Master chart reference no: 8) unstable fracture with singh's grade 3 and lateral wall thickness – 15mm.



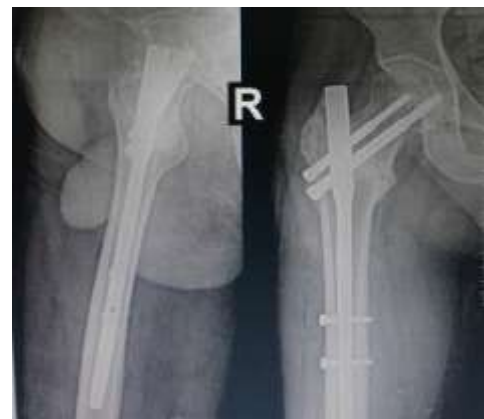Pre op x-ray



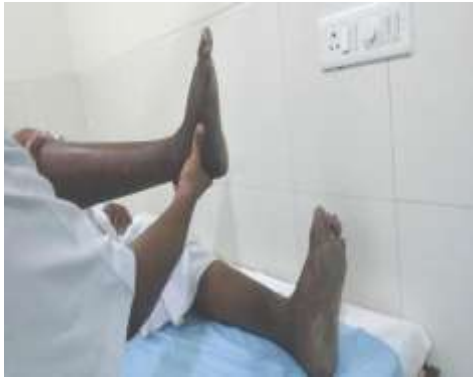Immediate post op x-ray



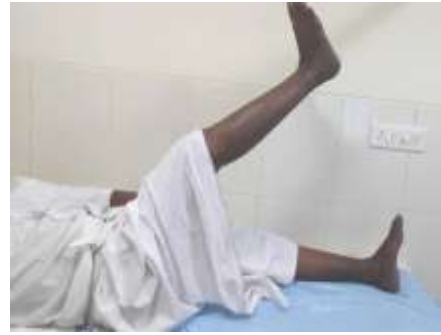3 months follow up



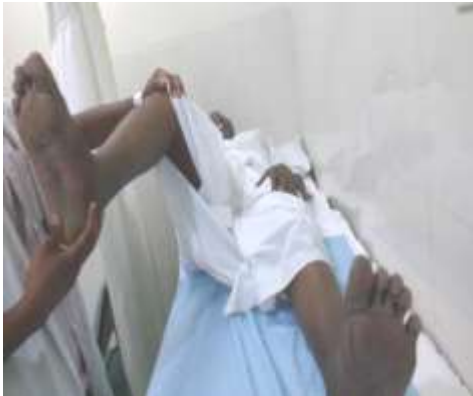6 months follow up



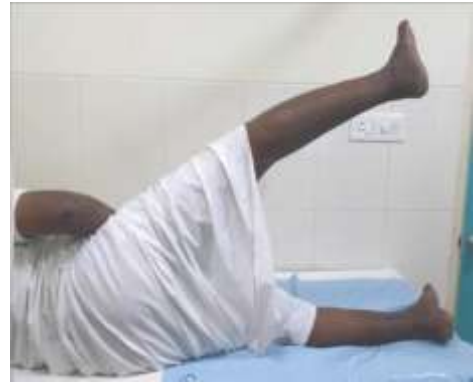External rotation



Hip flexion



Internal rotation

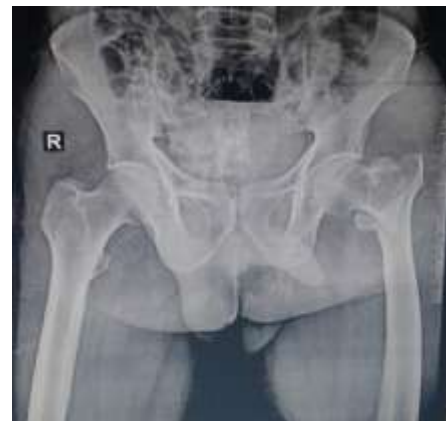

Hip Abduction

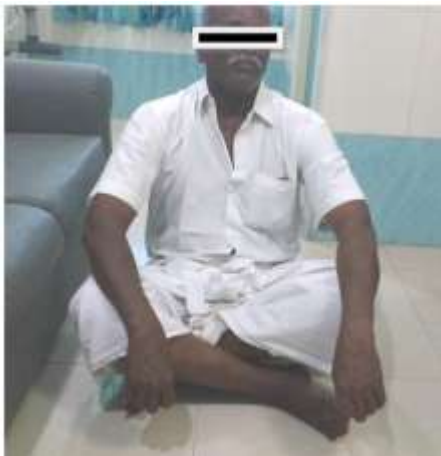Case 2: (Master chart reference no: 17) Unstable fracture with posteromedial comminution with singh's grade 2 and lateral wall thickness 19mm.



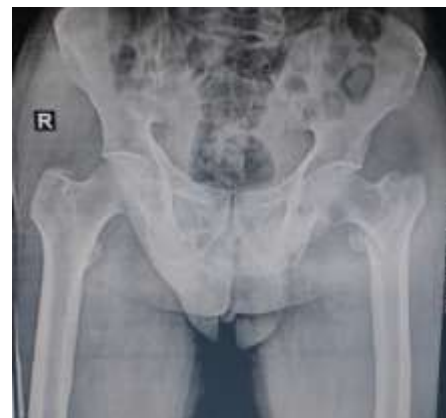Squatting



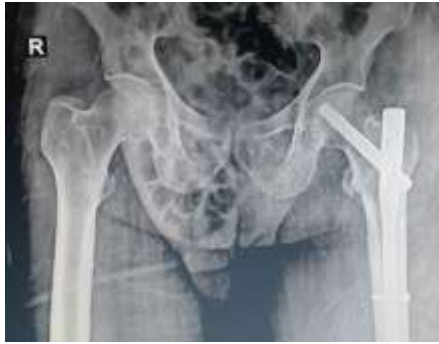Pre-operative pic (Without traction)



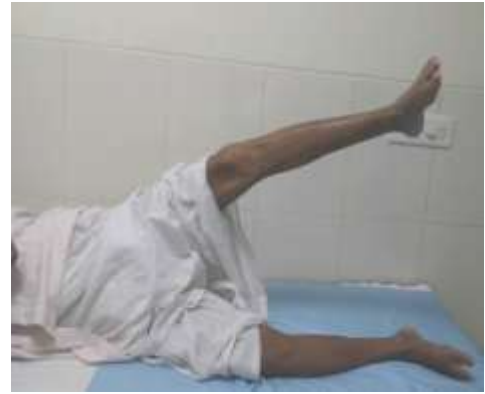Sitting cross legged



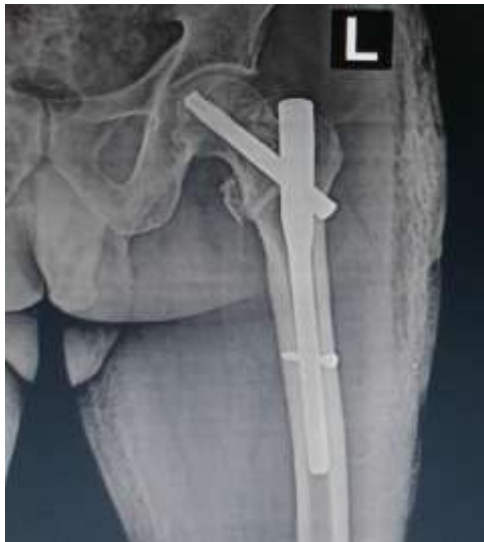With traction and internal rotation



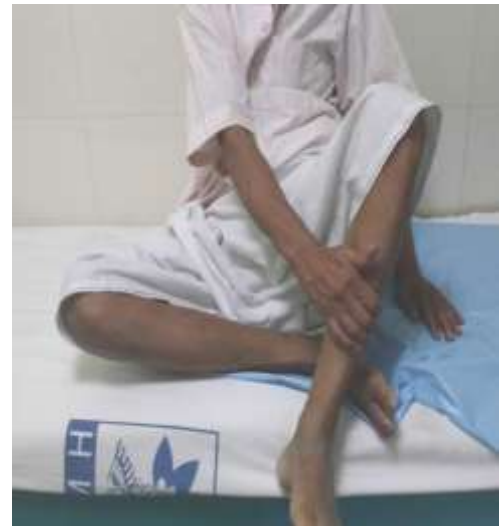Immediate post-operative



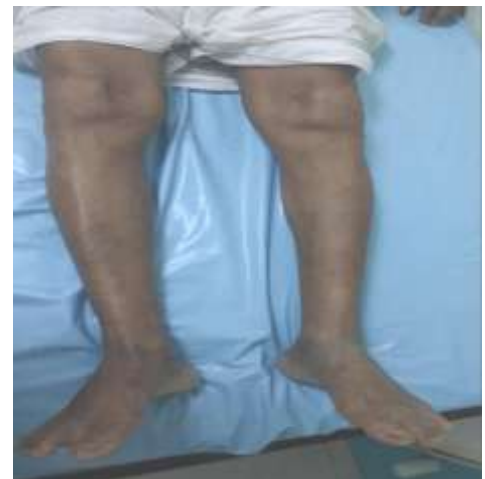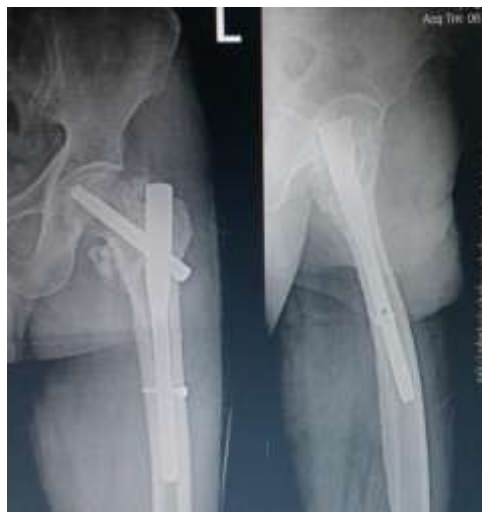Abduction



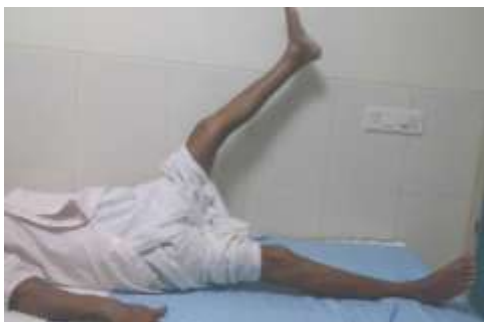One month followup



Sitting cross legged (restriction of abduction)



No limb length discrepancy



Hip flexion

Discussion

The treatment of intertrochanteric fractures of the proximal femur is still associated with some failures. The reasons are disregard for biomechanics, overestimation of the potentials of new surgical techniques or new implants or poor adherence to established procedures. High stress concentration that is subject to multiple deforming forces, slow healing time because of old age, high incidence of complications reported after surgical treatment compels the surgeon to give a second thought regarding selection of the proper implant.

The most common current modes of fixation are Sliding screw systems and Intramedullary devices. From the mechanical point of view, a combined intramedullary device

inserted by means of minimally invasive procedure seems to be better in elderly patients. Closed reduction preserves the fracture haematoma, an essential element in the consolidation process. Intramedullary fixation allows the surgeon to minimize soft tissue dissection there by reducing surgical trauma, blood loss, infection, and wound complications.

PFN is a novel, modern intramedullary implant based on experience with the gamma nail. The currently used gamma nail as an intramedullary device also has a high learning curve with technical and mechanical failure rates of about 10%. The gamma nail is susceptible to fail at its weakest point, the lag screw-implant interface.

The Arbeitsgemeinschaft für Osteosynthesefragen (AO ASIF) in 1996, therefore developed the proximal femoral nail with an antirotational hip pin together with a smaller distal shaft diameter which reduces stress concentration to avoid these failures. Proximal femoral nail has all advantages of an intramedullary device, such as decreasing the moment arm, can be inserted by closed technique, which retains the fracture haematoma an important consideration in fracture healing, decrease blood loss, infection, minimizes soft tissue dissection and wound complications.

PFN A2 is a novel implant in which a spiral blade replaces the compression screw and antirotation screw of PFN, Insertion of the blade compacts the cancellous bone. These characteristics provide optimal anchoring and stability when the implant is inserted into osteoporotic bone and have been bio-mechanically proven to retard rotation and varus collapse. The inserted PFNA blade achieves an excellent fit through bone compaction and requires less bone removal compared to a screw. In an experimental study, Gotze *et al.* [9]. (1998) compared the loadability of osteosynthesis of unstable per and subtrochanteric fractures and found that the PFN could bear the highest loads of all devices.

Li *et al.* [2] In 2015, concluded that in PFNA2 innovative helical blade design provides better hold on both compact and cancellous bone, increases contact area between implant and femoral head and less incidence of screw cut out in unstable fractures. In our study we wanted to compare the functional and radiological outcome of patients operated with PFN and PFNA2 who had Evans' unstable type of intertrochanteric fractures.

In our study total of 31 patients operated for unstable intertrochanteric fractures, out of which in 15 patients PFN A2 was used and in 16 patients PFN was used, mean age of patients in our study is about 69.1 yrs (35 – 80) in PFN A2 group and 69.9 (39 -87) yrs in PFN group with average followup of 1 yr. About 87% of our patients had sustained injury due to a trivial fall which is an indirect measure of osteoporosis, out of 31, 20 were males and 11 were females, with predominant involvement of left side (60%).

Pre operatively instability of the fracture was assessed using Evans' classification, posteromedial comminution and lateral cortical thickness, All the 31 patients had posteromedial comminution and in all the cases lateral wall thickness was less than 20mm except for one patient who had thickness of 24mm but with posteromedial comminution,

C-E. Hsu *et al.* - concludes that: lateral wall thickness is a reliable predictor of post-operative lateral wall fracture, lateral wall thickness < 20.5 mm should not be treated with an extramedullary implant.

Weon-Yoo Kim *et al.* [10] suggest that the use of Evans' classification and Singh's classification for femoral intertrochanteric fractures on the basis of a pre-operative radiograph allows for an accurate prediction of any post-

operative failure of fixation and maintenance of reduction, both classifications were used in our study,

Babst R *et al.* [11] concludes that in unstable intertrochanteric fractures with small lateral cortical buttress, addition of trochanteric support plate with dynamic hip screw effectively supports the fracture.

All the patients were assessed pre operatively for the quality of bone by using Singh's index, the proximal femoral trabeculae of opposite normal side is assessed and graded, patients with grade 3 or below were considered to have osteoporosis which is about 22 patients out of 31, these patients were assessed further with bone mineral density by DXA scan at one month follow up, as Singh's grading has high intra and inter observer variability as concluded by V.C.M. Koot *et al.* [12] who concluded that the Singh index has no value in assessing the grade of osteoporosis. In our study there was no correlation between Singh's and BMD.

Ming Hui Li *et al.* [13]., Statistical analysis revealed an average operation time of 45.7 min (range, 35–110 min), average intraoperative blood loss of 115.2 mL (range, 65–430 mL), The Harris hip score was 85.6 ± 17.5 points (range, 65–100 points) and included 41 excellent cases (25.15%), 92 good cases (56.44%), 26 moderate cases (15.95%), and 4 poor cases (2.45%) for a positive outcome rate of 81.60%. The patients comprised 69 men and 94 women with a mean age of 74.7 ± 13.0 years.

Mohan N. S *et al.* [3]. Out of 88 total cases 80 patients (50 males and 30 females). The mean operative time in PFNA was 50 minutes, Whereas 80 minutes in PFN, mean blood loss in case of PFNA is 110ml, Whereas in PFN is 150ml, The time of union in PFNA group is 12 weeks, In PFN group it is 14 weeks. One case screw cut out Z effect was noted, One case of broken nail at distal locking site, and One case of broken distal locking screw was noted. In PFNA group 36 cases (90%) showed excellent results 4 cases (10%) showed good results, Whereas in PFN group 30 cases (75%) showed excellent results, 8 cases (20%) showed good results and 2 cases (5%) showed poor results.

In our study totally 4 patients had associated fractures, one had scaphoid fracture which was treated conservatively with cast for 6 wks, one had 2nd metacarpal fracture and one patient had D12 compression fracture which was treated conservatively, one patient had both bone forearm fracture which was treated by plating on the same sitting. All the patients were operated on first or second day of admission once they were evaluated and stabilized.

On regular followup all the patients were assessed radiologically, all patients went in for union at average of 15 weeks except two, in one of the case in PFN A2 group, spiral blade Cut out was there with varus collapse and in one of the Case in PFN group hip screw was broken insitu, in both the cases implant removal was done and hemiarthroplasty was done with bipolar prosthesis.

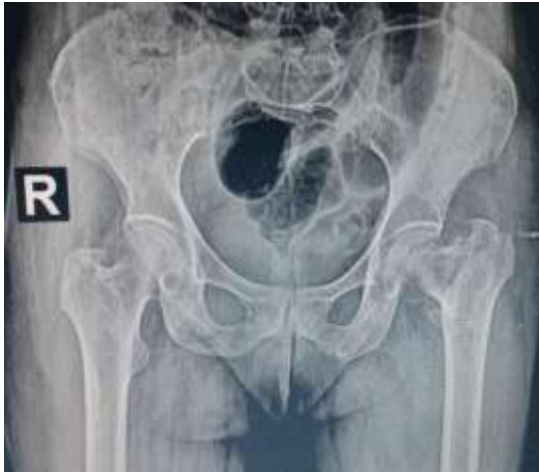In our study 3 patients had coxa vara at the time of fixation, but everyone's fracture was united and two of them had fair functional outcome and one of them had good functional outcome.

On comparing both the groups, age, sex, side affected, mode of injury, number of cases of osteoporosis were comparable in both the groups, except for the surgical time and intra operative bleeding which is statistically significant, in which both are less in PFN A2 group compared to the PFN which we attribute to single proximal spiral blade and distal locking screw in PFN A2 as compared to two proximal screws and two distal screws in PFN which is responsible for delay in the

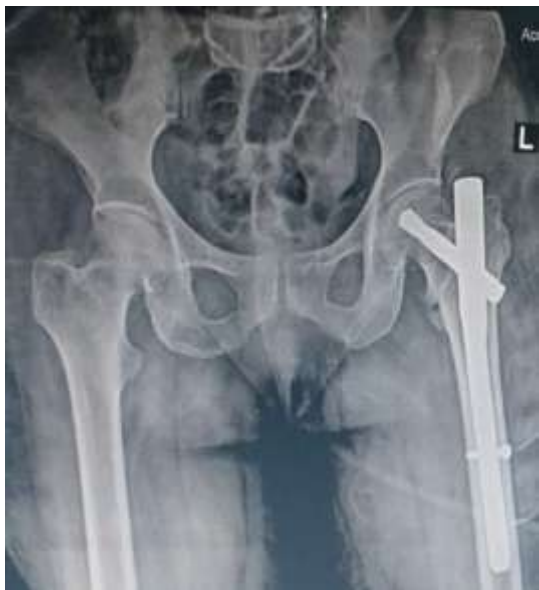operation time.

In our study as compared to Ming Hui Li *et al.* [13] and Mohan N. S *et al* [1] average surgical time in PFN A2 group is 59mins and in PFN group is 71.9 mins which is statistically significant and average blood loss in PFN A2 group is 98.9ml and in PFN group is 123.1ml which is also statistically significant and comparable to Suk Kyu Choo *et al.* [3].

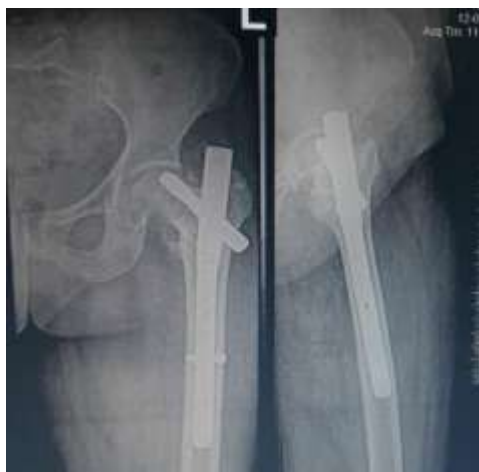CASE 1: (Master chart reference no 6).



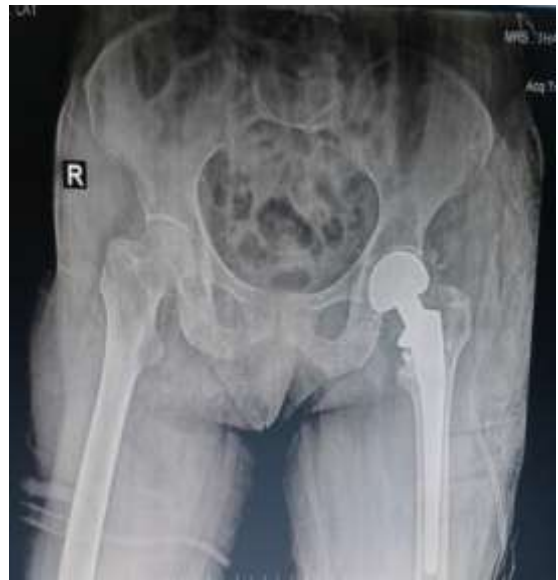Pre-operative



Immediate post-operative

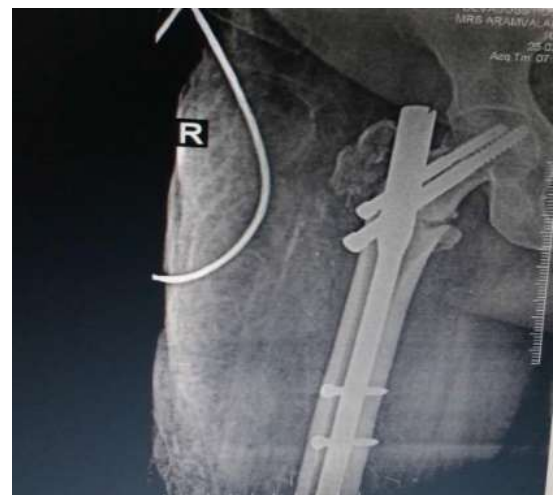


Screw cutout at 3months

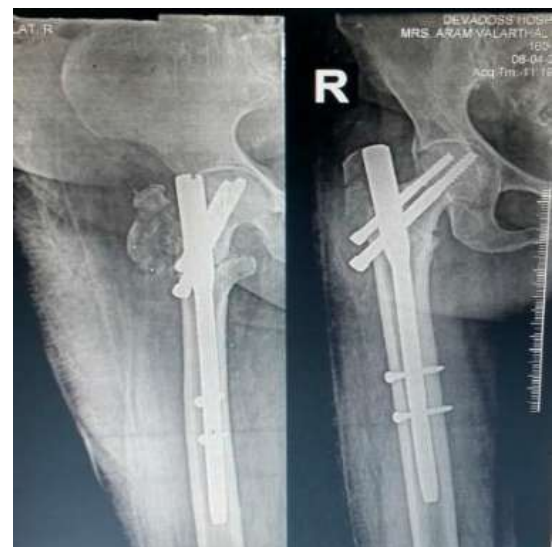

After hemiarthroplasty

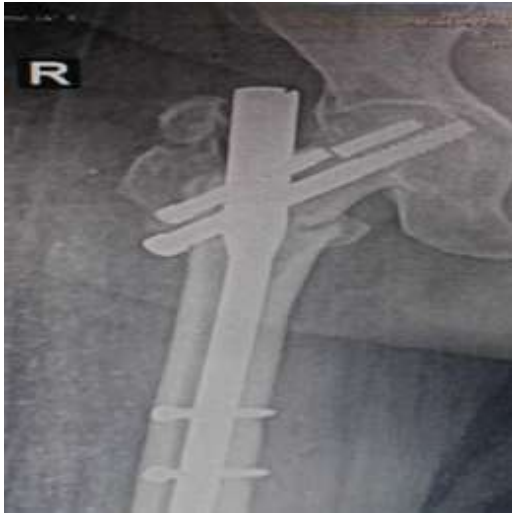Case NO 2: (Master chart reference no 11)



Immediate post-operative



6 months followup



8 months followup with

Finally in our study Functional outcome was assessed using modified harris hip scoring at 6 months followup in PFN A2 group 4 patients (26.7%) had excellent outcome, 9 patients (60%) had good outcome and 2 patients (13.3%) had fair outcome and in PFN group 3 patients (18.8%) had excellent outcome, 6 patients (37.5%) had good outcome, 7 patients (43.7%) had poor outcome which was comparable to Ming Hui Li *et al.* [13] Our results are comparable to Sheng zhang *et al.*, [13] who had less mean operative time and less blood loss in PFN A2 group compared to intertan nail, and they conclude that patients in PFN A2 group had more lateral thigh pain, but in our study none of our patients had lateral thigh pain.

Conclusion

Results suggest that age group, sex, mode of injury, side involved were comparable between both the groups, Mean time for radiological union and functional outcome was comparable in both the groups, Mean operative time and blood loss was lesser in PFN A2 group compared to PFN, This study concludes that both the implants have comparable radiological and functional outcome for unstable intertrochanteric fracture except for less surgical time and blood loss in PFN A2, Complications such as proximal migration spiral blade into the hip joint and lateral thigh pain were not seen in this study, About 71% of patients had osteoporosis in our study, as this fracture is common in elderly, Superiority of one implant over another could be arrived with still larger sample size, involving multi centre studies.

References

1. Mohan NS, Shivaprakash SU, Sridhar. "PFNA v/s PFN in the Management of Unstable Intertrochanteric Fractures". *Journal of Evolution of Medical and Dental Sciences* 2015; 4(24):4086-4091, DOI: 10.14260/jemds/2015/590.
2. Li. *et al.*: Clinical evaluation of the Asian proximal femur intramedullary nail antirotationsystem (PFNA2) for treatment of intertrochanteric fractures. *Journal of Orthopaedic Surgery and Research*. 2014; 9:112.
3. Suk Kyu Choo *et al.* PFNA and PFN in Intertrochanteric Fractures - Comparison study of sliding "- J. Korean Hip Society: Korean, 2010; 22(1):79-85.
4. Lateral femoral wall thickness C-E. Hsu, C-M. Shih, C-C. Wang, K-C. Huang *Bone Joint J*. 2013; 95-B(8):1134-1138; DOI: 10.1302/0301-620X.95B8.31495.

5. Singh M, Nagrath AR, Maini PS. Changes in trabecular pattern of the upper end of the femur as an index of osteoporosis. *J Bone Joint Surg [Am]*. 1970; 52-A:457-67.
6. Geller JA, Saifi C, Morrison TA, Macaulay W. Tip-apex distance of intramedullary devices as a predictor of cut-out failure in the treatment of peritrochanteric elderly hip fractures. *International Orthopaedics*. 2010; 34(5):719-722. doi:10.1007/s00264-009-0837-7.
7. Baumgaertner MR, Curtin SL, Lindskog DM. Intramedullary versus extramedullary fixation for the treatment of intertrochanteric hip fractures. *Clin Orthop Relat Res*. 1998; (348):87-94
8. Sadic S, Custovic S, Jasarevic M, Fazlic M, Krupic F. Proximal Femoral Nail Antirotation in Treatment of Intertrochanteric Hip Fractures: a Retrospective Study in 113 Patients. *Medical Archives*. 2015; 69(6):352-356. doi:10.5455/medarh.2015.69.353-356.
9. Götze B, Bonnaire F, Weise K, Friedl HP. Belastbarkeit von Osteosynthesen bei instabilen per- und subtrochanteren Femurfrakturen: experimentelle Untersuchungen mit PFN, Gamma-Nagel, DHS/ Trochanterstabilisierungsplatte, 95°-Kondylenplatte und UFN/ Spiralklinge. *Aktuelle Traumatologie*. 1998; 2(8):197-204, 108
10. Kim WY, Han CH, Park JI, *et al.* *International Orthopaedics (SICOT)*, 2001; (25):360. <https://doi.org/10.1007/s002640100287>. Clinical results using the trochanter stabilizing plate:the modular extension of the dynamic hip screw for internal fixation of selected unstable intertrochanteric fractures., Babst R, *et al.* *J Orthop Trauma*. 1998; 12(6):392-9.
11. Koot VC, Kesselaer SM, Clevers GJ, Hooge PD, Weits T, Werken C. Evaluation of the Singh index for measuring osteoporosis. *J Bone Joint Surg [Br]*. 1996; 78:831-834.
12. Li M, Wu L, Liu Y, Wang C. Clinical evaluation of the Asian proximal femur intramedullary nail antirotation system (PFNA-II) for treatment of intertrochanteric fractures. *Journal of Orthopaedic Surgery and Research*. 2014; 9:112. doi:10.1186/s13018 014-0112-5.
13. Zhang S, Zhang K, Jia Y, Yu B, Feng W. Inter Tan Nail Versus Proximal Femoral Nail Antirotation-Asia in the Treatment of Unstable Trochanteric Fractures. *Orthopaedics*. 2013; 36:182-183, e288-e292. doi: 10.3928/01477447 20130222-16.