



ISSN: 2395-1958
IJOS 2018; 4(4): 904-908
© 2018 IJOS
www.orthopaper.com
Received: 19-08-2018
Accepted: 20-09-2018

Rakesh Kumar Verma
Consultant Orthopaedic Surgeon,
District hospital, Bahraich, MLN
Medical College, Prayagraj,
Uttar Pradesh, India

Ajay Kumar Verma
Associate Professor, MLN
Medical College, Prayagraj,
Uttar Pradesh, India

Karunakar dwivedi
Associate Professor MLN
Medical College, Prayagraj,
Uttar Pradesh, India

Vinod Kumar Singh
Senior Resident, MLN Medical
College, Prayagraj, Uttar
Pradesh, India

Vijay Shankar
Resident, Department of
Orthopaedics, MLN Medical
College, Prayagraj, Uttar
Pradesh, India

Correspondence
Ajay Kumar Verma
Associate Professor, MLN
Medical College, Prayagraj,
Uttar Pradesh, India

A prospective comparative study between conservative and operative treatment with dynamic hip screw in the management of intertrochanteric fracture of the femur

Rakesh Kumar Verma, Ajay Kumar Verma, Karunakar dwivedi, Vinod Kumar Singh and Vijay Shankar

DOI: <https://doi.org/10.22271/ortho.2018.v4.i4l.119>

Abstract

Introduction: Trochanteric fracture of femur is extremely common in elderly age group. Nowadays, most of these fractures will be surgically fixed with implants. However, some patients can be treated with conservative treatment but internal fixation with Dynamic hip screw is most acceptable method and has better outcome. The aim of present study is to compare the result of conservative method and operative treatment with dynamic hip screw in management of intertrochanteric fracture of the femur in rural population where modern surgical facilities are unavailable.

Material and Method: In our study sixty patients were selected for the study out of which 40 patients were treated with operative method with dynamic hip screw (DHS) and twenty patient were treated with conservative method. The conservative group and the operative group are classified as Group I and Group II respectively. The result were evaluated and graded as excellent, good and poor as per Kyle's criteria.

Result: In the present study in Group I, 20% had union in 8 weeks, 60% in 10 – 12 weeks and 20% in more than 12 weeks. In Group II, 50% had union in 6 weeks, 40% in 6-8 weeks and 10% in more than 8 weeks. In group one 4 (20%) patients has excellent result, 4 (20%) patients had good result and 12 (60%) patients had poor result whereas in Group II 32 (80%) patients had excellent result, 6 (15%) patients had good and 2 (5%) patients had poor result. In Group I, 4 (20%) patients had no complications while 16 (80%) patients had one or more complications whereas in Group II 32 (80%) patients had no complications and 8 (20%) patients had one or more complications.

Conclusion: The overall quality of result was better with internal fixation with dynamic hip screw (DHS) as compared to conservative method, avoiding all the problems of prolonged recumbency and tended to leave the hospital sooner. However, conservative treatment will be acceptable where modern surgical facilities are unavailable.

Keywords: intertrochanteric fractures, conservative management, dynamic hip screw, hip fractures

Introduction

Trochanteric fracture of femur is extremely common in elderly age group due to trivial fall and the incidence is also increasing in young person due to high energy trauma. Increase in life expectancy has led to increased incidence of fracture around the hip and has tremendous impact on both health care system and society [1]. Patient with hip fractures, regardless of whether they received surgical or nonsurgical intervention, are predisposed to high complication rates (range - 14% - 52%) [2, 4]. Conservative methods include boot and bar traction, skin traction, upper tibial skeletal traction with Thomas knee splint with the affected limb put in wide abduction. The conservative treatment require long hospital stay and prolonged bed recumbency lead to bed sore, skin infection, pin tract infection, pneumonia and stasis thrombosis. However, conservative treatment will be acceptable where modern surgical facilities are unavailable and will result in a reduction in complications associated with surgery [5]. Various operative treatment consists of internally fixing the fractures by various implants such as fixed nail plate devices, sliding nail plate devices and intramedullary devices [6].

The aim of present study is to compare the result of conservative method and operative treatment with dynamic hip screw in management of intertrochanteric fracture of the femur.

Material and Methods

This prospective comparative study has been conducted on the patient with trochanteric fracture of femur admitted in department of orthopedics and emergency in district hospital, Bahraich, and M.L.N. Medical College, Prayagraj, Uttar Pradesh from July 2016 to October 2017. In our study sixty patients were selected for the study out of which 40 patients were treated with operative method with dynamic hip screw (DHS) and twenty patient were treated with conservative method. The conservative group and the operative group are classified as Group I and Group II respectively. All the patients were subjected to detailed history, clinical examination, necessary radiological and pathological investigations. Radiological examinations will be repeated postoperatively and at the end of 6 weeks, 12 weeks, and 6 months interval.

Inclusion Criteria

For conservative treatment (Group I)

- 1) Patient who are medically unfit for surgery
- 2) Low socio-economic group
- 3) Patient who were non-ambulatory prior to sustaining fracture
- 4) Patient with severe anemia.

For operative treatment (Group II)

- 1) Patient who are medically fit for surgery
- 2) Good socio-economic status
- 3) Patient with good bone quality
- 4) Mostly unstable fracture

Patients allocated for conservative method were put on traction with affected limb in wide abduction with good nursing care. In operative method we have used DHS lag screw, DHS barrel plate, 4.5 mm cortical screw and compression screw using standard technique with lateral

approach under spinal anaesthesia with antibiotic prophylaxis.

Evaluation of the Results

The result were evaluated and graded as excellent, good and poor as per criteria of Kyle [7].

Excellent- no pain, minimum limp, normal range of motion, can walk without support, can squat and sit crossed legged, no shortening

Good - occasional mild pain, noticeable limp, acceptable range of motion, can walk with the help of cane, can squat and sit crossed legged, shortening less than 2 cm

POOR- Moderate pain, marked limp, limited range of motion, can't walk, can't squat and sit cross legged, shortening greater than 2 cm.

Statistical analysis

Data was statistically analyzed by the SPSS (Statistical Package for the Social Sciences) 18 version. Relationship between variables was tested by Chi- Square test of association. Appropriate tables and chart are prepared by using Microsoft Excel.

Results

Out of 60 cases in our study majority of patients were male i.e. 40 patients (66.6%) and female were only 20 patients (33.3%). Thus in our series overall male to female ratio was 2:1. In our study out of sixty patients 40 patients (66.6%) were treated with operative method with dynamic hip screw (DHS) and 20 patients (33.3%) were treated with conservative method. Out of 60 patients, 40 patients (66.6%) had fracture of right side and 20 patients (33.3%) had fracture of left side. The mean age of conservative group i.e. Group I was 64.6 yrs while the mean age of operative group i.e. Group II was 60.9 yrs. We have classified, in our study, intertrochanteric fracture are classified into stable and unstable group as per Boyd and Griffin classification [6]. Boyd and Griffin Type 1 and type 2 fractures are stable fractures and type 3 and type 4 are unstable fractures. Demographic characteristics of study participants in both the groups is illustrated in Table I.

Table I: Demographic characteristics of study participants in both the groups.

Variables	Group I (n = 20)	%	Group II (n = 40)	%	Total (%)	P value
Age – 18 – 40	-		2	5	2 (3.33)	0.2635*
41 – 60	6	30	16	40	22 (36.66)	
61 – 80	14	70	22	55	36 (60)	
Sex – Male	14	70	26	65	40 (66.66)	0.6985*
Female	6	30	14	35	20 (33.33)	
Mode of injury						
Fall	18	90	34	85	52 (86.66)	0.5912*
RTA	2	10	6	15	8 (13.33)	
Side affected						
Right	16	80	24	60	40 (66.66)	0.1213*
Left	4	20	16	40	20 (33.33)	
Type of fracture						
Stable	6	30	10	25	16 (26.66)	0.6797*
Unstable	14	70	30	75	44 (73.33)	

* Results are not statistically significant at 5% Level of significance (P<0.05). This may be by chance of small sample size or due to case selected (selection of sample).

In the conservative group (Group I), all the cases were immobilized for about 10 -12 weeks whereas all patients in Group II, were mobilized within a week after surgery depending upon the fracture geometry and stability of

fixation. In Group I, upper tibial skeletal traction was used in 80% of cases (Table – 2) as shown in Figure 1 whereas in Group I, 90% of cases were immobilized by Thomas knee splint (Table -3) as demonstrated in Figure 2.

Table 2: Type of traction used in Group I

Type of traction applied	No. of cases	%
Upper tibial skeletal traction	16	80
Boot and bar traction	2	10
Below knee skin traction	2	10
Total	20	100

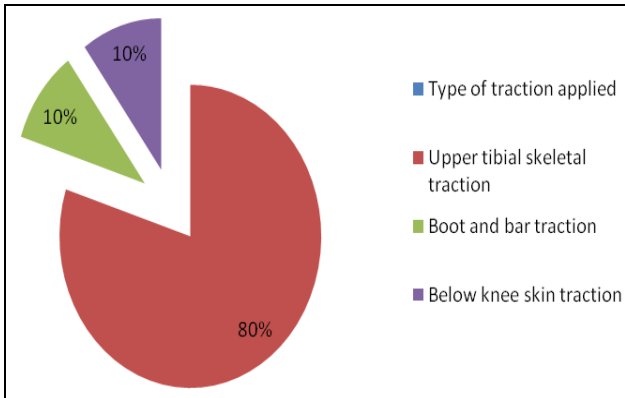


Fig 1: Percentage of type of traction used in Group I

Table 3: Method of immobilization in Group I

Methods of Immobilization	No. of cases	%
Thomas knee splint	18	90
Boot and bar	2	10
Total	20	100

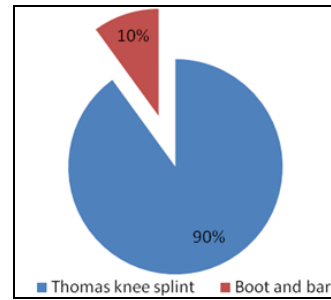


Fig 2: Method of immobilization used in Group I.

In the present study in Group I, 20% had union in 8 weeks, 60% in 10 – 12 weeks and 20% in more than 12 weeks. In Group II, 50% had union in 6 weeks, 40% in 6-8 weeks and 10% in more than 8 weeks.

After six month the result were evaluated and graded as excellent, good and poor. In group one 4 (20%) patients has excellent result, 4 (20%) patients had good result and 12 (60%) patients had poor result whereas in Group II 32 (80%) patients had excellent result, 6 (15%) patients had good and 2 (5%) patients had poor result. In Group I, 4 (20%) patients had no complications while 16 (80%) patients had one or more complications whereas in Group II 32 (80%) patients had no complications and 8 (20%) patients had one or more complications as shown in Figure 3. Anatomical and functional outcome in both the groups is depicted in Table – 4. Total outcome in both the group is illustrated in Table – 5.

Table 4: Anatomical and functional outcome in both groups

Outcome	Group I (n = 20)	%	Group II (n = 40)	%	Total (%)	P value
Shortening						
< 2 cm	4	20	6	15	10 (16.6)	0.6242
>2 cm	12	60	2	5	14 (23.3)	0.000002*
Coxa vara	12	60	-	-	12 (20)	-
Knee stiffness	14	70	-	-	14 (23.3)	-
Pressure sore	8	40	-	-	8 (13.3)	-
Superficial infection	-	-	2	5	2 (3.33)	-
Urinary tract infection	2	10	-	-	2 (3.33)	-
Pneumonia	6	30	-	-	6 (10)	-
Pin tract infection	8	40	-	-	8 (13.3)	-
Non union	-	-	-	-	0	-
No complication	4	20	32	80	36 (60)	0.000008*
Functional result						
Excellent	4	20	32	80	36 (60)	0.000008*
Good	4	20	6	15	10 (16.6)	
Poor	12	60	2	5	14 (23.3)	

* Results are highly statistically significant at 5% Level of significance (P<0.05)

Table 5: Outcome in both the groups

	No. (%)	No. (%)	P value
	Group I (n = 20)	Group II (n = 40)	
No. of complications	16 (80%)	8 (20%)	0.000008*

* Results are highly statistically significant at 5% Level of significance (P<0.05)

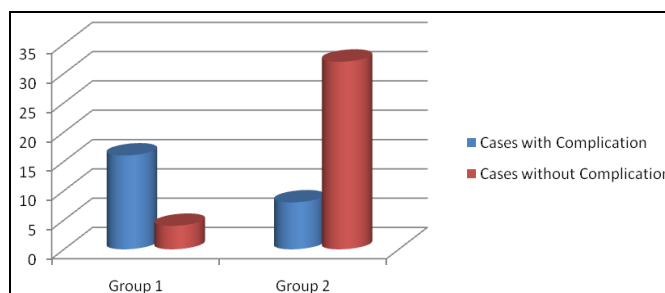


Fig 3: Showing overall outcome in both the Groups

Discussion

Patient with hip fractures have a considerable risk of various medical and surgical complications [3, 4]. Nonsurgical treatment conventionally involves the use of skeletal traction for an extended period of several weeks [8]. This, however, increases complications related to prolonged recumbency. In our series of 60 cases, most common mode of injury was due to fall i.e. 52 (86.6%) cases and road traffic accident was responsible for only 8 (13.3%) cases. The result is similar to the series of cases reported by Clawson [9] in which most common mode of injury was fall involving both direct and indirect forces. There was male preponderance seen in our series which may be due to the fact that Indian males are more active and mobile than females. This is contrast to the series of Ecker Malcolm L *et al.* [10] and Ingemar Sernbo Johnell O *et al.* [11] where there was female preponderance but this is comparable to the Indian series of Chacko *et al.* [12] and Sethi *et al.* [13]

In our study, it was found that unstable fracture accounted 73.3% of all cases. In Group I 70% of the cases had unstable fracture whereas in Group II 75% cases had unstable fracture. This is similar to the finding of Jacobs RR [14] who observed that incidence of unstable trochanteric fracture is increasing. Dimon and Hughston [15] considered 302 intertrochanteric fractures to assess the value of medial displacement fixation in unstable intertrochanteric fractures and he, further, suggested that unstable type should be treated by medial displacement fixation. A recent Cochrane systemic review and meta- analysis conducted by Parker *et al.* [16] pointed out that for stable intertrochanteric fracture, either IF and EF can achieve good reduction and stabilization results. On the other hand, for unstable fracture, they recommended the usage of IF prior to EF with the lack of functional comparison and more solid evidence.

Frew [17] observed shortening in 36.16% of patients treated conservatively. In our Series we have noted that there was shortening of less than 2 cm in 20% of cases and shortening of more than 2 cm was found in 60% of cases in Group I whereas in Group II we have noted shortening of less than 2 cm in 15% of cases and shortening of more than 2 cm in 5% of cases but most of the patients did functionally well with simple heel raise. T.S. Sethi *et al.* [13] noted shortening of less than 2 cm in 18% of cases and shortening of more than 2 cm in 10% of cases following Dynamic screw fixation.

Dynamic hip screw is better implant for the treatment of trochanteric fractures and due to controlled collapse mechanism of sliding screw fracture union was early in the operative group. Jensen, *et al.* [18] demonstrated that dynamic hip screw was most suitable implant in their series of an intertrochanteric fracture of the femur treated by various internal fixation devices. Chacko V and Mohanty SP¹² treated 53 patients with intertrochanteric fractures and found that simple non operative treatment was less superior than internal fixation with Dynamic hip screw which is similar to our observation. In our study in Group II, 40 cases were treated by internal fixation with dynamic hip screw. There were no complications in 32 patients (80%), only 2 cases (5%) develop superficial infection which was healed with regular dressing and suitable antibiotics. There were no complications due to implant failure or implant cut out in any of the cases. In our study of Group II, most of the fractures healed in 6 -14 weeks. Daniel Riha *et al.* [19] treated 41 patients with Dynamic hip screw where average healing time was 10 weeks. The results were evaluated and graded as excellent, good and poor as per criteria of Kyle [17].

Using above criteria, in Group I four cases (20%) had excellent, four cases (20%) had well and twelve cases (60%) have poor result. In Group II, we had 80% excellent, 15% good and 5% as poor result. T. S. Sethi *et al.* [13] reviewed 52 patients of trochanteric fracture and found that 72% had excellent, 18% good and 10% fair result. Babhulkar *et al.* [20] has showed excellent and good results in more than 90% of cases in a series comprising of 70 cases. Our result is, however, comparable to T. S. Sethi *et al.* [13] but inferior to Babhulkar *et al.* [20] due to the fact that our patient came from rural background.

Conclusion

In our series the patients who were treated conservatively immobilized for 10-12 weeks due to which they were suffering from the hazards of prolonged recumbency whereas operative patients were mobilized within a week after surgery. We have obtained overall better result when treated with internal fixation taking in to consideration anatomical or near anatomical fracture union and restoration of patient to his or her prefracture ambulatory status at the earliest possible and avoiding all problems of prolonged recumbency and tended to leave the hospital sooner. The overall quality of result was better with internal fixation with dynamic hip screw (DHS) as compared to conservative method. However, conservative treatment will be acceptable where modern surgical facilities are unavailable, and will result in a reductions in complications associated with surgery but rehabilitation likely to be slower and limb deformity more common.

Acknowledgements

Funding: No funding resources

Conflict of interest; none

Ethical approval: The study was approved by the institutional ethics committee.

References

1. Falch JA, Liebekk A, Slungaard U. Epideomology of hip fractures in Norway. *Acta Orthop Scand.* 1986; 56:12-16.
2. Clayer MT, Bauze RJ. Morbidity and mortality of elderly patients with fractured neck and trochanteric region: analysis of risk factors. *J Trauma.* 1989; 29:1673-8.
3. Doi LH, Wong TH, Toh CL, Wong HP. Hip fractures in Non agenaries – a study on operative and non-operative management. *Injury.* 2005; 36:142-7.
4. Nather A, Seow CS, Lau P, Chan A. Morbidity and mortality of elderly patients with fracture neck of femur treated by Hemiarthroplasty. *Injury.* 1995; 26:187-90.
5. Helen HG Handoll, Martin J Parker. Conservative versus Operative treatment of hip fracture in adults. *Cochrane systemic review,* 2008.
6. Crenshaw AH. Campbell's operative Orthopaedics. Crenshaw AH (Ed.) 11th edition, 2007, 329-330.
7. Kyle RF. Analysis of six hundred and twenty two intertrochanteric hipfractures. *J Bone Joint Surg.* 1979; 61A:216-221.
8. Bong SC, Lau HK, Leong JC, Fong D, Lau MT. The treatment of unstable intertrochanteric fractures of the hip: a prospective trial of 150 cases. *Injury.* 1981; 13:139-46.
9. Clawson DK. Intertrochanteric fracture treated by sliding plate fixation methods. *J Trauma.* 1964; 4:737-756.
10. Ecker Malcolm L. The treatment of trochanteric fractures using compression screw. *J Bone Jt. Surg. Am.* 1975; 57A:440-450.

11. Ingemar Sernbo Johnell O, Gent CF, Nilsson JA. Unstable intertrochanteric fractures of hip, treatment with ender pins compared with a compression hip screw. JBJS. 1988; 2(70 A):1297 -1302.
12. Chaco V, Mohanty SP. Comparative analysis of operative and non-operative management of trochanteric fractures. Indian Journal of Orthopaedics. 1984; 18(1):19-24.
13. Sethi TS, *et al.* DHS in trochanteric fractures. Indian Journal of Orthopaedics. 1993; 2(27):161-165.
14. Jacobs RR. Internal Fixation of intertrochanteric hip fracture: A Clinical and biochemical study. Clin. Orthop. 1998; 146:62-70.
15. Dimon JH, Hughston JC: Unstable intertrochanteric fractures of hip. J Bone Jt. Surg. (Am). 1967; 49(3):440-450.
16. Parker MJ, Handoll HH, Gamma. Other cephalocondylic intramedullary nails versus extramedullary implants for extracapsular hip fractures in adults. Frew JFM. Conservative treatment of fractures. JBJS (Am). 1972; 54B:748-749.
17. Jensen JS. Trochanteric fractures. Acta Orthop Scand Suppl. 1981; 188:1-100.
18. Daniel Riha, Jan Bartonicek. Internal fixation of pertrochanteric fracture using DHS with a two whole side plate. Int. Orthop. 2010; 34(6):877-882.
19. Babhulkar SS. Management of trochanteric fractures. Indian J Orthopaedics. 2006; 40:210-8.