



International Journal of Orthopaedics Sciences

ISSN: 2395-1958
IJOS 2018; 4(4): 829-833
© 2018 IJOS
www.orthopaper.com
Received: 12-08-2018
Accepted: 15-09-2018

Dr. Anshul Pancholiya
Resident, Dept. of Orthopaedics,
Krishna Institute of Medical
Sciences, Karad, Maharashtra,
India

Dr. Ravindra B Gunaki
Professor, Dept. of Orthopaedics,
Krishna Institute of Medical
Sciences, Karad, Maharashtra,
India

Dr. Vijay Sinh Patil
Senior Resident, Dept. of
Orthopaedics, Krishna Institute
of Medical Sciences, Karad,
Maharashtra, India

A study of the functional outcome of ipsilateral fracture of femur and tibia

Dr. Anshul Pancholiya, Dr. Ravindra B Gunaki and Dr. Vijay Sinh Patil

DOI: <https://doi.org/10.22271/ortho.2018.v4.i4k.106>

Abstract

Background: This study evaluated the functional outcome of ipsilateral fracture of femur and tibia.

Materials and Methods: 30 cases were studied. Fracture types were classified according to Fraser classification into Type1-22, Type2A-4, Type2B-2, Type2C-2 cases. Different modalities of treatment were used. Functional assessment was done according to Karlstrom and Olerud criteria.

Results: Most common mode of injury was road traffic accidents. Average time period for bony union was 20.43 weeks for femur and 24.26 weeks for tibia in Type-1, 38.28 weeks for femur and 29.42 weeks for tibia in type 2. Compound, comminuted, intra articular fractures took more time to unite. Complications like knee stiffness, infection, delayed and non union were encountered which required additional procedures. Average knee range of motion was 0-108.67°, functional outcome was excellent in 12, good in 11, acceptable in 2 and poor in 5 patients.

Conclusion: Functional outcome was better in Type-1 fractures treated with intramedullary interlock nailing which allowed early mobilization and weight bearing than in Type-2 intra articular fracture treated with plating.

Keywords: Ipsilateral, femur, tibia, fraser classification, Karlstrom and olerud criteria

Introduction

Ipsilateral fracture of femur and tibia includes a combination of diaphyseal, metaphyseal and intra articular fractures. These are extremely heterogeneous groups of injuries. They usually occur due to high energy trauma like road traffic accidents. These are relatively uncommon injuries. These are always associated with high morbidity. Most of these injuries result in some permanent disability. There are no specific guidelines for the management. The implant choice needs to be determined depending on nature of fracture and soft tissue injuries. A specific pattern of management can often not be determined. The incidence of floating knee injuries was reported as 2.6% of all fractures by Letts *et al* in 1986^[1]. These injuries were associated with life threatening injuries such as head injury, chest injury and abdominal injuries as shown by Veith^[2]. Other skeletal injuries were also seen in these patients. Injuries were often a combination of different fracture patterns. There was extensive soft tissue damage of the limb as well. The soft tissue injuries varied from minor abrasions to grade III open injuries. Injuries to the neurovascular structures add a treacherous component to the whole picture. This often perplexes even the most experienced clinicians in the choice of management.

The established principles of treatment are –

- Proper assessment of the injuries.
- Resuscitation and initial stabilization of the patient followed by early surgical stabilization of the fractures.
- Early and thorough debridement of the wound in case of open fractures.
- Accurate reduction of intra articular fractures.
- Stabilization of fractures with appropriate implants.
- Concurrent management of neurovascular injury.
- Primary or delayed closure of wounds and appropriate soft tissue cover.
- Early mobilization of the knee joint and introduction of the functional activities of the lower limb as a whole for the better functional outcome.

Correspondence

Dr. Ravindra B Gunaki
Professor, Dept. of Orthopaedics,
Krishna Institute of Medical
Sciences, Karad, Maharashtra,
India

Materials and methods

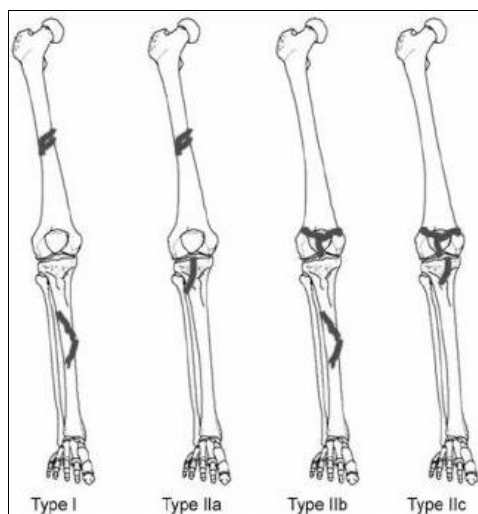
This is a combined prospective and retrospective study conducted in the Department Of Orthopedic Surgery at Krishna Institute of Medical Sciences Deemed University, Karad. For this study 30 patients with ipsilateral femur and tibia fractures were included who presented to KIMS casualty who fulfilled the criteria. The patients were classified according to Fraser Classification for floating knee injuries. Children (<18 years) - skeletally immature patients were excluded from the study.

Initial management

As the patient presented to the emergency department, proper assessment of the injuries was done. Initial management involved resuscitation and haemodynamic stabilization of the patient and splinting the limb in thomas splint or plaster slab or skeletal traction given later on. Radiographs of the affected limb, pelvis and chest were taken and all routine blood investigations were carried out. Open fractures and wounds were documented properly. Cultures were sent. Adequate wound wash and irrigation was done with sterile normal saline. Appropriate antibiotics were started and prophylactic tetanus toxoid was given. Primary closure of the wound was done. The subject was included into the study once a diagnosis of floating knee injury was made in the emergency room. Floating knee was classified according to Fraser Classification. Open fractures were classified according to Gustilo and Anderson classification. The plan of management for the given patient was made depending on the nature of fracture, location of fracture and associated soft tissue injuries. Primary care was given to all these patients and then they were treated with surgical management. 30 patients were classified according to Fraser classification. Of these 22 were Type 1, 4 were Type 2A and 2 were Type 2B and 2 were Type 2C.

Fraser Classification for floating knee

Type 1	Femoral shaft and Tibial shaft
Type 2A	Femoral shaft and tibia intra articular
Type 2B	Femur intra articular and tibial shaft
Type 2C	Both Femur and Tibia intra articular



Post Operative Evaluation

All patients were evaluated post operatively at regular follow up of 6 weeks, 3 months, 4.5 months, 6 months, 9 months and 1 year. Radiological and clinical assessment was carried out at each visit. All the patients were assessed using a standard

Proforma. Physiotherapy was started as early as post op day 1 as quadriceps and hamstring strengthening exercises. Knee mobilisation was started depending upon the fracture pattern and modality of fixation. Non weight bearing, gradually increasing to partial and full weight bearing was started depending upon the modality of fixation and radiological signs of union. The patients were followed up till bony union had been confirmed.

Results

In our study the most common mechanism of injury was road traffic accidents (96.66%). Two wheeler accidents (93.33%) accounted the most and 3.33% were pedestrians.

Males predominated in our study (96.67% male, 3.33% female). The age distribution was from 18 years to 55 years (Mean 33.50 years). Majority of the patients were from the age group 21-30 years (30%).

20 patients had right lower limb injury (66.67%) and 10 patients had left lower limb injury (33.33%). Right sided dominance was seen.

There were total 24 open fractures amongst which femur were 11 (36.67%) and tibia were 13 (43.33%). Out of 30 femur fractures, 19 were comminuted (63.34%), 9 were transverse or oblique (27%) and 2 were segmental (6.66%). Out of 30 tibia fractures, 15 were comminuted (50%) the majority, 12 were transverse or oblique (40%) and 3 were segmental (10%).

Majority of the femur fracture were diaphyseal in 25 cases (83.33%) followed by intra articular fracture knee in 4 cases (13.34%), and 1 patient had fracture at diaphyseal metaphyseal junction (3.33%). Majority of the tibia fractures were diaphyseal in 16 cases (53.33%) followed by 7 cases of diaphyseal metaphyseal fracture (23.33%), intra articular fracture knee in 6 cases (16.67%), and 1 patient had fracture at intra articular ankle (3.33%).

In our study, out of 30 femur fractures, intramedullary nailing was done in 24 patients (80%) and plating in 6 patients (20%). Out of total 30 tibia fractures, intramedullary nailing was done in 15 patients (50%), plating in 11 patients (36.67%), External fixation in 2 cases (6.67%), cancellous screws in 1 patient (3.33%) and conservative treatment in 1 patient (3.33%) having undisplaced fracture.

The time duration of surgery ranged from 90 minutes to 360 minutes. Average time duration of surgery was 229.50 minutes.

The associated injuries were found in 22 cases (73.33%). Contralateral lower limb injuries were found in 5 cases (16.66%). Upper limb injuries in 9 cases (30%). No patients had spine injuries in our study. Head injury was observed in 13 cases (43.33%) but all were treated with medical management. Surgical intervention was not required in any case. Chest injuries occurred in 2 patients (6.67%), Abdominal injuries were found in 3 patients (10%). Associated injuries in the same limb was observed in 3 cases (10%). One patient (3.33%) had anterior cruciate ligament injury diagnosed on follow up.

Femur fractures united within 12 weeks to 64 weeks. In Type 1 fractures (23 patients)-average time period for femur fracture to unite was 20.43 weeks. In Type 2 (intra articular) fractures (7 patients) it was 38.28 weeks. Overall average time period was 24.60 weeks. Tibia fractures united within 6 weeks to 60 weeks. In Type 1 fractures (23 patients)- average time period for tibia fracture to unite was 24.26 weeks. In Type 2 (intra articular) fractures (7 patients) it was 29.42 weeks. Overall average time period was 25.46 weeks.

Complications like Fat embolism occurred in 1 patient which was managed medically with strict intensive care and thrombolytic agents. Infection occurred in total 5 patients (16.66%) out of which 2 patients recovered with regular dressings but 3 patients required wound debridement which later on undergone implant removal. Delayed union occurred in 4 patients (13.33%). Non union tibia occurred in 2 cases (6.67%) which required bone grafting at later stages. Malunion occurred in 2 patients (6.67%). Knee stiffness occurred in 7 patients (23.33%). Shortening occurred in 9 cases (30%) ranging from 1-3 cm in 7 cases (23.34%) and >3 cm in 2 cases (6.66%).

Knee mobilisation was started as early as within 1 week in all fractures nailed and some plating group which had stable fixation, upto 12 weeks in plating-plating group which were intra articular and severely comminuted. Average time period was 3.37 weeks.

Full weight bearing was permitted depending on the modality of fixation and bony union seen radiologically. In majority, it was started within 10-20 weeks in 14 cases (46.67%) followed by 20-30 weeks in 11 cases (36.67%). Nailing group permitted early weight bearing in comparison to the plating group. Average time period was 21.07 weeks.

Minimum knee range of motion was 0-25° and maximum was 0-135°. In Type 1 fractures average range was 0-114.79° and in Type 2 (intra articular) fractures it was observed to be 0-63.12°. Knee range of motion was better in Type 1 fractures treated with nailing than in Type 2 fractures treated with plating.

Functional outcome was analysed according to the Karlstrom and Olerud Criteria as Excellent in 12 patients (40%), Good in 11 patients (36.67%), Acceptable in 2 patients (6.67%) and Poor in 5 patients (16.67%).

Discussion

The term Floating knee is used when the knee joint is partially or completely isolated due to ipsilateral fracture of femur and tibia. It occurs usually due to high velocity trauma. There is an increase in the occurrence of floating knee injuries due to the increase in number of road traffic accidents. These are always associated with high morbidity. The more number of road traffic accident cases were due to the fact that our hospital is situated on a major highway and that our hospital is a tertiary referral centre. Hayes JT^[3] suggested that automobile passengers with floating knee injury, braced their feet firmly against the sloping floor of the front seat just prior to the collision, their legs getting crumpled under the massive decelerating forces produced by the impact. Pedestrians were frequently catapulted some distance from the point of impact and were further injured by striking the pavement. In a study of 222 cases of floating knee by Fraser^[4], all cases were involved in road traffic accidents.

There are many studies showing the association of other injuries like head injuries, chest injuries, abdominal injuries and contralateral limb injuries. Many of these injuries are often life threatening. Adamson *et al.*^[5] in their study encountered 71% major associated injuries with 21% vascular injuries. There are different management options for floating knees.

For floating knee injuries in the 1970s and 80s, conservative management was favoured and surgical intervention with implant fixation was criticized. Complications such as non union, delayed union, osteomyelitis, knee stiffness and deformities were common. The management of these difficult injuries gradually evolved due to better understanding of

functional anatomy and biomechanics of the knee, femur and tibia, awareness of the associated injuries, the advent of internal fixation devices, microsurgery for neurovascular injury and aggressive soft tissue management.

In 1977, Karlstrom and Olerud^[6] reported thirty two patients with floating knee injuries, fourteen patients were treated by rigid internal fixation or external fixation for both fractures. Three patients had internal or external fixation of one fracture and conservative treatment of other fracture. Fifteen patients underwent non operative management for both fractures. The patients who were treated operatively for both fractures had a lower incidence of complications, shorter duration of hospitalization and shorter time to healing. An active surgical approach produced considerably better functional end results. In 1978, Fraser^[4] reported two hundred and twenty two patients with ipsilateral fractures of the femur and tibia. Patients were grouped according to the type of fracture and the method of treatment; sixty three patients were clinically examined. The worst results were in those following non operative management of both fractures. Following this, more use of external fixation and of cast bracing was recommended in the management of the fractured tibia. Internal fixation was advised for the femoral fractures. Clinical examination of the knee at post operative or follow up suggested that disruption of ligaments (collateral or cruciate ligaments) was a common occurrence and should always be suspected in the presence of recurrent knee instabilities.

Katada^[7] reported fourteen patients with floating knee injuries. He found that intramedullary nailing of both femur and tibia gave good results. As comminution is often severe in patients with floating knee injuries intramedullary nailing with Kuntscher nail may be difficult. He introduced a closed Enders nailing for 23 femoral and tibial shaft fractures. Its advantages were that it was technically simple, has wide indications and results in rapid bone union without knee stiffness. In 1984, Veith *et al.*^[2] reported about fifty seven patients, fifty six of those femoral fractures and half of the tibial fractures were treated with internal fixation. These included open fractures also. He reported that overall a good or excellent functional result was achieved in about 80 % of those patients. The best results were achieved when both fractures were stabilized surgically.

In 1968 Ratliff^[8] did a comparative study between patients with ipsilateral femur and tibia fractures surgically managed and conservatively managed. The results of the surgically managed patients were found to be better. In 1977 Hojer *et al.*^[9] conducted a prospective study on ipsilateral femur and tibia shaft fractures. They had immediately fixed tibia with either internal or external fixation. But the femur fixation was delayed by seven to fourteen days and was fixed with intramedullary nail. They had excellent functional results in majority of their patients.

Hayes³ suggested that in a patient with multiple fractures in the same extremity, surgical fixation of one or more of the fractures was valuable in the management of the entire limb. Omer *et al.*^[10] treated a floating knee using both conservative and surgical fixation, and found that where internal fixation was done for both femoral and tibial fractures, the healing time was approximately 8 weeks earlier than the group managed conservatively. Ostrum^[11] treated patients with a retrograde femoral tibial intramedullary nail through a 4 cm medial parapatellar incision. The mean time to union of the femoral and tibial fractures was 14.7 and 23 weeks, respectively. They opined that this method was an excellent treatment option.

Szalay *et al.* [12] demonstrated knee ligament laxity in 53% of patients, whereas 18% complained of instability. Most patients with instability had a rupture of the anterior cruciate ligament with or without damage to the other ligaments. They concluded that a knee ligament injury was more common with floating knee injuries than with isolated femoral fractures, and advocated careful assessment of knee in all cases of fractures of the femur and floating knee injuries. A meticulous examination of the knee at the time of injury is strongly advocated, even the practicality of this method is questionable.

Intra-articular involvement of the fractures, higher skeletal injury scores and the severity of soft tissue injuries are significant indicators of a poor outcome. Hee *et al.* [13] suggested a preoperative scoring system that considered age, smoking status at time of injury, injury severity scores, open fractures, segmental fractures and comminution to affect the prognosis of the final outcome of these fractures. The associated injuries played a major role in the initial outcome of patients with regard to a delay in initial surgery, prolonged duration of surgery, anesthetic exposure and delay in rehabilitation.

As per our study, the excellent to good results were obtained mostly when both fractures were treated by intramedullary nailing. These patients returned to their normal level of activity earlier than when the fractures were treated with other modalities. These patients showed early bony union, good range of knee motion as the final outcome. Acceptable to poor results are related to the type of fracture (open or closed, intra articular fractures, severe comminution) which were mostly

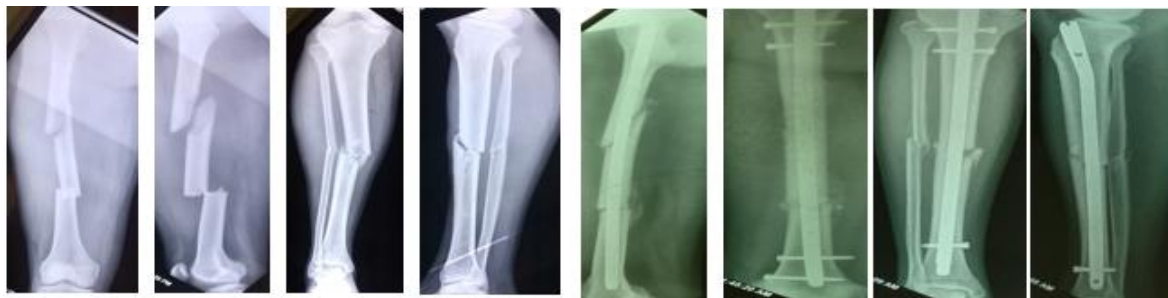plated. These patients developed complications like infection, delayed union, shortening and knee stiffness.

Rehabilitation process including the muscle strengthening exercises and gradual knee mobilisation plays an important role. A strict rehabilitation protocol in patients with floating knee injuries cannot be established as it depends upon the type of fracture, nature of comminution, intra articular extension, modality of fixation and the associated injuries.

Conclusion

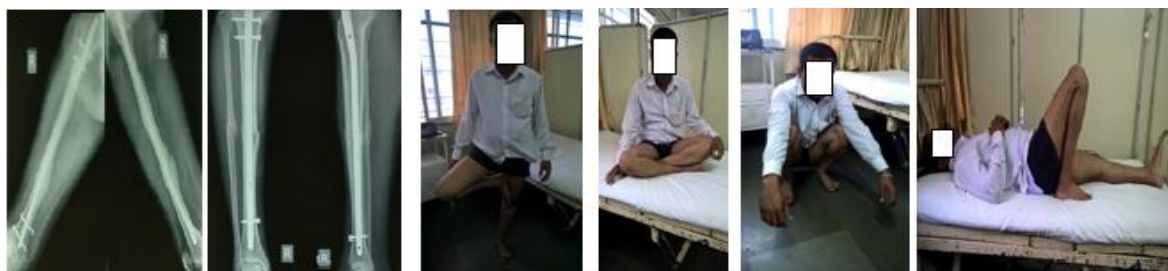The functional outcome was found to be better in Type I fractures (diaphyseal fractures femur and tibia) treated with intramedullary interlock nailing which allowed early mobilization and weight bearing than in Type II (intra articular) fractures treated with plating. The most important factors which determined the functional outcomes were the type of fractures (open or closed), nature of comminution including intraarticular extensions, timing and modality of fixation, post operative infections and medical comorbidities. Bony union occurred early in closed, diaphyseal and simple transverse or oblique fractures and delayed in open, intra articular and comminuted fractures. Early surgical stabilisation and mobilisation of the patient are key to success which results in better functional outcomes.

In conclusion, floating knee injuries are a group of complex injuries that require a careful assessment to detect poor prognostic factors and associated injuries. Internal fixation of the fractures with thorough surgical planning and prolonged rehabilitation are recommended. A combination of these determines the ultimate outcome of these patients.



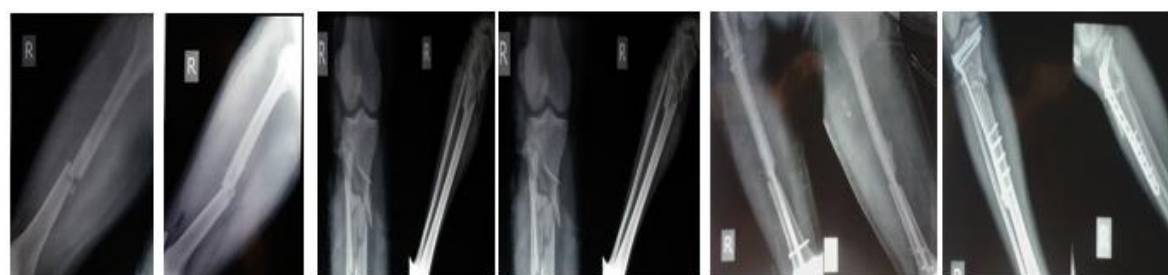Pre op x-ray

Post op x-ray



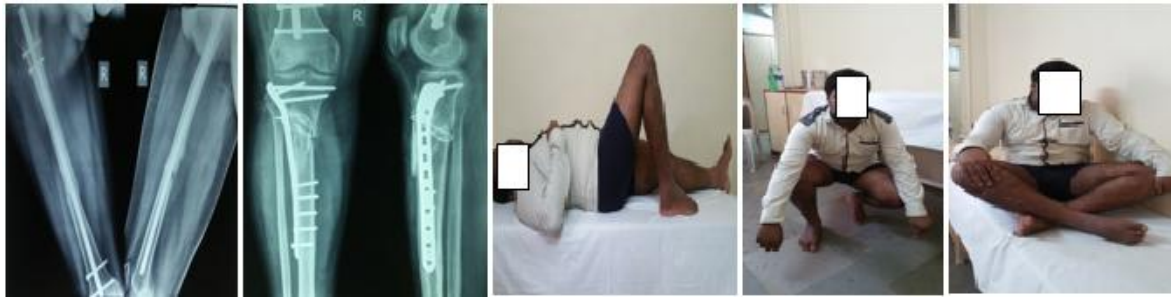Follow up at 1 year

Clinical pics



Pre op xray

Post op xray



Xray at 9 months follow up

Clinical pics

References

1. Letts M, Vincent N, Gouw G. The floating knee in children. *J Bone Joint Surg Br.* 1986; 68(3):442-46.
2. Veith RG, Winqvist RA, Hansen ST Jr. Ipsilateral fractures of the femur and tibia. A report of fifty-seven consecutive cases. *J Bone Joint Surg Am.* 1984; 66(7):991-1002
3. Hayes JT. Multiple fractures in same extremity: Some problems in their management. *Surgical Clinics of North America.* 1961; 41:1379-88.
4. Fraser RD, Hunter GA, Waddell JP. Ipsilateral fracture of the femur and tibia. *J Bone Joint Surg Br.* 1978; 60-B(4):510-15.
5. Adamson GJ, Wiss DA, Lowery GL, Peters CL. Type II floating knee: Ipsilateral Femoral and Tibial Fractures with Intraarticular Extension into the Knee Joint. *J Orthop Trauma.* 1992; 6(3):333-9.
6. Karlstrom G, Olerud S. Ipsilateral fracture of the femur and tibia. *J Bone Joint Surg Am.* 1977; 59(2):240-43.
7. Katada S, Ando K, Nakagawa K, Yamada T, Sasamoto H, Kawabe N *et al.* Floating knee fracture (ipsilateral fracture of the femur and tibia)-Treatment by closed Ender nailing. *Nippon Seikeigeka Gakkai Zasshi.* 1984; 58(5):475-83.
8. Ratliff AH. Fractures of the shaft of the femur and tibia in the same limb. *Pro Roy Soc Med.* 1968; 61:907-08.
9. Hojer H, Gillquist J, Liljedahl SO. Combined fractures of the femoral and tibial shafts in the same limb. *Injury* 1977; 8:206-12.
10. Omer GE Jr, Moll JH, Bacon WL. Combined fractures of the femur and tibia in a single extremity: analytical study of cases at Brooke General Hospital from 1961-to1967. *J Trauma.* 1968; 8(6):1026-41.
11. Ostrum RF. Treatment of floating knee injuries through a single percutaneous approach. *Clin Orthop Relat Res.* 2000; 375:43-50.
12. Szalay MJ, Hosking OR, Annear P. Injury of knee ligament associated with ipsilateral femoral shaft fractures and with ipsilateral femoral and tibial shaft fractures. *Injury.* 1990; 21(6):398-400.
13. Hee HT, Wong HP, Low YP, Myers L. Predictors of outcome of floating knee injuries in adults: 89 patients followed for 2-12 years. *Acta Orthop Scand.* 2001; 72(4):385-94.