International Journal of Orthopaedics Sciences

ISSN: 2395-1958
IJOS 2018; 4(4): 713-718

www.orthopaper.com
Received: 11-08-2018
Accepted: 15-09-2018

Md. Qamar Abdul Azeez
Assistant Professor, Department of Orthopaedics, NRIIMS, Visakhapatnam, Andhra Pradesh, India

Gudla Siva Prasad
Associate Professor, Department of Orthopaedics, NRIIMS, Visakhapatnam, Andhra Pradesh, India

Correspondence
Gudla Siva Prasad
Associate Professor, Department of Orthopaedics, NRIIMS, Visakhapatnam, Andhra Pradesh, India

Arthroscopic fixation of anterior cruciate ligament tibial avulsion fractures using fibre wire with endobutton

Md. Qamar Abdul Azeez and Gudla Siva Prasad

DOI: https://doi.org/10.22271/ortho.2018.v4.i4i.85

Abstract
Purpose: Most tibial eminence fractures are avulsion fractures of the anterior cruciate ligament (ACL) from its tibial insertion. The most common fixation techniques for tibial avulsion fractures of the anterior cruciate ligament (ACL) described in the literature are screw and suture fixation. The fixation of these fractures with the Tightrope® device might be an alternative. The aim of our study is to assess the clinical and radiological results of arthroscopic fixation using fibre wire with Endobutton in the management of ACL avulsion fractures using a simpler technique.
Materials and Methods: This is a Retrospective observational case study of Eleven patients (10 males and 1 female) who underwent arthroscopic fixation with standard anteromedial and anterolateral ports using fibre wire with Endobutton for displaced ACL avulsion fractures (Meyers and Mc Keever's classification grade 2, grade 3 and grade 4). 8 patients were skeletally mature and 3 had open physes. The average age was 21 years with a mean follow up of 1 year. All patients were assessed clinically by calculating their Lysholm scores, Lachman test and the radiological union was assessed in the follow up radiographs.
Results: The mean Lysholm score was 95.636. In all the eleven patients, Lachman test was negative at the end of final follow up and all the patients were able to return to their preinjury activity level.
Conclusion: Arthroscopic fixation using this technique of using fibre wire with Endobutton is a safe and reliable technique for producing good clinicoradiological outcome in displaced ACL avulsion fractures.

Keywords: anterior cruciate ligament, arthroscopic fixation, arthroscopy, avulsion fracture, endobutton, knee joint, fibre wire, tibia

Introduction

Tibial eminence fractures are rare and usually occur in children [1]. Meyers and McKeever [2, 3] developed a system for classifying these fractures: type 1 has minimal or no displacement and is usually treated conservatively; type 2 involves partial anterior 'duck-bill' elevation of the bony fragment but with preservation of a posterior hinge with the tibial eminence; type 3 involves complete fragment elevation anteriorly and posteriorly; and this system was modified by Zaricznyj [4] who suggested that comminution of a displaced avulsion fracture should be classified as a type IV fracture (Fig. 1). Types 2 to 4 are usually treated surgically with arthroscopic techniques [5, 6, 7]. In adults with large bony fragments, screw fixation provides strong fixation strength [6, 7]. In children with small or comminuted fragments, screw fixation is usually not available. Arthroscopic pullout suture techniques are suitable for tibial eminence fractures with small or comminuted fragments [8, 9, 10].

The Anterior Cruciate Ligament (ACL) receives its nourishment from branches of middle geniculate artery [11]. Which runs in the connective tissue of the synovial membrane covering the ligament. Atrophy of the ligament following its detachment at one end can be expected if the stimulus of tension thereby removed. Hence, such type of fractures need to be fixed. Surgical intervention is indicated for Meyers and McKeever types II, III and IV because displaced fractures may cause non-union or malunion as well as loss of knee extension or instability [12, 13, 14].

Although various fixation devices have been introduced for Arthroscopic Reduction and Internal Fixation of Anterior Cruciate Ligament (ACL) tibial avulsion fractures such as cannulated screws, staples, Kirschner wires, wires and non-absorbable sutures [15-24],

till now, no equivocally accepted technique is available that can be applied regardless of skeletal maturity, fragment size or comminution. Here we use a technique of Arthroscopic assisted ACL tibial avulsion fracture fixation with fibre wire and Endobutton using simple instrumentation. The purpose of this study was to assess the clinicoradiological outcome of patients with ACL avulsion fractures (type 2 to type 4) fixed arthroscopically using fibre wire and Endobutton.

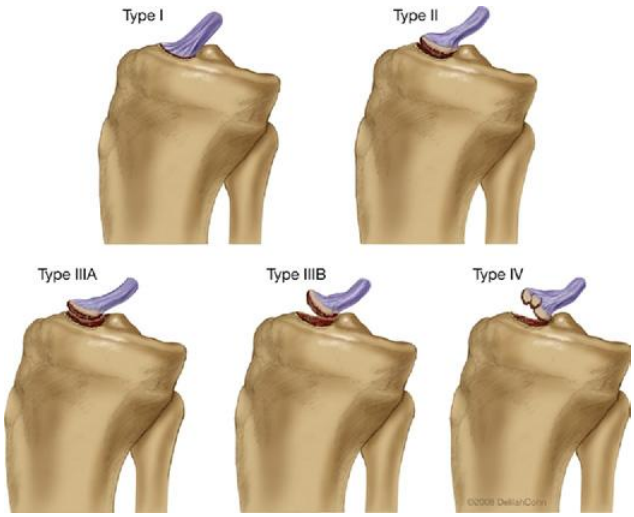

Fig 1: Classification system of tibial eminence fractures. Type I, nondisplaced or minimally displaced anterior margin; type II, the anterior 1/3 to 1/2 of the fragment is displaced; type IIIA, complete displacement of the fragment; type IIIB, complete displacement and cephalad rotation of the fragment; type IV, comminution of the fragment. (Courtesy of Delilah Cohn, MFA, CMI, Nashville, TN.)

Materials and Methods

Eleven patients (10 males and1 female) who underwent arthroscopic fixation with standard anteromedial and anterolateral portals using fibre wire with Endobutton for displaced ACL avulsion fractures (modified Meyers and McKeever's classification grade 2 and above) were analysed retrospectively. 8 patients were skeletally mature and 3 had open physes. Average age was 21 years (range 13-32). The mean follow-up period was of 1 year. All patients had haemarthrosis and positive Lachman test on presentation. The mode of trauma was RTA in 6 patients and sports injury in 5 others. All patients were assessed clinically at final follow up by calculating their Lysholm score in form of a subjective questionnaire and Lachman test with knee in 30-degree flexion. Radiological union was assessed by antero-posterior and lateral x-rays of the involved knee.

Operative Technique

Surgery was performed in supine position and under tourniquet control in spinal anaesthesia. Standard anteromedial and anterolateral portals were taken in 70^0 knee flexion and haemarthrosis was drained. ACL avulsion fragment was identified. Using a probe the status of the anterior cruciate ligament (ACL), fracture fragments, and intermeniscal ligament was assessed. The intermeniscal ligament was then retracted anteriorly with a skin hook inserted through the anterolateral portal. The fracture fragment was elevated to remove underlying haematoma and bone debris using a curette. Trial reduction was performed with a probe and was fixed temporarily with a 2 mm K-wire drilled from metaphysis into fracture fragment. Using a 18G LP needle 2.0 fiberwire was passed through the substance of ACL at the foot print and with suture retriever 2 ends of fiberwire were pulled out through anteromedial portal. A standard knot with one or two cross hitches were applied to the base of ACL with fiber wire through anteromedial portal. Using ACL zig, 2 tunnels were made with 2.4 mm guide pin from anteromedial aspect of tibia into the joint cavity such that both tunnels open anteromedially and posterolaterally to the ACL footprint. The 2.4mm guide pin was exchanged for an 18-gauge 70-mm needle pre-loaded with a loop of 2-0 nylon. From the anteromedial portal, a suture retriever was used to relay the 2-0 nylon loop with the loop of Fiberwire No. 2. At 30º knee flexion, the Fiberwire suture was fixed to Endobutton outside the tibial hole by pulling and knotting the Fiberwire with maximum tension.

Postoperative rehabilitation

Postoperatively, the knee was maintained with a knee immobilizer in full extension for 2 weeks. Touch weight walking was allowed on day 1. Partial weight bearing and range of motion exercises from 0° to 90° were allowed at 2 weeks. Full weight bearing was allowed at 6 weeks. Jogging was allowed at 10 weeks. All patients achieved bone union; no young patients had growth disturbance of the tibia; all knees were stable with excellent range of motion and negative Lachman and pivot shift tests and no flexion contracture.

Discussion

We found that all of our patients with displaced tibial avulsion fracture treated by arthroscopic assisted reduction of fracture fragment and by using fibre wire achieved a clinically stable knee with negative Lachman test and excellent to good, Lysholm score with radiological evidence of union at an average follow up of 1 year. This technique with simpler modification using easily available instrumentation such as 18G LP needle loaded with 2.0 Nylon suture and no intraarticular metal implant usage makes this procedure a useful tool in the armamentarium of arthroscopic surgeons in dealing with such type of fractures.

Displaced ACL tibial avulsion fractures result in anterior knee instability and occasionally in loss of knee extension [25]. Therefore, surgical treatment is recommended for all Meyers and McKeever [10] type III and IV fractures and should be considered in all cases of displaced type II fractures. The goals of fixation are to restore the articular surface, provide rigid internal fixation and to locate the ACL to its anatomic insertion at its proper length. With regard to surgical technique, arthroscopic treatment has become a popular procedure for ACL tibial avulsion fractures. Successful arthroscopic reduction and fixation has been described in several studies [26, 27].

Many fixation methods have been reported with promising results [28, 29]. Although, it is simple to use, K-wire fixation has difficulty in holding the fragment if the size is small and also the wire must be removed. Screw fixation, though it has strong purchasing power can be generally applied only to a large fracture fragment, although small sizes of screws are being developed [30]. Other possible disadvantages in screw fixation are possible breakage of fracture fragment during insertion, possible impingement of screw head during knee extension and the requirement of a secondary procedure for screw removal [27]. Both of these fixation methods cannot be applied to comminuted type IV fractures [31].

Suture cerclage is also popularly used [31, 32, 33]. Eggers *et al* reported that suture fixation of tibial eminence fractures provides more fixation strength than screw fixation using the biomechanical study. Hunter and Willis [34] reported that

suture fixation produced slightly better results than screw fixation, although without statistical significance. Bong *et al* showed similar result showing superiority of suture fixation over cannulated screws.

In our technique, we used fibre wire with Endobutton for fixation, which we consider a good alternative to suture fixation. The operative technique presented here has many potential qualitative advantages-

a) First, this fixation technique requires no further surgery for implant removal.
b) Second, fibre wires are sewn into the ACL base rather than into the avulsed bone; thus even reduction and fixation of type III or IV fractures are easily performed.
c) Fibre wire fixation is superior to screw fixation for treating avulsion fracture of the ACL because screw fixation may potentially break the bone fragments, hence can be used in comminuted fractures.
d) Moreover, with use of Endobutton, the fixation becomes more rigid with less hardware related problems.
e) Finally, special instruments such as suture punches are not required and can be done using simple 18G spinal needle.

The limitations of our study are that its a retrospective case series study, smaller sample size, lack of preoperative Lysholm score and lack of biomechanical study in evaluation. In future, it would be prudent to plan a controlled study having biomechanical evaluation in a larger size sample.

Tables

Lysholm score at final follow up: Table below showing distribution of patients as per Lysholm score at final follow up.

Table 1: Lysholm Score at Final Follow up

Result	Range	Number of Patients
Excellent	95-100	6 (54.54%)
Good	84-94	5 (45.45%)
Fair	65-83	0 (0%)
Poor	<65	0 (0%)

Lachman Test: done with knee 30-degree flexion below table showing preop and postop comparison.

Table 2: Lachman Test

Lachman Grading	Preop	Postop
Negative	0	11 (100%)
Grade 1	0	0 (0%)
Grade 2	5 (45.45%)	0
Grade 3	6 (54.54%)	0

Fig 2: Preop xray showing type 3 Avulsion Fracture of tibial eminence

Fig 3: Preop CT Scan showing type 2 acl avulsion fracture

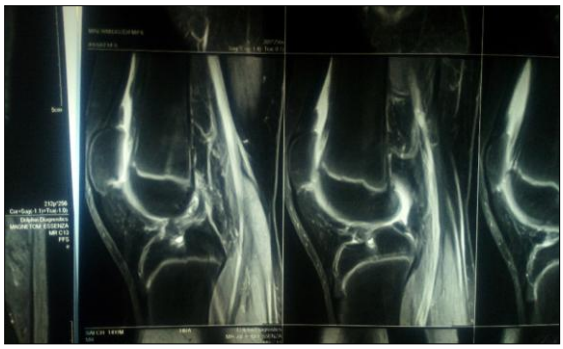

Fig 4: Preop MRI showing intact ACL fibers and type 3 Avulsion fracture of tibial eminence

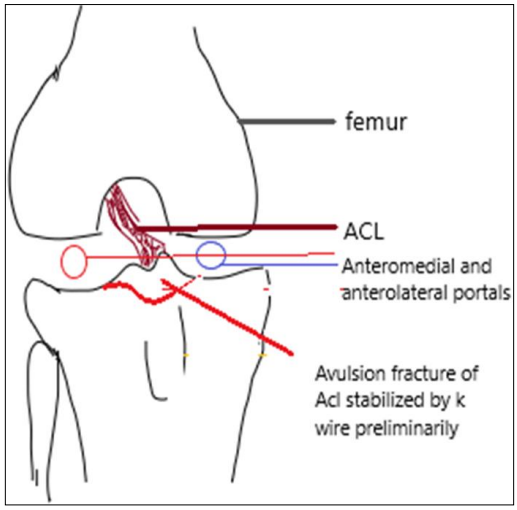

Fig 5: Line diagram showing acl avlusion fracture held in reduction with k wire



Fig 6: Showing 18G LP needle loaded with 2.0 Nylon suture

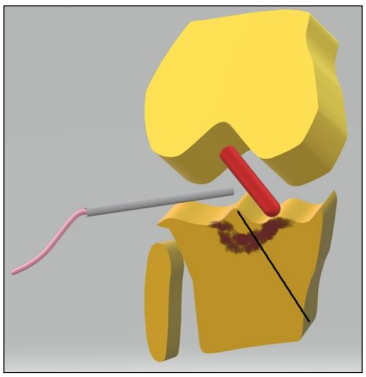

Fig 7: Showing ACL reduction with k wire and LP needle loaded with fibre wire through AL Portal

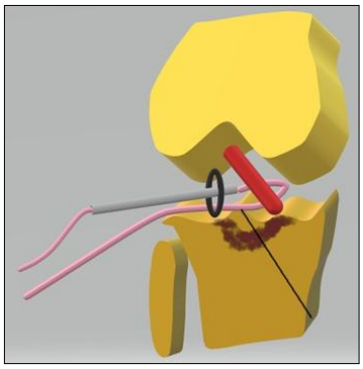

Fig 8: Showing fiberwire passing through acl substance and retreived out from AL portal

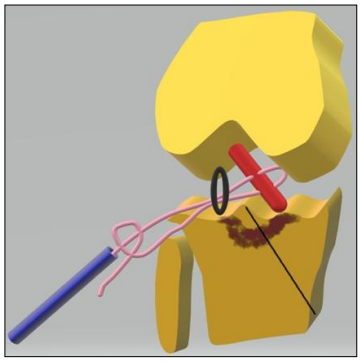

Fig 9: Showing application of simple knot with knot pusher

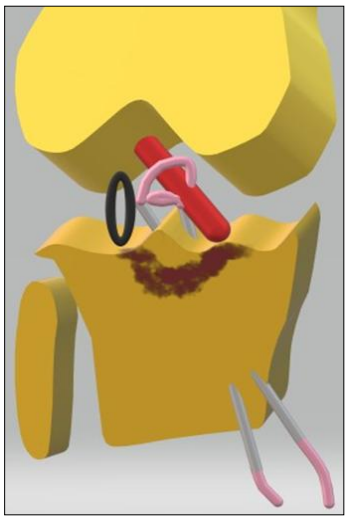

Fig 10: Showing knot at ACL base and two ends of fibre wire out through anteromedial cortex of tibia over LP needle loaded with nylon 2.0 suture

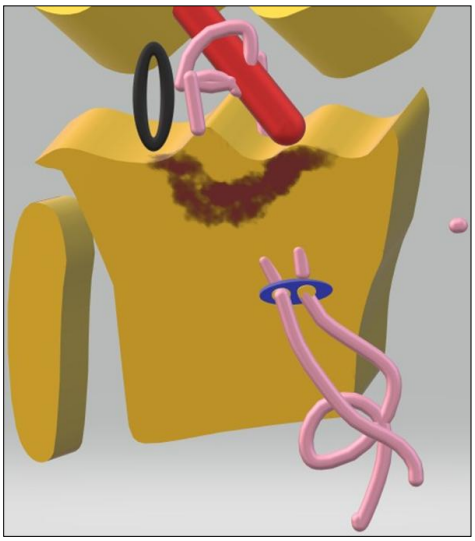

Fig 11: Showing knot tied over endobutton on anteromedial cortex of tibia after pulling the fibrewires in tension

Fig 12: Post op xray AP view showing healed fracture with endobotton insitu.

Fig 13: Post op xray Lateral view showing healed fracture with endobotton insitu.

Fig 14: 1Yr follow-up with good Range of movement.

Fig 15: 1Yr follow-up with no extension lag.

Conclusion

This retrospective observational case series study shows qualitative advantage of this modified surgical technique of arthroscopic fixation of comminuted ACL avulsion fracture using fibre wire with Endobutton. This technique is safe, reliable and applicable to any type of avulsion fracture to achieve a good clinicoradiological outcome. Larger randomized control studies would be required for improving the evidence for the desired technique.

References

1. Wiley JJ, Baxter MP. Tibial spine fractures in children. Clin Orthop Relat Res. 1990; (225):54-60.
2. Meyers MH, McKeever FM. Fracture of the intercondylar eminence of the tibia. J Bone Joint Surg Am. 1959; 41-A(2):209-220.
3. Meyers MH, McKeever FM. Fracture of the intercondylar eminence of the tibia. J Bone Joint Surg Am. 1970; 52(8):1677-1684.
4. Zaricznyj B. Avulsion fracture of the tibial eminence: treatment by open reduction and pinning. J Bone Joint Surg Am. 1977; 59(8):1111-1114.
5. Kluemper CT, Snyder GM, Coats AC, Johnson DL, Mair SD. Arthroscopic suture fixation of tibial eminence fractures. Orthopedics. 2013; 36:e1401-6.
6. Pan RY, Yang JJ, Chang JH, Shen HC, Lin LC, Lian YT. Clinical outcome of arthroscopic fixation of anterior tibial eminence avulsion fractures in skeletally mature patients: a comparison of suture and screw fixation technique. J Trauma Acute Care Surg. 2012; 72:E88-93.
7. Wiegand N, Naumov I, Vamhidy L, Not LG. Arthroscopic treatment of tibial spine fracture in children with a cannulated Herbert screw. Knee. 2014; 21:481-5.
8. Berg EE. Pediatric tibial eminence fractures: arthroscopic cannulated screw fixation. Arthroscopy. 1995; 11:328-31.
9. Hunter RE, Willis JA. Arthroscopic fixation of avulsion fractures of the tibial eminence: technique and outcome. Arthroscopy. 2004; 20:113-21.
10. Lubowitz JH, Elson WS, Guttmann D. Part II: arthroscopic treatment of tibial plateau fractures: intercondylar eminence avulsion fractures. Arthroscopy. 2005; 21:86-92.
11. Scapinelli R. Studies on the vasculature of the human knee joint. Acta Anat (Basel). 1968; 70(3):305-331.
12. Panni AS, Milano G, Tartarone M *et al*. Arthroscopic treatment of malunited and nonunited avulsion fractures of the anterior tibial spine. Arthroscopy. 1988; 14(3):233-240.
13. Sullivan DJ, Dines DM, Hershon SJ *et al*. Natural history of a type III fracture of the intercondylar eminence of the tibia in an adult. A case report. Am J Sports Med. 1989; 17(1):132-133.
14. Kawate K, Fujisawa Y, Yajima H *et al*. Seventeenyear follow-up of a reattachment of anon united anterior tibial spine avulsion fracture. Arthroscopy. 2005; 21(6):760.e1-760.e5.
15. Berg EE. Pediatric tibial eminence fractures: arthroscopic cannulated screw fixation. Arthroscopy. 1995; 11(3):328-331.
16. Jung YB, Yum JK, Koo BH. A new method for arthroscopic treatment of tibial eminence fractures with eyed Steinmann pins. Arthroscopy. 1999; 15(6):672-675.
17. Kogan MG, Marks P, Amendola A. Technique for arthroscopic suture fixation of displaced tibial intercondylar eminence fractures. Arthroscopy. 1997; 13(3):301-306.
18. Lehman RA, Murphy KP, Machen MS *et al*. Modified arthroscopic suture fixation of a displaced tibial eminence fracture. Arthroscopy. 2003; 19(2):E6.
19. Matthews DE, Geissler WB. Arthroscopic suture fixation of displaced tibial eminence fractures. Arthroscopy. 1994; 10(4):418-423.
20. Oohashi Y. A simple technique for arthroscopic suture fixation of displaced fracture of the intercondylar eminence of the tibia using folded surgical steels. Arthroscopy. 2001; 17(9):1007-1011.
21. Osti L, Merlo F, Liu SH *et al*. A simple modified arthroscopic procedure for fixation of displaced tibial eminence fractures. Arthroscopy. 2000; 16(4):379-382.
22. Reynders P, Reynders K, Broos P. Pediatric and adolescent tibial eminence fractures: arthroscopic cannulated screw fixation. J Trauma. 2002; 53(1):49-54.
23. Senekovic V, Veselko M. Anterograde arthroscopic fixation of avulsion fractures of the tibial eminence with a cannulated screw: five-year results. Arthroscopy. 2003; 19(1):54-61.
24. Yip DK, Wong JW, Chien EP *et al*. Modified arthroscopic suture fixation of displaced tibial eminence fractures using a suture loop transporter. Arthroscopy. 2001; 17(1):101-106.
25. Kendall NS, Hsu SY, Chan KM. Fracture of the tibial spine in adults and children. A review of 31 cases. J Bone Joint Surg Br. 1992; 74(6):848-852.
26. Lubowitz JH, Grauer JD. Arthroscopic treatment of anterior cruciate ligament avulsion. Clin Orthop Relat Res. 1993; (294):242-246.
27. Medler RG, Jansson KA. Arthroscopic treatment of fractures of the tibial spine. Arthroscopy. 1994; 10(3):292-295.
28. Berg EE. Comminuted tibial eminence anterior cruciate ligament avulsion fractures: failure of arthroscopic treatment. Arthroscopy. 1993; 9(4):446-450.
29. Prince JS, Laor T, Bean JA. MRI of anterior cruciate ligament injuries and associated finding in the pediatric knee: changes with skeletal maturation. AJR Am J Roentgenol. 2005; 185(3):756-762.
30. Davis DS, Post WR. Segond fracture: lateral capsular ligament avulsion. J Orthop Sports Phys Ther. 1997; 25(2):103-106.
31. Ahn JH, Yoo JC. Clinical outcome of arthroscopic reduction and suture for displaced acute and chronic tibial spine fractures. Knee Surg Sports Traumatol Arthrosc. 2005; 13(2):116-121.
32. Hsu SY. An easy and effective method for reattaching an anterior cruciate ligament avulsion fracture from the tibial eminence. Arthroscopy. 2004; 20(1):96-100.
33. Kim YM, Kim SJ, Yang JY *et al*. Pullout reattachment of tibial avulsion fractures of the anterior cruciate ligament: a firm effective suture-tying method using a tensioner. Knee Surg Sports Traumatol Arthrosc. 2007; 15(7):847-850.
34. Hunter RE, Willis JA. Arthroscopic fixation of avulsion fractures of the tibial eminence: technique and outcome. Arthroscopy. 2004; 20(2):113-121.