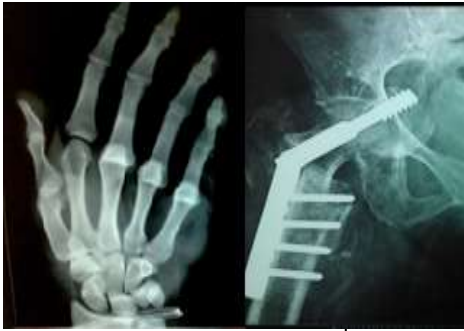



International Journal of Orthopaedics Sciences

ISSN: 2395-1958
IJOS 2018; 4(4): 524-529
© 2018 IJOS
www.orthopaper.com
Received: 25-08-2018
Accepted: 28-09-2018

Dr. Hiren Sarma
Consultant Surgeon, Department
of Orthopaedic surgery, Solace
hospital and Research Centre,
Goalpara, Assam, India

Dr. M Ravikumar
Head of The Department of
Orthopaedic Surgery, Chief Staff
Surgeon, Southern Railway
Hospital, Chennai, Tamil Nadu,
India

Dr. D Dhanalakshmi
ACHD, Department of
Orthopaedic Surgery, Southern
Railway Hospital, Chennai,
Tamil Nadu, India

Dr. TE Ramesh
Sr. DMO, Department of
Orthopaedic Surgery, Southern
Railway Hospital, Chennai,
Tamil Nadu, India

Correspondence
Dr. M Ravikumar
Head of The Department of
Orthopaedic Surgery, Chief Staff
Surgeon, Southern Railway
Hospital, Chennai, Tamil Nadu,
India

Management of medial patellofemoral ligament injury: A case report

Dr. Hiren Sarma, Dr. M Ravikumar, Dr. D Dhanalakshmi and Dr. TE Ramesh

DOI: <https://doi.org/10.22271/ortho.2018.v4.i4f.59>

Abstract

The medial patellofemoral ligament (MPFL) is the primary stabilizer of the patellofemoral joint; its reconstruction has been recommended in adults over the past decade after recurrent patellar instability. However, there has been no standardized technique for reconstruction, therefore, ideal graft and technique for reconstruction are as yet undetermined. We performed this procedure in a patient with chronic pain and patellar instability following trauma. MPFL reconstruction was done with hamstring tendons detached distally and secured to patellar periosteum after being passed through a bony tunnel in the patella without an implant and using the medial collateral ligament as a pulley. The MPFL reconstruction was isolated and was not associated with any other realignment procedures. No recurrent episodes of dislocation or subluxation were reported at 6 weeks follow up.

Keywords: MPFL, patellar periosteum, subluxation, RPD

Introduction

Patellar instability is a relatively common problem, with prevalence of 77 per 100,000 population [1]. The cause of recurrent patellar dislocation (RPD) is multifactorial including alterations in articular geometry (trochlear dysplasia), limb alignment, rotational deformity, patellar height and ligamentous laxity [2, 3]. However pathological insufficiency of the medial patellofemoral ligament (MPFL) has been described as the essential lesion of RPD [4].

The medial side of the knee consists of three layers: The first layer consisting of the deep or crural fascia forming a layer which invests sartorius but is superficial to gracilis and semitendinosus. The second forming the fibers of the superficial medial ligament whose anterior fibers pass upwards to blend with the vastus medialis, and posterior fibers run from the patella to insert at the medial epicondyle (medial patello femoral ligament) The third deep layer forming the capsule of the knee joint. Vertically aligned fibers form the deep layer of the medial ligament or the middle capsular ligament to the mid portion of the medial meniscus and the tibia. (Fig. 1)

The MPFL is thus a distinct soft tissue structure within the medial retinaculum (second layer of knee). It originates from saddle between the adductor tubercle and epicondyle and inserts at the superior two-thirds of medial border of patella, typically at the location where the perimeter of the patella becomes more vertical. It is approximately 55 mm long and its width ranges from 3 to 30 mm and has a mean tensile strength of 203N. This ligament is most taut in full extension, with the quadriceps contracted. The initial treatment of patellar instability is always conservative, comprising of pelvi-femoral rehabilitation, quadriceps progressive strengthening exercises (focusing on vastus medialis obliquus) and braces [4, 7].

Surgical treatment is indicated only when patient remains symptomatic after a good conservative trial [8]. Medial patellofemoral ligament (MPFL) is the most important static stabilizer of the patella, contributing 50-60% (average 53%) of the restraint during initial 30 degrees of knee flexion. 94% patients of patellar dislocation have been found to have involvement of MPFL, 70% at the patellar insertion and the rest at the femoral origin. In all, however, there is also interstitial damage. Patellar tracking is significantly affected by a lateral force in the absence of the MPFL, but returns to normal following reconstruction [9, 11].

So, MPFL reconstruction surgeries are increasingly being used for recurrent patellar dislocations. The Anatomic Double Bundle MPFL Reconstruction technique, replicates the native shape of the MPFL and provides the best possible stability in both flexion and extension. The Double Bundle technique also effectively limits rotation throughout the ROM minimizing postoperative instability. The technique, if accomplished directly and anatomically, may also provide for more aggressive rehabilitation protocols and earlier return to activity.

Recurrent patellar instability is common after a primary episode of traumatic patellofemoral dislocation [1]. Medial patellofemoral ligament (MPFL) is the main soft tissue restraint to lateral patellar translation [2]. There is damage to

the MPFL in almost all cases of traumatic patellofemoral dislocation. Graft anchorage, viability and anisometry of reconstruct play an important role in outcomes of the procedure. Numerous surgical techniques such as proximal realignment, distal realignment, combined realignment, lateral retinacular release and MPFL reconstruction have been described to treat this instability. There has been no comparison between different techniques; therefore ideal graft and technique for reconstruction are yet undetermined. MPFL reconstruction has been recommended in adults over the past decade after recurrent patellar instability. We present a surgical technique for MPFL reconstruction using hamstring graft in a dynamic pattern. We used Kujala score to evaluate outcome.

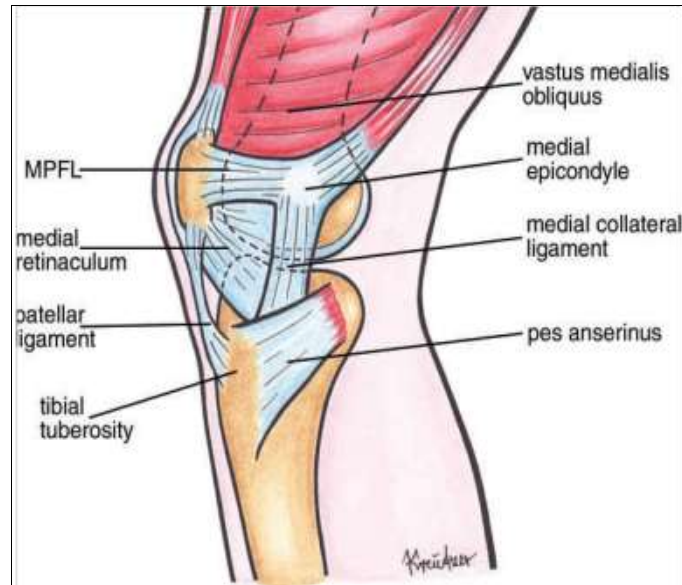


Fig 1: Anatomy of MPFL

Case description

21 year old woman who is a student, presented to our outpatient department with complaints of left anterior knee pain and instability since 8 months. She felt a popping sensation in her right knee after slip and fall with twisting injury to left knee 8 months ago. After this episode, she had severe pain and was unable to move her knee. She was then taken to a quack, after a local manipulation and massaging by him she was relieved of acute symptoms but had persistent knee swelling and mild knee pain. She had one more similar episode since then following non contact twisting injury to knee.

The patient was evaluated in the OPD, she had anterior knee pain, tenderness over medial patellofemoral joint, a positive apprehension test. Patella was dislocatable at moderate pressure. Patellar maltracking was present. Vastus lateralis was wasted. There was no swelling or retropatellar tenderness. Her Q-angle was 21°. Patient had instability of both knees in coronal plane with varus stress opening out of the knee, more of it on the left side. There was tibial external rotation with thigh foot axis measurement of 30 degrees.

Radiographs showed, no bony fragment in the medial patellofemoral joint, lateral patellar subluxation, Insall-Salvatti Index was 1.4 (Fig 2a, 2b). Magnetic resonance imaging (MRI) showed mild effusion of knee joint with complete tear in the MPFL at the patellar attachment, no osteochondral defect in the lateral patellar facet and no osteochondral fragment (fig 3). Of note, she had no other knee surgeries performed to the same knee.

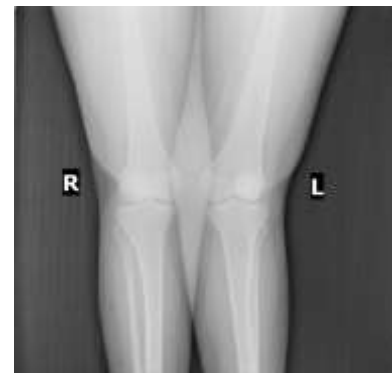

Fig 2a: AP radiograph of knee

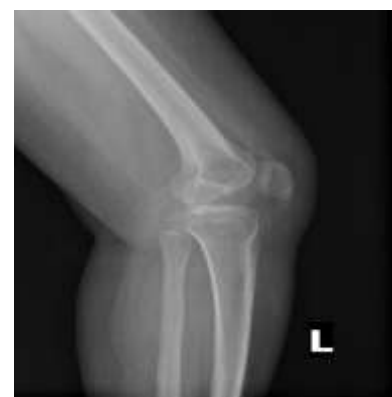

Fig 2b: Lateral radiograph of knee

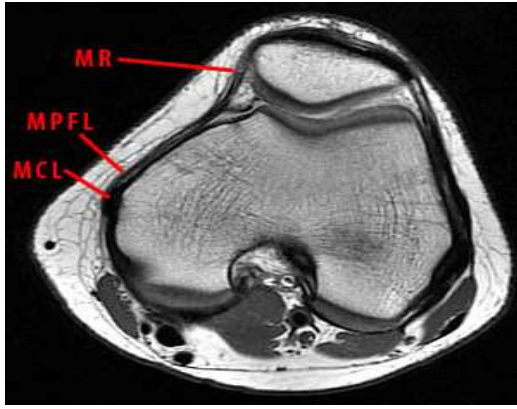


Fig 3: MRI anatomy of normal MPFL

Reconstruction of the MPFL was planned. The patient was informed regarding the need and nature of surgical intervention and also that her case will be considered for publication. Under spinal anesthesia and tourniquet control after the administration of prophylactic antibiotics, first the Semitendinosus and Gracilis tendons were harvested in the usual fashion. A double bundle was prepared (fig 4). Medial patellar border was palpated and a 2 cm skin incision was made from the superomedial corner, extending to the center of the medial edge of the patella. The medial edge of the patella was dissected down and exposed (fig 5). Under fluoroscopic guidance, at a point 3 mm distal to the proximomedial corner of the patella, a 2.4mm drill tip Guide Pin was drilled in a transverse fashion across the patella to a minimum depth of 25 mm. A second 2.4 mm Guide Pin 15-20 mm placed distally and parallel to the first one. The 2 guide pins were over drilled with a 4.5 mm cannulated reamer to a depth of 25mm. The tails of one graft end passed through the eyelet of the first 4.75mm SwiveLock™ (fig 6).The graft/anchor pushed into the proximal drill hole until the eyelet is fully seated. Maintaining tension on the suture limbs and the SwiveLock Anchor screwed into the patella (fig 7, 8). After removal of the driver, the SwiveLock suture should be removed or tied to the graft sutures to reinforce the fixation. This procedure with the second graft end repeated. The proper position of the femoral insertion of the MPFL is very important to maintain proper biomechanics of the patellofemoral joint throughout the entire range of motion. The insertion point is approximately 1mm anterior to the posterior cortex extension line, 2.5mm distal to the posterior

articular border of the medial femoral condyle, and proximal to the level of the posterior point of Blumensaat's line. Under fluoroscopic guidance, a 2.4mm guide pin is drilled across the femur and out through the lateral epicondyle (fig 9,). As the diameter of the doubled gracilis graft is predictably between 4mm and 5mm, the femur is drilled with a 6mm Low Profile Reamer (fig 10). Distal femur was drilled to the far cortex, maintaining the 2.4mm guide pin in the femur, as it will be used to pass the graft into the femur. The space between the vastus medialis and the capsule identified, and bluntly dissected towards the femoral insertion area with a scissor, leaving the capsule intact. A right angle clamp is inserted into the prepared layer down to the medial epicondyle and the tip of the clamp is turned towards the skin. A 1cm longitudinal incision is made and, using the clamp, a looped fiber wire passed back to the patellar insertion area. A 1.1 mm Nitinol guide wire was placed into the drill hole next to the femoral guide wire to facilitate insertion of the 6 mm X 23 mm Bio-Interference Screw. The lateral patellar facet manually fixated flush with the lateral femoral condyle with the knee at 30° of flexion. The isometry of the MPFL was provisionally evaluated at this time by maintaining adequate tension on the graft and cycling the knee through the ROM. The graft sutures were looped into the eyelet of the K-wire and deliver the suture tails out of the lateral femur prior to the graft entering the femoral socket. Using a clamp as a pulley, the graft was pretensioned and insert it into the socket with equal tension on both graft bundles. Once the proper isometry of the construct was confirmed, final fixation can be accomplished. While maintaining tension on the graft under arthroscopic guidance, the 6mmx23mm screw into the femur inserted (fig 11, 12). The wound was closed and a knee immobilizer was applied.

As in post operative rehabilitation and followup, static quadriceps exercises and non-weight bearing walking with walker were started as soon as tolerated (at 3 weeks).At 6 weeks the brace was discarded and knee range of motion exercises and gradual weight bearing were started. The patient is being planned for allowed normal activities at 12 weeks. At the last follow up, which was 6 weeks post surgery, there was no pain, apprehension or lateral instability of the patella. The knee range of motion was 0-100 degrees. The radiograph showed no patellar subluxation and some osteopenia .The Kujala score was 72/100.

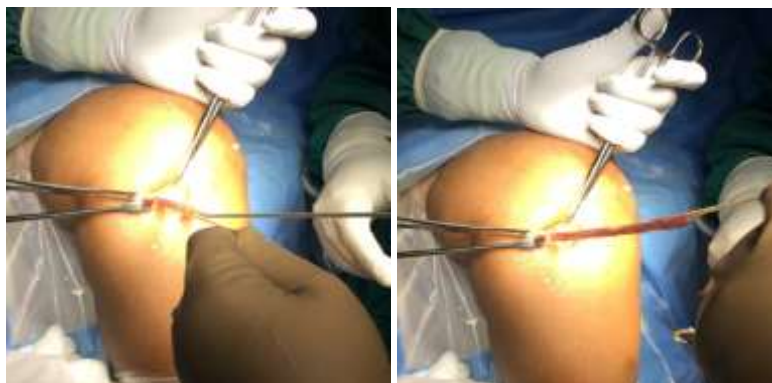

Fig 4(a, b): Double bundle anatomical graft preparation

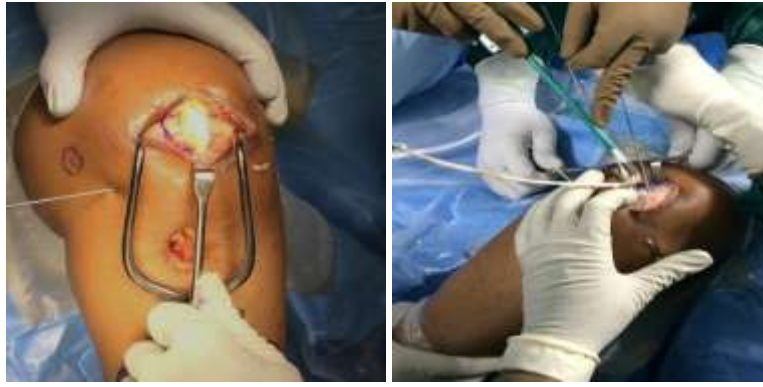

Fig 5, 6: Preperation of patella

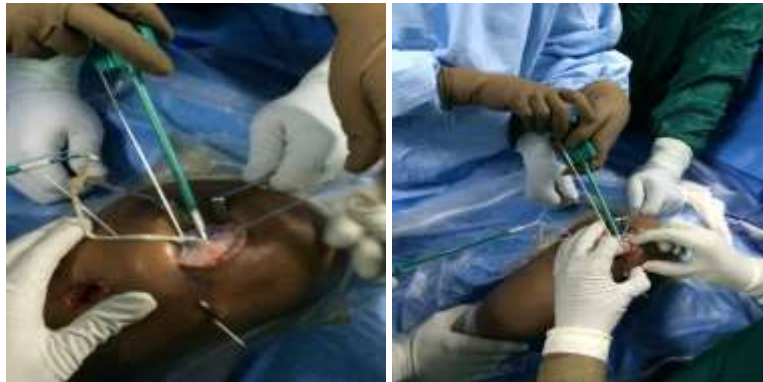

Fig 7, 8: Fixation of patellar end of graft

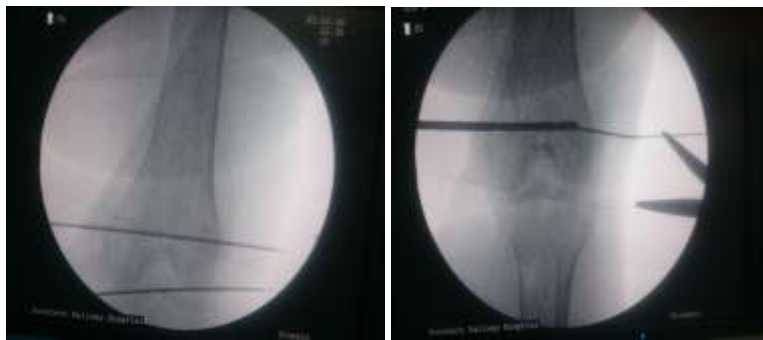

Fig 9, 10: Femoral tunnel preparation

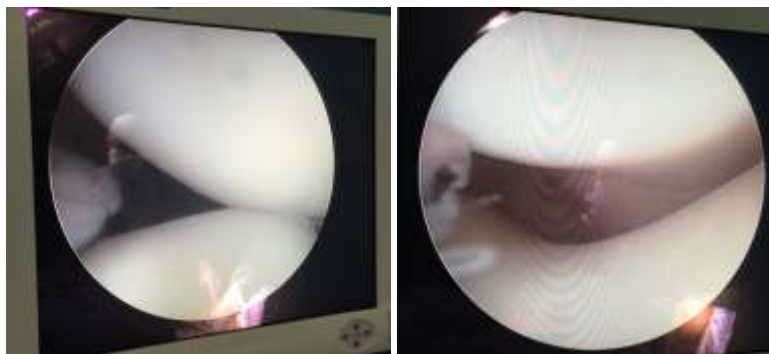

Fig 11, 12: Fixation of femoral end of graft under fluroscopic guidance

Discussion

Chronic recurrent dislocations and subluxations of the patella are often more disabling to the patient than any other isolated ligamentous instability of the knee, and they are more disabling than instability associated with injury to the anterior cruciate ligament (ACL) and also unlike ACL injury patellar instability is typically associated with the knee giving way unexpectedly with minimal trauma during activities of daily living.

Initial treatment of recurrent patellar dislocation is always conservative. Surgery is needed when the patient continues to have symptoms after adequate bracing and muscle strengthening [7, 8]. More than 100 different techniques have been described for patellar stabilization in recurrent dislocation/subluxation in past 100 years [12]. Various procedures, which have been described, are lateral release, medial augmentation, proximal/distal realignment and MPFL reconstruction [2, 12]. The reconstruction of the MPFL gives

better results in recurrent patellar dislocations than with non-anatomical reconstruction, which would alter the biomechanics of the patellofemoral joint [6, 12]. Medial transfer of the tibial tubercle increases joint loading within the medial tibiofemoral compartment and the medial facet of the patellofemoral joint and induces variable changes within the lateral tibiofemoral compartment. Other proximal or distal realignment procedures also lead to poor results due to associated knee osteoarthritis

As MPFL contributes for more than half of the restraint and is involved in most cases, its reconstruction restores the stability and normal patellar tracking [13, 14]. Of the various options, the double bundle autologous hamstring graft has the advantages of good strength, no additional cost, technical ease and minimal donor site morbidity [2, 15]. To replicate the normal MPFL the graft must span between the superior portion of the medial border of the patella and the superior aspect of the medial femoral condyle. The ideal position of the femoral tunnel is at the saddle area between medial epicondyle and adductor tubercle, which is more posterior than expected [16]. Understanding the possible errors in femoral tunnel positioning during MPFL reconstruction, as well as their complications, is key to performing the procedure successfully. The femoral tunnel can be positioned too proximally or too distally, with proximal tunnels causing grafts to become increasingly tight in flexion and distal tunnels causing tightness in extension. Femoral tunnels can also be placed too anteriorly or too posteriorly. In addition to tunnel position, there are other factors that contribute to a successful MPFL reconstruction. The position of the patellar tunnel and the presence of patella alta can also affect the function of the graft. Even a perfectly positioned graft can cause serious problems if it is fixed too tightly. To have optimal position Bollier *et al.* have advised to use a larger incision so that the epicondyle and adductor tubercle can be clearly palpated, to palpate the adductor magnus tendon to have proper orientation and to check the guide wire position in fluoroscopy [17].

Patellar tunnel position and presence of patella alta are another important determinants of the final result [17]. In our case a lower tunnel position would have contributed to the postoperative patella alta. However the most important issue in MPFL reconstruction is to maintain appropriate tension in the graft throughout the knee range of motion and slight alteration in the tension can significantly restrict the joint range of motion, increase the patellofemoral contact pressure or leave residual instability [5, 17, 18]. To have ideal tension the tendon graft should be cycled before fixation and patella should be hold flushed to lateral border of trochlea at 30 of flexion so that patella should engage the trochlea at 20-30 degrees of flexion and be fully centered at 60 flexion. Various patellar fixation methods are direct suturing to the periosteum, single tunnel, loop, endobutton and double tunnel [5, 12, 19, 20].

The strength of fixation is better with the double tunnel technique, but this increases the risk of patellar fracture and joint penetration [12]. Various fixation methods described for femoral fixation are looping over the adductor magnus insertion, direct suturing to the periosteum, by endobutton, with staple, "blind tunnel" or "through tunnel" [12, 19]. Mountney *et al.* have compared various fixation techniques in cadaver and found that the best method of fixation is the screw fixation inside the "through tunnel" [2]. Similar method has also produced good results in vivo by Carmont *et al.* [5] In the present case we have used the through tunnel technique for femoral fixation. We have used cancellous screws similar

to Schock *et al.* [19] Additionally in our technique, we have used small cosmetic incisions and tunneled the graft in between the 2 incisions. To conclude, our low cost and relatively simple technique of MPFL reconstruction has given acceptable results.

References

1. Fithian DC, Paxton EW, Stone ML *et al.* Epidemiology and natural history of acute patellar dislocation. *Am J Sports Med.* 2004; 32(5):1114-1121.
2. Mountney J, Senavongse W, Amis AA, Thomas NP. Tensile strength of the medial patellofemoral ligament before and after repair or reconstruction. *J Bone Joint Surg [Br].* 2005; 87:36e-40.
3. Dejour H, Walch G, Nevret P, Adeleine P. Dysplasia of the femoral trochlea. *Rev Chir Orthop Reparatrice Appar Mot.* 1990; 76(1):45e-54.
4. Andrish J. The management of recurrent patellar dislocation. *Orthop Clin North Am.* 2008; 39:313e-327.
5. Carmont MR, Maffulli N. Medial patellofemoral ligament reconstruction: a new technique. *BMC Musculoskelet Disord.* 2007; 8:22.
6. Reddy KR, Mishra CB. Reconstruction of medial patellofemoral ligament for chronic patellar instability. *Indian J Orthop.* 2012; 46(4):447e-454.
7. Buchner M, Baudendistel B, Sabo D, Schmitt H. Acute traumatic primary patellar dislocation: long term results comparing conservative and surgical treatment. *Clin J Sport Med.* 2005; 15(2):62e-66.
8. Beth E, Shubin S, Christopher SA. The management of patellar instability in the skeletally immature patient. *OperTech Orthop.* 2007; 17(4):250e-256.
9. Conlan T, Garth WP, Lemons JE. Evaluation of the medial soft-tissue restraints of the extensor mechanism of the knee. *J Bone Joint Surg [Am].* 1993; 75:682e-693.
10. Hautamaa PV, Fithian DC, Kaufman KR, Daniel DM, Pohlmeier AM. Medial soft tissue restraints in lateral patellar instability and repair. *Clin Orthop.* 1998; 349:174e-182.
11. Sallay PI, Poggi J, Speer KP, Garrett WE. Acute dislocation of the patella; a correlative pathoanatomic study. *Am J Sports Med.* 1996; 24(1):52-e60.
12. Mikashima Y, Kimura M, Kobayashi Y, Miyawaki M, Tomatsu T. Clinical results of isolated reconstruction of the medial patellofemoral ligament for recurrent dislocation and subluxation of the patella. *Acta Orthop Belg.* 2006; 72:65e-71.
13. Sandmeier RH, Burks RT, Bachus KN, Billings A. The effect of reconstruction of the patellofemoral ligament on patella tracking. *Am J Sports Med.* 2000; 28(3):345e-349.
14. Nomura E. Classification of lesions of the medial patellofemoral ligament in patellar dislocation. *Int Ortho.* 1999; 23(5):260e-263.
15. Cross M, Roger G, Kujawa P. Regeneration of the semitendinosus and gracilis tendons following their transection for repair of the anterior cruciate ligament. *Am J Sports Med.* 1991; 20:221e-223.
16. Schottle PB, Fucentese SF, Romero J. Clinical and radiological outcome of medial patellofemoral ligament reconstruction with a semitendinosus autograft for patella instability. *Knee Surg Sports Traumatol Arthrosc.* 2005; 13:516e-521.
17. Bollier M, Fulkerson J, Cosgarea A, Tanaka M. Technical failure of medial patellofemoral ligament

- reconstruction. *Arthroscopy*. 2011; 27(8):1153e-1159.
18. Beck P, Brown NA, Greis PE, Burks RT. Patellofemoral contact pressures and lateral patellar translation after medial patellofemoral ligament reconstruction. *Am J Sports Med*. 2007; 35:1557e-1563.
 19. Schock EJ, Burks RT. Medial patellofemoral ligament reconstruction using a hamstring graft. *Oper Tech Sports Med*. 2001; 9(3):169e-175.
 20. Drez D, Edwards TB, Williams CS. Results of medial patellofemoral ligament reconstruction in the treatment of patellar dislocation. *Arthroscopy*. 2001; 17(3):298e-306.
 21. Ellera Gomes JL. Medial patellofemoral ligament reconstruction for recurrent dislocation of the patella: a preliminary report. *Arthroscopy*. 1992; 8(3):335e-340.
 22. Muneta T, Sekiya I, Tsuchiya M, Shinomiya K. A technique for reconstruction of the medial patellofemoral ligament. *Clin Orthop Relat Res*. 1999; 359:151e-155.