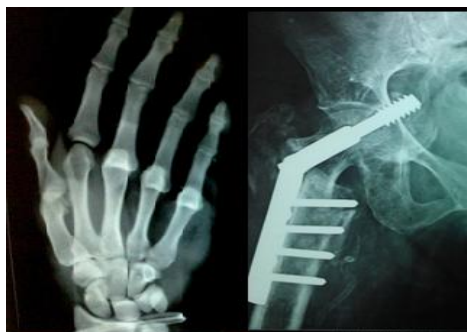



International Journal of Orthopaedics Sciences

ISSN: 2395-1958
IJOS 2018; 4(4): 51-57
© 2018 IJOS
www.orthopaper.com
Received: 12-08-2018
Accepted: 13-09-2018

Dr. Uday B Pote
DNB Orthopedics, Consultant
Spine Surgeon, Jupiter Hospital,
Pune, Maharashtra, India

Dr. Prajakta U Pote
DNB Anesthesia, IDCCM,
Consultant Anesthetist and
Intensivist, Ruby Hall Hospital,
Pune, Maharashtra, India

Dr. Bande B D
MD Anesthesia, MD Medicine,
FICCM, EDIC, Senior
Consultant, KEM Hospital,
Pune, Maharashtra, India

Dr Sonali Khanapurkar
MD Anatomy, Head of Anatomy
Dept. Sinhgad Dental College,
Pune, Maharashtra, India

Correspondence
Dr. Uday B Pote
DNB Orthopedics, Consultant
Spine Surgeon, Jupiter Hospital,
Pune, Maharashtra, India

Novel technique of diagnosing and reducing pain in cervical radiculopathy

Dr. Uday B Pote, Dr. Prajakta U Pote, Dr. Bande BD and Dr Sonali Khanapurkar

DOI: <https://doi.org/10.22271/ortho.2018.v4.i4b.12>

Abstract

Background: Neck pain with upper limb pain is a common complaint of patients seen in Out Patient Department (OPD). Such pain may be because of a pinched nerve. There is inflammation in the nerve which causes radicular symptoms. The available clinical tests for cervical radiculopathy are provocative tests, difficult to perform and techniques vary from author to author. The reliability of these tests is only when done in clusters. We devised a novel non-provocative clinical sign to diagnose cervical radiculopathy and a method to reduce upper limb radicular pain and thereby improving the function of the upper limb.

Method: Patient's bilateral pronated wrists were palpated dorsomedially on the ulnar styloid. This elicited tenderness over the Dorsal Cutaneous branch of Ulnar Nerve (DCU). The painless active degree of movement at shoulder and elbow joints was noted. Nerve block at the palpated tender point was given using 2% lignocaine in 95 patients. We used Visual Analogue Scale score to measure radicular pain intensity before and 5 minutes after injection.

Results: All patients had tenderness at the DCU on the symptomatic upper limb. All patients had reduction in VAS of radicular pain from 7.36 ± 0.89 before injection to 1.89 ± 0.98 after injection with improvement of shoulder and elbow active movement.

Conclusion: We recommend palpation of DCU in both upper limbs in all cases of suspected cervical radiculopathy. Palpation to elicit tenderness over DCU in cervical radiculopathy, was documented as Pote's sign positive. Injection of local anesthetic agent over DCU reduces pain and improves upper limb function and it was documented as Pote's test positive. This test is of diagnostic and therapeutic significance. This test is minimally invasive and can be done in an OPD set-up.

Keywords: Cervical radiculopathy, distal block, dorsal cutaneous branch of ulnar nerve, Pote's sign, Pote's test

Introduction

The neck pain with associated upper limb radiculopathy is a common complaint in an orthopedic Out Patient Department (OPD). Cervical radiculopathy is a pain radiating to the upper limb due to irritation of the nerve. The symptomatic presentation ranges from mild upper limb pain to severe pain with restriction of upper limb movements.

Some patients may have co-existent shoulder pathology. The clinical examination of shoulder joint often rules out shoulder pathologies. But, the symptoms radiating from or to the shoulder joint present a diagnostic dilemma to rule out cervical radiculopathy. The clinical features of tingling, numbness and weakness are classical to radiculopathy but such presentation is infrequent or usually late.

In general population, the prevalence of cervical radiculopathy is 3.5 per 1000 population^[1]. The cervical radiculopathy result from nerve root dysfunction and is often due to mechanical compression. However, inflammatory cytokines released from damaged intervertebral discs can also result in radicular symptoms^[2]. The nerve root inflammation has the potential to produce significant pain and functional limitation. This often leads to panic in patients resulting in unnecessary hospital admissions and investigations.

Many clinical examination tests are found to be reliable when done in cluster. The upper limb tension tests are reliable to diagnose cervical radiculopathy^[3]. These are provocative tests which increase the pain in already distressed patient.

Also, performing these test maneuvers is difficult. Investigations like Magnetic Resonance Imaging (MRI) and Neurophysiological studies (NPS) are costly and cannot be done in an OPD set-up. We propose a unique, non provocative, reliable and cheap test to be performed in an OPD set-up, in which we locate and inject lignocaine over the Dorsal Cutaneous branch of the Ulnar nerve (DCU). This test not only helps in diagnosis but also relieves the radicular symptoms. We selected the DCU as it is one of the sensory pseudo unipolar nerves. The pseudounipolar neurons are most common type of neurons in the human nervous system. These neurons sense pressure, touch and pain. They are also found in bundles grouped in Dorsal Root Ganglion (DRG), which are blocked in selective nerve root block procedure [4]. In pseudounipolar neurons the axons and dendrites are fused, giving the appearance of a single process. Here axons and dendrites are biochemically indistinct. This is significant as this afferent neuron can send and receive signals from either ends [5]. The radicular pain is mostly due to radiculitis, an inflammatory pain sensation [6]. This pain can be elicited by palpating the nerve distally [7].

In cervical radiculopathy the pain distribution pattern is non-dermatomal, with the exception of C4 dermatome. In upper limb the dermatomal pattern of pain distribution is seen in one-third of patients as against lower limb radiculopathy wherein it is seen in two-third of patients [8]. There are many intersegmental anastomoses in the dorsal nerve roots at cervical level [9]. Due to such connections, when a particular nerve root is affected, the pain distribution pattern is not always along the supply of the nerve. There is often a

mismatch between affected nerve root and presenting clinical pattern of symptoms. Similarly we have found consistent DCU tenderness on the affected side in all cases of cervical radiculopathy, regardless of the nerve roots affected at the spinal level. Pain is a sensation resulting from sodium-channel dysfunction in the neural tissue, leading to ectopic generation of action potentials [10, 11]. We plan to block these sensations using lignocaine which is a sodium channel blocker [12].

Material and methods

Prospective study was carried out on 111 patients over duration of 18 months from January 2016 to April 2017. All the patients with neck pain and upper limb radicular pain presenting within 3 -12 weeks of symptoms were screened for the study. Patients with neck or shoulder pain and pain over any one or more of the dermatomes C4, C5, C6, C7, C8 and T1, were included in the study. Patients were assessed for neck motion range and power of muscles of the painful upper limb. MRI of cervical spine was done in all the patients included in the study after the sign or the test was performed to determine the confirmation of the cervical pathology for the radiculopathy. The study was performed by a single examiner. Shoulder examination was carried out to rule out impingement syndromes, rotator cuff injuries and other shoulder pathologies. Patients with neurodeficit, sensitivity to lignocaine, and those with shoulder pathologies were excluded from the study. Patients with isolated neck pain, with solitary C4 distribution of pain were also excluded. The exclusion criteria are summarized in Table 1.

Table 1: Exclusion criteria

Exclusion criteria
Isolated neck pain
Neck pain with sole C4 dermatomal pain
Neurodeficit
Shoulder pathology (on examination)
Sensitivity to injection lignocaine

This led to exclusion of 16 out of 111 patients screened for the study. Out of 95 patients who were included in the study, 33 were females and 62 were males. Written information about the study plan was given and explained to the patients highlighting the diagnosis and injection part. All the patients consented willingly for the study by signing the printed consent form (Appendix A). We had attained the ethical board clearance for the conduction of the test.

The procedure was divided into two parts.

Part A consisted of assessment of radicular pain in the upper limb with VAS and locating the dorsal cutaneous nerve of ulna and determining the tenderness at site of palpation.

Part B consisted of injecting the identified region with lignocaine injection and reassessment of radicular pain using VAS at 5 minutes after injection.

Part A

- 1. Assessment of upper limb pain using VAS score:** Patients were asked to mark on the visual analogue scale showing face scale along with mark from 0 to 10 where 0 is no pain and 10 is worst pain imaginable like cutting off of the limb. Refer to Appendix A.
- 2. Eliciting tenderness over DCU:** Clinically location of nerve was determined by using thumb to palpate on the

dorso-medial aspect of the ulnar styloid with forearm fully pronated (Figure 1). We palpated the DCU in both the hands at the same time so as to find out whether the symptomatic side had increased tenderness. Slight rolling movement of the thumb was used to stimulate the nerve (Figure 2). Tenderness at the DCU was considered as the positive sign for cervical radiculopathy.

- 3. Functional assessment of upper limb joints:** We asked the patients to move the upper arm at shoulder joint and elbow to see if pain aggravated with movement and same was noted.

Part B: DCU block with injection of lignocaine

1. Patients were screened for lignocaine hypersensitivity. Under aseptic precautions, 4cc of 2% injection lignocaine was injected using a 26 gauge needle over the palpated tender spot corresponding to the DCU. As the nerve is superficial, injection was given just below the dermis.
2. Upper limb pain reassessment was done with VAS score at minutes after the injection.
3. We then asked the patient to move the upper limb at shoulder and elbow joints to note any improvement in movements.

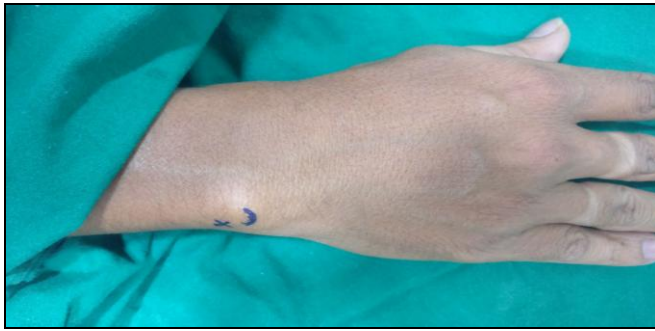

Fig 1: Location of tenderness corresponding to DCU is marked dorsomedially on the fully pronated wrist. Curved mark is the



Fig 2: Palpation of DCU on both the pronated wrists, using the thumb and rolling movement to stimulate the nerve.

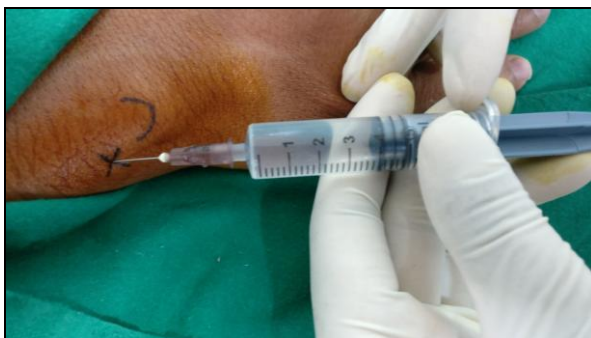

Fig 3: Injection of lignocaine subdermally over the DCU.

Observations and Results

Table 2: The distribution of general characteristics of cases studied (n = 95).

Parameters	No. of Cases (n)	% of Cases
Age Group (years)	18.0 – 27.0	10
	28.0 – 37.0	26
	38.0 – 47.0	12
	48.0 – 57.0	31
	58.0 – 67.0	13
	68.0 – 70.0	3
Sex	Male	62
	Female	33
Pain Site	Right	48
	Left	47

Values are 'n' (% of cases).

Of 95 cases studied, the most common age group was 48.0 – 57.0 years (32.6% of total cases). The minimum – maximum age range of the cases studied was 18.0 years to 70.0 years and the mean ± standard deviation of age of the entire study group was 44.6 ± 13.6 years.

The male to female sex ratio in the entire study group was 1.88: 1.00.

The most affected pain side was right upper limb (50.53% of total cases).

All patients with positive test had positive MRI findings correlating to the radicular pain.

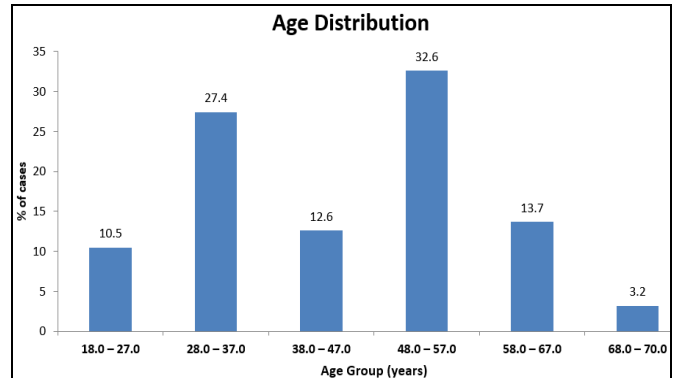


Fig 4a: The sex distribution of cases studied (n = 95).

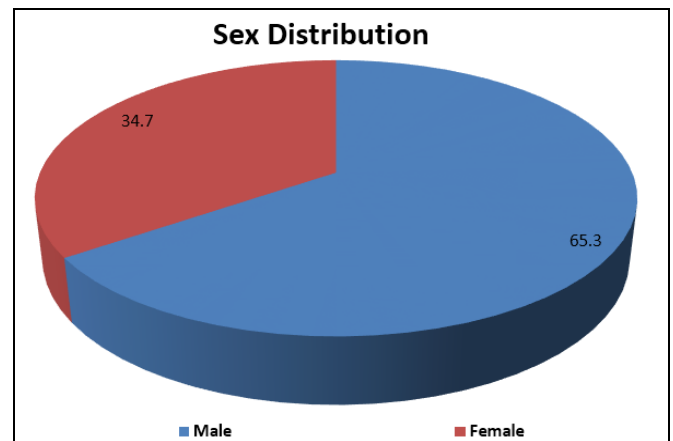


Fig 4b: The sex distribution of cases studied (n = 95)

Table 3: The before and after injection comparison of Pain score (VAS) (n = 95).

Follow-up	Pain Score (VAS)	
	Mean	SD
Before Injection	7.36	0.89
After Injection (5-Mins)	1.89	0.98
% Change After Injection	73.50%	15.99%
P-values (Intra-Group)	T-value	P-value
Before Vs After	36.911	0.001***

P-values by Paired t test. P-value <0.05 is considered to be statistically significant.

***P-value <0.001 (Highly Significant).

The mean ± SD of VAS before injection and 5-min after injection was 7.36 ± 0.89, and 1.89 ± 0.98 respectively. The mean percentage improvement (change) in VAS, after injection (5-mins) compared to VAS before injection was 73.50%.

The mean VAS had significantly improved after injection (5-mins) compared to mean VAS before injection (P-value <0.001).

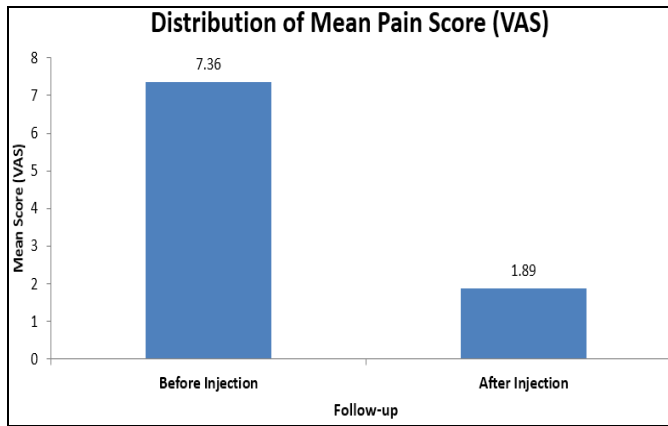


Fig 5: The comparison of Pain score (VAS) before and after injection (n = 95).

Results

All the symptomatic patients in the study had tenderness over the DCU on the affected side. The pain in C5 to T1 dermatomes was found to be relieved after the lignocaine injection. The shoulder and elbow movements were also found to be improved. Neck pain and trapezial tender point were found to be relieved only to some extent but it could not be assessed completely as the muscle spasm around the neck was variable in different patients.

Discussion

Cervical radiculopathy is a neurologic condition characterized by dysfunction of a cervical spinal nerve and nerve root or both. It usually presents with pain in the neck and in one or both upper limbs. Such pain may or may not be associated with sensory or motor deficit and reflex changes in the affected nerve root distribution [13].

Most common causes of cervical radiculopathy are degenerative changes in the cervical uncovertebral joints leading to cervical spondylosis, intervertebral disc prolapse with resulting nerve root impingement. There are many instances wherein cervical radiculopathy cannot be attributed to a definite cause. In these cases pain is derived from root irritation from inflammation produced by degrading discal proteoglycans. Less common causes include vertebral collapse, spondylolisthesis, vertebral fracture dislocation, trauma to cervical roots with avulsion or radiation injury, infectious, neoplastic, infiltrative, para-infectious and metabolic conditions [14]. Though the process of nerve compression or nerve hypoxia and interaction between neurogenic and non-neurogenic cytokines is not well understood, it is certain that dorsal root ganglion affection is important in pain perception resulting from the afferent conduction of nociceptive stimuli [15].

Cervical radiculopathy presentation is varied and does not follow classical myotomal or dermatomal distribution associated with each nerve root [2]. The examiner must keep in mind that dermatomal descriptions as demonstrated in the medical textbooks do not match the sensory symptoms presented by the patients [16]. Almost all areas in skin are innervated by two or more spinal nerve roots, which is the reason for variability in dermatomal pattern of pain distribution in individuals. Also, the intrathecal intersegmental anastomoses between dorsal spinal rootlets, enable the sensory neurones with a ganglion cell at one dorsal root ganglion to enter the spinal cord at a different level [9]. The dermatomal pattern distribution is not useful to delineate the affected nerve in radicular pain [17]. This means, a patient

complaining of neck pain and pain along ventral aspect of arm (C5/C6/C7 dermatomes) will not correlate to have affection of the same nerve roots. So, the dermatomes do not help to delineate a particular nerve involvement.

There are no universally accepted criteria to diagnose cervical radiculopathy [14, 18]. Diagnosis of cervical radiculopathy can be made on history [13]. But, history alone cannot be relied upon for making a diagnosis. There are several clinical tests like Spurling's test, distraction test, muscle squeeze test, the upper limb tension tests. These tests have only fair to acceptable level of reliability, so use of 'cluster of test items' is recommended [3]. There is poor standardization of the clinical examination which leads to inter-observer variability [19]. So we are left with various authors describing the particular tests differently. Gore and Nadkarni, had described a technique to diagnose sciatica by palpating the sensory afferent of the affected nerve distally in ankle [7]. We have designed a similar study wherein we palpated the sensory afferent nerves of the affected upper limb. The location of the nerve to be palpated should be easy and well defined. If the palpation is against a defined and small area of the bone the interobserver error is reduced. We chose the afferent sensory only nerves which are characteristically pseudounipolar. The palpation of the dorsal cutaneous nerve of radius against the radial styloid and the dorsal cutaneous nerve of ulna against the ulnar styloid was done. The area of radial styloid is larger and there are high chances of missing the radial cutaneous nerve. The superficial radial nerve in the anatomical snuffbox is very susceptible to mild trauma and shearing forces as well [20]. The palmar cutaneous branch of median nerve is over the flexor retinaculum at the wrist and has variable course [21]. The non-proximity to vessels or tendons and ease in isolation of the nerve for palpation and injection is the reason we chose to study the dorsal cutaneous nerve of ulna instead.

Puna and Poon have described the relation of dorsal cutaneous branch of ulnar nerve in relation to ulnar styloid. They have mentioned the nerve to be subcutaneous and crossing from palmar aspect to dorsum 0.2 cm proximal to the ulnar styloid. It came slightly palmar and radial on full pronation [22]. We palpated the patient's wrist at the dorsomedial surface of the ulnar styloid with forearm in full pronation using our thumb. Palpating the area with thumb and using small rotatory movements would stimulate the nerve precisely. The ulnar styloid as a landmark is small, we can easily use this landmark to delineate the DCU. There are no vessels crossing the field of injection so the location is safe to inject lignocaine.

Cervical radiculopathy due to nerve irritation results due to affliction of the DRG. The disc degeneration begins with the structural failure within the disc. There is loss of normal structure and weight bearing properties which lead to abnormal vertebral motions. This leads to neo-vascularization of otherwise avascular annulus. There is increase in influx of inflammatory and signaling substances such as tumor necrosis factor and interleukins [23]. The annular tear thus caused, leads to exposure of the Nucleus Pulposus (NP) which is immunogenic that leads to rise in inflammation of nearby nervous structures like the DRG [24]. There is resulting disintegration of DRG capsule which leads to increased permeability leading to increased inflammatory input from surrounding nucleus pulposus. This leads to ectopic discharges in the A-delta and C-fiber primary afferents, including nociceptors. It has been proposed that acute exposure of nerve root to NP causes inflammation induced morphological changes like minor axonal and Schwann cell

damage and also membrane changes in the axons leading to altered mechanical properties. This results in pain along the sensitized nerve root. This pain can be stimulated also by mechanical manipulation like movement of the limb or bending; stretching of the nerve [25]. Sodium channel dysfunction plays a major role in ectopic generation of action potentials. Patients get episodes of "pain attacks", corresponding to bursts of spontaneous activity in the injured afferent neurons [6]. Peripheral pain input is documented as necessary for persistence of pain states which leads to unresolved nociceptor sensitization [26]. This sensitization is detected by palpating the nerve also called as mechanosensitisation [7].

The ongoing nociceptive afferent input from a peripheral focus causes allodynia. It can also cause variable sensory-motor symptoms. The mechanism is thought to be an alteration in central processing of these afferent inputs and is often observed in neuropathic pain. Blockade of these peripheral inputs is known to abolish the symptoms by reversal of central processing [27]. Depending on the affection of various structures by the lesion, there will be difference in symptoms. If the posterior columns of the cord are affected, it will lead to paresthesias and if nerves, nerve roots, root entry zone or the spino thalamic tracts are affected, it will lead to pain. These pain and paresthesia are due to discharge from the affected nerve fibres in or near lesion. The evidence suggests that, the local anaesthetic injections distal to the site of the lesion may lead to abolition of such symptoms and this effect may prolong beyond the duration of action of local anaesthetic. Further, the symptoms from the entire region seem to be abolished [28]. The mechanism seems to be mediated through the sodium gated channels, NaV, causing the blockade of action potential initiation and propagation in nociceptors [26]. This is also observed in injured nerve tissue. The sodium gated channel is well documented as cause of pain and ectopic ongoing activity in injured afferent cutaneous and muscle A-and C-fibers. This is inhibited by local application of lignocaine which is a sodium channel blocker [12]. We have had similar results wherein blocking of the DCU with lignocaine has reduced the pain of the area far larger and wider than the supply of the nerve and also the effect of the local anesthetic was seen outlasting its documented duration of action. However the exact mechanism responsible of this relief of symptoms is not yet known. DCU is a primary afferent sensory nerve and its neurons have a unique morphology of being pseudo-unipolar, in which recipient branch (the dendrite) and the transmission branch (the axon) are biochemically indistinct [5]. This facilitates that theurapeutics directed at either terminals can influence pain message transmission. Thus, lignocaine applied to one terminal can regulate action potential throughout the nerve, leading to relief from the proximal pain [28]. As described by Remak, the C-fibre axons assemble into bundles within the nerve. The study of these bundles in rats have shown that there is discrepancy of the number of exiting Remak bundles from the DRG of L5 and distal plantar nerve [29]. This suggests that the Remak bundles from DRG spread to areas other than their respective territory. So, the lesion and its expression distally may not always coincide. In one more study on rats, the injured L5 afferents could also project to the adjacent L4 segment where they could produce heterosynaptic sensitization to input from L4 segment. This could account for the hyper-algesia to mechanical and heat stimuli that is signaled by activity in the intact L4 afferents. Thus the abnormalities seen in these "intact" nociceptors are likely to

account for the response seen after the application or injection of local anaesthetic to the skin where these intact nociceptors are located. The pain signals arise not only from the injured axons but also from the nearby intact afferents that share the same innervation territory [6]. There are various mechanisms proposed to explain the extended effects of the nerve injury, beyond the innervated territory. The injury to a nerve, results in loss of its access to the trophic factors, which leads to changes in expression, density and distribution of ion channels. This leads to hyper excitability in injured afferents. At the same time the trophic factors released at the target sites are freely available without competition to the uninjured afferents. This increase in accessibility to trophic factors leads to phenotypic changes in the neighboring uninjured afferents and resulting into increased excitability [26]. Thus the intact afferent seems to be acting as the source of ongoing pain and we thought, by blocking the same by the local lignocaine injection the relief from the symptoms can be achieved. Unlike the lower limb which has intersegmental anastomoses in 22% of nerves, the upper limb has 61% of intersegmental anastomoses of spinal nerves [9]. Considering all the above facts we can establish the upper limb as one territory. This one territory has common nerve supply which is the brachial plexus (C5/6/7/8/T1). We can block sensory afferent from any of the C5 to T1 nerve roots to abolish the cervical radicular symptoms. Our study group patients had relief in the radicular pain from C5 to T1 dermatomes. We found some patients had relief in C4 dermatome and some didn't. High brachial variant of normal brachial plexus anatomy may be responsible for such relief in the patients. Somatic pain is neck pain which does not involve the nerves or nerve roots and it radiates from the cervical spine to shoulder, supraspinous fossa or scapula and is rarely felt below elbow. [16] This type of pain was seen unrelieved in our patients. Electrodiagnostic studies are sensitive to motor radiculopathies. They are not useful to evaluate sensory fibres. Also, the results change with operators, methods or baseline values used by these laboratories. Magnetic resonance imaging has higher sensitivity but the structural abnormalities shown may not necessarily indicate the cause of the pain [30]. MRI scans or electrodiagnostic studies cannot demonstrate the pain due to chemical neuritis or radiculitis. These tests are costly and require larger set-up. The test we propose is cheap and can be performed in OPD. Our results show two surges in incidence of pain according to age group. First surge at 28-37 years of age and second larger surge at 48-57 years of age group. The previous survey studies show a high incidence of cervical radiculopathy in the age group of 40-60 years [1, 14]. The surge seen in younger age group of 28-37 years of age has not been reported by any study so far. This may get attributed to different lifestyle changes encountered in younger generation. Further studies will be needed to know the prevalence. There are mixed reports of dominance of pain in men and women [1, 14]. In our study, we have found a slightly more male predominance for cervical radiculopathy (Table 2 and Figure 4b). Patients with neck pain and radiculopathy may have severe neck muscle spasms and may be associated with inability to use the affected limb. In such symptomatic patient, doing a provocative test to find out the radicular nature of pain adds to the suffering he already is in. Instead, we asses and relieve the pain by a distal block and then analyze the likely cause and plan further treatment. This kind of correlation between the severity of nerve injury and pain relief by local anesthetic injection in intact afferents also needs further evaluation.

Palpation of DCU and eliciting the tenderness is a sign we propose to be called as “Pote’s sign” to diagnose cervical radiculopathy and injection of lignocaine at the DCU to reduce the radicular pain, we propose to be “Pote’s test”. We recommend this sign and the test as well defined and cheaper tools for diagnosing and confirming the radicular nature of the pain especially in cases of overlap on the shoulder pathologies or other conditions that mimic cervical radiculopathy. We do not claim this test to resolve the underlying pathology of cervical radiculopathy. This sign and test is highly recommended for diagnostic purposes rather than a therapeutic measure. Neck pain radiating only to shoulder or elbow (C5/6 dermatome) may be somatic pain or originating from cervical elements not affecting nerves. We have used Pote’s sign in such patients, to identify if nerve involvement is there and if positive then only performed Pote’s test. Thus we reiterate that Pote’s test should be performed only in those cases that show Pote’s sign positive. Looking at the various proposed mechanisms which could explain the pain relief obtained, it is possible that any afferent nerve injection in affected upper limb will potentially relieve the radicular pain. Tests like MRI and NPS have high sensitivity 93% and 42% respectively for cervical radiculopathy. But, the negative predictive value for MRI and NPS is 25% and 7% respectively [30, 31]. We feel this test could be a correlate test to MRI to reduce the negative predictive value. This is a preliminary study. As history is considerable proof of diagnosis, we have seen positive sign and relief in pain after the test in all the patients of cervical radiculopathy; this suggests high sensitivity of the sign and the test. Yet we do feel the need of a study with larger sample size and one that correlates findings with MRI or NPS and other clinical tests to decide the level of sensitivity and specificity. Further studies also will be needed to know, whether injecting lignocaine distally in the afferent neurons, leads to stimulation of different descending pathways giving prolonged relief of the pain. This study opens doors to research the block of peripheral sensory nerve to reduce centrally erupted pain.

Conclusion

We recommend palpation of DCU of both upper limbs in all cases of suspected cervical radiculopathy. Palpating the DCU on the affected limb in cervical radiculopathy elicits tenderness which we document as Pote’s sign positive. Injection of local anesthetic agent around area of DCU reduces pain and improves upper limb function in symptomatic patients with radicular pain and we document the same as Pote’s test positive. This sign is of diagnostic significance as it is non provocative and the test relieves the pain.

References

- Salemi G, Savettieri G, Meneghini F *et al.* Prevalence of cervical spondylotic radiculopathy: a door-to-door survey in a Sicilian municipality. *Acta Neurol Scand.* 2009; 93(2-3):184-188. doi:10.1111/j.1600-0404.1996.tb00196.x
- Ellenberg MR, Honet JC, Treanor WJ. Cervical radiculopathy. *Arch Phys Med Rehabil.* 1994; 75(3):342-352. doi:10.1056/NEJMcp043887
- Wainner RS, Fritz JM, Irrgang JJ, Boninger ML, Delitto A, Allison S. Reliability and diagnostic accuracy of the clinical examination and patient self-report measures for cervical radiculopathy. *Spine (Phila Pa),* 1976, 2003; 28(1):52-62. doi:10.1097/00007632-200301010-00014
- Klessinger S, Freund W, Karpel-Massler G, Halatsch ME. Response to transforaminal injection of steroids and correlation to MRI findings in patients with cervical radicular pain or radiculopathy due to disc herniation or spondylosis. *Pain Med (United States).* 2014; 15:929-937. doi:10.1111/pme.12415
- Basbaum AI, Bautista DM, Scherrer G, Julius D. Cellular and Molecular Mechanisms of Pain. *NIH Public Access.* 2010; 139(2):267-284. doi:10.1016/j.cell.2009.09.028. Cellular
- Campbell JN, Meyer RA. Review Mechanisms of Neuropathic Pain. *Neuron.* 2006; 2:77-92. doi:10.1016/j.neuron.2006.09.021
- Gore S, Nadkarni S. Sciatica: Detection and Confirmation by New Method. *Int J Spine Surg.* 2014; 8:15. doi:10.14444/1015
- Murphy DR, Hurwitz EL, Gerrard JK, Clary R. Pain patterns and descriptions in patients with radicular pain: Does the pain necessarily follow a specific dermatome? *Chiropr Osteopat.* 2009; 17:9. doi:10.1186/1746-1340-17-9
- Moriishi J, Otani K, Tanaka K, Inoue SI. The intersegmental anastomoses between spinal nerve roots. *Anat Rec.* 1989; 224(1):110-116. doi:10.1002/ar. 1092 240114
- Nickel FT, Seifert F, Lanz S, Maihöfner C. Mechanisms of neuropathic pain. *Eur Neuropsychopharmacol.* 2012; 22:81-91. doi:10.1016/j.euroneuro.2011.05.005
- Omoigui S. The biochemical origin of pain-Proposing a new law of pain: The origin of all pain is inflammation and the inflammatory response. Part 1 of 3-A unifying law of pain. *Med Hypotheses.* 2007; 69:70-82. doi:10.1016/j.mehy.2006.11.028
- Kirillova I, Teliban A, Gorodetskaya N *et al.* Effect of local and intravenous lidocaine on ongoing activity in injured afferent nerve fibers. *Pain.* 2011; 152(7):1562-1571. doi:10.1016/j.pain.2011.02.046
- Carette S, Fehlings MG. Cervical radiculopathy. *N Engl J Med.* 2005; 353(4):392-399. doi:10.1056/NEJMcp 043887
- Dillin W, Booth R, Cuckler J, Balderston R, Simeone F RR. Cervical radiculopathy. A Review. *Spine (Phila Pa),* 1976, 1986; 11(10):988-991. <https://www.ncbi.nlm.nih.gov/pubmed/3576348>.
- Song XJ, Hu SJ, Greenquist KW, Zhang JM, LaMotte RH. Mechanical and thermal hyperalgesia and ectopic neuronal discharge after chronic compression of dorsal root ganglia. *J Neurophysiol.* 1999; 82(6):3347-3358.
- Abbed KM, Coumans JVCE. Cervical radiculopathy: Pathophysiology, presentation, and clinical evaluation. *Neurosurgery.* 2007; 60(1):28-34. doi:10.1227/01.NEU.0000249223.51871.C2
- Radhakrishnan K, Litchy WJ, O’fallon WM, Kurland LT. Epidemiology of cervical radiculopathy a population-based study from Rochester, Minnesota, 1976 through 1990. *Brain.* 1994; 117:325-335.
- Honet JC, Ellenberg MR. What you always wanted to know about the history and physical examination of neck pain but were afraid to ask. *Phys Med Rehabil Clin N Am.* 2003; 14(3):473-491. doi:10.1016/S1047-9651(03)00039-1
- Viikari-Juntura E. Interexaminer reliability of observations in physical examinations of the neck. *Phys Ther.* 1987; 67(10):1526-1532. doi:10.1093/ptj/67.10. 1526

20. Lee Dellon A, Mackinnon SE. Susceptibility of the superficial sensory branch of the radial nerve to form painful neuromas. *J Hand Surg Am.* 1984; 9(1):42-45. doi:10.1016/0266-7681(84)90012-3
21. De Smet L. Palmar cutaneous branch of the median nerve. *J Hand Surg Eur.* 1998; 23(1):115-116. doi:10.1016/S0266-7681(98)80240-4
22. Puna R, Poon P. The Anatomy of the Dorsal Cutaneous Branch of the Ulnar Nerve. *J Hand Surg European.* 2010; 35(7):583-585.
23. Brisby H. Pathology and possible mechanisms of nervous system response to disc degeneration. In: *Journal of Bone and Joint Surgery-Series A.* 2006; 88:68-71. doi:10.2106/JBJS.E.01282
24. Byröd G, Rydevik B, Nordborg C, Olmarker K. Early effects of nucleus pulposus application on spinal nerve root morphology and function. *Eur Spine J,* 1998; 7(6):445-449. doi:10.1007/s005860050106
25. Murata Y, Rydevik B, Takahashi K, Larsson K, Olmarker K. Incision of the intervertebral disc induces disintegration and increases permeability of the dorsal root ganglion capsule. *Spine (Phila Pa),* 1976, 2005; 30(15):1712-1716. doi:10.1097/01.brs.0000172231.111296.13
26. Gold, Michael S, Gebhart GF. Nociceptor sensitization in pain pathogenesis. *Nat Med.* 2010; 16(11):1248-1257. doi:10.1038/nm.2235
27. Gracely RH, Lynch SA, Bennett GJ. Painful neuropathy: altered central processing maintained dynamically by peripheral input. *Pain.* 1992; 51(2):175-194. doi:10.1016/0304-3959(92)90259-E
28. Kibler RF, Nathan PW. Relief of pain and paraesthesiae by nerve block distal to a lesion. *J Neurol Neurosurg Psychiatry.* 1960; 23:91-98. <http://www.pubmedcentral.nih.gov/articlerender.fcgi?artid=495338&tool=pmcentrez&rendertype=abstract>.
29. Murinson BB, Griffin JW. C-Fiber Structure Varies with Location in Peripheral Nerve. *J Neuropathol Exp Neurol.* 2004; 63(3):246-254. doi:10.1093/jnen/63.3.246
30. Reza Soltani Z, Sajadi S, Tavana B. A comparison of magnetic resonance imaging with electrodiagnostic findings in the evaluation of clinical radiculopathy: A cross-sectional study. *Eur Spine J,* 2014; 23(4):916-921. doi:10.1007/s00586-013-3164-z
31. Ashkan K, Johnston P, Moore AJ. Original Article A comparison of magnetic resonance imaging and neurophysiological studies in the assessment of cervical radiculopathy. *Br J Neurosurg.* 2002; 16:146-148. doi:10.1080/0268869022013174