



## International Journal of Orthopaedics Sciences

ISSN: 2395-1958  
IJOS 2018; 4(4): 23-27  
© 2018 IJOS  
www.orthopaper.com  
Received: 07-08-2018  
Accepted: 09-09-2018

**Dr. Ravijeet Prakash**  
Post Diploma DNB, Department  
of Orthopaedics, Tata Main  
Hospital, Jamshedpur  
Jharkhand, India

**Dr. Shashi Kant Kumar Singh**  
Senior Resident, Department of  
Orthopaedics, RIMS, Ranchi  
Jharkhand, India

**Dr. Ankur Ojha**  
Junior Resident Academic,  
Department of Orthopaedics,  
RIMS, Ranchi Jharkhand, India

**Dr. LB Manjhi**  
Professor, Head of Department,  
Department of Orthopaedics,  
RIMS, Ranchi Jharkhand, India

### Functional outcome of surgical management of fracture both bones forearm in adults using LC-DCP

**Dr. Ravijeet Prakash, Dr. Shashi Kant Kumar Singh, Dr. Ankur Ojha  
and Dr. LB Manjhi**

DOI: <https://doi.org/10.22271/ortho.2018.v4.i4a.06>

#### Abstract

**Background:** Forearm bone fractures are commonly encountered in today's industrial era due to road traffic accidents, contact athletic participation and falls from a height. Treatment by closed reduction and cast immobilization risks a poor functional outcome with unsatisfactory results reported in up to 92% of cases, usually caused by malunion, nonunion, or synostosis. Open reduction and internal fixation with plating is generally accepted as the best method of treatment for displaced diaphyseal fractures of the forearm in the adult. This study will be conducted to analyze diaphyseal fractures of the forearm treated with limited contact dynamic compression plate and will document their clinical and functional outcome.

**Materials and Methods:** A prospective, non-controlled, non-randomized, non-blinded observational study, on patients with diaphyseal fractures of both bone forearm admitted in Department of Orthopaedics, RIMS, Ranchi during two years time interval (from 1<sup>st</sup> October 2015 to 30<sup>th</sup> September 2017) in the age group of 19 to 70 years with a mean age of 36.29 years was conducted. 53 Patients were selected for the study from those presenting to our hospital. The outcome was assessed based the disabilities of arm; shoulder and hand (DASH) score.

**Results:** Results were analysed according to disabilities of arm; shoulder and hand (DASH) score. Excellent functional outcome result in 40 patients (80%), satisfactory in 5 patients (10%) while remaining had fair to poor outcome. Mean final DASH score of 23.99 was recorded among the study group. Maximum number of patients had no complication, complication like superficial infection were reported among few patients. Despite these complication the overall functional result was good; suggesting that open reduction and internal fixation with limited contact dynamic compression plate (LC-DCP) is an effective treatment modality in these fractures.

**Conclusion:** Open reduction and internal fixation with limited contact dynamic compression plate (LC-DCP) is an effective method of treatment for AO type A3, B3 and type C both bone forearm fracture. This implant is particularly helpful in osteoporotic bones.

**Keywords:** Both bone forearm fractures, limited contact dynamic compression plate

#### Introduction

Forearm bone fractures are commonly encountered in today's industrial era due to road traffic accidents, contact athletic participation and falls from a height. The human forearm serves an important role in upper extremity function, facilitating placement of the hand in space, thus helping to provide the upper extremity with its unique mobility. The presence of the proximal and distal radio ulnar joints allows pronation and supination and such movements are important to all of us in the usual activities of daily living. Moreover, the forearm serves as the origin for muscles inserting on the hand. Therefore, fracture involving the bones of the forearm present unique problems not encountered with fractured of other long bones and may significantly affect the function of the upper limb <sup>[1]</sup>.

It is essential to regain length, apposition, axial alignment and normal rotational alignment while treating diaphyseal fractures of the radius and the ulna to gain good range of pronation and supination. The chances for the occurrence of malunion and non-union are greater because of the difficulties in reducing and maintaining the reduction of two parallel bones in the presence of the pronating and supinating muscles, which have angulatory as well as rotatory influences <sup>[2]</sup>.

#### Correspondence

**Dr. Ravijeet Prakash**  
Post diploma DNB, Department  
of Orthopaedics, Tata Main  
Hospital, Jamshedpur  
Jharkhand, India

Conservative treatment of displaced forearm shaft fractures usually results in a poor functional outcome because of the importance of the anatomic relationship of the radius and ulna and the difficulty in obtaining and maintaining an acceptable reduction. Treatment by closed reduction and cast immobilization risks a poor functional outcome with unsatisfactory results reported in up to 92% of cases [2]. Usually caused by malunion, nonunion, or synostosis. Open reduction and internal fixation with plating is generally accepted as the best method of treatment for displaced diaphyseal fractures of the forearm in the adult [3]. Compression techniques have a lower incidence of non-union and are found to hasten rehabilitation, with less joint stiffness [4, 5, 6, 7, 8, 9].

Various types of plates are available for open reduction and internal fixation using plate and screws. The 3.5 mm LC-DCP (Limited contact dynamic compression plate) remains the gold standard for internal fixation of forearm fractures [10]. The LC-DCP has groove within the undersurface (leads to an improvement in the blood supply to the underlying plate bone segment) allows for a small amount of callus formation as well as even distribution of stiffness along the plate, undercut plate holes allow extended tilting of plate screws, uniformly spaced as well as symmetrical plate holes and has a optimal screw effect [11, 12].

This study will be conducted to analyze diaphyseal fractures of the forearm treated with limited contact dynamic compression plate and will document their clinical and functional outcome.

### Materials and methods

A prospective, non-controlled, non-randomized, non-blinded observational study, on patients with diaphyseal fractures of both bone forearm admitted in Department of Orthopaedics, RIMS, Ranchi during two years' time interval (from 1<sup>st</sup> October 2015 to 30<sup>th</sup> September 2017) in the age group of 19 to 70 years with a mean age of 36.29 years was conducted. 53 Patients were selected for the study from those presenting to our hospital.

### Inclusion Criteria

- Age group: patients above 18years
- Gender: Male and female patients.
- Patients with radiologically diagnosed diaphyseal fractures both bone forearm
- AO/OTA type A3, B3, C diaphyseal fractures of forearm
- Patients who are willing to give consent to participate in the study

### Exclusion Criteria

- Children and adolescent patients under 18yrs
- Patients with Undisplaced fractures
- Patients with fractures associated with neurovascular deficits
- Patients not willing for surgery.
- Patients with Open fractures
- Patients with Both bones forearm fracture with compartment syndrome needing fasciotomy

The data was collected with informed consent for the study from patient and their relatives by interview and analyzing records. Radiographs of Forearm both anteroposterior view and lateral view were taken and fractures were classified according to the AO classification. Patients underwent open

reduction and internal fixation with limited contact dynamic compression plate for the sustained fractures under general anaesthesia.

### Surgical technique

All the patients were put supine on the operating table, with the arm on an arm board. Surgery was done under tourniquet control. Painting and draping of part done. Radius was exposed by two approaches depending on the site of fracture – Henry's approach and Thompson's approach, and ulna was exposed by Boyd's approach. By these approaches fracture sites were exposed, fracture ends freshened and reduced with a reduction clamp and secured with 3.5 mm limited contact dynamic compression plate which was fixed with 2.5 mm cortical screws. The tourniquet was let down and haemostasis carefully secured and over a large suction drain the wound was closed in layers. Pressure bandage was applied and limb kept in a cough collar.

Patients were instructed to keep the limb elevated and move their fingers and shoulder joint. Check X-ray in anteroposterior and lateral views were obtained on 1<sup>st</sup> postoperative day. Wound was inspected after 2-3 days postoperatively. After discharge, patients were advised to report for follow up at 13<sup>th</sup> postoperative day for suture removal and then at 6 weeks, 3months and at 6 months. Patients were instructed to carry out physiotherapy in the form of active flexion- extension and pronation-supination without loading.

The final results were assessed 6 months after the procedure. The final results were evaluated using the disabilities of arm; shoulder and hand (DASH) score. DASH is a 30-item questionnaire intended to assess the function and symptoms of persons with disorders of the upper limb [13, 36, 37, 38, 39]. Patients rate their ability to perform 21 physical activities such as opening jars, turning doorknobs and similar activities. The remaining nine items relate to symptoms (six items) and self-image and social life (three items). Each is scored on a five-point Likert scale. The raw score is converted to a global score ranging from 0 to 100. A score of 0 indicates 'no disability', and 100 indicates 'severe disability'. On overall score, the patients are grouped as –EXCELLENT IF SCORE < 20, GOOD IF SCORE 20-39, FAIR IF SCORE 40-60 and POOR IF SCORE >60.

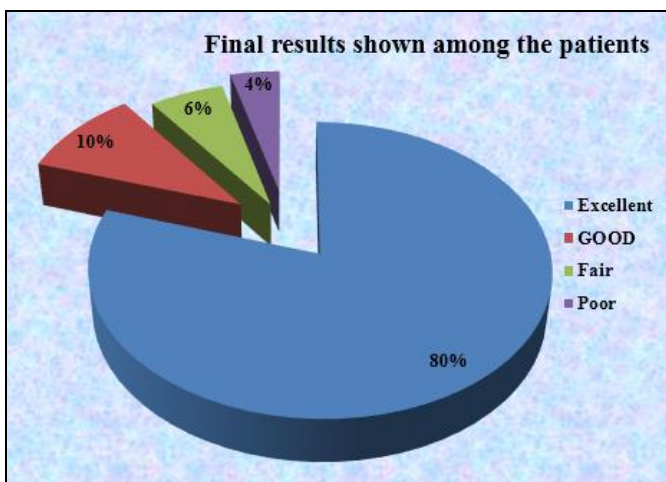
### Results

In this study, 53 cases of fracture both bone forearm of were treated with limited contact dynamic compression plates. The study included patients with age ranging from 19 to 70 years with a mean age of 36.29 years. The fracture incidence is more common in the age group between 31-40 years (20 patients). There were 29 male and 24 female patients. In this study, 77.36% of cases had road traffic accident (high energy) and 22.64% of the cases were due to direct fall (low energy). In our study we have 23 (62.26%) patients whose right forearm is involved and 20 (37.74%) patients whose left forearm is involved Dominant extremity was involved in 35 patients and no dominant in 18. We have more patients (39.3% & 24.5%) with simple fracture pattern, simple wedge pattern (AO TYPE A3 & B3) while patients with AO type C1, C2, C3 were 13.2%, 11.3, 11.3% respectively. Out of 53 patients, 4 had blunt chest trauma which was managed conservatively, 3 had head injury for which CT scan of brain was done and neurosurgical opinion taken which was treated conservatively, 2 patients had ipsilateral # metacarpal, among these two, one was managed conservatively the other with k wire. The mean

injury to operation interval in present study was 3.6 days. Maximum number of patients had no complication, complication like superficial infection were reported among few patients (5.6%). The mean time for union for the forearms fixed with LC-DCP was 13.9 weeks, 40% patients achieved union by 13-14 weeks, 32% had union at more than 14 weeks while remaining 20% patients achieved union at less than 13 weeks. There was excellent functional outcome result in 40 patients (80%), satisfactory in 5 patients (10%) while remaining had fair to poor outcome. The mean ranges of elbow and wrist joint flexion extension was 138 and 144 while and pronation-supination were 60 and 66 respectively

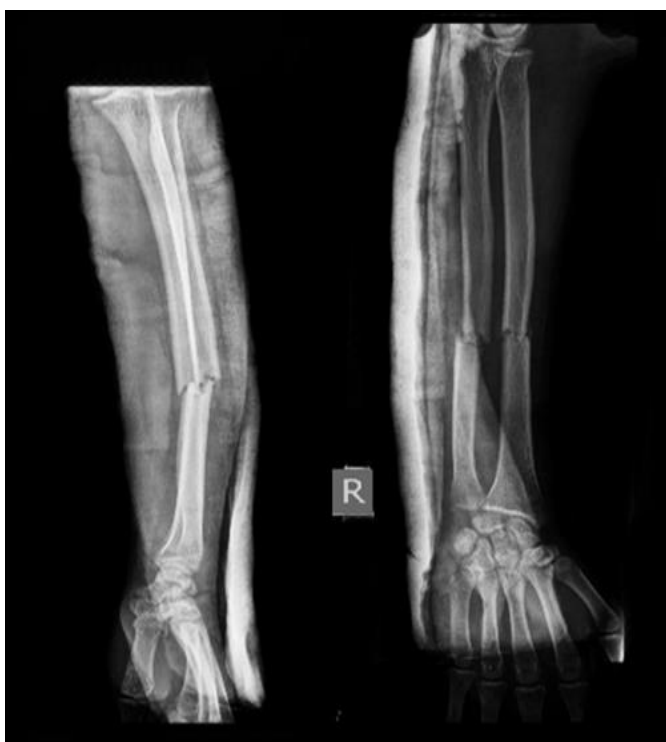**Table 1:** Final results shown among the patients

Overall results	No. of patients	Percentage
Excellent	40	80%
GOOD	5	10%
Fair	3	6%
Poor	2	4%

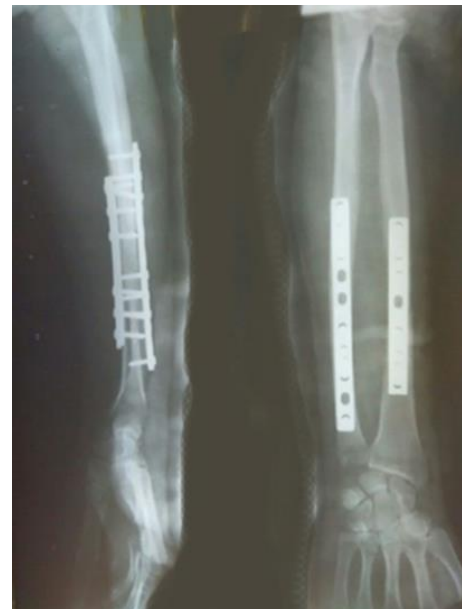

**Graph 1**

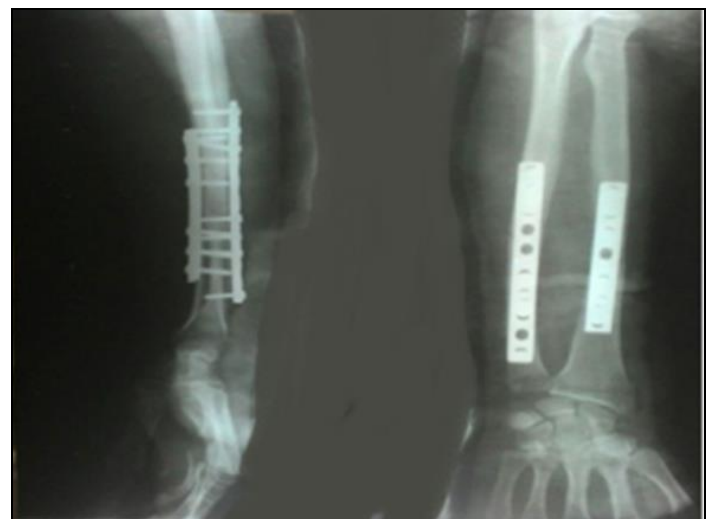**Clinical Photographs**



**Photo 1:** Pre-Operative X Ray



**Photo 2:** Immediate Post-Operative X Ray



**Photo 3:** X-Ray at 6 Months Follow Up

**Discussion**

Fracture bones of forearm are commonly encountered in day-to-day orthopedic practice in our hospital and it presents a formidable challenge to the Orthopaedicians, as the various muscle forces acting upon the fracture tend to displace it. Hence to provide the functional rehabilitation of the upper limb, anatomic reduction and rigid fixation is mandatory.

As reported by Knight and Purvis closed reduction and its maintenance is difficult.<sup>2</sup> Intra medullary nails have got high failure rate. Though there are few advantages like closed nailing, minimal tissue dissection and hospital stay. So, the best option is plating. Different types of plates are available. The dynamic compression plates (DCPs) give good results, but there are few disadvantages. Since these plates interfere with periosteal circulation, osteoporosis and re fracture are very common after plate removal. Much work had not been done on PC-fixators and as reported by Frankie Leung *et al.* they have no added advantage over the LC-DCPs<sup>[3]</sup>.

So, the LC-DCPs are the best implants for diaphyseal fracture of both bones forearm at present. LC-DCPs have got multiple advantages since their interference with the periosteal circulation is less. They give good results. The rate of union is high osteoporosis and re fracture after removal is very low. The present study was undertaken to determine the efficacy of

LC-DCP in the treatment of fractures of both bones of the forearm.

A total of 53 patients of fracture both bones of forearm were treated with open reduction and internal fixation using 3.5 mm LC-DCP. We evaluated our results and compared with those obtained by various other studies utilizing different modalities of treatment.

The higher incidence in male adults in our study could be due to higher exposure to riskier environment and employment in hard labor. The fracture incidence is more common in the age group between 31-40 years (20 patients), which is comparable to previous studies KC Saikia *et al.* [15]. Noted mean age group 30.5 years, Aljo a Matejic *et al.* [16]. Noted 43 yrs, Frankie *et al.* [14].

Noted 36 years. In our study there were nearly same numbers of patients in both the groups (RTA /High energy and Fall/Low energy) with regard to mode of injury. As ours is an industrial hospital and there are many industries surrounding

it, road traffic accidents are more common in this area, which might be related to the fact that in our study we had many patients sustaining injury as a result of it. The results of dominance of extremity involved were comparable with other studies suggesting that the non-dominant extremity was involved more than the dominant one. This may be because in case of assaults the person tries to protect himself/herself with the left limb, also in falls the person may land with the left hand first as he/she would be holding something in the right hand or would use the right hand to hold something. But it is always difficult to determine the exact sequence of events in RTA or fall. However, the results of present study are comparable with the previous studies.

Complications: In the present study, there were few cases of superficial infection (5.6%). They were treated with appropriate antibiotics and the wound healed without any problem.

**Table 2:** Complications

Complication	Anderson [13]	Chapman [17]	Frankie [14]	Hemant HP [22]	Present study
Superficial infection	2.9%	2.5%	2%	6.6%	5.6%
Deep infection	-	-	-	-	0
Radio-ulnar synostosis	1.2%	2.3%	-	-	0
Nonunion	2.9%	2.3%	-	3.3%	0
Nerve injury-PIN	2%	1.5%	3%	3.3%	0

In present study the mean time for union for the forearms fixed with LC-DCP was 13.9 weeks

**Table 3:** Mean union time: Comparison with other studies

Study	Average time for union
Manjappa CN <i>et al.</i> [20]	17 week
Saikia <i>et al.</i> [15]	16 week
Meena <i>et al.</i> [19]	16 week
Sharma S <i>et al.</i> [21]	12 week
Present study	14 week

Our study included 53 patients, which are divided into two age groups (<40 & ≥40 years). The final DASH is compared between these two groups. It is seen that the group with patient's age less than 40 years have a lower mean DASH score as compared to the group with patient's age more than 40 years. Mean final DASH score of 23.99 was recorded among the study group. There was statistically significant differences between the two age groups with respect to final DASH ( $p < 0.05$ ).

#### The reason for this could be

1. Younger patient had good compliance for follow-up.
2. Follow proper physiotherapy.

**Table 4:** Functional outcome Comparison with other studies

Study	Excellent (%)	Satisfactory/Good (%)	Unsatisfactory/Fair (%)	Failure/Poor (%)
Meena <i>et al.</i> [18]	80	15	5	0
Saikia KC [15]	89	8	3	0
Marya KM [23]	88	7	4	1
Frankie [14]	98	2	-	-
Present study	80	10	6	4

#### Conclusion

The present study was conducted to assess the functional outcome of fifty three cases of both bone forearm fracture managed with limited contact dynamic compression plate (LC-DCP). We conclude the following from our study—Open reduction and internal fixation with limited contact dynamic compression plate (LC-DCP) is an effective method of treatment for AO type A3, B3 and type C both bone forearm

#### 3. Cooperative patients.

The mean ranges of elbow and wrist joint flexion extension was 138 and 144 while and pronation–supination were 60 and 66 respectively. Our results are comparable with study conducted by Saikia *et al.* Similar study conducted by Prakash S *et al* had 70% patients with nil to 15° loss of elbow, wrist flexion–extension and supination and pronation movements. In present study patients in <40 years age group had good range of motion as compared to patients above 40 years. Reason could be:

1. Reduction in muscle strength.
2. Associated arthritic changes in bones

All the cases were followed up as per protocol and findings were recorded. Results were analysed according to Disability arm, shoulder and hand score [9, 45]. Excellent results were achieved in 40 (80%), good results in 5 (10%), fair results in 3 (6%) and poor result in 2(4%) of the cases. Similar results shown by Saikia KC *et al*, Marya KM *et al*, Meena *et al*.

fracture. Stable fixation allows early, active and aggressive postoperative mobilisation. This implant yields excellent or good results in majority of patients, even in C3 fractures because of improved biomechanics. Even in elderly patients it should be considered the treatment of choice. The rate of implant failure is remarkably low. Both bone forearm fracture demands careful evaluation, classification of fracture type and through preoperative planning. Henry's and Boyd's approach

provides adequate visualisation of fracture site and. Open reduction internal fixation should be done as early as possible. During open reduction internal fixation, fracture reduction should be given primary importance. Vigorous, early, active rehabilitation is a must for good results. Residual pain is not uncommon, and patients should be informed about this. Patient counselling is paramount.

## References

- Moore KL, Dalley AF, Agur AMR. Clinically oriented Anatomy. 6th Ed. Philadelphia: Lippincott William and Wilkins; Crenshaw AH, Perez FA, Fractures of the shoulder, arm and forearm, 2010.
- Knight RA, Purvis GD. Fractures of both bone forearm in Adults. J Bone Joint Surg. Am. 1949; 31:755-64.
- Leung F, Chow SP. Locking compression plate in the treatment of forearm fractures: A prospective study. J Orthop Surg (Hong Kong). 2006; 14:291-4.
- Chapman MW, Gorden JE, Zissimos AG. Compression plate fixation of acute fractures of the diaphyses of the radius and ulna. J Bone Joint Surg. Am. 1989; 71:159-69.
- Hertel R, Pisan M, Lambert S, Ballmer FT. Plate osteosynthesis of diaphyseal fracture of the radius and ulna. Injury. 1996; 27:545-8.
- Hadden WA, Reschauer R, Seggl W. Results of AO plate fixation of forearm shaft fractures in adults. Injury. 1983; 15:44-52.
- Lloyd GJ, Wright TA. Self-compressing implants in the management of fracture. Can Med Assoc J. 1977; 116:626-8.
- Grace TG, Eversmann WW. Jr Forearm fractures: Treatment by rigid fixation with early motion. J Bone Joint Surg Am. 1980; 62:433-8.
- Goldfarb CA, Ricci WM, Tull F, Ray D, Borelli J. Jr Functional outcome after fracture of both bones of the forearm. J Bone Joint Surg Br. 2005; 87:374-9.
- Kotwal PP. Fractures of the Radius and Ulna. In: Kulkarni GS (Ed.); Textbook of orthopaedics and Trauma, 2nd Ed. New Delhi: Jay pee, 1967-2008.
- Gustilo RB, Mendoza RM, Williams DN. Problems in the management of type (III) (Severe) open fractures: a new classification of type (III) open fracture. J Trauma. 1984; 24:742.
- Perreo SM. The concept of biological plating using the Limited contact dynamic compression plate (LC-DCP). Scientific background, design and application: Injury 1991; 22:1-41.
- Anderson LD, Sisk D, Tooms RE, Park WI 3rd. Compression-plate fixation in acute diaphyseal fractures of the radius and ulna. J Bone Joint Surg. 1975; 57A:287-297.
- Leung, Frankie, Shew-Ping Chow. A prospective, randomized trial comparing the LC-DCP with the point contact fixator for forearm fractures. JBJS. 2003; 85A(12):2343-48.
- Saikia KC, Bhuyan SK, Bhattacharya, Borgohain M, Jitesh P, Ahmed F. Internal fixation of fractures of both bones forearm: Comparison of locked compression and limited contact dynamic compression plate. Indian J Orthop. 2011; 45:417-21
- Aljo A Matejcic, Milhovil Ivica, Mladen Tomljenovic. Forearm shaft fractures: results of ten- year follow-up. Acta clin Croat. 2000; 39:147-53.
- Chapman Michael W, *et al.* Compression plate fixation of acute fractures of the diaphysis of forearm. J Bone & Joint Surg. 1989; 68(7):1008-16.
- Meena RA. Prospective study comparing locking compression plate with limited contact dynamic compression plate for the treatment of adult diaphyseal both bone forearm fractures. IOSR Journal of Dental and Medical Sciences. 2013; 3(6):38-43.
- Prakash S, Basanthi B. Study of Rate of Union of Fracture Forearm Bones by Open Reduction and LC-DCP Fixation. Indian Journal of Public Health Research & Development. 2015; 6(2):31.
- Manjappa CN, Naveen, Vijay C, Mahendra KL. Surgical management of forearm bone fractures in adult using limited contact dynamic compression plate. Journal of Health Sciences and Research. 2011; 2(3):23-26.
- Sharma S, Dang H, Sharma V, Sharma S. Treatment of diaphyseal forearm by locking compression plate (LCP). The internet JOURNAL of Orthopaedic Surgery. 2009; 11:1.
- Hemanth HP. A Prospective Study of Clinical and Radiological Outcome in Fracture Both Bone Forearm in Adults Operated With Dynamic Compression Plate. IOSR Journal of Dental and Medical Sciences. 2016; 15(6)01-07.
- Marya KM, Devgan A, Siwach RC, Yadav V. Limited contact dynamic compression plate for adult forearm fracture. Hong Kong Journal of orthopaedic Surgery. 2003; 7(1):19-24.