



ISSN: 2395-1958  
IJOS 2018; 4(3): 408-413  
© 2018 IJOS  
www.orthopaper.com  
Received: 13-05-2018  
Accepted: 15-06-2018

**Apser Khan**  
Assistant Professor, Department  
of Orthopaedics, SRMS IMS,  
Bareilly, Uttar Pradesh, India

**Syed Ifthekar**  
Assistant Professor, Department  
of Orthopaedics, SRMS IMS,  
Bareilly, Uttar Pradesh, India

## Evaluation of functional outcome of high tibial osteotomy in medial compartment osteoarthritis of knee fixed with orthofix and puddu plate: A comparative study

**Apser Khan and Syed Ifthekar**

DOI: <https://doi.org/10.22271/ortho.2018.v4.i3h.72>

### Abstract

**Introduction:** Osteoarthritis of knee joint is the most common form of arthritis, affecting a huge population of about 237 million (3.3% of the population). Among those over 60 years old, about 10% of males and 18% of females are affected. Medial compartment is a common disease, caused by additional force on the medial compartment as a result of varus malalignment. The high tibial osteotomy (HTO) is one possibility for the treatment of varus gonarthrosis. Especially for younger and active patients this method can produce long-term relief, which often significantly delays the need for knee arthroplasty. Various techniques for valgus HTOs are described. High tibial osteotomy (HTO) is a widely performed procedure to treat medial knee arthrosis.

**Materials and Methods:** This was a prospective study of 30 patients in the age group between 50 years and 70 years of medial compartment osteoarthritis of knee joint treated by opening wedge osteotomy fixed with orthofix and puddu plate. The study was conducted in the Department of Orthopaedics, SRMS IMS, Bareilly in between September 2016 to march 2018. Patients were randomly allocated in two groups by a computer generated selection system. Their functional results were analysed using knee society score.

**Results:** Statistical analysis was performed to compare the demographic characteristics between two groups. The groups were compared with regards to age and sex, grade of osteoarthritis, time of consolidation and functional outcome. Majority of patients were males accounting to 73.33% (n=22). Mean age of patients was 61.5 years. Minimum age in this series was 52 years and maximum age in this series was 70 years. An unilateral Osteotomy was done in a single setting even when bilateral procedures were required. In our study bilateral osteotomy was done in 12 (40%) patients out of 30 patients. 18 Patients were treated unilaterally (60%). Among unilaterally treated patients majority of these were treated on right knee.

**Conclusion:** Shorter follow-up period is the main shortcoming of our study. However, early results obtained indicate that medial open-wedge osteotomies in medial compartment osteoarthritis of knee fixed using Puudu plates and ortho fix could be done safely and effectively with considerable success with encouraging outcomes, and this technique could be a good alternative for unicompartmental total knee arthroplasty.

**Keywords:** High tibial osteotomy, Orthofix, Puudu Plate, kelling Lawrence classification, Knee society score

### Introduction

Osteoarthritis of knee joint is the most common form of arthritis, affecting a huge population of about 237 million (3.3% of the population) <sup>[1, 2]</sup>. Among those over 60 years old, about 10% of males and 18% of females are affected <sup>[3]</sup>. Medial compartment osteoarthritis of knee is a common disease, caused by additional force on the medial compartment as a result of varus malalignment. Deformity increases the risk of progression of osteoarthritis of the knee <sup>[4]</sup>. A study described that, a varus axis of 6° in one-leg position, leads to a strain on the medial compartment of 95% of the total weight. By shifting the mechanical axis laterally the medial compartment is relieved <sup>[5]</sup>. The high tibial osteotomy (HTO) is one possibility for the treatment of varus gonarthrosis. Especially for younger and active patients this method can produce long-term relief, which often significantly delays the need for knee arthroplasty.

**Correspondence**  
**Syed Ifthekar**  
Assistant Professor, Department  
of Orthopaedics, SRMS IMS,  
Bareilly, Uttar Pradesh, India

Various techniques for valgus HTOs are described. High tibial osteotomy (HTO) is a widely and commonly performed procedure to treat medial knee arthrosis. Many techniques have been developed (i.e. closing wedge, opening wedge, dome and chevron osteotomies), but opening (medial) and closing (lateral) wedge osteotomies are the most commonly used [6, 7]. In 1965, Coventry described the closed wedge technique (CWO) for HTO. One advantage of this technique is an accelerated healing process of the bone due to the positioning of the osteotomy in the metaphysis. The position is above the tibial tubercle, which means a good compression of the osteotomy, caused by the traction of the patellar tendon and the quadriceps muscle is achieved. The goal of the treatment is to relieve medial compartment knee pain and slow down the arthritic progression. This is achieved by a partial unloading of the medial compartment with a slight overcorrection of the mechanical axis (from 6 to 10° of valgus) [8]. Although overall HTO results show the effectiveness of the procedure [9], there are still some debated issues about osteotomies. The issues include the choice between opening or closing wedge tibial osteotomy, the graft selection in opening wedge osteotomies, the type of fixation, the comparison with unicompartmental knee arthroplasty (UKA) and whether HTO affects a subsequent total joint replacement (TKR) [6].

### Material and Methods

This was a prospective study of 30 patients in the age group between 50 years and 70 years of medial compartment osteoarthritis of knee joint treated by opening wedge osteotomy fixed with orthofix and puddu plate. The study was conducted in the Department of Orthopaedics, SRMS IMS, Bareilly in between September 2016 to march 2018. Patients were randomly allocated in two groups by a computer generated selection system. Their functional results were analysed using knee socety score.

Patients with osteoarthritis of knee falling under grade 1, 2 and grade 3 Kellgren Lawrence classification were included in the study. Patients with tri-compartmental osteoarthritis, inflammatory arthritis, markedly decreased range of motion, lateral tibial thrust, severe joint distraction, and those who did not give consent to the study were excluded from the study.

### Kellgren Lawrence Grading system

**Grade 0:** no radiographic features of OA are present

**Grade 1:** doubtful joint space narrowing (JSN) and possible osteophytic lipping

**Grade 2:** definite osteophytes and possible JSN on anteroposterior weight-bearing radiograph.

**Grade 3:** multiple osteophytes, definite JSN, sclerosis, possible bony deformity.

**Grade 4:** large osteophytes, marked JSN, severe sclerosis and definite bony deformity.

**Surgical technique:** After all the preliminary investigations, the patient was taken to Operation Theatre. The patient was mounted supine on the OT table, with the Patella facing the roof. This position was easily attained by keeping a bolster under the ipsilateral hip.

**Orthofix Group:** Under C Arm guidance, a k wire was placed in the proximal tibia as posterior as possible. Once the position was confirmed, a cannulated drill was passed over the k-wire. The anterior pin was placed in respect to the distal pin in a1 and 3 position of the fixator. Ortho fix was slid into

the two proximal pins and the distal pin site was marked. Subsequently distal pins of the fixator were placed and the ortho fix was slid off.

**Osteotomy-** A k wire was passed below the tibial tuberosity aiming towards the tip of the head of the fibula from medial side. A 10mm corticotome was used and posterior cortex corticotomy was done followed by anteromedial cortex. The lateral cortex acts as a hinge during the distraction and correction of varus deformity. Precautions were taken so that the lateral cortex doesn't break. Once osteotomy was completed, the fixator was slid in and fixed. The ball and socket joint tightened and distraction was done to check the effectiveness of osteotomy.

**Puddu plate group:** With the help of pre-operative weight bearing x rays, the existing mechanical axis determined. The target mechanical axis was calculated and thus the correction of the varus required was determined. A general formula of 1 mm wedge for every 10 degrees of correction was used to calculate the thickness of wedge. With the thickness of the wedge determined, under c arm guidance two k wires parallel in antero-posterior direction were passed from medial to lateral in the proximal end of tibia. By using these k wires as reference guide an osteotomy is used to make an osteotomy. With the help of a lamina spreader, calculated thickness of wedge was opened and the wedge was filled with an iliac crest bone graft. The osteotomy was then fixed with puddu plate and 4 screws.

### Observations and Results

The observations of this study series are based on 30 patients treated by orthofix and puddu plate fixation in knee osteoarthritis patients in the department of orthopaedics, SRMS IMS Bareilly in between September 2016 and March 2018. Statistical analysis was performed to compare the demographic characteristics between two groups. The groups were compared with regards to age and sex, grade of osteoarthritis, time of consolidation and functional outcome. Majority of patients were males accounting to 73.33% (n=22). Mean age of patients was 61.5years. Minimum age in this series was 52 years and maximum age in this series was 70 years. In our study Weight bearing in the post-operative period was started on first post-operative day in orthofix group as compared to partial weight bearing in puddu plate group. Full weight bearing was started on an average period of 6 post-operative weeks in puddu plate group. Distraction in orthofix was started on 8th postoperative day. With the calculation of the amount of distraction needed to correct the deformity, distraction was started with 1mm per day in 4 regular intervals. An unilateral Osteotomy was done in a single setting even when bilateral procedures were required. In our study bilateral osteotomy was done in 12 (40%) patients out of 30 patients. 18 Patients were treated unilaterally (60%). Among unilaterally treated patients majority of these were treated on right knee. In Orthofix group, the superficial pin tract infection was seen in 8 patients amounting to 26.7%. No infective complications were seen in puddu plate group. In orthofix group, 2 patients developed recurvatum deformity of proximal tibia due to loosening of proximal ball and socket joint (6%). The mean consolidation time in the puddu plate group was 3.6 months (calculation of consolidation time in puddu plate was started from the day of operation till the day of radiological consolidation) where as the mean consolidation time in the orthofix group was 2.8 months (calculation of consolidation time in orthofix group

was started after stopping distraction). Functional outcome after 6 months in orthofix group was excellent in 11 patients and good in 4 patients where as in puddu plate group the outcome was excellent in 9 patients and good in 6 patients

(according to knee soceity score). Implant removal was done in orthofix group in mean time of 4.2 months and in puddu plate group only 6 patients turned out for implant removal the mean time for plate removal was 3.8 months.

**Table 1:** (Age and sex distribution) Group A: Orthofix group Group B; Puddu Plate group

Age group (years)	No. of Male Patients		No of Female Patients		Total Patients	Percentage (%)
	Group A	Group B	Group A	Group B		
50-59	3	4	2	1	10	33.33%
60-70	7	8	3	2	20	66.66%
Total	10	12	5	3	30	100%

**Table 2:** (Consolidation time)

Consolidation time (in months)	Orthofix Group	Puddu Plate Group
<3 months	10	9
3-6 months	5	6
>6 months	-	-

**Table 3:** (Functional Outcomes) Knee Soceity Score <sup>[10]</sup>

Knee Soceity Score (KSS)	Orthofix Group	Puddu Plate Group
Excellent	11	9
Good	4	6
Fair	-	-
Poor	-	-

Functional outcome score was calculated on the basis of knee soceity score (KSS) which calculated a score based on Pain, Flexion contracture, Extension lag, Total range of flexion, Alignment, Stability (Medio lateral and antero-posterior) and functional score like walking, stair climbing and use of functional aids.

A score of 80-100(excellent), 70-79(good), 60-69(fair), <60 (poor).

### Discussion

High tibial osteotomy has been a widely accepted treatment for medial gonarthrosis for several years. Studies reveal survivorships as well as good and very good results after 10 years in 63–96% of patients <sup>[11, 12, 13]</sup>. According to some studies even after 15 years, 39–57% of the patients did not need further surgery <sup>[14]</sup>. The mean age of the patients in our study was 61.5 years. In a similar study done by Nakamura *et al* the mean age of the patient was 62 years which is very similar to our age group <sup>[15]</sup>. Where as in the study done on 46 patients by Brouwer RW *et al* on 92 patients the mean age was 50.2 years <sup>[16]</sup>. The difference in the age groups with our study might be due to delay in the seeking of treatment in our part of the world. The angle of correction aimed in our both the groups was 8 degrees of valgus at knee. Majority of the patients in our study had excellent functional outcomes with the degree of valgus correction. The functional outcome was according to the knee soceity score. In a study done by Coventry *et al*. they obtained the best results for an angle of correction greater than 8° valgus with a 10-year survivorship of 94% <sup>[12]</sup>. Compared to that there were only 63% of the patients satisfied after 10 years, if the angle of correction was lower than or equal to 5° <sup>[12]</sup>. In another study done by Install *et al*. they described best results if the angle of correction was between 5° and 10° valgus <sup>[17]</sup>. In a study done by We ale *et al*. they did not find any correlation between the score and the correction of the angle at the knee <sup>[18]</sup>. In a study done by Choi *et al*. they discovered an increase of lateral arthrosis after 15 years for 90% of the patients <sup>[19]</sup>. We require long term follow up of our study to document changes in the lateral compartment of the knee joint. However our study did not

have any patients in both the groups with lateral gonarthrosis as a result of the treatment with the modest follow up of two years. In our study group, we did not have any loss of correction in the follow-up period in both the groups. In a study done by Hoell s *et al*. they did not find any loss of correction with a follow up of 22.5 months <sup>[20]</sup>. In a study done by Choi HR *et al*. 92 patients having received an osteotomy using an angular stable plate, no loss of correction was found during a short-term follow-up <sup>[21]</sup>. However Pascher *et al*. discovered equal results regarding a loss of correction after 5.7 years for 61 patients treated with osteotomy for the staple group as well as for the plate group <sup>[22]</sup>. In our study two patients developed patella Baja in puddu plate group and no changes were noticed in install salvati ratio in orthofix group. In a study done by Hoell S *et al*, they did not find a change in install salvati ratio with a follow up of 22.5 months <sup>[20]</sup>. In a study done by Wright *et al*. who treated medial compartment gonarthrosis with open wedge osteotomy, found a patella Baja according to the joint site in all cases <sup>[23]</sup>. These changes in the install salvati ratio in the puddu plate group may be related to the amount of osteotomy correction above tibial tuberosity. This can also be attributed to the amount of bone formed at the level of insertion of the patellar tendon n the tibia. However same was not found in any cases of orthofix group as the osteotomy was done below tibial tuberosity <sup>[24]</sup>. For future total knee arthroplasty, HTO with patella Baja could lead to longer operation time and more complicated access to the lateral compartment <sup>[5, 25]</sup>. Patella infera makes eversion of the patella and access to the lateral compartment more difficult, resulting in the frequent need for procedures such as V-Y quadricepsplasty or resection of the tibial tuberosity <sup>[24]</sup>. We put the patients in our study on early motion with full weight bearing in orthofix group and toe touch weight bearing in puddu plate group. In a study done by Hoell S *et al*, they kept the patient on limited range of motion for 6 weeks with detachable cuffs <sup>[20]</sup>. The complications in our study included superficial pin tract infection and recurvatum deformity in orthofix group which amounted to 20%. These complication rates are comparable to the similar studies done in the literature <sup>[11, 26, 27]</sup>. No patient in

our study required revision for the complications. However in a study done by Hoell S *et al.* one patient required revision. The number being very less can be attributed to chance and no significant derivations can be made out of it. There was no neurovascular deficit during the course of treatment in both the groups of our study. Other studies done in the literature also reported almost no neurovascular deficits. The Advantages and Disadvantages of the two methods used in our study are as follows.

**Orthofix group**

**Advantages**

- 1. Easy technique with relatively less learning curve
- 2. Gradual and better control of correction
- 3. Less chances of patella Baja
- 4. Full weight bearing from second post-operative day

**Disadvantages**

- 1. Patient unfriendly and cumbersome
- 2. Pin tract infections

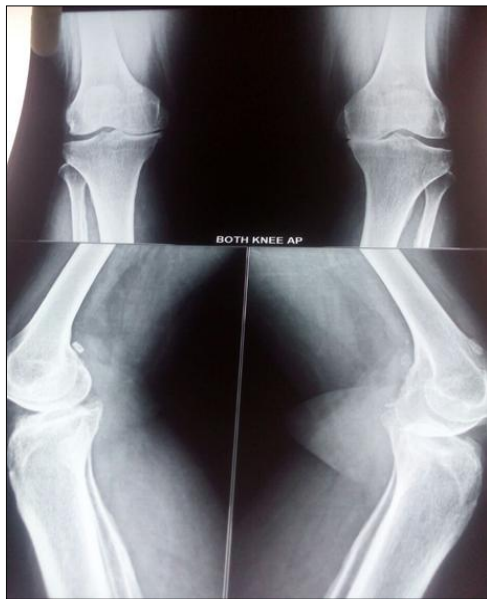**Puddu plate group**

**Advantages**

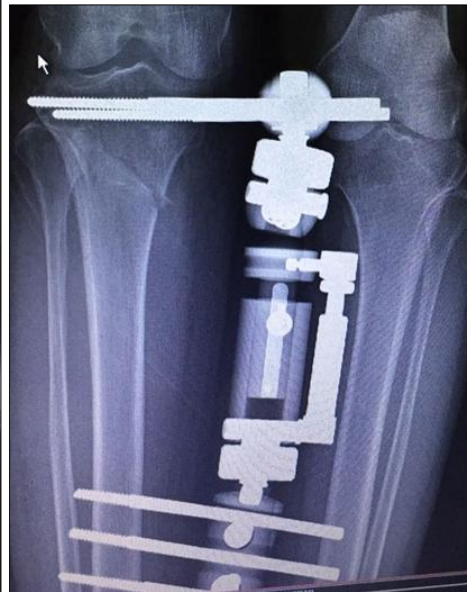- 1. Patient friendly and less cumbersome compared to fixator

**Disadvantages**

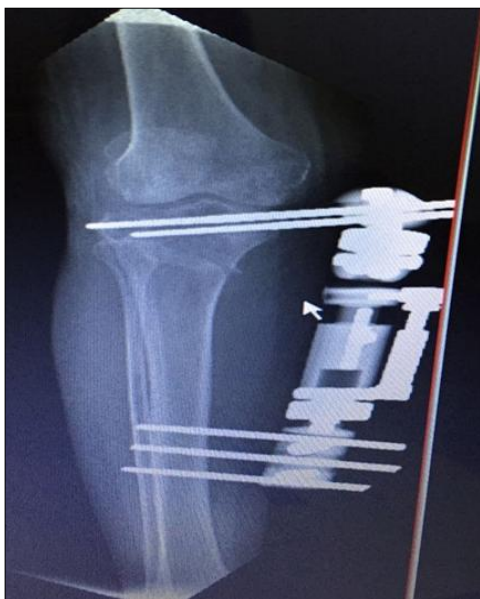- 1. Precise surgical technique required
- 2. Entire correction achieved in a single setting
- 3. Loss of correction
- 4. Patella Baja
- 5. Requirement of bone graft



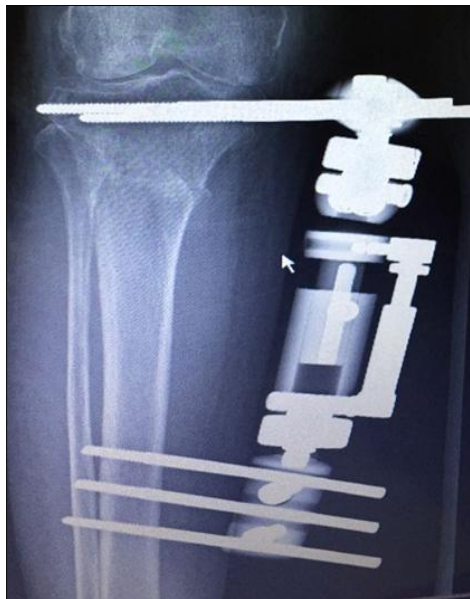Pre-operative



Immediate Post-Operative



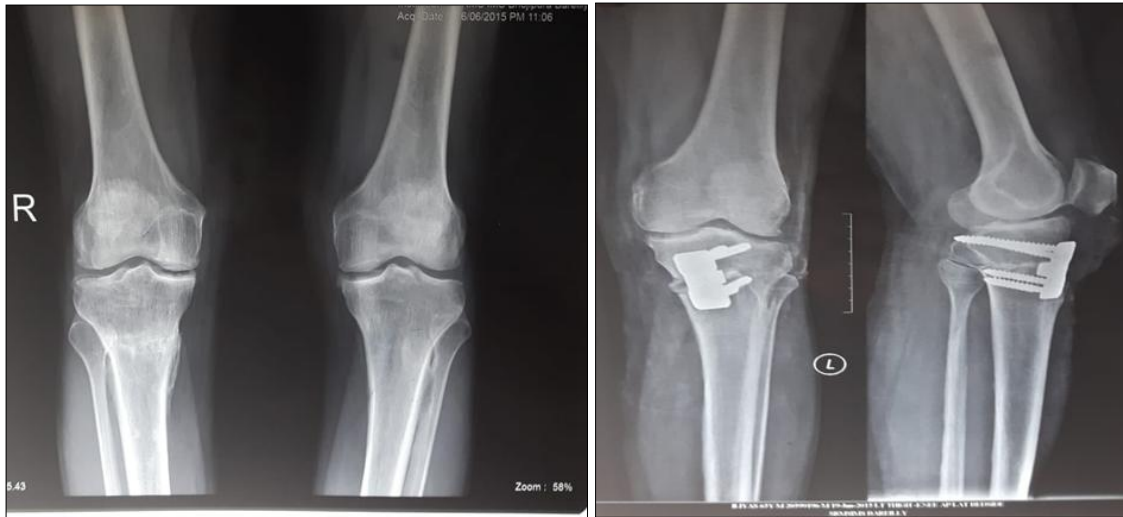6 weeks post-operative



6 Months post-operative

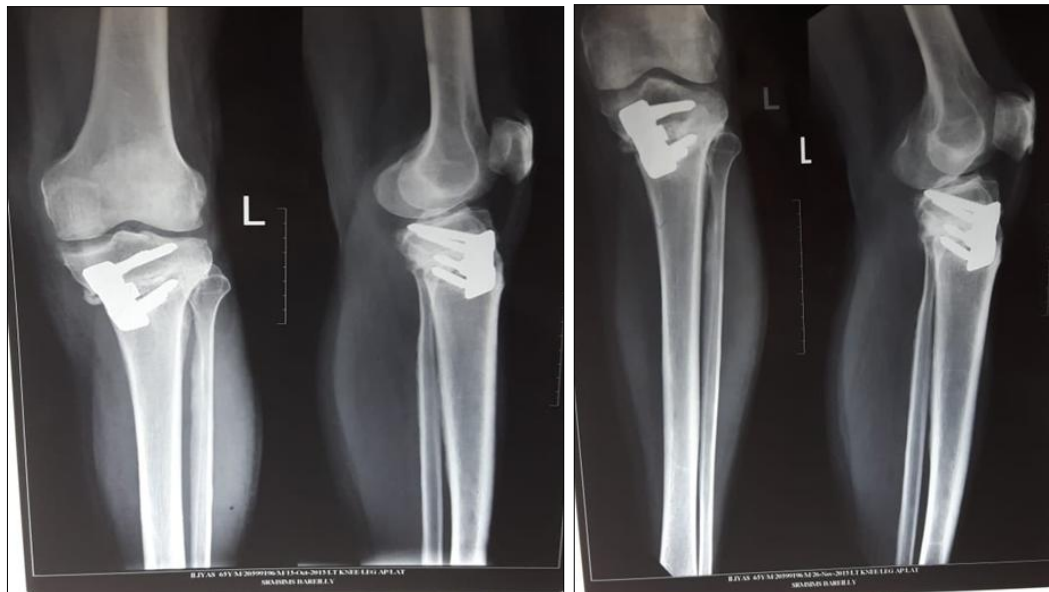
High Tibial Osteotomy Fixed With Orthofix





Pre-operative

Immediate Post-Operative



6 weeks post-operative

6 Months post-operative

High Tibial Osteotomy Fixed With Puudu Plate

**Conclusion**

Shorter follow-up period is the main shortcoming of our study. However, early results obtained indicate that medial open-wedge osteotomies in medial gonarthrosis knee fixed using Puudu plates and ortho fix could be done safely and effectively with considerable success with encouraging outcomes, and this technique could be a good alternative for unicompartmental total knee arthroplasty. We after our evaluation of the study are more comfortable and recommend using Orthofix because of the simplicity of the technique and controlled correction. With a proper patient selection and precise surgical technique, High tibial osteotomy can be a very reliable procedure for the treatment of medial gonarthrosis. Studies with longer follow-up periods and a larger sample size will be required to demonstrate its favorable effects on arthrosis in the long term.

**Ethical Approval:** The study was approved by the institutional ethics committee.

**References**

1. GBD 2015 Disease and Injury Incidence and Prevalence Collaborators (October 2016). Global, regional, and

- national incidence, prevalence, and years lived with disability for 310 diseases and injuries, 1990-2015: a systematic analysis for the Global Burden of Disease Study. *Lancet*. 2015; 388 (10053):1545-1602. Doi: 10.1016/S0140-6736(16)31678-6.
2. March L, Smith EU, Hoy DG, Cross MJ, Sanchez-Riera L, Blyth F *et al*. Burden of disability due to musculoskeletal (MSK) disorders. *Best Practice & Research. Clinical Rheumatology*. 2014; 28 (3):353-66. doi:10.1016/j.berh.2014.08.002.
3. Glyn-Jones S, Palmer AJ, Agricola R, Price AJ, Vincent TL, Weinans H *et al*. Osteoarthritis. *Lancet*. 2015; 386 (9991):376-87. Doi: 10.1016/S0140-6736(14)60802-3.
4. Sharma L, Song J, Felson DT *et al*. The role of knee alignment in disease progression and functional decline in knee osteoarthritis. *JAMA*. 2001; 286:188-95.
5. Haddad FS, Bentley G. Total knee arthroplasty after high tibial osteotomy: a medium-term review. *J Arthroplasty*. 2000; 15(5):597-603.
6. Amendola A, Bonasia DE. Results of HTO in medial OA of the knee. In: Amendola A, Bellemans J, Bonnin M, MacDonald S, Menetrey J (eds) *Surgery of the knee*.

7. Amendola A. Unicompartmental osteoarthritis in the active patient: the role of high tibial osteotomy. *Arthroscopy*. 2003; 19(10):109-116.
8. Shaw JA, Moulton MJ. High tibial osteotomy: an operation based on a spurious mechanical concept. A theoretic treatise. *Am J Orthop*. 1996; 25:429-436.
9. Amendola A, Panarella L. High tibial osteotomy for the treatment of unicompartmental arthritis of the knee. *Orthop Clin North Am*. 2005; 36(4):497-504.
10. Insall JN, Dorr LD, Scott RD, Scott WN. Rationale of the Knee Society clinical rating system. *Clin Orthop relat res*. 1989; 1:248(248):13-4.
11. Aglietti P *et al*. High tibial valgus osteotomy for medial gonarthrosis: a 10- to 21 year study. *J Knee Surg*. 2003; 16(1):21-26.
12. Coventry MB, Ilstrup DM, Wallrichs SL. Proximal tibial osteotomy. A critical long-term study of eighty-seven cases. *J Bone Joint Surg Am*. 1993; 75(2):196-201.
13. Paley D. In: *Principles of Deformity Correction*. Springer Verlag, Berlin Heidelberg New York, 2002.
14. Naudie D *et al*. The Install Award. Survivorship of the high tibial valgus osteotomy. A 10- to -22 year follow-up study. *Clin Orthop*. 1999; (367):18-27.
15. Nakamura E, Mizuta H, Kudo S, Takagi K, Sakamoto K. Open-wedge osteotomy of the proximal tibia with hemicallotasis. *The Journal of bone and joint surgery. British volume*. 2001; 83(8):1111-5.
16. Brouwer RW, Bierma-Zeinstra SM, Van Raaij TM, Verhaar JA. Osteotomy for medial compartment arthritis of the knee using a closing wedge or an opening wedge controlled by a Puudu plate: a one-year randomised, controlled study. *The Journal of bone and joint surgery. British volume*. 2006; 88(11):1454-9.
17. Insall JN, Joseph DM, Msika C. High tibial osteotomy for varus gonarthrosis. A long-term follow-up study. *J Bone Joint Surg Am*. 1984; 66(7):1040-1048.
18. Flamme CH *et al*. Long-term outcome following high tibial osteotomy with tension bend principle. *Arch Orthop Trauma Surg*. 2003; 123(1):12-16.
19. Leutloff D, Tobian F, Perka C. High tibial osteotomy for valgus and varus deformities of the knee. *Int Orthop*. 2001; 25(2):93-96.
20. Hoell S, Suttmoeller J, Stoll V *et al*. *Arch Orthop Trauma Surg*. 2005; 125:638. <https://doi.org/10.1007/s00402-005-0004-6>.
21. Choi HR *et al*. High tibial osteotomy for varus gonarthrosis: a 10- to 24 year follow-up study. *J Orthop Sci*. 2001; 6(6):493-497.
22. Pascher A, Materna W, Windhager R. Analysis of two different techniques of osteosynthesis in high tibial osteotomy. *Z Orthop Ihre Grenzgeb*. 2003; 141(1):37-41.
23. Wright JM *et al*. Observations on patellar height following opening wedge proximal tibial osteotomy. *Am J Knee Surg*. 2001; 14(3):163-173.
24. Windsor RE, Insall JN, Vince KG. Technical considerations of total knee arthroplasty after proximal tibial osteotomy. *J Bone Joint Surg [Am]*. 1988; 70-A:547-55.
25. Meding JB *et al*. Total knee arthroplasty after high tibial osteotomy. *Clin Orthop*. 2000; (375):175-84.
26. Koshino T, Murase T, Saito T. Medial opening-wedge high tibial osteotomy with use of porous hydroxyapatite to treat medial compartment osteoarthritis of the knee. *J Bone Joint Surg Am*. 2003; 85-A:(1):78-85.
27. Staubli AE *et al*. Tomo Fix: a new LCP-concept for open wedge osteotomy of the medial proximal tibia—early results in 92 cases. *Injury*. 2003; 34(2):B55-B62.