



ISSN: 2395-1958
IJOS 2018; 4(3): 380-383
© 2018 IJOS
www.orthopaper.com
Received: 06-05-2018
Accepted: 07-06-2018

J Thiyageswaran
Department of Orthopaedics,
Meenakshi Medical College
Hospital and Research Institute,
Enathur, Kancheepuram,
Tamil Nadu, India

S Sudharsan
Department of Orthopaedics,
Meenakshi Medical College
Hospital and Research Institute,
Enathur, Kancheepuram,
Tamil Nadu, India

K Arul Vignesh
Department of Orthopaedics,
Meenakshi Medical College
Hospital and Research Institute,
Enathur, Kancheepuram,
Tamil Nadu, India

KM Vijay
Department of Orthopaedics,
Meenakshi Medical College
Hospital and Research Institute,
Enathur, Kancheepuram,
Tamil Nadu, India

Efstathios Chronopoulos
Department of Orthopaedics,
Meenakshi Medical College
Hospital and Research Institute,
Enathur, Kancheepuram,
Tamil Nadu, India

Correspondence
J Thiyageswaran
Department of Orthopaedics,
Meenakshi Medical College
Hospital and Research Institute,
Enathur, Kancheepuram,
Tamil Nadu, India

International Journal of Orthopaedics Sciences

Short term analysis of functional outcome of inter-trochanteric femur fracture treated by PFN-A2

J Thiyageswaran, S Sudharsan, K Arul Vignesh and KM Vijay

DOI: <https://doi.org/10.22271/ortho.2018.v4.i3g.66>

Abstract

Background: Femoral Inter-Trochanteric fracture is one of the most frequently occurring fractures in the elderly, usually following trivial trauma. In the younger age group of people, it occurs almost always due to high velocity trauma.

Objectives: This study aimed to study the functional outcome of operative management of inter-trochanteric fracture treated by PFN-A2. The results have been studied in depth with a view to outline guideline for better management of this fracture.

Material & Methods: A prospective study of 30 cases of intertrochanteric femur fracture treated by PFN-A2, minimum 6 months of follow up. All cases are evaluated according to Modified Harris Hip Score on residual effects on clinical ground at final examination. Pain & functional capacity are the two basic considerations for this scoring system. Points are given for pain, function, range of motion & absence of deformity.

Result: Functional result according to Modified Harris Hip score was found to be excellent in 17(57.33%) patients, good in 8(25.33%) patients, fair in 3(10.3%) patients & poor in 2(7%) patients. poor outcome occurs due to development of complications and old age & medical illness.

Conclusion: Modified Harris Hip Score is good score to evaluate functional outcome of the intertrochanteric fracture treated with PFN-A2. Intertrochanteric fracture treated with PFN-A2 gives Excellent to Good (82.66%) functional results.

Keywords: Intertrochanteric fracture, modified Harris hip score, proximal femoral nail

Introduction

Femoral intertrochanteric fractures ^[1] are one of the most frequently occurring fractures in the elderly, usually following trivial trauma. In the younger age group of people, in whom it is uncommon, it occurs almost always due to high velocity trauma. The ideal internal fixation device should be such that the patient can be mobilized at the earliest without jeopardizing the reduction, stability and union of the fracture.

This thesis is an attempt to study the short term analysis of operative management of intertrochanteric fractures by PFN-A2 in a standardized and objective manner. Factors affecting the quality of fixation and hence patients ambulation have been analyzed. A form of pre-operative assessment and final assessment has been used. The results have been studied in depth with a view to outline guidelines for better management of these fractures.

Intertrochanteric fracture ^[2-3] include:-

- 3-fragment fracture with postero-medial comminution
- Fracture >2 intermediate fragments(lateral wall blow out)
- Reverse oblique fracture
- Transverse oblique fracture
- Intertrochanteric fracture with subtrochanteric extension

Materials and methods

Study area, duration: A prospective, all inclusive, non-controlled, non-randomized, non-blinded study Thiyageswaran J *et al*: Outcome of intertrochanteric fracture of 30 cases of intertrochanteric femur fracture, treated by PFN-A2 was done from January 2015 to December 2017 at Meenakshi Medical College Hospital and Research Institute, Enathur, Kancheepuram, Tamil Nadu, India.

Inclusion criteria

- All unstable types of fracture pattern AO/OTA type 31A2.2 to 31A3.3 [4]
- Age between 18 - 90 years.
- Men and women both included in study.
- Patient undergoing Primary or Index surgery.
- Different mode of injuries i.e. fall from standing height, slippage, road traffic accident, fall from height are included.
- Patients who survives minimum 6 months after operation are included

Exclusion criteria

- Age < 18 years.
- Pathological fractures.
- Previous surgery on proximal femur.
- Patients with intertrochanteric femur fracture treated with other modalities of internal fixation.
- Old non-unions and mal-unions.

Preoperatively

Radiological confirmation of the diagnosis was carried out by taking anterior-posterior x-rays of hip and the fractures were classified according to AO/OTA Classification [4], UNSTABLE varieties include 31A2.2 to 31A3.3.

Intraoperatively

Intertrochanteric fractures were treated by closed reduction on a fracture table and internal fixation using a proximal femoral nail (PFN-A2) [5-6] inserted under radiographic control.

All the fractures were operated using proximal femoral nail (PFN) [7, 8] basic design invented by AO

Post operative regimen

Parenteral antibiotics, usually third generation cephalosporin were started immediately after the admission and postoperatively. Static quadriceps exercises were encouraged from the first day and the knee was mobilized from the third day.

Check x-rays were taken on the same day as soon as patient was stabilized following the surgery.

Simultaneously active hip and knee strengthening exercises are also started. The stitches are removed on 12th post operative day.

Patients were first followed up usually at stitch removal if not already done or at one and a half months after discharge, if stitch removal is already done. Clinical assessment of fracture union, range of movement of hip and knee and radiological assessment of fracture union is done on subsequent follow up. If union is found satisfactory and radiological union is found to be in progress, partial weight bearing is started as tolerated. Patients are next called after another 1&1/2 months and reassessment, both clinical as well as radiological, is done and if union is found to be progressing satisfactorily full weight bearing is started as tolerated. Patients are next called at every 3 months and reassessment, both clinical as well as radiological is done. Functional outcome assessed using Modified Harris Hip Score [9].

Ethical consent: Ethical clearance was taken from the institutional committee

Results**Table 1:** Distribution of cases according to age Age in years No. of patients (% , n=30)

31-40	01(3.3%)
41-50	04(13.33%)
51-60	3(10%)
61-70	12(40.%)
71-80	10(33%)
81-90	04(13.33%)
Total	30(100%)

Table 2: Distribution of cases according to sex No. of patients (% , n=30)

Male	20(65.33%)
Female	10(34.67%)
Total	30(100%)

Table 3: Distribution of cases according to type of fracture (AO/ASIF) Fracture type Number of Patients (% , n=30)

A2.2	16(53.33%)
A2.3	5(16%)
A3.1	2(8%)
A3.2	1(1.33%)
A3.3	6(21.33%)
Total	30(100%)

Table 4: Distribution of cases according to functional results in present study: surgeon's assessment (according to harris hip score) Clinical results Total points No. of Patients (% , n=30)

Excellent	81-100	17(57.33%)
Good	61-80	8(25.33%)
Fair	41-60	03 (10.3%)
Poor	<40	2 (7%)
Total		30 (100%)

Observation & discussion

In current study highest number of patients, 25(33.33%) patients are in 61-70 years age group. A comparative study done by Christian Boldin *et al.* [10] shows highest numbers of patients are in 61-70 years age group.

In this study Male patients slightly predominated with a ratio of Male: Female 1.9:1. AO classification was used in this study; A2.2 was the most common fracture type in 16(53.33%) patients, followed by A3.3, A2.3 & A3.1.

All the patients are followed up closely and at least for 6 months.

All patients were allowed to partial weight bear by 6 weeks of surgery. 18 (60.00%) patients were allowed full weight bearing within 12 weeks after surgery, whereas in 11(34.67%) patients were allowed full weight bearing after 12 weeks of surgery. These patients were allowed delayed full weight bearing because of old age, having medical illness, psychiatric illness, not following advice properly. 1 patient was not able to walk due to implant failure and infection.

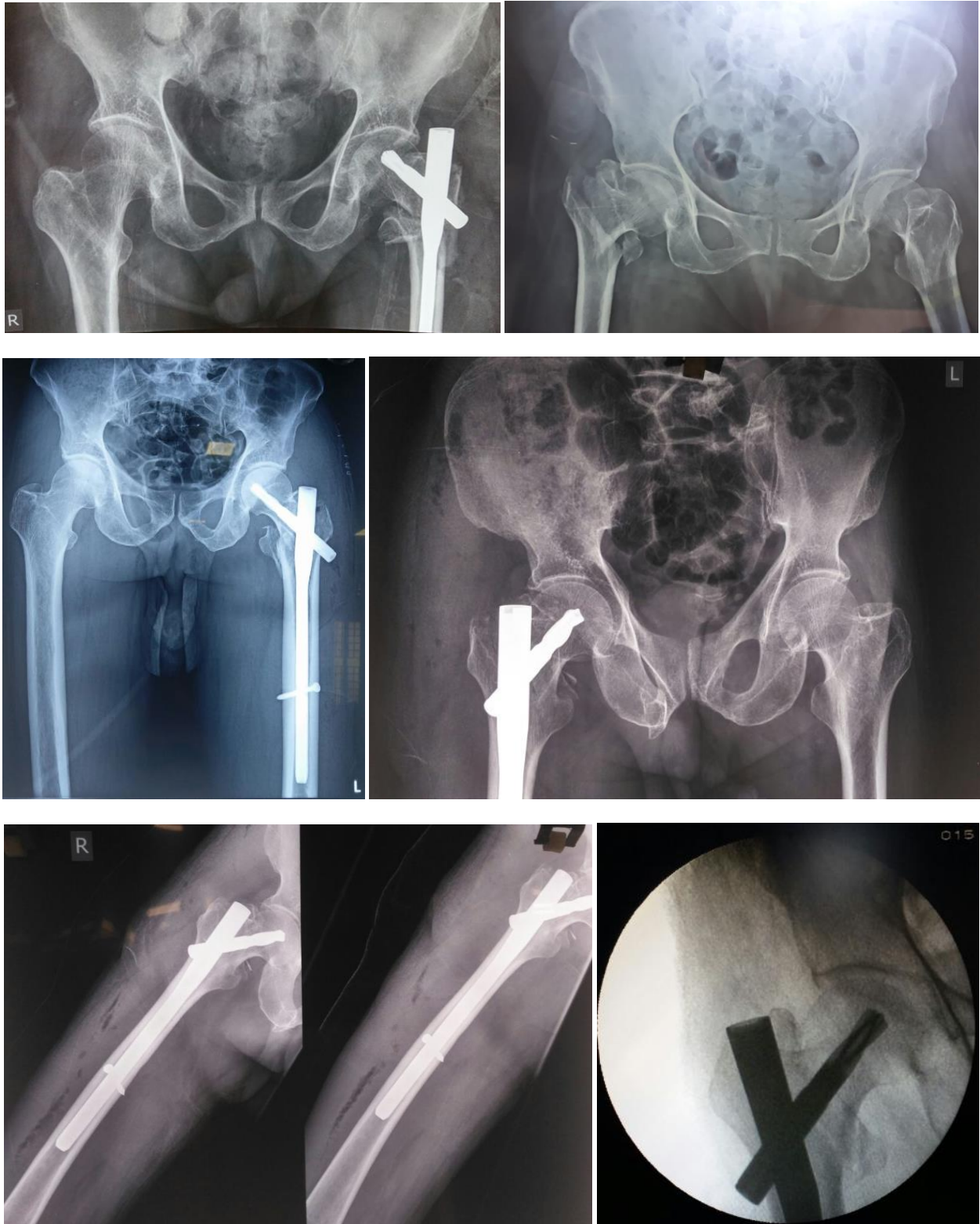
All cases are evaluated according to modified Harris hip score on residual effects on clinical grounds at final examination.

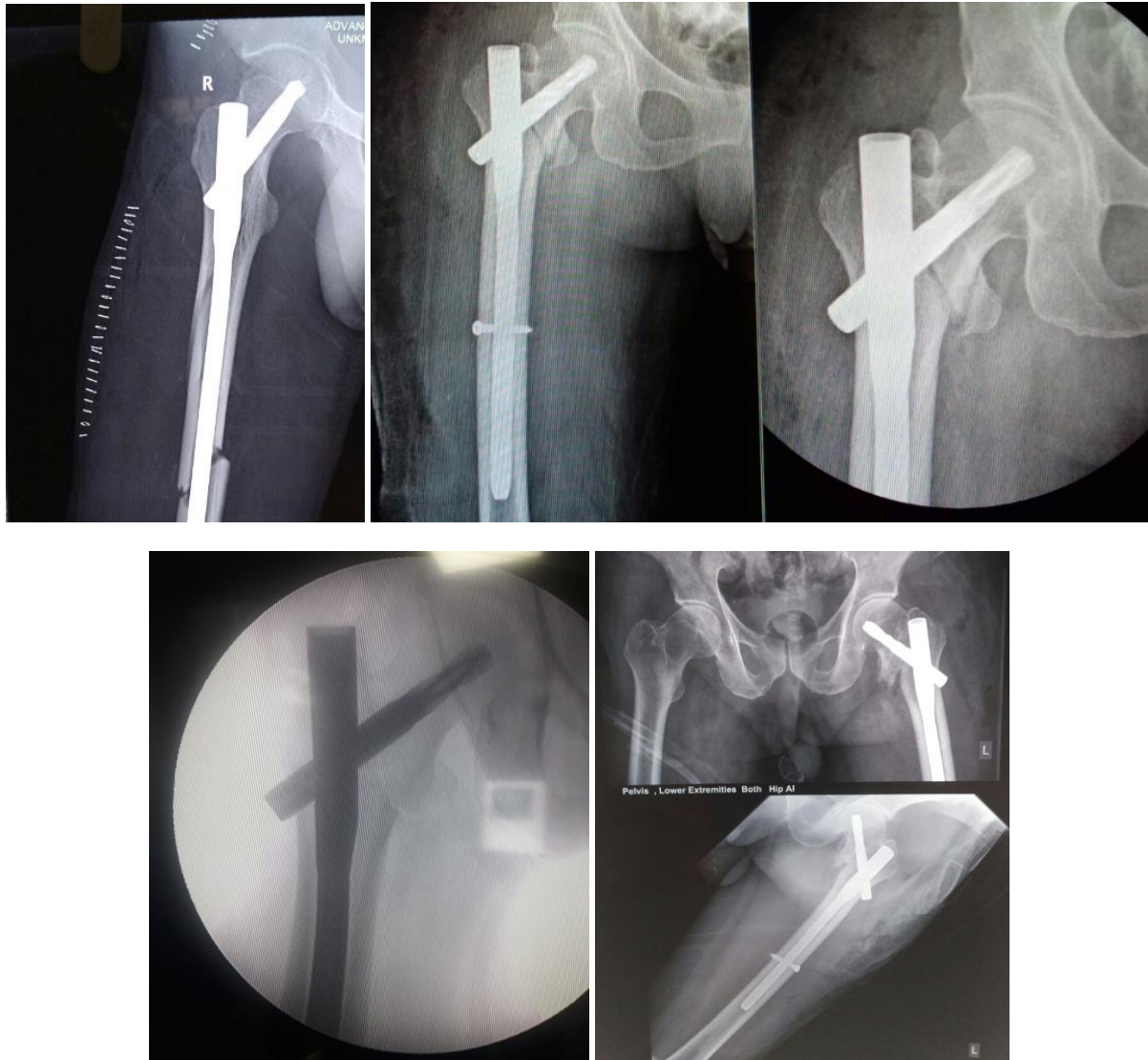Pain and functional capacity are the two basic considerations for this scoring system. Points are given for pain, function, range of motion and absence of deformity.

Based on all the above criteria the functional result according to Modified Harris Hip Score was found to be excellent in 17(57.33%) patients, good in 08(25.33%) patients, fair in 3(10.3%) patients and poor in 2(7%) patients. Poor outcome occurs due to development of complications and old age and

medical illness.

So in this study intertrochanteric fracture treated with PFN-A2 gives modified Harris hip score Excellent to Good in 82.66% patients.





Conclusion

Modified Harris Hip score is good score to evaluate functional outcome of the patients. In conclusion the PFN-A2, is an optimum implant for the internal fixation of intertrochanteric fractures with advantages of stable fixation, early load sharing fixation, early weight bearing and ambulation, shortened hospital stay and improved rate of union with early resumption of independent life style, excellent functional outcome.

References

1. Rockwood & Green's Fractures in Adults, Intertrochanteric fractures. 7th edition. Lippincot Williams and Wilkins; Philadelphia, 2010.
2. Dhiraj VS. Evans – classification of intertrochanteric fractures and their clinical importance. Trauma International. 2015; 1(1):7-11.
3. Tronzo RG. Use of extramedullary guide pin for fractures of the upper end of the femur. Orthop Clin North Am. 1974; 5(3):525-7.
4. Preetesh E, Pattanashetty OB, Dayanand BB, Arravind P, Ullas T. Outcome of intertrochanteric fracture treated with proximal femoral nail. Jotr. 2015; 8(1):25-29.
5. Al-yassari G, Langstaff RJ, Jones JM, Al-Lami M. The AO/ASIF proximal femoral nail (PFN) for the treatment of unstable trochanteric femoral fracture. Injury. 2002; 33:395-9.
6. Anglen JO, Weinstein JN. Nail or plate fixation of intertrochanteric hip fractures: changing pattern of practice. A review of the American Board of Orthopedic Surgery Database. J Bone Joint Surg Am. 2008; 90-A:700-7.
7. Banan H, Al-Sabti A, Jimulia T, Hart Af. The treatment of unstable, extracapsular hip fractures with the AO/ASIF proximal femoral nail (PFN)-our first 60 cases. Injury. 2002; 33:401-5.
8. Saudan M, Ltibbeke A, Sadowski C, Riand N, Stern R, Hoffmeyer P. Intertrochanteric fracture fractures: is there an advantage to an Intramedullary Nail? A randomized, prospective study of 206 patients comparing the dynamic hip screw and proximal femoral nail, J Orthop Trauma. 2002; 16:386-393.
9. Omar AB, Kharma C. Foucher. Harris Hip Score; Clin orthop Relat res. 2014; 472(11):3452-3461.
10. Boldin C, Seibert FJ, Fankhauser F, Peicha G, Grechenig W, Szyzkowitz R. The proximal femoral nail (PFN)-a minimal invasive treatment of unstable proximal femoral fractures: a prospective study of 55 patients with a follow-up of 15 months. Acta Orthop Scand. 2003; 74(1):53-8.
11. Schipper B, Steyerberg EW, Castelein RM, van der Heijden FHWM, den Hoed PT, Kerver JH *et al.* Treatment of unstable trochanteric fractures randomised comparison of the gamma nail and the proximal femoral nail. J Bone Joint Surg Br. 2004; 86(1):86-94.