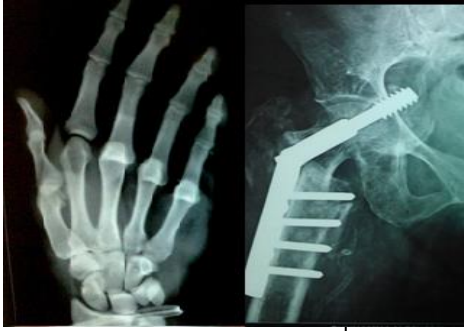

# International Journal of Orthopaedics Sciences

ISSN: 2395-1958  
IJOS 2018; 4(3): 395-397  
© 2018 IJOS  
www.orthopaper.com  
Received: 10-05-2018  
Accepted: 11-06-2018

**Mazharuddin Ali Khan**  
Professor and Head of the  
Department, Department of  
Orthopaedics, Deccan College of  
Medical Sciences, Hyderabad,  
Telangana, India

**Narender Reddy J**  
Post-Graduate, Department of  
Orthopaedics, Deccan College of  
Medical Sciences, Hyderabad,  
Telangana, India

**Mohammad Nomaan Abdul  
Waheed**  
Post-Graduate, Department of  
Orthopaedics, Deccan College of  
Medical Sciences, Hyderabad,  
Telangana, India

**Correspondence**  
**Mazharuddin Ali Khan**  
Professor and Head of the  
Department, Department of  
Orthopaedics, Deccan College of  
Medical Sciences, Hyderabad,  
Telangana, India

## A rare case report of bilateral dupuytren's contracture of hand

**Mazharuddin Ali Khan, Narender Reddy J and Mohammad Nomaan  
Abdul Waheed**

DOI: <https://doi.org/10.22271/ortho.2018.v4.i3g.70>

### Abstract

Dupuytren's contracture (DC) is painless flexion contracture of ulnar side of palm where fingers bend towards palm and cannot be straightened. It is a fibrosing disorder that results in slowly progressive thickening and shortening of the palmar fascia, leading to the debilitating digital contractures. We report the case of a 60-year-old male with bilateral contractures on ulnar side of hands, suggestive of DC.

**Keywords:** Dupuytren's contracture, fibrosing disorder

### Introduction

Dupuytren's disease is a common and disabling fibroproliferative condition of the hand. It tends to strike patients in advancing age, causing progressive digital flexion contracture. Pitting and thickening of the palmar skin are the earliest manifestations of Dupuytren's disease. However, the key to early diagnosis is recognition of the nodule, a firm painless mass fixed to skin and deeper fascia. Classically, a nodule precedes development of a cord. Over time, which may be months or several years, the cord gradually contracts, reeling in the metacarpophalangeal joint and the proximal interphalangeal joint and leading to progressive digital flexion deformity (fig 1). Contracture is a common presenting complaint, although fear of malignancy or embarrassment of a handshake may precipitate the initial consultation. The condition most commonly affects the ring and little fingers, although any digit can be involved. The main consequence is impaired function. Contractures can affect activities at the workplace (manual labour, wearing gloves) and home (washing, dressing), posing a threat to independence. The condition is commonly bilateral and often associated with involvement of other areas of the body, so called ectopic disease-Garrod's knuckle pads (44-54%), plantar fibromatosis (Ledderhose disease, 6-31%), and penile fibromatosis (Peyronie's disease, 2-8%). A diathesis is recognised in Dupuytren's disease and describes disease affecting young white men with a strong family history, bilateral involvement, severe disease, and ectopic manifestations. Recognition of this clinical type is essential, as it carries a more serious prognosis and warrants aggressive follow-up and treatment.

### Epidemiology

Dupuytren's disease typically affects elderly men of northern European descent. Prevalence varies widely according to the selected population, ranging from 2% to 42%.<sup>4</sup> A strong familial component is recognised, and the pattern of inheritance has been suggested to be autosomal dominant with variable penetrance. Men typically present earlier (mean age 55 years) than women (10 years later) and have more severe disease.

### Associations

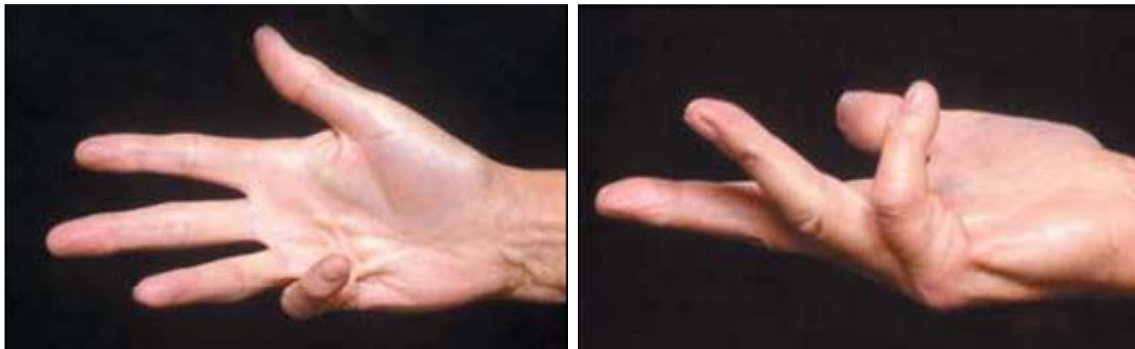
As illustrated below, Dupuytren's disease has many recognised associations. Smoking and excessive alcohol intake are independent risk factors for disease development, and in both cases the relation is dose dependent. Chronic liver disease is not a risk factor independent of alcohol consumption. The condition is more prevalent among people with diabetes, especially those dependent on insulin. Diabetic patients tend to have a milder form of the disease.

Patients with Dupuytren's disease have also been noted to have raised serum lipids compared with controls. Controversy exists as to the significance of either anticonvulsant drugs or epilepsy.

Factors associated with Dupuytren's disease

- Smoking
- Alcohol

- Diabetes mellitus
- Anticonvulsants
- Epilepsy
- Hypercholesterolaemia
- Hand trauma



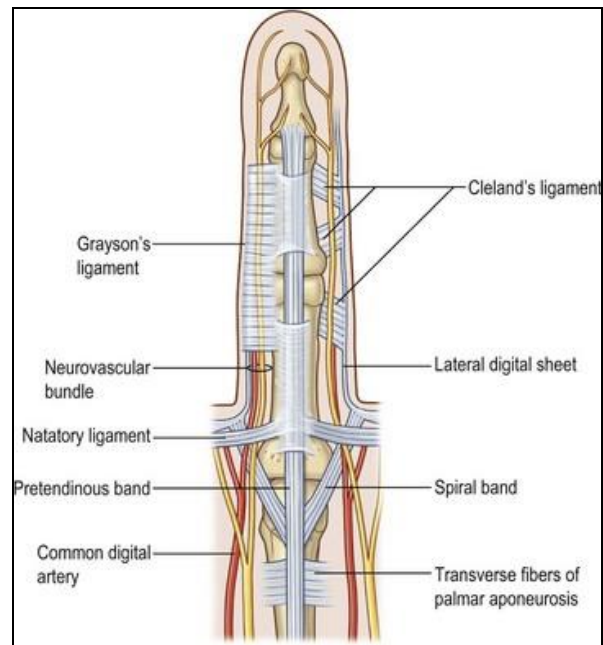
**Fig 1:** Dupuytren's cord, causing metacarpophalangeal and proximal interphalangeal contracture of the little finger

**Pathophysiology**

Although the cause of Dupuytren's disease remains unknown, much has been uncovered about the associated cellular and connective tissue changes. It is classified as a fibroproliferative disorder in a group that includes keloid scars. Fibroblast proliferation is a key feature of early Dupuytren's disease and manifests clinically as the nodule. In these early stages, Dupuytren's disease shares certain properties with malignant tumours and histologically often resembles fibrosarcoma. As the disease progresses, proliferation fizzles out and connective tissue assembles, manifesting clinically as the cord.

**Anatomy**

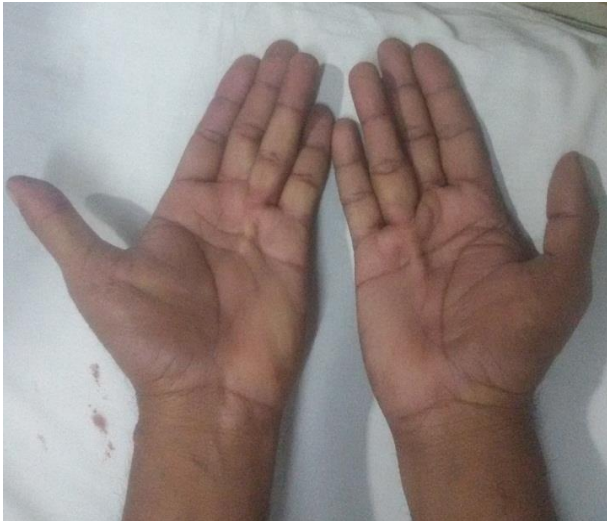An appreciation of the normal anatomy is the key to understanding the deformities of Dupuytren's disease and the surgical basis of their correction. Dupuytren's disease affects the palmar fascial complex, a tough aponeurotic sheet that lies deep to the dermis and superficial to the flexor tendons and small muscles of the hand. It fans outwards from the wrist across the palm, proceeding distally first as the palmo-digital fascia and finally the digital fascia. Within each digit, the fibres of fascia continue longitudinally as the pretendinous band, the spiral band, and the lateral digital sheet (fig 2). As well as protecting deeper structures, notably the neurovascular bundle, the palmar fascia allows conformation of the palmar skin to assist in grasping objects. The clinical presentation of Dupuytren's disease can be explained in terms of a distortion of the normal palmar fascia. Skin pitting is a result of involvement of small vertical fibres (Grapow fibres) that connect the dermis to the palmar fascia. Nodules develop from the superficial fibres of the palmo-digital fascia, adhere to the overlying skin, and usually precede cords. The affected bands of the digital fascia are referred to as cords. Contraction of cords results in predictable deformity as they cross joints- the pretendinous cord causes flexion contracture at the metacarpophalangeal joint; the lateral digital sheet becomes the lateral cord and causes flexion of the proximal interphalangeal joint through its attachment to Grayson's ligament. The spiral cord is responsible for both proximal interphalangeal joint contracture and superficial displacement of the neurovascular bundle, making it more susceptible to accidental division at surgery.



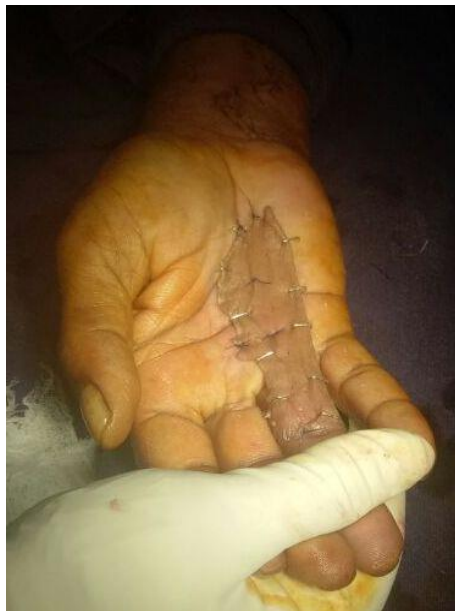**Case presentation**

A 60-year-old male patient presented to the orthopaedic out patient department with deformity of both palms since 8 months. There was no history of trauma. The patient is non smoker and non alcoholic. There is no history of any epilepsy. On examination there is a small cord palpable on both the palms of his hands which is firm in consistency. Contractures of the ring finger of both hands seen with ring finger going in to flexion at metacarpophalangeal and proximal interphalangeal joint. We posted the case for excision of the cord of both palms to treat the flexor contractures. Surgical profile and pre anaesthetic check up done. Patient under General anaesthesia, cords in the palm of both hands excised and shortening of flexor tendon of the ring finger noted. Palmaris longus tendon transfer done to lengthen the flexor tendons and sutured with modified Kessler suture. Skin loss cover been done with split thickness skin graft. Below elbow volar slabs applied with the hand splinted initially in the position of function. Hand physiotherapy is started immediately to prevent stiffness, retain the new range of motion, and restore strength and function. Regular dressing of

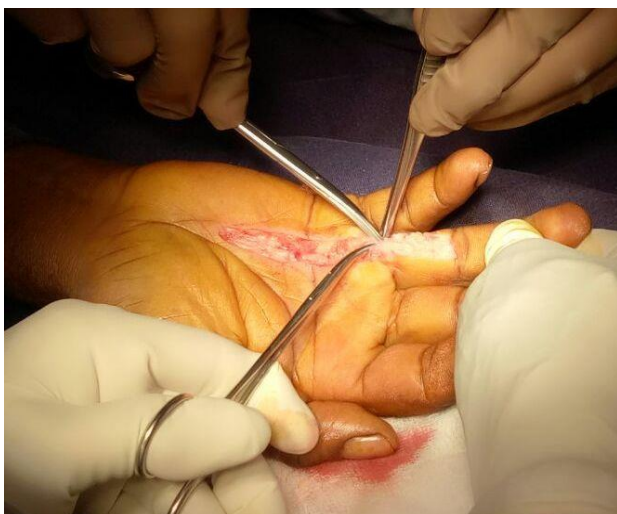the wound was done. Six weeks later slab was removed and rehabilitation continued with physiotherapy after which he was able to carry out his daily routine activities comfortably.



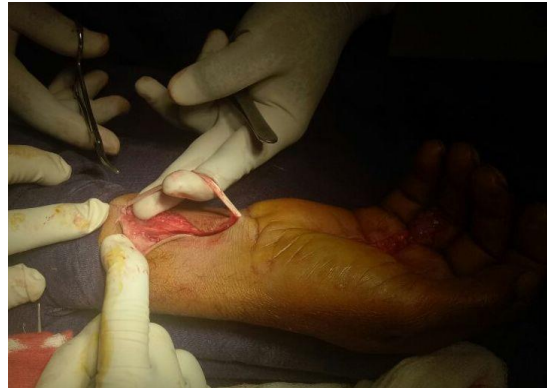1: Clinical picture of patient with bilateral Dupuytren's contracture



4: Split thickness skin grafting after tendon transfer



2. Incision and shortening of flexor tendon of ring finger



3. Palmaris longus tendon transfer and flexor tendon repair

### Discussion

Dupuytren's contracture is a painless flexion contracture of the ulnar side of the palm where the fingers bend towards the palm and cannot be straightened. It is named after the surgeon who described the release procedure for such a contracture. The ring and little fingers are commonly affected, and the incidence increases after the age of 40. There are various theories regarding the etiology of DC, such as genetic, microinjury, immunological, toxic, and ischemic. The condition is a fibrosing disorder that results in slowly progressive thickening and shortening of the palmar fascia, leading to debilitating digital contractures. Clinically, it starts with a nodule on the palmar aspect of the hand, which progresses to form cords along the tendons, and this thickening progresses up to the fingers. There is local fascial fibroplasia and development of a nodule, in which myofibroblasts proliferate and later, leaving acellular tissue and thick bands of collagen. It belongs to the group of plantar fibromatosis (Ledderhose disease), penile fibromatosis (Peyronie disease), and fibromatosis of the dorsal proximal interphalangeal joints. DC is known to recur even after correction. Although many cases appear to be idiopathic and without coexisting conditions, a variety of associated diseases have been reported. Family history, manual labor with vibration exposure, prior hand trauma, alcoholism, smoking, diabetes mellitus, hyperlipidemia, Peyronie disease, and complex regional pain syndrome.

### Conclusion

Bilateral Dupuytren's is a very rare presentation. There are many underlying causes for this condition, but in our case the presentation is idiopathic. We operated on this patient by opening up the palmar surface of both hands and found there was shortening of the flexor tendon of the ring finger. We excised the cord of tissue that was palpable and performed a tendon transfer of the palmaris longus to fill the deficit of the flexor tendons of both hands. Finally, split-thickness skin grafting was taken and covered the palmar exposed area. After rehabilitation, he was able to carry out his daily routine activities comfortably.

### References

1. Van Rijssen AL, Werker PM. Percutaneous needle fasciotomy in Dupuytren's disease. *Hand Surg Br.* 2006; 31(5):498-501.
2. Hindocha S, McGrouther DA, Bayat A. Epidemiological evaluation of Dupuytren's disease incidence and prevalence rates in relation to etiology. *Hand (NY).* 2009; 4(3):256-69.
3. Attali P, Ink O, Pelletier G, Vernier C, Jean F, Moulton L *et al.* Dupuytren's contracture, alcohol consumption and chronic liver disease. *Arch Intern Med.* 1987; 147(6):1065-7.