



International Journal of Orthopaedics Sciences

ISSN: 2395-1958
IJOS 2018; 4(3): 308-313
© 2018 IJOS
www.orthopaper.com
Received: 26-05-2018
Accepted: 27-06-2018

Dr. D Thulasi Raman
Department of Orthopaedics,
Meenakshi Medical College
Hospital and Research Institute,
Enathur, Kancheepuram,
Tamil Nadu, India

Dr. Arul Vignesh
Department of Orthopaedics,
Meenakshi Medical College
Hospital and Research Institute,
Enathur, Kancheepuram,
Tamil Nadu, India

Dr. Siva Swaminathan
Department of Orthopaedics,
Meenakshi Medical College
Hospital and Research Institute,
Enathur, Kancheepuram,
Tamil Nadu, India

Clinico-radiological results of unstable trochanteric fractures treated with custom-made trochanteric stabilisation plate and dynamic hip screw (DHS)

Dr. D Thulasi Raman, Dr. Arul Vignesh and Dr. Siva Swaminathan

DOI: <https://doi.org/10.22271/ortho.2018.v4.i3f.56>

Abstract

Aim: To evaluate the clinico-radiological results of implantation of Custom-made Trochanteric stabilisation plate (TSP) along with Dynamic Hip Screw (DHS) in unstable trochanteric fractures and assess whether it prevents complications such as excessive collapse and femoral medialization.

Materials and Methods: 58 consecutive patients with unstable intertrochanteric fractures (AO CLASSIFICATION) were treated with an additional custom-made TSP superimposed on the regular DHS at our institution between JAN 2012 TO DEC 2015. 9 patients did not turn up for regular follow-up. Thus, 49 patients were followed-up for a period of 6 months. Patients were assessed clinically using Harris His Score and Salvati-Wilson score at each follow-up.

Results: Excessive collapse and medialization of femur were successfully prevented in 49 patients. Clinico-radiological consolidation of fracture was observed at an average of 15.23 weeks in all the cases. The average sliding distance was 7.3 mm. 38 patients had a Harris Hips Score (HHS) of above 90 at the final follow up and the rest had a HHS of above 80. Functional results were excellent in 88 percent of patients and good in the rest 12 percent according to Salvati- Wilson score.

Conclusion: In unstable intertrochanteric fractures with lateral wall comminution, the use of our custom-made TSP along with DHS helps in achieving a stable fixation and prevents complications such as excessive collapse and femoral medialization. Custom-made TSP is easily available and is a cost-effective alternative for anatomical TSP.

Keywords: Clinico-radiological results, unstable trochanteric fractures treated, custom-made trochanteric stabilisation plate, dynamic hip screw

Introduction

The use of Dynamic Hip Screw (DHS) in the treatment of inter-trochanteric fractures has been well documented in literature. DHS works on the principle of controlled collapse and impaction at the fracture site during weight bearing. However, use of this implant in unstable inter-trochanteric fractures has been associated with excessive collapse, femoral medialization and lag screw cut-out^[1, 2]. Inter-trochanteric fractures in which the lateral femoral wall is fractured preoperatively or intra-operatively during triple reaming for DHS, invariably unites in varus while using DHS alone. So providing a buttress for the lateral wall is important to achieve a stable fixation and allow early weight bearing.

The addition of Trochanteric stabilisation plate (TSP) to the DHS can effectively reconstruct the lateral trochanteric wall and help in preventing complications such as excessive collapse and varus malunion. The aim of our study was to assess the effectiveness of custom-made TSP used in conjunction with DHS in unstable inter-trochanteric fractures, in terms of fracture collapse, femoral medialization and functional outcome of the patient.

Materials and Methods

This was a prospective study conducted in LKM Hospital, Erode, India, between the year 2013 and 2015 with a sample size of 58 patients. Patients of all age and gender with unstable inter-trochanteric fractures (AO/OTA 31-A2.2) were included in this study. Patients with fractures extending into subtrochanteric region, open fractures, ipsilateral or contralateral lower limb fractures, patients with psychiatric illness and those with history of previous hip surgery were

Correspondence

Dr. D Thulasi Raman
Department of Orthopaedics,
Meenakshi Medical College
Hospital and Research Institute,
Enathur, Kancheepuram,
Tamil Nadu, India

excluded from the study. A customised TSP was used in this study. A standard 4 holed proximal tibial T-buttruss plate was used for this purpose. The plate was customised by elongating the oval hole (2nd hole from the proximal aspect) proximally (Fig 1a, b).

All patients were operated under spinal or general anaesthesia in supine position on a fracture table. A standard lateral approach was applied to the proximal femur for the DHS implantation. Placement of the guide wire was directed below the centre of the femoral head in the antero-posterior (A-P) view and in the centre or slightly posterior on the lateral view. Triple reaming was done and an appropriate size lag screw was inserted, the 4 holed side plate was fixed with insertion of only the third screw. The customised TSP was superimposed on top of the side plate such that the lag screw is placed on the elongated oval hole. The T-part of the buttress plate was moulded in such a way that it sits on the greater trochanter. In cases where fixation of the greater trochanter was needed, it

was fixed with screws through the buttress plate (Fig. 2) and in some cases only a buttressing was provided to the greater trochanter without any fixation (Fig.3). The hole proximal to the oval hole was used in some cases to insert a 6.5mm partially threaded cancellous screw parallel to the lag screw which can act as a anti-rotation screw providing two-point fixation to the whole construct instead of a normal one-point fixation with a mere DHS and side plate fixation (Fig 4).

Patients were allowed to weight bear as tolerated with a walker under the supervision of a physiotherapist. They were reviewed at 4 weeks, 8 weeks, 12 weeks and 24 weeks. At each review, A-P and lateral radiographs of the involved hip was taken. Radiographic union of the fracture was scored according to Radiographic Union score of the Hip (RUSH score) [3]. At each follow up functional outcome was calculated using Harris Hip Score (HHS) [4] and Salvati-Wilson score [5].



Fig 1a

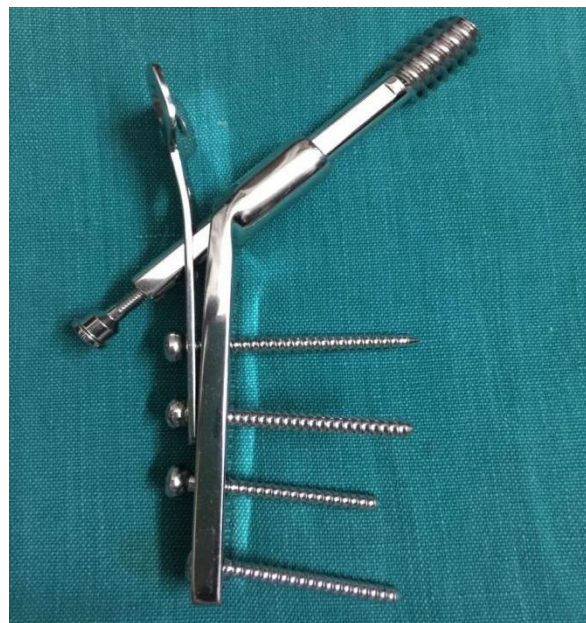

Fig 1b

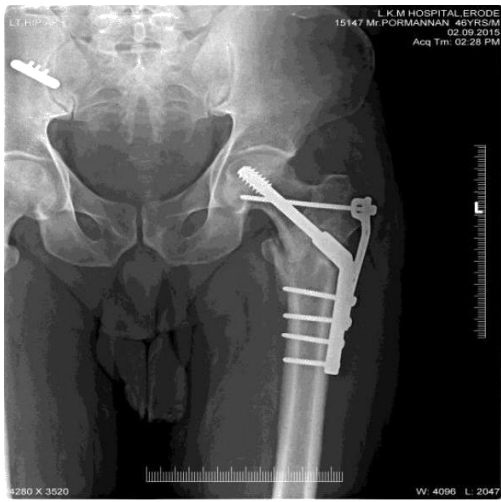

Fig 2

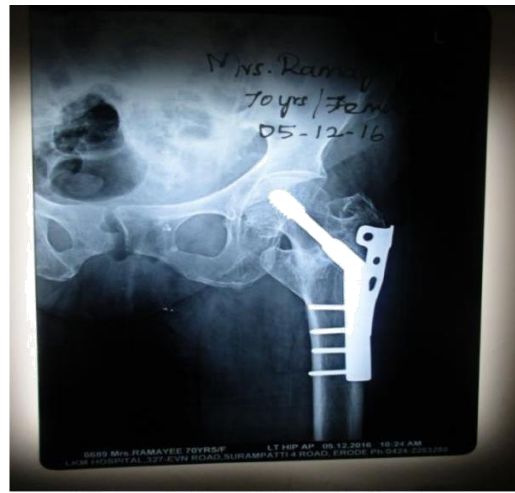

Fig 3

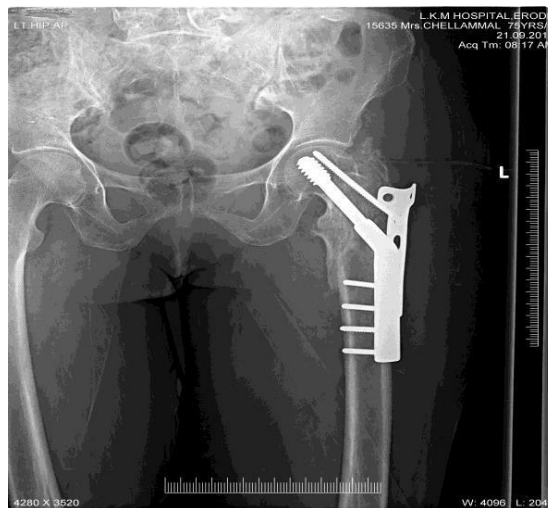

Fig 4

Results

Out of the 58 selected patients, 6 patients did not turn up for regular follow up and 3 patients died before the final follow up. So the remaining 49 cases were analysed in this study.

There were 36 males and 13 females. The average age was 68 years. The most common mode of injury was accidental fall at home (90%) with road traffic accidents being the second most common mode of injury. Out of 49 patients, 26 patients were grouped under AO/OTA 31-A2.1, 15 patients under A2.2 and 8 patients under A2.3. The average follow up for the study was 18 months. The average fracture collapse was 4.8 mm and the time taken for clinic-radiological consolidation of fracture was 15.8 weeks.

There was no lateral displacement of greater trochanter or a medial displacement of the femoral shaft in all the cases. 33 patients were able to walk without any aid at the end of 6.5 months, 16 patients needed a walking aid (a stick in the contralateral hand).

42 patients (86%) had a HHS of > 90 and 7 patients (14%) had a HHS of > 80. 84% of patients had a Salvati-Wilson score of > 30 points. RUSH score was used to calculate the fracture union and all the cases had a score in the range of 20 to 30.

Discussion

Inter-trochanteric fractures of femur are one of the most common fractures of the lower limb in Indian population. Closed reduction or open reduction and internal fixation with

DHS have evolved as one of the standard treatment options in elderly, in order to achieve rigid stabilisation and early mobilisation. However, excessive collapse at the fracture site, medialization of the femoral shaft and lag screw cut off are the complications associated with DHS fixation when used in unstable inter-trochanteric fractures with thin lateral wall. Also, an increased reoperation rates have been reported in patients who had intraoperative or post-operative lateral wall fractures [6]. The importance of lateral wall integrity in inter-trochanteric fractures fixed with DHS was first noted by Parker [7]. In a series of 1039 patients treated with DHS, all the failed cases had uncontrolled medialization of the distal fragment relative to the proximal fragment. He also noted that all of these cases had fracture of the lateral femoral wall at the site of insertion of lag screw. Gotfried [8] found that all his patients with postoperative fracture collapse had fracture of the lateral femoral wall.

As fracture impaction is the key to a good surgical outcome in a DHS fixation, an intact lateral femoral wall is a vital part in achieving stable fixation. When there is a fracture in the lateral femoral wall, the fracture line is parallel to the sliding vector of the DHS and this allows the femoral head and neck fragment to shift laterally and the femoral shaft medially, eventually resulting in implant failure. But when an intramedullary nail is used in fixation of inter-trochanteric fractures, it stops the telescoping displacement of fracture by directly blocking the lateralisation of the head-neck fragment [9].

Trochanteric stabilisation plate (TSP) is a modular extension of the DHS and is mounted on the lateral femoral wall after DHS fixation. In a biomechanical study, TSP has been found to provide extra stability and also resists femoral medialization similar to intramedullary devices when used in conjunction with DHS [10].

Since the new-age TSP's are twice as much expensive as a DHS, we used a custom-made TSP made from a simple modification of the regular T-buttress plate used in fixing proximal tibial fractures. The only modification that was done was the oval hole in the 4- holed buttress plate was elongated proximally to accommodate the lag screw and the 'T' part was bent in such a way that it sits over the greater trochanter.

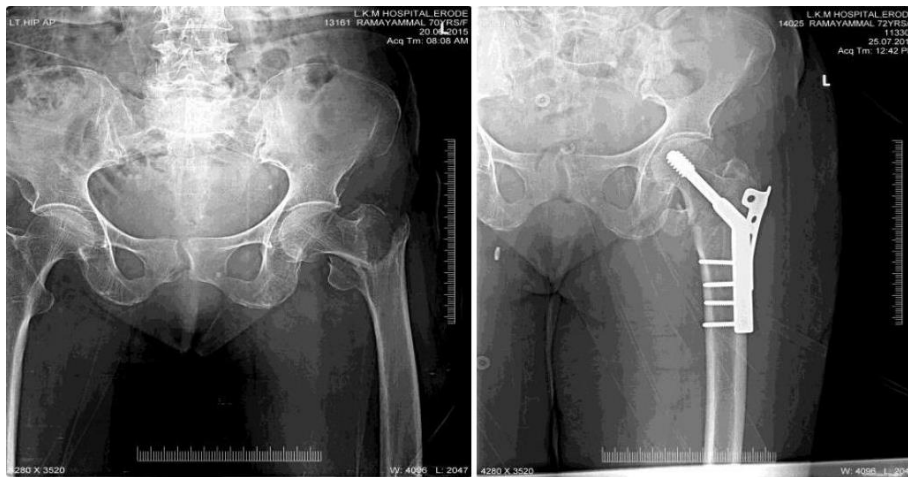
In this series of 49 cases, medialization of the distal shaft fragment, excessive collapse and lag screw cut out was prevented in all the cases. The average collapse at the fracture site was 4.8mm which was significantly lower than 10.2mm and 9.3mm in stable and unstable fractures respectively as reported by Hardy *et al.* And Steinberg *et al.* [11]. Muller –Farber *et al.* [12] found an association between extent of screw sliding and postoperative mobility. A screw sliding of below 6.7mm did not affect the level of mobility, a sliding of 13.4mm resulted in lower mobility level and an 18.7mm slide resulted in lowest mobility level. The average sliding distance in our study was only 4.8mm and all the patients had good level of mobility. In a clinical study by

Madsen *et al.*, comparing the use of TSP with DHS fixation to DHS only fixation, he noted that TSP reduced the lag screw sliding by 5.4mm without interfering with fracture healing [13]. All the cases in our study had a very good fracture healing although the sliding distance was only 4.8mm.

The time taken for clinic-radiological consolidation of fracture in this series was 15.8 weeks. Chiavras *et al.*, developed the RUSH scoring system to assess the radiographic union of hip fractures after fixation [3]. The RUSH system has a minimal score of 10 and a maximum of 30. All the cases in our series had score in the range of 20 to 30 indicating good radiological union.

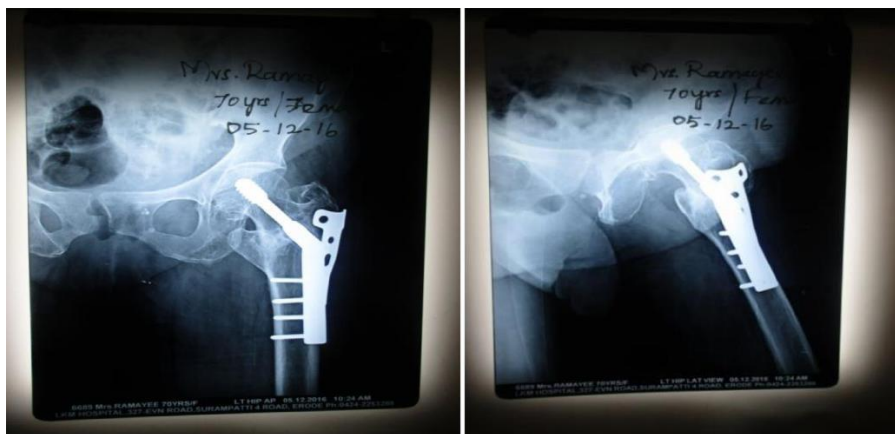
Functional outcome was assessed using the HHS and Salvati-Wilson score. 42 patients (86%) had a HHS of > 90 and 7 patients (14%) had a HHS of > 80. Also 84% of patients had a Salvati –Wilson score of > 30 points (Fig 5, 6). Although the exact mechanism of action of TSP is not fully understood, it has been accepted that TSP provides a buttress to the greater trochanter and mechanical hindrance against the medialization of the distal fragment, at the same time allowing the lag screw to slide in the oval hole which is of pivotal importance in fracture healing.

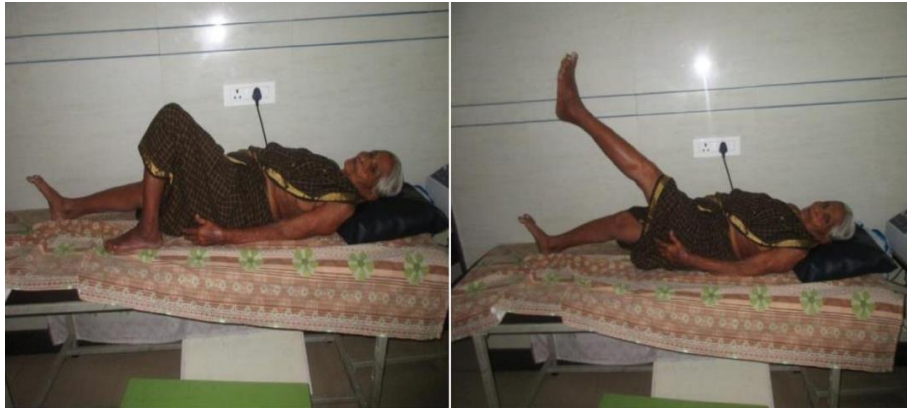By using a customised low cost TSP in this study we were able to achieve good results comparable to those achieved while using an anatomical TSP.



Pre-Op

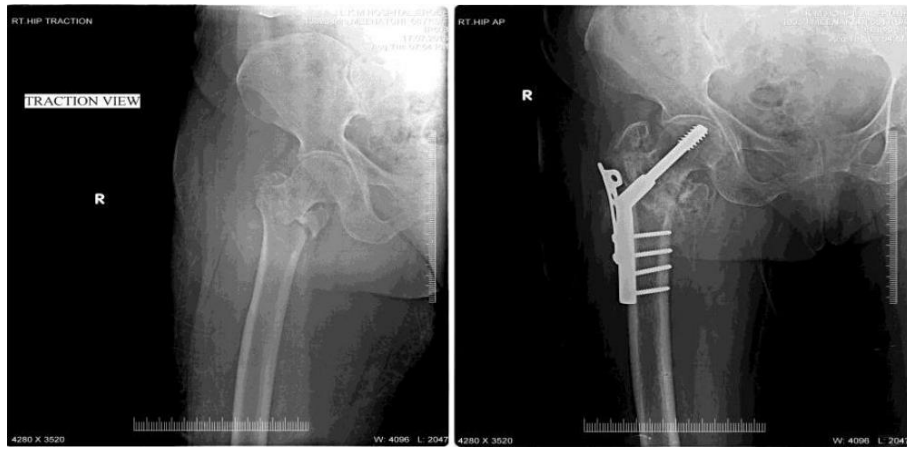At 3 Months





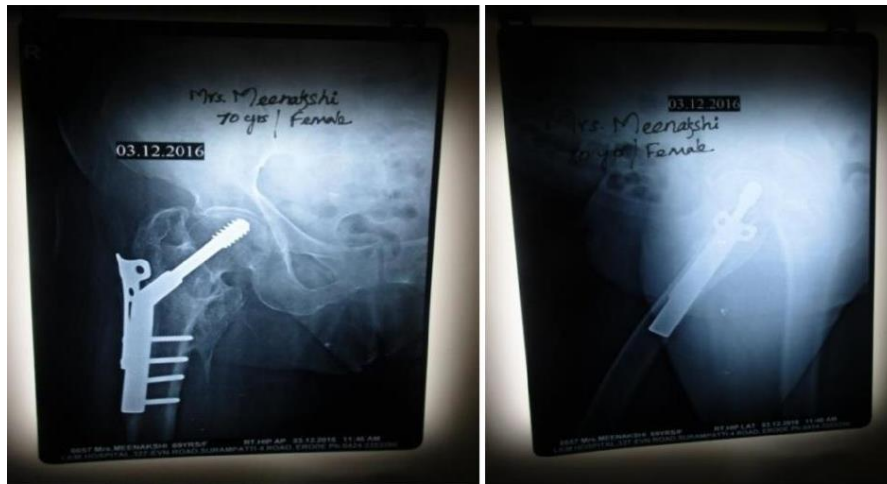
At 6 Months

Fig 5: Patient 1



Pre-Op

At 3 Months



At 6 Months

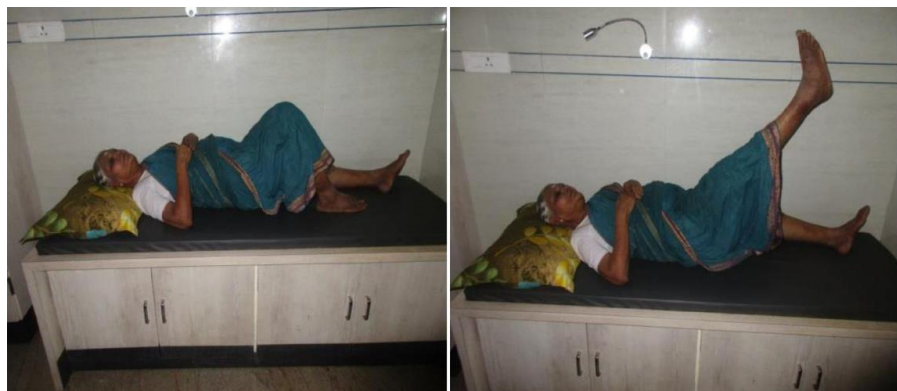

Fig 6: Patient 2

Conclusion

Trochanteric stabilisation plate when used in conjunction with DHS in the treatment of unstable inter-trochanteric fractures provides excellent results and prevents complications such as excessive collapse, femoral medialization and lag screw cut out. Although several TSP's are commercially available in the market, a simple customization of the T-buttruss plate can be easily done and can be used in the treatment of inter-trochanteric fractures as effectively as a anatomical TSP.

References

1. Ecker ML, Joyce JJ, Kohl JE. The treatment of trochanteric hip fractures using a compression screw. *J Bone Joint Surg.* 1975; 87-A(1):23-27.
2. Gadegone WM, Salphale YS. Proximal femoral nail-an analysis of cases of proximal femoral fractures with an average follow up of 1 year. *Int Orthop.* 2007; 31(3):403-408.
3. Chiavras Mary M, Bains S, Choudur H, Parasu N, Jacobson J, Ayeni O *et al.* The Radiographic Union Score for Hip (RUSH): the use of a checklist to evaluate hip fracture healing improves agreement between radiologists and orthopaedic surgeons. *Skeletal Radiol.* 2013; 42:1079-88.
4. HHS.
5. Salvati-Wilson.
6. Palm H, Jacobsen S, Sonne-Holm S, Gebuhr P. Integrity of the lateral femoral wall in inter-trochanteric hip fractures: an important predictor of a reoperation. *J Bone Joint Surg Am.* 2007; 89:470-5.
7. Parker M. Trochanteric hip fractures. Fixation failure commoner with femoral medialisation, a comparison of 101 cases. *Acta Orthop Scand.* 1996; 67:329-32.
8. Gotfried Y. The lateral trochanteric wall: a key element in the reconstruction of unstable pertrochanteric hip fractures. *Clin Orthop Relat Res.* 2004; 8:2-6.
9. Hardy DC, Descamps PY, Krallis P, Fabeck L, Smets P, Bertens CL *et al.* Use of an intramedullary hip-screw compared with a compression hip-screw with a plate for inter-trochanteric femoral fractures. A prospective, randomized study of one hundred patients. *J Bone Joint Surg Am.* 1998; 80:618-30.
10. Bong MR, Patel V, Iesaka K, Egol KA, Kummer FJ, Koval KJ. Comparison of a sliding hip screw with a trochanteric lateral support plate to an intramedullary hip screw for fixation of unstable inter-trochanteric hip fractures: a cadaver study. *J Trauma.* 2004; 56:791-4.
11. Steinberg GC, Desai SS, Kornwitz NA, Sullivan TJ. The inter-trochanteric hip fracture. A retrospective analysis. *Orthopaedics.* 1988; 11:265-273.
12. Muller-Farber J, Wittner B, Reichel R. Spätergebnisse nach Versorgung pertrochanterer Femurfrakturen des alten Menschen mit der DHS. *Unfallchirurg.* 1988; 91:341-350.
13. Madsen JE, Naess L, Aune AK, Alho A, Ekeland A, Stromsoe K. Dynamic hip screw with trochanteric stabilizing plate in the treatment of unstable proximal femoral fractures: a comparative study with the Gamma nail and compression hip screw. *J Orthop Trauma.* 1998; 12:241-248.