



International Journal of Orthopaedics Sciences

ISSN: 2395-1958
IJOS 2018; 4(3): 282-286
© 2018 IJOS
www.orthopaper.com
Received: 20-05-2018
Accepted: 21-06-2018

Dr. S Noordeen
M.S. Orthopaedics,
Department of Orthopaedics,
Trichy SRM Medical College and
Research Centre, Trichy,
Tamil Nadu, India

Dr. G Samynathan
M.S. Orthopaedics, Assistant
Professor in Department of
Orthopaedics, Trichy SRM
Medical College and Research
Centre, Trichy, Tamil Nadu,
India

Dr. R Bharath
Ms Ortho, 45 south car street,
Tiruchendur-628215 Tuticorin
Dt, Tamil Nadu, India

Is the clavicle fractures fixed with plates and screws really improves the functional outcomes a prospective study

Dr. S Noordeen, Dr. G Samynathan and Dr. R Bharath

DOI: <https://doi.org/10.22271/ortho.2018.v4.i3e.50>

Abstract

Background: Clavicular fractures account for approximately 2.6% of all fractures. Fractures occur most commonly in the middle third of the bone. Displaced Mid-shaft clavicle fractures are common and are generally treated non-operatively. Non-operative treatment of these fractures with axial shortening is associated with a non union rate of 13 – 18% and a delayed union rate of 25%. Prompt fixation of these clavicle fractures permits increased patient comfort, and early shoulder mobility.

Objective: To analyse the functional outcome of surgical management of clavicle fracture fixed with plates and screws in terms of union, functions and complications. Displaced Mid-shaft clavicle fractures are common and are generally treated non-operatively.

Methods: A prospective study of 30 cases of midshaft clavicle fractures in adults. Managed surgically during the period from August 2015 to August 2017 satisfying the inclusion and exclusion criteria were studied. The functional outcome was evaluated using the Constant and Murley scoring system.

Results: In our study we achieved 90% excellent results and 10% good results. The results were comparable to other studies.

Conclusion: In this study demonstrate early pain relief with good shoulder function, quick return to activities and a high patient satisfaction rate. Therefore, we believe that open reduction and rigid internal fixation is a valuable option in the acute treatment of displaced Mid-shaft clavicle fractures in active adults with high functional demands.

Keywords: Clavicle fractures fixed, plates, screws really improves, functional outcomes

Introduction

Clavicle fractures are common injuries in young, active individuals, especially those who participate in activities of sports where high speed falls (eg. bicycling, motor cycles) or violent collisions (eg. foot ball, hockey) are frequent and they account for approximately 2.6% of all fractures [1-6] Most (85%) clavicle fractures occur in the mid shaft of the bone, whereas can be seen in cross section, the bone is narrowest and the enveloping soft tissue structures are most scarce [7, 8]. Displaced Mid-shaft clavicle fractures are common and are generally treated non-operatively. Non-operative treatment of these fractures with axial shortening is associated with a non-union rate of 13 – 18% and a delayed union rate of 25%. Intractable pain, neurological complications and loss of shoulder function have been reported. So persons with high activity level will hesitate to accept prolonged recovery and impaired shoulder function, therefore may require more aggressive acute treatment of middle third clavicle fractures. Prompt fixation of these clavicle fractures permits increased patient comfort, and early shoulder mobility. In cases of associated scapula fractures, fixation of the clavicle may provide restoration of shoulder mechanics leading to improvement of function. More recently, there has been increasing evidence that the outcome of non-operatively treated (especially displaced or shortened) mid shaft fractures is not as optimal as was once thought [9-12].

Aims and Objectives

The aim of the study is to analyse the functional outcome of surgical management of clavicle fracture fixed with plates and screws in terms of union, functions and complications.

Correspondence

Dr. G Samynathan
M.S. Orthopaedics, Assistant
Professor in Department of
Orthopaedics, Trichy SRM
Medical College and Research
Centre, Trichy, Tamil Nadu,
India

Materials and Methods

This prospective randomized study was conducted at Department of Orthopaedic Surgery and Traumatology, Vinayaka Mission's Medical College and Hospital, Salem. Duration of study was from August 2015 to August 2017. The mean follow up period was 24 months. Informed consent was taken from the patients who are included in this study for the selection criteria. The ethical committee of Vinayaka Mission's Medical College and Hospital, Salem was informed about the intended work and permission was obtained to conduct the work. In this study of 30 patients treated in Department of Orthopaedic Surgery and Traumatology, Vinayaka Mission's Medical College and Hospital, Salem of clavicle fractures and willing to undergo the study were taken. These will be selected based on inclusion and exclusion criteria.

Inclusion criteria

1. Robinson type II B1 and type II B2 fractures.
2. Age group between 20 to 50 years.
3. Impending skin disruption
4. Shortening ≥ 20 mm
5. Displacement > 20 mm

Exclusion criteria

1. Age below 20 years and above 50 years
2. Undisplaced fractures
3. Medial third and lateral third fractures

Mode of Surgical Management

The injured limbs were initially immobilized with cuff and collar. All cases were assessed preoperatively with x-rays, the mechanism of injury, type of fracture and method of treatment was documented.

Thirty patients with mid-shaft clavicular fractures were treated surgically, among them 21 patients had Robinson type II B1 and 9 patients had Robinson type II B2 fracture. 10 patients were fixed with Reconstruction Plate, 10 patients with Dynamic Compression Plate and 10 patients with Locking Plate.

All patients were operated under general anaesthesia with plate and screws. We have done Iliac Crest Bone Grafting for five cases of Robinson type II B2 fractures. All patients were immobilized in an arm pouch for 12 days. Gradual mobilization started after suture removal on 12th day. They were asked to restrict heavy activities for six weeks. They were reviewed at an interval of 6 weeks upto 12 weeks and then every 12 weeks. The follow up period ranged from 12 months to 18 months. Clinical parameters like tenderness at the fracture site, pain at the shoulder and the range of motion recorded. Radiologically callus formation and progress of union was looked.

Surgical Technique

Patient is kept in beach chair position under general anesthesia with towel or sand bag under affected shoulder. Entire upper limb from the base of the neck to hand is prepared and draped. About 7-9cm skin incision is made in the anterior aspect centering over the fracture site. The skin, subcutaneous tissue is cut platysma divided, minimal soft tissue and periosteal stripping done. Clavicle blood supply is mostly periosteal and has minimal endosteal blood supply. Fracture site reduced and fixed with plates with lag screws used to fix butterfly fragments. Six cortical purchases with minimum three screws in each fragment in most cases.

Wound closed in layers after securing meticulous haemostasis with suction drain kept and patient immobilized in an arm sling.

Post-Operative Regimen

Arm is rested in sling, suction drain removed after 48 hours. Patient given intravenous antibiotics for five days. Open reduction and stable internal fixation allows early mobilization without the fear of collapse of reduction. It allows perfect anatomic reduction. The patient is allowed to mobilize the shoulder as early as 4 to 5 days if the pain permits. However the patient should be warned against developing a "false sense of security". The success of open reduction and internal fixation depends on early restoration of joint mobility. Suture removal is done on 12th day. Shoulder mobilization exercises started after suture removal. Patient is asked to restrict heavy activities for 6 weeks.

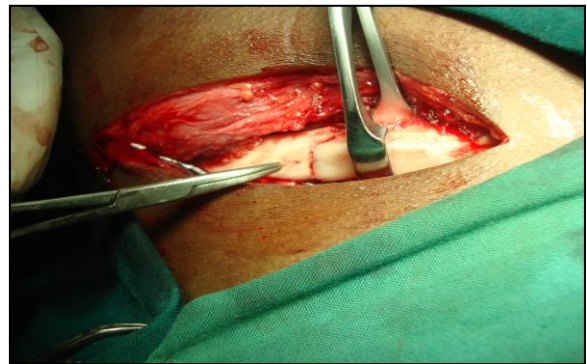


Fig 1: Fracture Reduction

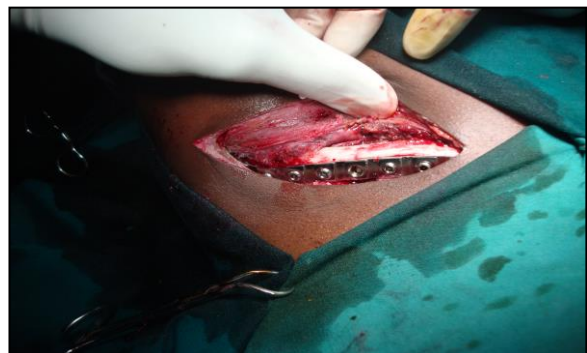

Fig 2: Plate fixation

Results

Table 1: Age Distribution

Age group of patients	No. of patients	Percentage
15 – 30	8	26.7
31 – 45	12	40.0
46 – 60	6	20.0
Above 60	4	13.3
Total	30	100.0

Clavicle fractures are common in males aged from 31-45 years with subsequent fall in incidence with age until the seventh decade.

Table 2: Sex Distribution

Sex	Frequency	Percent
Male	17	56.7
Female	13	43.3
Total	30	100.0

Male preponderance is due to the more active social life style of males.

Table 3: Occupation

S. No.	Occupation	No. of patients	Percent
1	Clerical work	5	16.7
2	House Hold work	2	6.7
3	Manual Labour	16	53.3
4	Sports person	5	16.7
5	Student	2	6.7
	Total	30	100.0

Mostly working population like manual labour (53.3%) had fractures with involvement of dominant hand.

Table 4: Mode of Injury

Mode of injury	No. of patients	Percentage
Fall by Outstretched hand	8	26.7
Road Traffic Accident	13	43.3
Sports Injury	9	30.0
Total	30	100.0

Road traffic accident was the cause for clavicle fracture in most of the patients (43.3%).

Table 5: Side of Injury

Side	No. of Patients	Percent
Right	18	60.0
Left	12	40.0
Total	30	100.0

Right side fracture (60%) are common than left side.

Table 6: Fracture Type

Classification	No. of Patients	Percentage
Robinson II B1	21	70.0
Robinson II B2	9	30.0
Total	30	100.0

Type II B1, fractures are more common (70%). Type II B2 fractures had an incidence of 30%.

Table 7: Associated Injuries

Associated Injuries	No. of Patients	Percent
Ankle fracture	1	3.3
Both bones leg	2	6.7
Shaft femur	2	6.7
Shoulder dislocation	1	3.3
Nil	24	20.0
Total	30	80.0

20% of the patients had associated injuries like fracture shaft of femur, fracture both bones leg, shoulder dislocation and ankle fractures.

Table 8: Time Interval between Injury and Surgery

Time Interval	No. of Patients	Percent
0-2 days	5	16.7
2-5 days	14	46.7
5-7 days	9	30.0
> 7 days	2	6.7
Total	30	100.0

Time interval from injury to surgery is 2-5 days is more common 46.7%.

Table 9: Time for Union (In Weeks)

Time for Union (in weeks)	Frequency	Percent
6 weeks	13	43.3
7 weeks	13	43.3
8 weeks	3	10.0
9 weeks	1	3.3
Total	30	100.0

Time for union is 6-7 weeks is more common 86.6%

Table 10: Complications

Complications	Frequency	Percent
Nil	23	76.7
Delayed union	2	6.7
Hardware irritation	5	16.7
Total	30	100.0

Complication hardware irritation is more common in 16.7% cases and 76.7% cases with no complication.

Table 11: The Functional Outcome Assessment

Grade	No. of Patients	Percentage
Excellent	27	90%
Good	3	10%
Poor	0	0

The functional outcome assessment according to constant and Murley score for middle third clavicle fracture treated by plate and screws showed excellent functional outcome in 27 patients (90%) and good functional outcome in 3 patients (10%).

Complications in This Study

There was no post-operative wound infection in this study. Two cases (6.7%) of Robinson type II B1 fixed with Reconstruction Plate developed union around 18 weeks with good movements and had good results. There were no nonunion in this study, all fractures ultimately united. We had to removed implants in five cases 16.7% in that two Dynamic Compression Plate implant and three Reconstruction plate because of subcutaneous position makes hardware extremely prominent. No cases with hypertrophic scar and implant failure.

Case Illustrations

Case - I

Diagnosis : Robinson IIB2 (L)

Procedure : Open Reduction and Internal Fixation with Locking Plate / Nailing

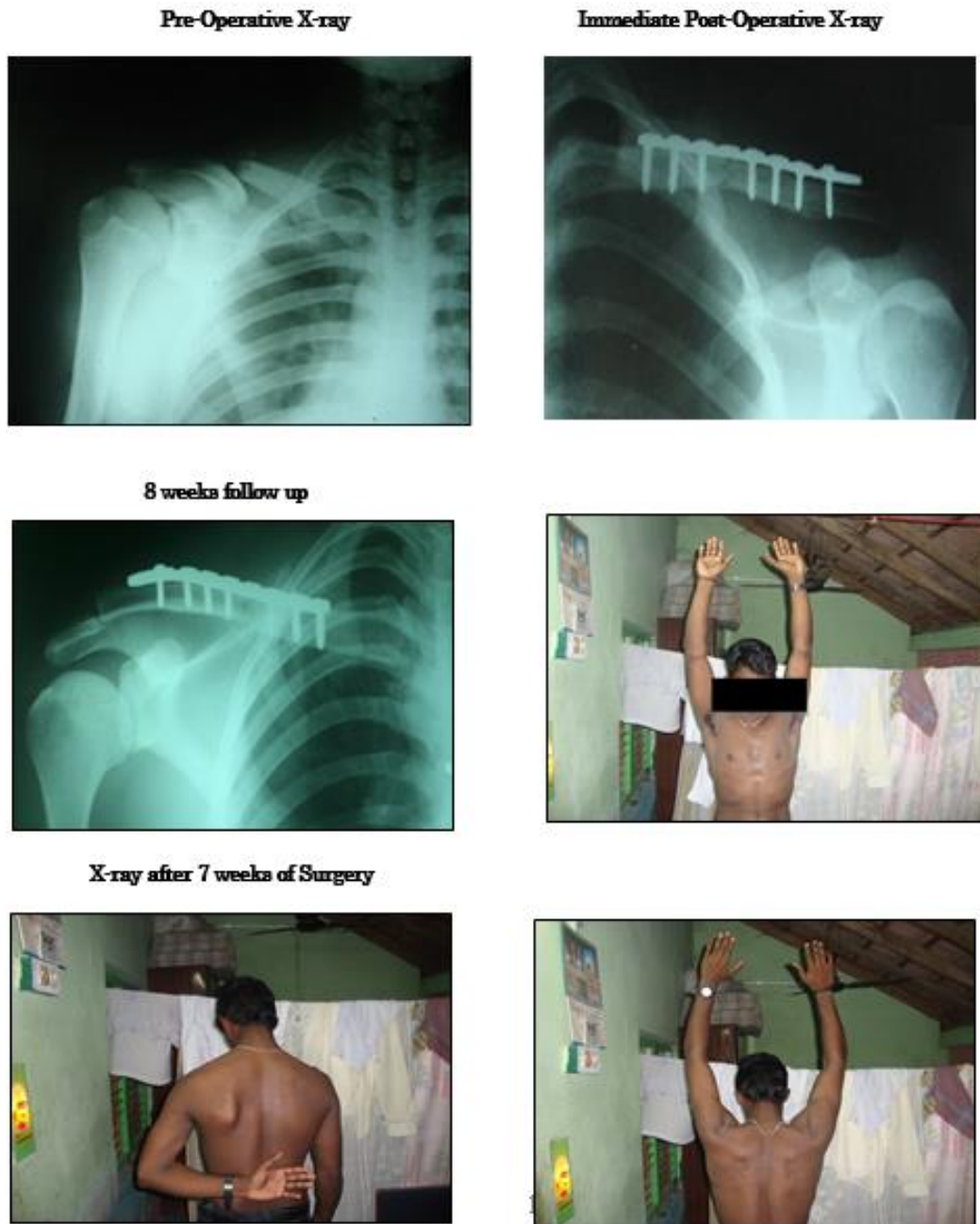

Fig 3: Case – I

Discussion

This study shows excellent results of operative treatment of displaced mid shaft clavicle fractures in adults. The patients treated with early, rigid fixation of their clavicle fractures shared a high postoperative constant score, early pain resolution early return to activity and high patient satisfaction rating.

Displaced mid-shaft clavicle fractures are considered as benign injuries with satisfactory outcome if treated conservatively [13-15] However several reports challenge this view and there has been a resurgence of interest in operative treatment for fractures of the clavicle that display significant shortening. Possible complications resulting from conservatively treated clavicle fractures are cosmetically displeasing end results, delayed union, persisting non union, chronic shoulder pain and impaired shoulder function [14-16] A more unusual complication of clavicular malunion includes thoracic outlet syndrome [17, 18]

We achieved the average union rate of Robinson type II B1 fractures with 6.5 weeks and Robinson type II B2 fractures

with 7.5 weeks. We had two cases of delayed union (6.7%) one case was due to more than three screws in each fragments and in one case delayed union was due to the presence of screw on the fracture site. Conservative management of displaced mid shaft clavicle fractures shows delayed union upto 25%. [19-21] We have done Iliac Crest Bone Grafting for five cases of Robinson type II B2 fractures.

There was no non-union in this study. But studies show conservative management of displaced and shaft clavicle fractures show upto 15% non-union [16, 22] Literature review shows Mid-shaft fractures with a shortening of more than 2cm predispose to non-union [21]. The risk of non union was increased by lack of cortical apposition, female gender, the presence of comminution and advancing age [23].

Open reduction with internal fixation was considered one of the reasons for non-union. But special attention was directed at preservation of all soft tissue attachments to the fracture fragments and careful elevation of platysma and minimal periosteal stripping provides good union [24, 25] In this study we had 100% union with delayed union. In reviewing the

literature open reduction with internal fixation with plate osteosynthesis shows union from 90-100%.

Late neurovascular compromise upto 6% was seen in patients treated conservatively due to non union and excessive callus formation.^{26,27} In this study we had no transient neurological abnormalities.

The range of motion was good and the mean constant and murley score was 90 in this study fractures treated with operative fixation show good constant and murley score. On reviewing the literature we found patients treated conservatively had substantial residual disability of the affected shoulder with minimal loss of muscle strength^[14-16, 22]. The advantages of internal fixation of clavicle fractures, which includes early pain resolution, early return of shoulder function and potentially early return to work makes it an appealing option for the treatment of displaced fractures in active individuals.

In this study, the other major complication of study was hardware irritation and prominence in 16.7% of patients mostly treated with Dynamic Compression Plates and Reconstruction plate. These patients under went implant removal. All cases were followed up regularly we have no refractures till date. There were no complaints of numbness at the fracture site, pseudoarthrosis or any other complications. We had only one case of hypertrophic scar so we have no definitive conclusion regarding preferred incision techniques.

Conclusion

The acute treatment of displaced mid-shaft clavicle fractures remains a subject of controversy. In this study demonstrate early pain relief with good shoulder function, quick return to activities and a high patient satisfaction rate. Therefore, we believe that open reduction and rigid internal fixation is a valuable option in the acute treatment of displaced Mid-shaft clavicle fractures in active adults with high functional demands.

Reference

- Craig EV. Fractures of the clavicle. In Rockwood CA, Matsem FA. eds. The shoulder Philadelphia: WB saunders, 1990, 367-412.
- Eiff MP. Management of clavicle fractures. Am Fam. Physician 1997; 55:121-128.
- Neer C. Fractures of the clavicle. In: Rockwood CA, Green DP, eds. Fractures in Adults, 2nd ed. Philadelphia: JB Lippincott, 1984, 707-713.
- Neviaser JS. The treatment of fractures of the clavicle. Surg clin North Am 1963; 43:1555-1563.
- Nordqvist A, Peterson C. The incidence of fractures of the clavicle Clin Orthop 1994; 300:127-132.
- Nowak, J, Mallmin H, Larson S. The aetiology and epidemiology of clavicular fractures. A prospective study during a 2 – year period in Uppsala, Sweden. Injury. 2006; 35:353-358.
- Robinson CM. Fractures of the clavical in the adult. J Bone Joint Surg Br. 1998; 80B:476-484.
- Robinson CM, Cairns DA. Primary non operative treatment of displaced lateral fractures of the clavicle. J Bone Joint Surg AM 2004; 86A:778-782.
- Brinker MR, Edwards TB, O'connor DP. Letter to the editor. J Bone Joint Surg AM. 2005; 87AA:677-678.
- Edwards DJ, Karanagh TG, Flannery MC. Fractures of the distal clavical: a case for fixation. Injury. 1992; 23:44-46.
- Hill JM. closed treatment of displaced middle – third fractures of the clavicle gives poor results (letter to the editor). J Bone joint Surg Br. 1998; 80B:558.
- McKee MD, Wild LM, Schemitsch EH. Mid-shaft mal-unions of the clavicle J Bone Joint Surg AM 2003; 85A:790-797.
- Der Tavitian J, Davison JN, Dias JJ. Clavicular fracture non-union: surgical outcome and complications. Injury. 2002; 33:135-143.
- Hill JM, McGuire MH, Crosby LA. Closed treatment of displaced middle-third fractures of the clavicle gives poor results. J Bone Joint Surg. 1997; 79-B:537-539.
- McKee MD, Pedersen E, Wild L, Schemitsch EH. Objective measured strength deficits following conservative treatment of clavicle fractures. 71st Ann Meet AAOS San Francisco: 2004, 285.
- McKee MD, Pedersen E, Wild L, Schemitsch EH, Potter J. Deficits following non operative treatment of displaced mid shaft clavicular fracture. JBJS Am. 2006; 88(1):35-40.
- Chen DJ, Chuang DC, Wei FC. Unusual thoracic outlet syndrome secondary to fractured clavicle. J Trauma. 2002; 52:393-8.
- Fujita K, Matsuda K, Sakai Y, Sakai H, Mizuno K. Late thoracic outlet syndrome secondary to malunion of the fractured clavicle: case report and review of the literature. J Trauma. 2001; 50:332-5.
- Jupiter JB, Leffert RD. Non-union of the clavicle. Associated complications and surgical management. J. Bone Joint Surg. 1987; 69-A:753-760.
- Simpson NS, Jupiter JB. Clavicular nonunion and malunion: evaluation and surgical management. J Am Acad Orthop Surg. 1996; 4:1-8.
- Wick MR, Muller EJ. Mid-shaft fractures of the clavicle with a shortening of more than 2cm predispose to non union. Arch Orthop. Trauma Surg. 2001; 121(4):207-211.
- Nordqvist A, Petersson CJ, Redlund-Johnell I. Midclavicle fractures in adults : end results study after conservative treatment. J Orthop Trauma. 1998; 12:572-576.
- Michael Robinson, Margret M Mequeen, Charles M, Court Brown. Estimating the risk of non union following non operative treatment of a clavicle fracture. JBJSBr 2004; 186-A:1359-1365.
- Lisa K Cannada, Allen, Wibber John. Operative fixation of high energy displaced mid shaft clavicle fractures. AAOS Meet, Cleveland, 1999.
- Show J, Liv TJ. Plate fixation of fresh displaced Mid-shaft clavicle fractures. Injury, 1999, 30.
- Barbier O, Malghem J, Delaere O. Injury to the brachial plexus by a fragment of bone after fracture of the clavicle. J. Bone Joint Surg. 1997; 79-B:534-536.
- Loncan LI, Sempere DF, Ajuria JE. Brown-Sequard syndrome caused by a Kirschner wire as a complication of clavicular osteosynthesis. Spinal Cord. 1998; 36:797-799.