



International Journal of Orthopaedics Sciences

ISSN: 2395-1958
IJOS 2018; 4(3): 209-213
© 2018 IJOS
www.orthopaper.com
Received: 09-05-2018
Accepted: 10-06-2018

Dr. Prakash Wali
Associate Professor, Belagavi
Institute of Medical Sciences,
Belagavi, Karnataka, India

Dr. Santosh Mared
Senior Resident, Belagavi
Institute of Medical Sciences,
Belagavi, Karnataka, India

Pro's and Con's of proximal femoral nail in Peri trochanteric fractures

Dr. Prakash Wali and Dr. Santosh Mared

DOI: <https://doi.org/10.22271/ortho.2018.v4.i3d.39>

Abstract

Background: Fractures of the trochanteric region of femur can be difficult to treat. This anatomic region experiences the highest tensile and compressive stresses in the human skeleton. The proximal fragment is often quiet short, offering limited opportunity for internal fixation, which must withstand these substantial forces. In subtrochanteric fracture, the proximal fragment is flexed, abducted and externally rotated due to the Iliopsoas, abductor muscles, and short external rotators muscle pull. Hence, it is useful to perform an open reduction of the fracture fragments and then stabilise the proximal fragment to restore anatomical position, prior to nail insertion.

Methods: The present study consists of 20 adult patients with proximal femoral fractures of femur who were treated with PFN at Bims, Belgaum between Jan 2014 to March 2018. The fractures were classified according to Russell and Taylor classification. 20 cases were followed at regular intervals. This study was conducted with due emphasis for clinical observation and analysis of results after surgical management of peritrochanteric fractures of femur.

Results: In our study of peritrochanteric fractures treated with PFN, we encountered intraoperative complications like iatrogenic fracture of lateral cortex in 2 cases (10%) due to selection of wrong entry point, failure to put derotation screw in 2 cases (10%) and guidewire breakage in 1 case (5%). Delayed complications like hip joint stiffness in 3 cases (15%), knee joint stiffness in 1 case (5%) and shortening of more than one cm in 1 case (5%) and delayed union in 2 cases (10%).

Conclusions: Open reduction offer advantage in preventing malalignment of peritrochanteric fractures as compared to closed reduction. From our study we conclude that PFN is a reliable implant for peritrochanteric fractures, leading to high rate of bone union restoring the anatomical alignment and reduced chance of implant failure or deformities.

Keywords: Pfn, peritrochantric fracures

Introduction

Peritrochanteric fractures occur typically at the junction between trabecular bone and cortical bone where the mechanical stress across the junction is highest in the femur, which is responsible for their frequent comminution. These fractures account for 10% to 34% of all hip fractures.

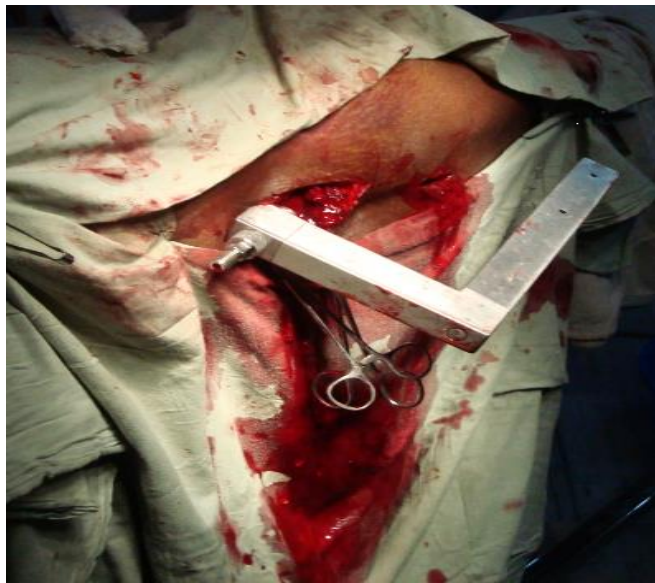These fractures occur typically in two age groups. In young and healthy individuals, the injury results from high-energy trauma, whereas in the elderly population, most of the fractures are osteoporotic, resulting from a fall. With the increase in the aging population, there is also considerable growth in the number of pathological fractures and fractures around hip prostheses (periprosthetic fractures).

Proximal femoral region is usually exposed to high stresses during activities of daily living. Axial loading forces through the hip joint create a large moment arm, with significant lateral tensile stresses and medial compressive loads. In addition to the bending forces, muscle forces at the hip also create torsional effects that lead to significant rotational shear forces. During normal activities of daily living, up to 6 times the body weight is transmitted across the proximal femoral region of the femur.

As a result of these high forces, the bone in this region is a thick cortical bone with less vascularity and results in increased potential for healing disturbances. Hence subtrochanteric fracture is difficult to manage and associated with many complications.

Correspondence
Dr. Santosh Mared
Senior Resident, Belagavi
Institute of Medical Sciences,
Belagavi, Karnataka, India

Closed management of these proximal femoral fractures thus poses difficulties in obtaining and maintaining a reduction, making operative management the preferred treatment. The goal of operative treatment is restoration of normal length and angulation to restore adequate tension to the abductors.



The obvious advantages of operative treatment are:

1. it avoids complications of prolonged bed rest and hospitalization.
2. Accurate reduction and anatomical alignment.
3. Early mobilization and weight bearing, is possible with new implants and fixation technology.

The two primary options for treatment of proximal femoral fractures are intramedullary fixation and extramedullary fixation. Many internal fixation devices have been recommended, but because of high incidence of complications like nonunion and implant failure, a series of evolution in designing a perfect implant has begun. Only recently better understanding of biology, reduction techniques and biomechanically improved implants like Gamma nail, Russell Taylor nail, Proximal femoral nail allowed for these fractures to be addressed with consistent success.

Fractures of the peritrochanteric region of femur can be difficult to treat. This anatomic region experiences the highest tensile and compressive stresses in the human skeleton. The proximal fragment is often quite short, offering limited opportunity for internal fixation, which must withstand these substantial forces. In peritrochanteric fracture, the proximal fragment is flexed, abducted and externally rotated due to the Iliopsoas, abductor muscles, and short external rotators muscle pull.

Hence, it is useful to perform an open reduction of the fracture fragments and then stabilise the proximal fragment to restore anatomical position, prior to nail insertion.

The forces typically displace the proximal fragment, positioning it in such a way that it may be difficult to achieve an accurate reduction and internal fixation. In general, nail fixation has been preferred for these fractures because of its biomechanical superiority compared with plates. The proximal fragment is abducted, making entry into the tip of the greater trochanter difficult as a result of problems with nail entry trajectory. The proximal fragment is also flexed and externally rotated, often necessitating nail starting point trajectories that are quite awkward while closed method of

nailing is considered for treating these fractures. So by opening the fracture site and by carefully handling the proximal fragment with a clamp, the deforming forces can be reversed-i.e. the proximal fragment can be adducted, extended and internally rotated.

Objectives

1. To study peritrochanteric femoral fractures
2. To determine the rate of union, complications, operative risks and functional outcomes in peritrochanteric Femoral fractures

Methodology

The present study consists of 20 adult patients (13males and 7females) with peritrochanteric femoral fractures of femur who were treated with PFN at Bims, belgaum between jan 2014 to march 2018. Patients were selected depending on admissions with subtrochanteric fracture in this period. The fractures were classified according to Russell and Taylor classification. 20 cases were followed at regular intervals. This retrospective study was conducted with due emphasis for clinical observation and analysis of results after surgical management of proximal femoral fractures of femur with proximal femoral nail.

Inclusion Criteria

- Age group : above 20yrs
- Male and female patients
- If fracture is 2.5cm distal to lesser trochanter or even more proximal fractures if the lesser trochanter is intact
- Proximal 1/3rd shaft femur fractures
- Subtrochanteric fractures in which lesser trochanter is not comminated off proximal femur
- Consent to participate in the study

Exclusion Criteria

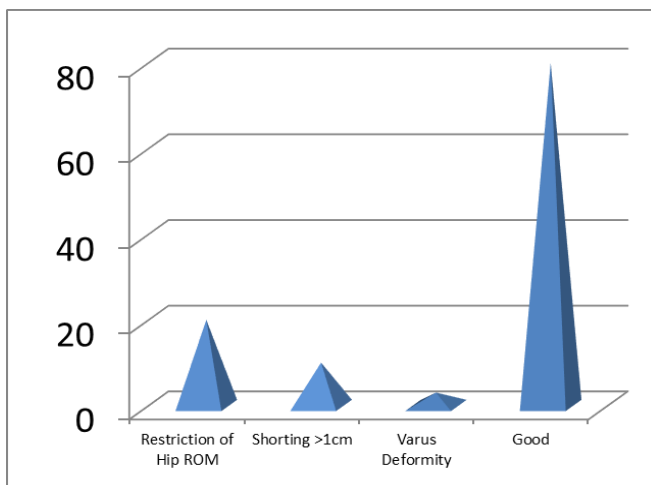
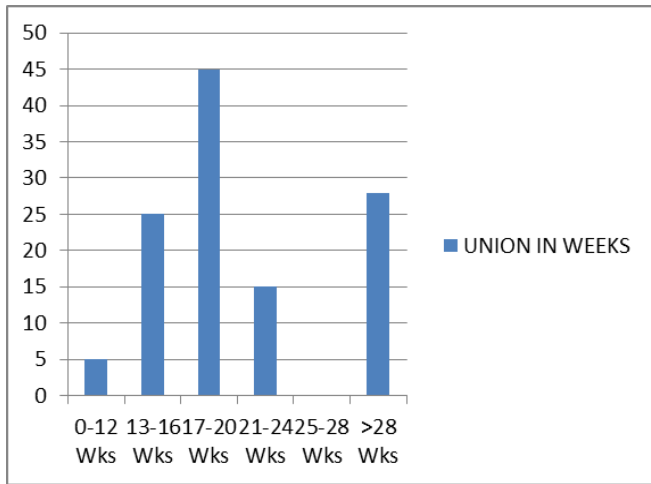
- Pathological fractures
- Multiple fractures
- Fractures in children
- Old neglected fractures

Result

Statistical Analysis of Intraoperative Complications

Intraoperative Complications	No of Cases	Percentage
Fracture Of Lateral Cortex	5	10
Failure To Put Derotation Screw	5	10
Jamming Of Nail	1	2
Drill Bit Breakage	2	4
Guide Wire Breakage	1	2

Delayed Comlications	No of Cases	Percentage
Hip Joint Stiffness	7	15
Knee Joint Stiffness	2	5
Delayed Union	5	10
Shortening	2	5



Discussion

Unlike osteoporotic trochanteric fractures, peritrochanteric fractures are usually the result of high-energy trauma and often subjected to significant displacement and great difficulty in close reduction through traction. The high incidence of delayed union, malunion and non-union of fractures has left conservative treatment, as advocated by DeLee *et al.*, abolished in modern trauma care.

Extra medullary fixation with plating has the potential disadvantages of extensive surgical exposure, severe soft tissue damage and blood loss, thus leading to problems of fracture union and implant failure. In addition, the eccentrically plating is prone to fatigue breakage due to their mechanical load-sharing effect.

Allowing a minimally open approach, intramedullary nailing is closely linked to "biological internal fixation", in addition to its mechanical benefits over plate fixation. Intramedullary fixation allows the surgeon to minimize soft tissue dissection thereby reducing surgical trauma, blood loss, infection, and wound complications (Leung *et al.* 1992) [34].

A laboratory study comparing a locked Gamma nail to a standard sliding hip screw for the fixation of stable and unstable subtrochanteric fractures showed that the intramedullary nail was more rigid and permitted less fracture displacement and concluded that intramedullary fixation was superior to extramedullary fixation. The currently used Gamma nail as an intramedullary device also has a high learning curves with technical and mechanical failure rates of about 10% (collapse of the fracture area, cut-out of the implant, fracture of the femur shaft)

(Valverde *et al.* 1998). The Gamma nail is susceptible to fail at its weakest point, the lag screw — implant interface.

The AO ASIF in 1996, therefore developed the Proximal Femoral Nail to reduce the risk of implant related complications. Therefore in addition to the 8 mm load bearing femoral neck screw, the PFN has a 6.5mm antirotation screw to increase the rotational stability of the neck fragment. An anatomic 60 neck valgus bend in the coronal plane, a narrower distal diameter and distal flexibility of the nail eliminates the need for routine reaming of the femoral shaft and also minimizes stress concentration and tension in the femoral shaft. This should reduce the risk of intraoperative and postoperative femoral shaft fractures.

PFN also has all the advantages of an intramedullary device such as decreasing the moment arm, can be inserted by closed technique which retains the fracture hematoma, decreases blood loss, minimizes soft tissue dissection and wound infections. In an experimental study compared the load ability of osteosynthesis of unstable per and subtrochanteric fractures and found that the PFN could bear the highest loads of all devices. Since its introduction in 1997 several clinical studies have shown good result (with few intra operative problems and low rates of complications).

The Aim of our study was to assess the epidemiology and functional outcomes of subtrochanteric fractures with this newer method of intramedullary fixation with proximal femoral nail. We assessed the results with respect to intraoperative details, post-operative results and functional outcome.

By virtue of its load-sharing characteristics, the shorter lever on the proximal fixation and its biologically friendly implantation techniques, intramedullary nail fixation of subtrochanteric fractures has resulted in high union rates.

Although biomechanically and biologically superior to plate fixation, closed nailing techniques can be technically difficult as a result of the position of the proximal fragment which is flexed, abducted and externally rotated. Awkward starting trajectories have often resulted in eccentric nail channels in the proximal fragment. Starting points were often too lateral, resulting in varus alignment of the proximal fragment.

Hence, by opening the fracture site and bringing the proximal fragment in anatomical position w.r.t. distal fragment and subsequent nailing, results in high bone union rates without any rotational or angular deformities.

Lei-Sheng Jiang *et al.* in his study has no complications such as cutout or breakage of the implants, or pen-implant fractures. He recommended that the lag screw of PFN should be placed in the lower part of the femoral neck close to the femoral calcar, with screw tip reaching the subchondral bone 5 to 10 mm below the articular cartilage in anteroposterior view. In lateral view, it should be placed in the centre of the femoral neck. There, the lag screw will be definitely placed in the area of best bone quality. In 2002, Inger B Schipper in his study on biomechanical evaluation of PFN also concluded that if the hole through the nail of the hip pin was modified to a slot there is significant reduction of axial loads on hip pin thereby reducing the cut out risk.

Werner *et al.* was the first who introduced the term Z-effect, detected in 5 (7.1%) of 70 cases. The incidence of cut-out of the neck screw in this study was 8.6%. The Z-effect phenomenon is referred as a characteristic sliding of the proximal screws to opposite directions during the postoperative weight-bearing period.

The reverse Z-effect described by Boldin *et al.* occurred with movement of the hip pin towards the lateral side, which required early removal. The mechanism is similar, but here the hip pin is sliding back, whereas the neck screw remains

impacted to the hole of the nail. In their prospective study of 55 patients with unstable intertrochanteric or subtrochanteric fractures, they had 3 cases with Z effect and 2 with reverse Z-effect. The authors in an effort to prevent the Z-effect phenomenon suggest the use of a "ring" in the lateral side of the hip pin.

The most recent study evaluating the use of PFN is from Fogagnolo *et al.* who reported 46 patients with an average rate of intraoperative technical or mechanical complications of 23.4%. They also reported 2 implant failures and 1 fracture below the tip of the nail.

In a clinical study of 155 consecutive patients treated with proximal femoral nail, reported failure of fixation in 2%, femoral shaft in 0.7%, fixation failures included one cut out, one delayed fracture healing and one lateral displacement of the antirotation screw. Christian Boldin *et al.* in his study of 55 patients of proximal femoral fractures with PFN noted 3 cases with Z effect and 2 patients with Reverse Z effect. 2 patients had screw cut-out without any relation to fracture pattern and 10% of open reduction.

In a clinical multicenter study, reported technical failures of the PFN after poor reduction, malrotation or wrong choice of screws in 5% of the cases. A cut-out of the neck screw occurred in 0.6%.

In our study of subtrochanteric fractures treated with PFN, we encountered intraoperative complications like iatrogenic fracture of lateral cortex in 2 cases (10%) due to selection of wrong entry point, failure to put derotation screw in 2 cases (10%) and guidewire breakage in 1 case (5%). Delayed complications like hip joint stiffness in 3 cases (15%), knee joint stiffness in 1 case (5%) and shortening of more than one cm in 1 case (5%) and delayed union in 2 cases (10%).

In our study mean frequency of radiation exposure were 140 sec and mean duration of operation is 105 minutes and mean blood loss was 300ml.

Iatrogenic fracture of lateral cortex was seen in 2 cases, 2 cases antirotation screw could not be put. Post operatively 2 of our cases had superficial infection Mean duration of hospital stay was 24 days in and mean time of full weight bearing was 14 weeks in our study.

In our 20 cases, excellent results were seen in 45%, good in 35% cases, fair in 15% cases and poor in 5% cases by PFN by open method.

Conclusion

Peritrochanteric femoral fractures are usually treated surgically. In the last decade, extramedullary methods of fixation with various angular plates or with a compression hip screw with a plate are more and more replaced by newer intramedullary techniques because of their advantages: the surgical procedure is faster, the blood loss is smaller, the bone healing mainly remains in the reduced position with a biomechanically strong fixation, that allows earlier weightbearing on the bone with less local and general complications.

The abundant muscles around the subtrochanteric region usually cause significant displacement of the fractured fragments, leading to great difficulties in close reduction under traction. Open clamp assisted reduction through an incision at the fracture site restores the normal anatomical alignment and prevents any rotational/angular deformities. The use of appropriate nail length and proper positioning of the nail and screws are necessary to avoid failure or revision. Most of the complications of proximal femoral nailing are surgeon and instruments related which can be cut down by

proper patient selection and good preoperative planning and restoring the anatomical alignment. Because of increasing occurrence of subtrochanteric fractures in younger age active males, higher demand is placed on treating surgeon to restore near normal function of leg.

Osteosynthesis with the Proximal femoral nail offers the advantages of high rotational stability of the head-neck fragment. Proximal femoral nail has the advantage of collapse at fracture site and is biomechanically sound as it's a intramedullary device. Post operatively early mobilization can be begun as the fixation is rigid.

PFN being an intramedullary load sharing device offers better biomechanical stability.

1. Early weight bearing, better range of movements, and early post-operative mobilisation are distinct advantages of PFN in sub trochanteric fractures.
2. Union rates through open technique are high since better reduction is achieved and option of bone grafting is present in comminuted fractures.
3. In our study, there were no cases with screw cut out, Z-effect, reverse Z-effect and implant failure or femoral fracture below the tip in any case.
4. Average duration of surgery was 1 05mm which is more when compared with other standard studies since we used open technique. However, rate of infection and other operative complications were same as cases treated with closed reduction. But reduction achieved was better.
5. However, no cases of significant Limb Length Discrepancy or varus deformities were seen in our study.

Hence, we conclude that open reduction offer advantage in preventing malalignment of subtrochanteric fractures as compared to closed reduction.

From our study we conclude that PFN is a reliable implant for subtrochanteric fractures, leading to high rate of bone union restoring the anatomical alignment and reduced chance of implant failure or deformities. Intramedullary fixation has biological and biomechanical advantages, but the operation is technically demanding. Gradual learning and great patience is needed in order to make this method truly successful.

Reference

1. Robert W Bucholz, James D Flückner, Charles M Court-Brown. Rockwood and Green's Fractures in Adults; 6th edition; 2, 1827-1844.
2. David G Lavelle. Fractures and dislocations of the hip chapter-52 in Cambell's Operative Orthopaedics, eleventh edition, 3, 3237-3308.
3. Toni M McLaunn, Ericka A Lawler. Treatment Modalities for Subtrochanteric Fractures in Elderly. Lippincott Williams and Wilkins Inc. Philadelphia. Techniques in Orthopaedics. 2004; 19(3):197-213.
4. DeLee JC, Clanton TO, Rockwood CA Jr. Closed treatment of subtrochanteric fractures of the femur in a modified cast-brace. J Bone Joint Surg Am 1981; 63:773.
5. The association of age, race and sex with the location of proximal femoral fractures in elderly'. JBJS 1993; 75(5):752-9.
6. Boyd HB, Griffin classification and treatment of trochanteric fractures Arch surgery, 1949; 58; 853-866.
7. Fielding JW, Magliato HJ. Subtrochanteric fractures. Surg Gynecol Obstet. 1966; 122:555-560.
8. Zickel RE. Subtrochanteric femoral fractures. Orthop din North Am 1980; 1(1):555-568.
9. Habernek H, Wallnce T, Aschaner E, Schmid L.

- comparison of Ender's nails, dynamic hip screw and gamma nails in treatment of peritrochanteric femoral fractures *Orthopaedic*. 2000; 23(2):127(7).
10. Velasco RU, Comfort T. Analysis of treatment problems in subtrochanteric fractures of the femur. *J Trauma*. 1978; 18:513-522. 104.
 11. Kenneth J, Koval Joseph D, Zuckerman. Hip fractures-A practical guide to management, 191-252.
 12. Waddell JP. Subtrochanteric fractures of the femur: a review of 130 patients, *J Trauma*. 1978; 18(5):13,
 13. Teitge RA. Subtrochanteric fracture of the femur. *J Bone Joint Surg Am* 1976; 58:282.
 14. Whatley JR, Garland DR, Whitecloud T, Wickstrom J. Subtrochanteric fractures of the femur: treatment with ASIF blade plate fixation. *South Med J*. 1978;17:1372-1375.
 15. Van Meeteren M, Van Rief Y, Roukema J. Van der Werken C. Condylar plate fixation of subtrochanteric femoral fractures. *Injury*. 1996; 27:715-717.
 16. Kinast C, Bolhofner BR, Mast JW, Ganz R. Subtrochanteric fractures of the femur: results of treatment with the 95-degree condylar blade plate. *Clin Orthop*. 1989; 238:122-130.
 17. Wiie PB, Panjabi MM, Southwick WO. Treatment of subtrochanteric fractures with a high-angle compression hip-screw. *Clin Orthop*. 1983; 175:72-78.
 18. Berman AT, Metzger PC, Bosacco SJ. Treatment of the subtrochanteric fracture with the compression hip nail-a review of thirty-eight consecutive cases. *Orthop Trans*. 1979; 3:225-256.
 19. Ruff ME, Lubbers LM. Treatment of subtrochanteric fractures with a sliding screw-plate device. *J Trauma*. 1986; 26:75-80.
 20. Ceder L, Lunsjo L, Olson O. Different ways to treat subtrochanteric fractures with the Medoff sliding plate. *Clin Orthop*. 1998; 348:101-106.
 21. Asher MA, Tipper JW, Rockwool CA, Zilber S. Compression fixation of subtrochanteric fractures *Clin Orthop*. 1976; 117:202-208.
 22. Michael W. Chapman's *Chapman's Orthopaedic Surgery* third edition I, 650-666.
 23. Sanders R, Regazoni P, Rout M. The treatment of subtrochanteric fractures of the femur using the dynamic condylar screw. Paper presented at the annual meeting of the American Academy of Orthopaedic Surgeons, Atlanta. GA February, 1988.
 24. Watson Jones, *Injuries of the thigh*, chapter 30 in *Watson-Jones Fractures and Joint Injuries*, 6th Edition; 2, 999-1003.
 25. Koch JC. The laws of bone architecture. *Am J Anat* 1917; 21:177-298
 26. Harty M The calcar femorale and the Femoral neck: *J Bone Joint Surg Am*. 1957; 39:625-630.
 26. Halder SC. The Gamma nail for peritrochanteric fractures *J Bone Joint Surg(Br)* 1992; 74:340-344.
 27. Chapman MW. The role of intramedullary nailing in fracture management. In: Browner BD, Edwards CD, eds. *The Science and Practice of Intramedullary Nailing*. Philadelphia: Lea & Febiger. 1987, 17-23.
 28. Bergman GD, Winquist RA, Mayo KA, Hansen STJ. Subtrochanteric fracture of the femur: fixation using the Zickel nail. *J Bone Joint Surg Am* 1987; 69:1032-1040.
 29. Chapman MW, Bowman WE, Csongradi JJ. The use of Ender's pins in extracapsular fractures of the hip. *J Bone Joint Surg Am*. 1981; 63:14-28.
 30. Jensen JS, Sonne-Holms, Tondevold E. Critical analysis of Ender nailing in the treatment of trochanteric fractures. *Acta Orthop Scand* 1980; 5(1):817-825.
 31. Slater J, Taylor J, Russell T, Walker B. Intramedullary nailing of complex subtrochanteric fractures of the femur. *Orthop Trans*. 1991; 15:774.
 32. Taylor D, Erpelding J. Treatment of comminuted subtrochanteric femoral fractures in a young population with a reconstruction nail. *Mil Med*. 1996; 161:735-738.
 33. Wiss DA, Brien WW. Subtrochanteric fractures of the femur. treatment by interlocking nailing. *Clin Orthop*. 1992; 283:231-236.
 34. Leung KS, SO WS, Shen WY, Hui PW. gamma nails and dynamic hip screws for peritrochanteric fractures *JBJS (Br)*. 1992; 74(B):345-51.
 35. Lei-Sheng Jiang, Lei Shen, Li-Yang Dai. Intra medullary Fixation of subtrochanteric fractures with Long proximal femoral nail or Long Gamma Nail; Technical Notes and Preliminary Results; *Ann Acad Med Singapore*. 2007; 36:821-826.
 36. Taglang G, Favrel E. 77 patients, mean age 75 years, one year follow up". Paper presented to advanced course in Intramedullary locking nailing, Courchel, France. *Gray's Anatomy*, 16th Edition, 1991, 151-153.
 37. Mc Kibbin B. The Biology of fracture healing in long bones. *JBJS (Br)*. 1978; 60:150-62.