



International Journal of Orthopaedics Sciences

ISSN: 2395-1958
IJOS 2018; 4(3): 95-98
© 2018 IJOS
www.orthopaper.com
Received: 20-05-2018
Accepted: 21-06-2018

Dr. Narendra Singh Kushwaha
Associate Professor, Department
of Orthopaedic Surgery, King
George's Medical University,
Lucknow, Uttar Pradesh, India

Dr. Devarshi Rastogi
Assistant Professor, Department
of Orthopaedic Surgery, King
George's Medical University,
Lucknow, Uttar Pradesh, India

Dr. Mukesh Kumar Dwivedi
PhD, Department of
Orthopaedic Surgery, King
George's Medical University,
Lucknow, Uttar Pradesh, India

Two stage revision arthroplasty for infected THA with handmade antibiotic impregnated cement hip spacer: A prospective cohort study

**Dr. Narendra Singh Kushwaha, Dr. Devarshi Rastogi and Dr. Mukesh
Kumar Dwivedi**

DOI: <https://doi.org/10.22271/ortho.2018.v4.i3b.20>

Abstract

Introduction: Periprosthetic joint infection is a serious problem and requires great effort and cost for its treatment. The issues related to this situation are duration of antibiotic, stages of surgery and time of reimplantation of prosthesis. The surgical solution may vary from Antibiotic suppression, Irrigation and Debridement, Head and Liner exchange, One stage exchange, two stage exchange and Resection Arthroplasty. Two stage revision remains the gold standard for the treatment of periprosthetic joint infection after THA. It has seen infection free survival rates of 80-100%. We aim to find the efficacy and cost effectiveness of handmade antibiotic impregnated articulating cement spacer over commercially available prefabricated hip spacer for the treatment of deep periprosthetic joint infection.

Material and methods: A total of 23 patients were enrolled in this prospective cohort study. In the two stages of revision, the first stage surgery comprised of removal of infected prosthesis and bone cement, thorough debridement of all infected and necrotic tissue and implantation of handmade articulating antibiotic impregnated cement hip spacer. Antibiotics were given for 6 weeks after first stage surgery based on culture sensitivity. Antibiotics were stopped two weeks prior to second stage to foresee the patient's response. Routine aspiration of the involved joint was done prior to 2nd stage. The decision to proceed with prosthesis implantation was determined by clinical evaluation, resolution of blood markers (ESR and CRP) and a negative hip joint aspirate. The second stage surgery consisted of removal of cement spacer and implantation of new prosthesis. Patients were evaluated for rate of infection control and hip joint function.

Results: The two stage revision total hip arthroplasty with handmade articulating antibiotic impregnated cement spacer was done in 23 patients. The mean age of the patients was 57+₋7 years, with 15 male and 8 females. All patients had deep chronic periprosthetic joint infection with increased ESR and CRP level. Coagulase negative staphylococci were the most common pathogen followed by Staphylococcus aureus. The mean time between the two stages is 16-20weeks. All hip cultures were found to be negative before second stage. Three patients had persistent joint infection following the first stage of surgery. In one patient the infection was cured by additional debridement and repeated first stage surgery. In two patients, infection was not cured, Resection Arthroplasty was done. 19 patients were free of infection at an average follow up of 24months. Infection free survival was 82.60% at the end of 2 years. HHS was 82 (Range) at 2 years follow up.

Conclusion: After evaluation of our 23 patients we conclude that two stage revision by hand made cement spacer for treatment of infected arthroplasty is an effective means of treating infected THR. Our handmade antibiotic impregnated cement spacer is safe and cost effective and provides effective local antibiotic delivery.

Keywords: Periprosthetic joint infection, Handmade spacer etc

Introduction

Periprosthetic joint infection is the most devastating complication of THA and requires great effort and cost for its treatment. The issues related to this situation are duration of antibiotic, stages of surgery and time of reimplantation of prosthesis^[1-2]. The incidence of PJI continues to range between 0.5% - 0.2% following primary THR^[3]. Management of PJI depends upon accurate diagnosis and successful treatment, both of which are challenging.

Correspondence

Dr. Devarshi Rastogi
Assistant Professor, Department
of Orthopaedic Surgery, King
George's Medical University,
Lucknow, Uttar Pradesh, India

A number of different treatment strategies have been described for the management of patients with infected THR. The decision regarding the ideal treatment procedure for management of PJI of the hip joint is based on several factors such as duration of symptoms, local soft tissue condition, prior surgeries, identification of pathogenic organisms and its virulence. Irrigation and debridement with prosthesis retention, may be considered in patients with early infections (4-6 weeks) and should be performed as soon as possible after the development of symptoms. It has less morbidity, shorter hospital stay and lower cost as compared to revision surgery. The reported rate of eradication varies from 21-89% [4-5]. One stage exchange has been employed primarily in Europe, several centres have reported their results with up to 100% success [6]. Resection remains a viable salvage procedure in cases where the infection is unable to be eradicated. The two stage revision offers a high success rate and it remains the gold standard for an infected THR with success rate up to 80-100% [7].

A wide variety handmade cement spacer with metal endoskeleton including cerclage wire, rush pins, kirshner wire and intramedullary nails have been developed. We selected 5.5mm Steinman pin as endoskeleton for our handmade cement spacer. Based on this observation, this study was aimed to find the efficacy and cost effectiveness of handmade antibiotic impregnated articulating cement spacer for the treatment of deep PJI of hip prosthesis. Further, we evaluated the recurrence of infection and determined the hip joint function postoperatively.

Material and Methods

This study was conducted at the Department of Orthopedic Surgery, King George's Medical University (KGMU), Lucknow. Patients were recruited from January 2016 to March 2017. All patients of infected hip who were admitted to the Department of Orthopedics were included in the study. All patients were screened and PJI was diagnosed according

to the criteria proposed by Parvizi *et al.* [8] The inclusion criteria of the subjects was: 1. Two positive periprosthetic cultures with matching organisms; 2. A sinus tract communicating with the joint. Having 3 of the following criteria- 1. Increased CRP (>100mg/L in acute PJI, >10mg/L in chronic PJI); 2. Increased Synovial WBC count (>10000 cells/micro L in Acute PJI, >3000 cells/micro L in chronic PJI); 3. Increased Synovial fluid PMN% (>90% in Acute PJI, PMN% >80% in chronic PJI); 4. Positive histological analysis of periprosthetic tissue (>5 neutrophils/HPF); 5. A single positive periprosthetic culture.

The two stage protocol was used. All the operations were done through same incision as index procedure. The first stage consisted of component removal, irrigation and debridement and implantation of handmade articulating antibiotic impregnated cement spacer. The type of antibiotic used in the spacer was determined by preoperative hip joint aspirate culture. We used combination of vancomycin 4 gm and gentamycin 2 gm per 40 gm cement. For handmade spacer we used 4.5 mm Steinman pin with antibiotic cement mould. The core part of femoral head was formed and placed at the tip of Steinman pin based on the size of acetabulum. The cement is wrapped over the stem part so that it should not become too thick, the neck part should be thicker to prevent fractures. Intravenous antibiotics were given postoperatively for 2 weeks based on culture sensitivity followed by 4 weeks of oral therapy. The patients were allowed non weight bearing walking with walker/crutches. ESR and CRP were checked every 15 days. The decision to proceed with implantation was determined by clinical evaluation, resolution of blood markers (ESR and CRP) and negative hip joint aspirate. The second stage of revision includes spacer removal, tissue sampling, irrigation and debridement and reimplantation. After the second stage, patients were treated with prophylactic antibiotic for 15 days. All the patients were followed up for a minimum of 2 years after implantation.

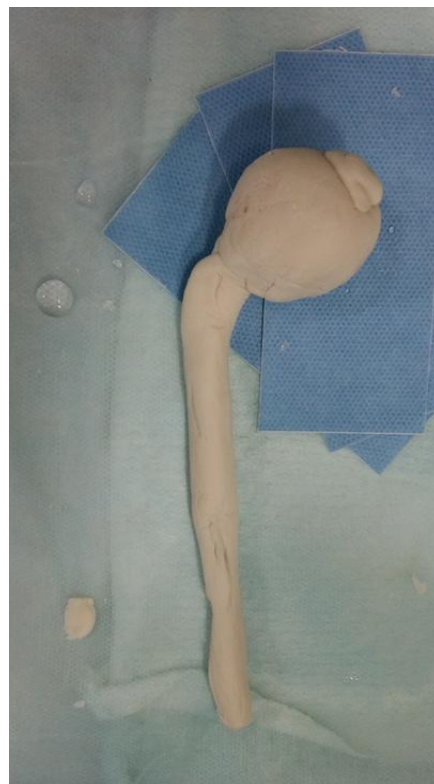

Fig 1: Handmade spacer

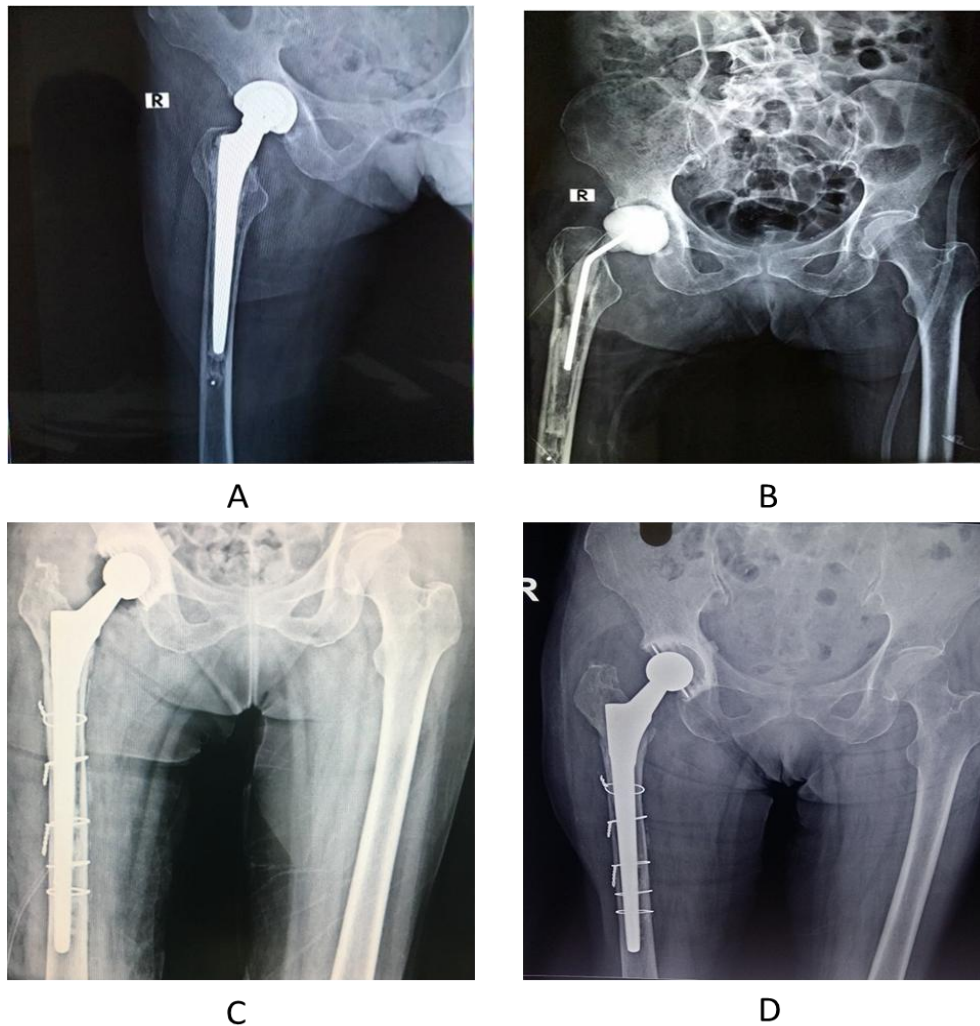


Fig 2: A: Pre Op X Rays; B: First stage revision with handmade cement spacer; C: Immediate Post Op second stage; D: 12 months follow-up

Table 1: Demography of the patients.

General characteristics of patients	
Number of patients (N)	23
Mean Age	57+/-7 years
Sex (Male/Female)	15/8
Characteristics of PJI	
1. Primary total hip	6
2. Bipolar/ unipolar hemiarthroplasty	8
3. Failed Osteosynthesis with infection	9

Table 2: Pathological organism observed.

Organisms	N
Coagulase negative Staphylococcus	6
Methicillin resistant Staphylococcus aureus	3
Methicillin sensitive Staphylococcus aureus	6
E Coli	1
Mycobacterium tuberculosis	1
Pseudomonas aeruginosa	2
Enterococcus faecalis	1
Staphylococcus epidermidis	1
Culture negative	2

Results

A total of 23 patients (15 males and 8 females) underwent two stage revision arthroplasty for chronic periprosthetic hip joint infection. The mean age of the patient was 57+/-7 years. All patients had chronic PJI with increased ESR and CRP levels. The handmade antibiotic impregnated cement spacer was retained for an average 16-20 weeks. Coagulase negative

staphylococci were the most common pathogen followed by Staphylococcus aureus. After an average follow up of 2 years, 19 patients with PJI remained clinically free of infection. Infection free survival was 82.60% at the end of 2 years. In 3 patients there was recurrence of infection by the same organism. In 2 patents, infection was not eradicated even by repeated debridement and change of antibiotic cement spacer. Resection arthroplasty was done. In one patient infection was eradicated by repeated debridement and change of cement spacer. Complication of handmade cement spacer were also noted like dislocation of cement spacer in one patient and perforation of medial wall of acetabulum by Steinman pin in one patient. Hip joint function was satisfactory in all patients with HHS from preoperatively mean of 43(28-62) to a postoperative mean of 87(79-96) at 2 years follow up.

Discussion

A number of treatment options are available and have been described in the literature for the management of PJI. The ideal treatment of PJI is still a matter of debate. Although the two stage revision is the gold standard for the management of PJI [9]. The decision regarding the management of PJI is based on several factors such as duration of symptoms, local soft tissue condition, identification of pathogenic organisms and its virulence [10]. The surgical solution available in the literature varies from Antibiotic suppression, Irrigation and Debridement, Head and Liner exchange, one stage exchange, two stage exchange and Resection Arthroplasty. We preferred to use handmade articulating antibiotic impregnated cement

spacer for the interim period over prefabricated articulating spacer and static spacer. The articulating spacers maintain leg length and soft tissue tension which makes the second surgery easy. The main concern with static spacer is that patient has to be bed ridden for longer period and it makes the exposure difficult at reimplantation due to quadriceps contracture [10]. The Prefabricated/custom made spacers are costly as compared to Handmade cement spacer and in developing countries where cost is the deciding factor the handmade spacers are good choice since it permits the surgeon to treat PJI at much lower cost with almost similar efficacy. In this study, we concluded that handmade cement spacer is cost effective and provides satisfactory results with reduced complications.

Fehring *et al.* reported a failure rate of 63% for treatment of periprosthetic joint infection by using irrigation and debridement alone [11]. They found that only 56% of patients undergoing Incision and Drainage in the first month after index surgery failed as compared to a 76% failure rate in the second and third month. Haddad *et al.* followed up 50 patients for an average of 5.8 years (range 2-8.7 years). Antibiotic-loaded beads were placed in the femoral shaft and an antibiotic-loaded cement ball in the acetabulum and found an infection recurrence rate of 8%. Patients with static spacer requires long duration of bed rest so we do not recommend static spacer. Younger *et al.* followed up 61 patients undergoing a two stage revision using a prosthesis of antibiotic loaded acrylic cement (Prostalac), for an average of 43 months, their success rate was 94%. Prostalac is costly as compared to handmade spacer. Yamamoto *et al.* used cement moulds with 2.0mm Kirschner wires. They followed 17 patients with success rate of 100%. Darbhakula *et al.* used cement mould with central rod pin and followed 20 patients for 38 months with success rate of 100%. Etienne *et al.* used autoclaved femoral component/ polyethylene acetabular component in 32 patients and followed up for 19 months, with success rate of 91%. They rely on coating the femoral component with a layer of cement. We do not have any experience with it. In our patients, we use only handmade cement spacer. We used 4.5 mm Steinman pin with antibiotic cement mould. Steinman pin act as endoskeleton. After putting cement spacer we apply cement in doughy state over the calcar to provide additional strength to the spacer and to prevent dislocation. We followed 23 patients for a period of 02 years with success rate of 86.9%. Our results are comparable to prefabricated spacers described in literature. In 2 patients there was recurrence of infection by the same organism, so repeated debridement and reimplantation of cement spacer was done. Our Handmade spacer can withstand toe touching walking with walker. On the contrary prefabricated spacer provides better stability but they are costly. They are available in two sizes i.e. small and large, no in between sizes are available. While in handmade spacer we can tailor the size of spacer according to the size of acetabulum and thickness of femoral canal. The main limitation of the present study are the small sample size, lack of comparator group and relatively short duration of follow up.

Conclusion

To conclude, our finding suggest that two stage revision with an intermediate handmade antibiotic impregnated cement spacer was an effective means of treating infected THR. Our handmade spacer is cost-effective and provides effective local antibiotic delivery. It helps in early mobilization, facilitates

reimplantation, and improves patient satisfaction.

References

- Goulet JA, Pellicci PM, Brause BD, Salvati EM. Prolonged suppression of infection in total hip arthroplasty. *J Arthroplasty*. 1988; 3:109-116.
- Canner GC, Steinberg ME, Heppenstall RB, Balderston R. The infected hip after total hip arthroplasty. *J Bone Joint Surg Am*. 1984; 66:1393-1399.
- Engesæter LB, Dale H, Schrama JC, Hallan G, Lie SA. Surgical procedures in the treatment of 784 infected THAs reported to the Norwegian Arthroplasty Register. *Acta Orthop*. 2011; 82:530-537.
- Neogi DS, Yadav CS, Madhuri VP. Risk factors associated with acute hip prosthetic joint infections and outcome of treatment with a rifampin-based regimen. *ActaOrthop*. 2008; 79:455-6.
- Meehan AM, Osmon DR, Duffy MC, Hanssen AD, Keating MR. Outcome of penicillin-susceptible streptococcal prosthetic joint infection treated with debridement and retention of the prosthesis. *Clin Infect Dis*. 2003; 36:845-9.
- Klouché S, Leonard P, Zeller V. Infected total hip arthroplasty revision: one- or two-stage procedure? *Orthop Traumatol Surg Res*. 2012; 98(2):144-50.
- Hsieh PH, Shih CH, Chang YH, Lee MS, Shih HN. Two stage revision hip arthroplasty for infection: comparison between the interim use of antibiotic-loaded cement beads and a spacer prosthesis. *J Bone Joint Surg Am*. 2004; 86:1989-1997.
- Diagnosis of Periprosthetic Joint Infection Following Hip and Knee Arthroplasty Javad Parvizi, Safa Cyrus Fassihi, BS, Mohammad A. Enayatollahi, *Orthop Clin N Am*. 2016; 47:505-515.
- Preformed antibiotic-loaded cement spacers for two-stage revision of infected total hip arthroplasty. Long-term results. Romanò CL1, Romanò D, Albisetti A, Meani E *Hip Int*. 2012; 22(8):S46-53. doi: 10.5301/HIP.2012.9570.
- Two-stage Revision for Periprosthetic Hip and Knee Joint Infections. Sunil Gupur Kini, Ayman Gabr, Rishi Das, Mohamed Sukeik, and Fares Sami Haddad *The Open Orthopaedics Journal*. 2016; 10(2, M2):579-588.
- Failure of Irrigation and Debridement for Early Postoperative Periprosthetic Infection Thomas K. Fehring, Susan M. Odum, Keith R. Berend, William A. Jiranek, Javad Parvizi, Kevin J. Bozic, Craig J. Della Valle, Terence J Gioe *Clin Orthop Relat Res*. 2013; 471:250-257.